Orthodontic Definition

Open bite (Negative overbite):

Inherited, developmental, or acquired malocclusion, whereby no vertical overlap exists between maxillary and mandibular anterior teeth (anterior open bite), or no vertical contact is exhibited between maxillary and mandibular posterior teeth (posterior open bite).

Subdivided to:

1. Dental open bite: A localized open bite that involves only a few teeth due to a digit-sucking habit or other local factors.

2. Skeletal open bite: Caused by the divergence of the skeletal mandibular or/and maxillary planes leading to increased facial height as in the case of posterior rotational growth of the mandible (Fig



Figure 1 shows the anterior open bite (left) and posterior open bite (right)

Deep bite (Excessive overbite): A type of malocclusion in which the vertical overlap of the anterior teeth is increased beyond the ideal relationship (more than the normal range which is 2-4 mm); it is frequently associated with decreased vertical facial dimensions, subdivided into;

1- Non-traumatic deep bite: In which the deep bite is still associated with teeth–teeth relation.



Figure (2) Deep bite in general

2. Traumatic deep bite: in which the deep bite is associated with the Impingement of the mandibular incisors in the mucosa palatal to the maxillary incisors commonly seen in malocclusions with extremely deep bite as in severe Class II malocclusion.



Figure (3) Traumatic deep bite

3. Bi-traumatic deep bite: usually seen in some Class II, Division 2 malocclusions with minimal overjet, the reclined maxillary incisors may impinge in the keratinized tissue labial to the mandibular incisors, causing gingival recession at the same time there is a trauma to palatal mucosa caused by lower incisors.



Figure (4) Bi-traumatic deep bite

Buccal overjet:

The distance between the buccal surfaces of the maxillary posterior teeth and the buccal surfaces of their mandibular antagonists. An unofficial term is sometimes used to indicate whether or not there is a tendency for a posterior crossbite.

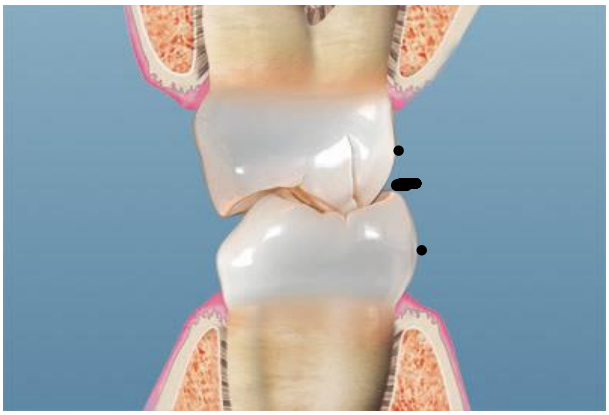

Figure (5) demonstrates buccal overjet.

Crossbite:

An abnormal relationship of one or more teeth to one or more teeth of the opposing arch, in the buccolingual or labiolingual direction. A crossbite can be dental or skeletal in etiology. [Note: The appropriate type of crossbite can be specified by identifying the teeth or jaws that deviate the most from their ideal position (e.g. when a crossbite is mainly due to a narrow maxillary arch the correct term is "maxillary posterior lingual crossbite" as opposed to "mandibular posterior buccal crossbite" which indicates wider mandibular arch).

ETIOLOGY OF CROSSBITE

Etiology of Dental Crossbite

I. Anomalies of the number of teeth

Supernumerary teeth or Missing teeth.

II. Anomalies of tooth shape III. Anomalies of tooth size

1. Microdontia
2. Macrodontia

Etiology of Skeletal Crossbite

I. Habits—Thumb sucking, mouth breathing, etc.
II. Traumaatbirth(ankylosisoftheTMJbyforcepsinjury during delivery).

Classification of crossbite:

- ***Based on Location***
  1. ANTERIOR CROSSBITE:

• According to no. of teeth involved:
A. Single tooth Crossbite. B. Segmental Cross bite.

2. POSTERIORCROSSBITE:

- **According to no. of teeth involved:**

A. Single tooth Crossbite. B. Segmental Crossbite.

• According to the side involved: A. Unilateral. B. Bilateral.

• According to extent:
A. Single posture Cross bite. B. Buccal Non-occlusion (Scissor bite).

C. Lingual Non-occlusion (Buccal crossbite).

Based on the Etiologic Factor

1. Skeletal crossbite.
2. Dental crossbite. 3. Functional crossbite.

If one or more of the lower incisors is in front of the upper incisors, the condition is called **reverse overjet**. as shown.



Figure 6 shows reverse overjet.

Posterior crossbite: A crossbite due to the buccal displacement of the affected posterior tooth (or group of teeth) from its (their) ideal position relative to its (their) antagonist(s). Subdivided into:

1. **Unilateral posterior**: Affects only one side of the dental arch, and can be either:

   a-True unilateral posterior crossbite: Caused by the asymmetry present in the dental arch and usually is not associated with deviation of the mandible.

   b- False unilateral posterior crossbite: caused by narrowing of the maxilla or widening of the mandible leading to cusp–cusp relation then the patient tries to get maximum intercuspation by deviation of the mandible to one side leading to unilateral crossbite.

2. **Bilateral posterior crossbite**: Caused by severe maxillary collapse or/ and mandibular widening, there is no mandibular deviation during closure.

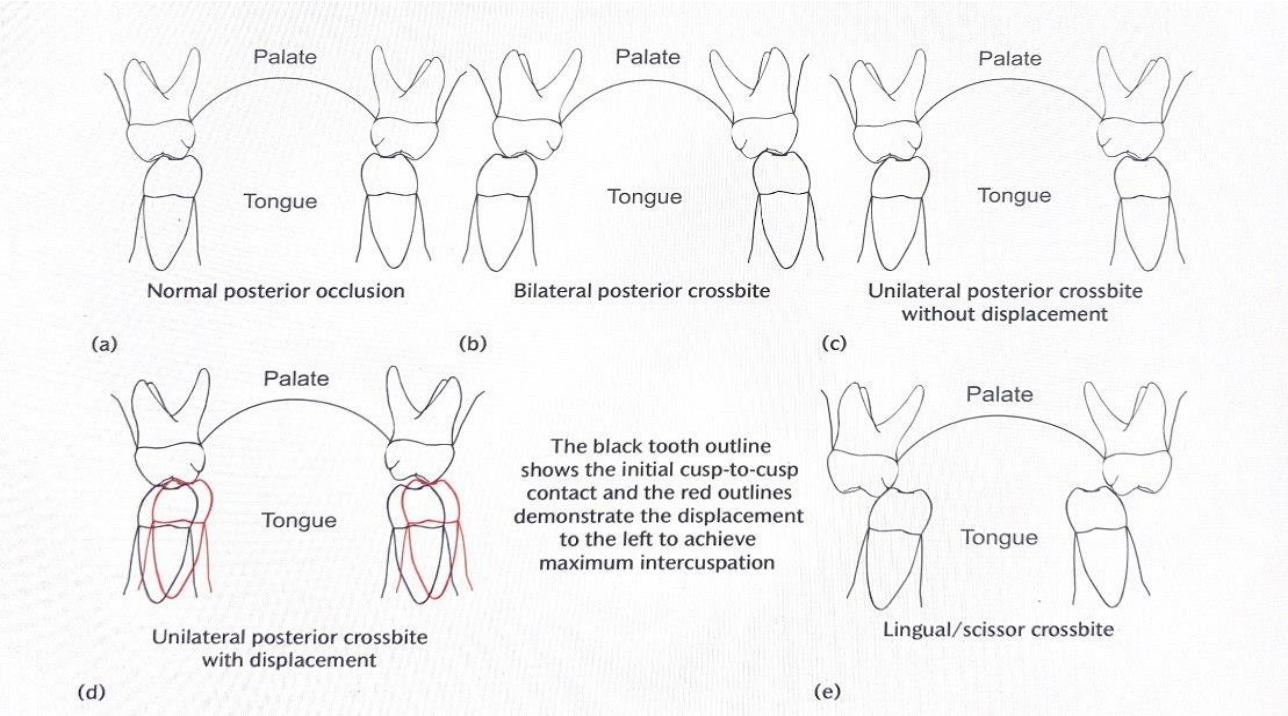

Diagrams representing the different types of posterior crossbite.

1. **Skeletal crossbite**: It is a crossbite with a skeletal basis (constricted maxilla and/or wide mandible).

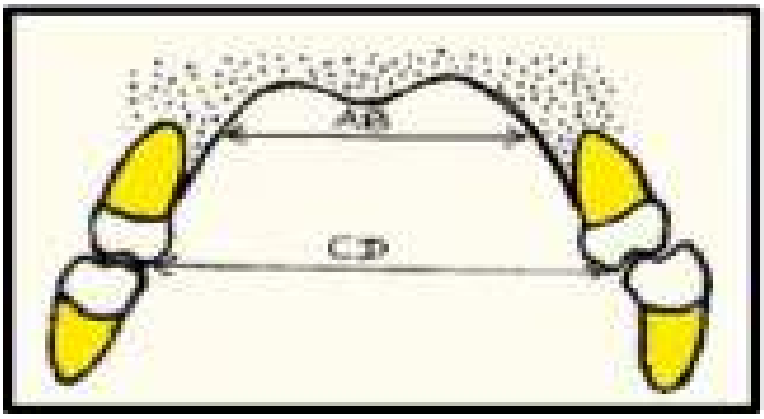

Figure 7 Palatal arch width (AB) is inadequate and quite less than dental arch width (CD)

Dental crossbite: It is caused by distortion of the dental arch where the jaws are of normal proportions.

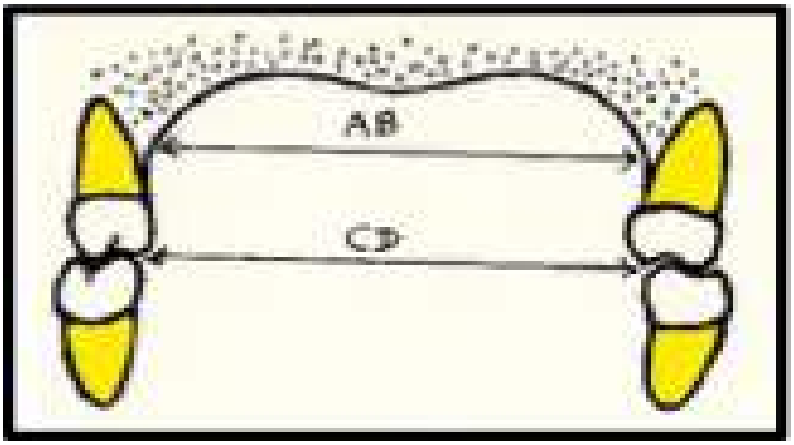

Figure 8 Palatal arch width (AB) is adequate and nearly equal to dental arch width (CD)

Functional crossbite (False): It is a crossbite due to a functional shift of the mandible, it should be treated early if recognized, because if uncorrected, true crossbite may result in modification of growth.

Scissors-bite: A situation in which several adjacent posterior teeth overlap vertically in habitual occlusion with their antagonists, without contact with their occlusal surfaces. The deviation of the affected teeth from their ideal position could occur either in the maxillary buccal or mandibular lingual direction, where mandibular dentition are completely contained within the maxillary dentition in habitual occlusion.



Figure 9 A lingual (scissors) crossbite.

Spacing of the dentition: A dental arch with spacing of more than the accepted range **(2 mm or more)**, it is either:

a- Localized: Localized in one position like median Diasthema that is caused by abnormal frenal attachment.

b- Generalized: Affect the whole dental arch mostly caused by abnormal soft tissue function like tongue thrust.



Figure (10) localized spacing also called diastema (left), generalized spacing (right)

Crowding of the dentition: A dental arch with crowding of more than the accepted range (2 mm or more), either caused by local factors like early extraction of deciduous teeth or general factors like a collapsed maxillary arch that leads to crowding of the whole arch.



Figure 11 demonstrates how the crowding seen.

Imbrication: The overlapping of incisors and canines in the same arch, usually due to crowding.

Midline shift (deviation): Occurs when the upper and lower dental midline are not coinciding, and subdivided into:

1. Associated with mandibular deviation during closure as in case of premature occlusal contact.
2. Not associated with mandibular deviation during closure as in the case of unilateral missing of the teeth or crowding.

Midline shift may be due to a shift of upper or lower teeth or sometimes both of them and it is very important to determine that during diagnosis and treatment planning especially to choosing a tooth or teeth to be extracted, in addition to that it is important to differentiate between midline shift of the dentition and the face because we may see one of them or sometimes both of them.

Midline shift of the face is mostly caused by abnormal skeletal factors (like unilateral hyperplasia of the mandible) or deviation of the nose.
Midline shift of the dentition is mostly associated with unilateral extraction or congenital missing or impaction of a tooth.

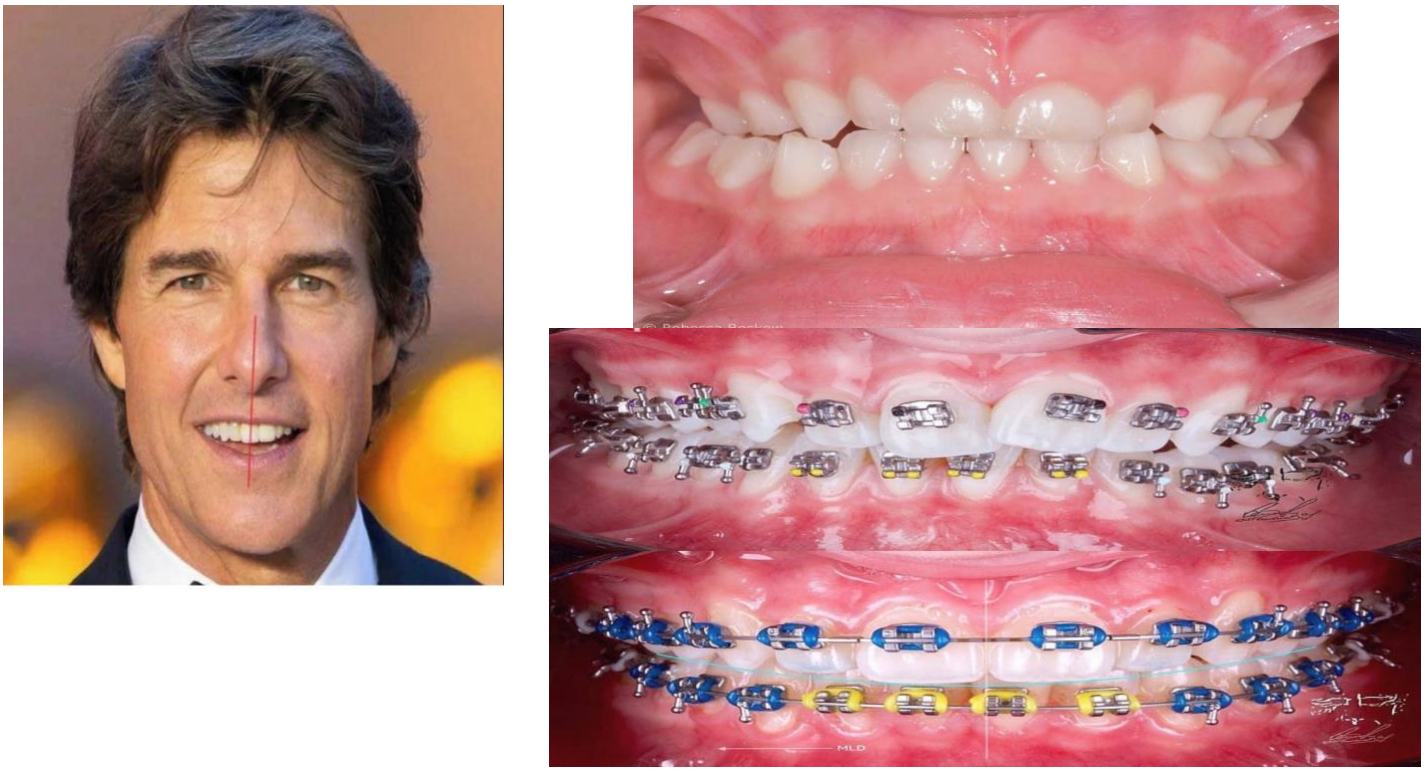

Figure 12 shows the midline deviation.

Infraposition (Infraocclusion): A situation in which a tooth or group of teeth is positioned below the occlusal plane; commonly due to a deleterious habit or to ankylosis.



Figure (13) shows infra occlusion.

Overeruption (Supraeruption, Supraposition, Supraocclusion): The situation whereby an unopposed or non-occluding tooth extends beyond the occlusal plane.



Figure (14) shows supra occlusion.

Dental retrusion: Posterior position of a tooth or group of teeth but keeping their long axis with normal inclination.

Dental retroclination: Posterior positioning of a tooth or group of teeth but their long axis is tipped labio-lingually.

[Note: A tooth can be retrusive without being retroclined if it is positioned too far posteriorly but has a normal inclination.]

Dental proclination: Anterior positioning of a tooth or group of teeth but their long axis is tipped labially.

Dental protrusion: Anterior positioning of a tooth or group of teeth but keeping their long axis with normal inclination.

Impaction of teeth:

Occurs when the eruption is completely blocked by other teeth due to crowding, it tends to affect the last teeth to erupt in each segment (as in the case of canine).

Rotation of teeth: A type of malocclusion in which there is a rotation of a tooth about its long axis, most evident when viewing the tooth from an occlusal perspective mostly, caused by crowding and subdivided into:

1**- Mild (less than 90°)**: Can be treated easily by removable orthodontic appliance using a couple force system.

2- **Sever (more than 90°)**: Must be treated by Fixed orthodontic appliance only

Displacement of tooth: Abnormal position of the tooth (crown and root) in the dental arch

Overlapping of teeth: Abnormal position of the crown of the tooth in the dental arch while there is a normal position of root in the jaw.

Best wishes.