Vesiculobullous diseases

Vesiculobullous disease is a type of mucocutaneous disease characterized by vesicles and bullae (i.e. blisters). Both vesicles and bullae are fluid-filled lesions, and they are distinguished by size (vesicles being less than 5 mm and bulla being larger than 5 mm)**,** In the case of vesiculobullous diseases which are also immune disorders, the term ***immunobullous*** is sometimes used. Examples of vesiculobullous diseases include:



- ***Infectious:*** *(viral)*
  - Herpes simplex
  - Varicella-Zoster infection
  - Hand, foot and mouth disease
  - Herpangina
  - Measles (Rubeola)
- ***Immunobullous****:*
  - Pemphigus vulgaris
  - Mucous Membrane Pemphigoid(MMP).
- ***Genetic:***
  - Epidermolysis bullosa.

Types of pemphigus

The different types of pemphigus are diagnosed based on the location of the blisters. They include:

Pemphigus vulgaris

Pemphigus vulgaris is the most common type of pemphigus. Blisters usually first **appear in the mouth**. **The blisters don't itch**. They can be **painful**. **Blisters may then appear on the skin and sometimes on the genitals**.



Pemphigus foliaceus

Pemphigus foliaceus **doesn't cause blisters in the mouth**. The blisters first appear on **the face and scalp**. Blisters then appear on **the chest and back**. The blisters are **usually itchy and painless**.



Pemphigus vegetans

Pemphigus vegetans causes blisters that appear on **the groin, under the arms, and on the feet.**



Paraneoplastic pemphigus

A very rare type of pemphigus that occurs in people with some **cancers is called paraneoplastic pemphigus**. The blisters and sores may appear in the **mouth**, on the

lips, and on the skin. This type may also **cause scars on the eyelids and eyes**. It can also cause lung problems.



Pemphigus Vulgaris

Pemphigus vulgaris is a rare autoimmune disease that **causes painful blistering** on the skin and mucous membranes . Pemphigus vulgaris is the most common type of a group of autoimmune disorders called pemphigus characterized by **intraepithelial blister formation and cell separation known as acantholysis.** Pemphigus vulgaris affects the mucous membranes, which are found in areas including the: mouth , throat, nose, eyes, genitals, lungs. This disease usually starts with blisters **in the mouth and then on the skin. The blisters sometimes affect the membranes of the genitals**.

Pemphigus vulgaris can be dangerous. Treatment is essential, and typically involves the use of corticosteroids to suppress the immune system. The condition can cause serious complications if it isn't treated. Some of these complications can be fatal.

Causes

The immune system produces proteins called antibodies. Antibodies normally attack harmful foreign substances like bacteria and viruses. Pemphigus vulgaris occurs when the immune system mistakenly makes antibodies against proteins in healthy skin and mucous membranes.

The antibodies break down the bonds between the cells, and fluid collects between the layers of the skin. This leads to blisters and erosions on the skin.

Signs and symptoms

The symptoms of pemphigus vulgaris include:

Painful blisters that start in **the mouth** and Blisters may then appear on the skin and sometimes on the genitals. **The blisters don't itch**,Skin blisters near the surface of the skin that come and go,Oozing, crusting, or peeling at the blister site.

Pemphigus vulgaris **isn't contagious and cannot be transmitted from one person to another. It also doesn't appear to be transmitted from parent to child**. However, a person's genes can put them at a higher risk for the condition. Pemphigus vulgaris can affect people of all races, genders, and ages. However females between 40-60 years old are predominately most affected. Lesions often first appear in the mouth but spread widely on the skin. Vesicles are **fragile and infrequently seen intact in the mouth**. Residual erosions are superficial, painful and tender.



Gently stroking or pushing the intact mucosa with blunt instrument can cause a vesicle or bulla to appear and this test known as positive Nikolsky's sign.

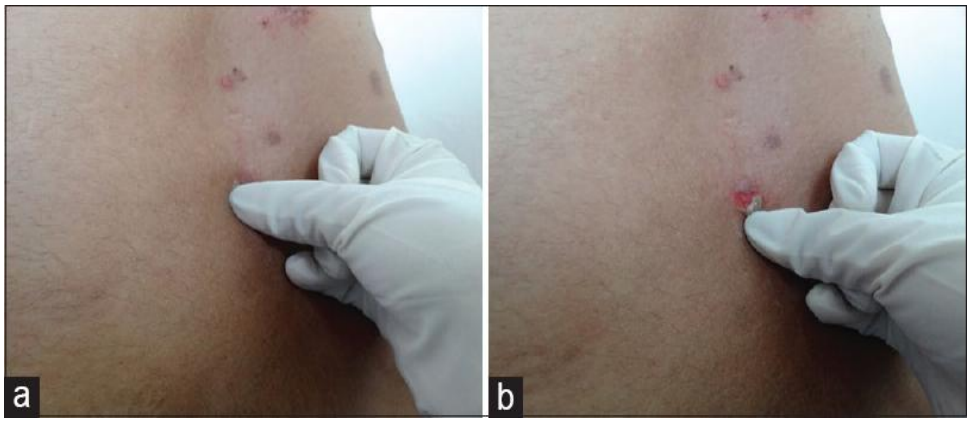

Skin lesions consist of vesicles or bullae varying from a few mm – cm.The bullae at first contain clear fluid which may then become purulent or haemorrhagic. Rupture of vesicle leaves painful ragged erosions. Protein, fluid and electrolytes are lost from the raw areas and they become **secondary infected**. **Without treatment, death usually follows**, but **immunosuppressive treatment is usually life – saving.**

Histopathology: Pemphigus vulgaris appears **as intraepithelial clefting with keratinocyte acantholysis(cell separation)**. Loss of desmosomal attachments and reaction of tonofilaments results **in Free-Floating or acntholytic , Tzanck cells. (large round keratinocyte cells) (Tzanck cells present in Pemphigus vulgaris, Chicken pox, Herpes simplex and Herpes zoster.**

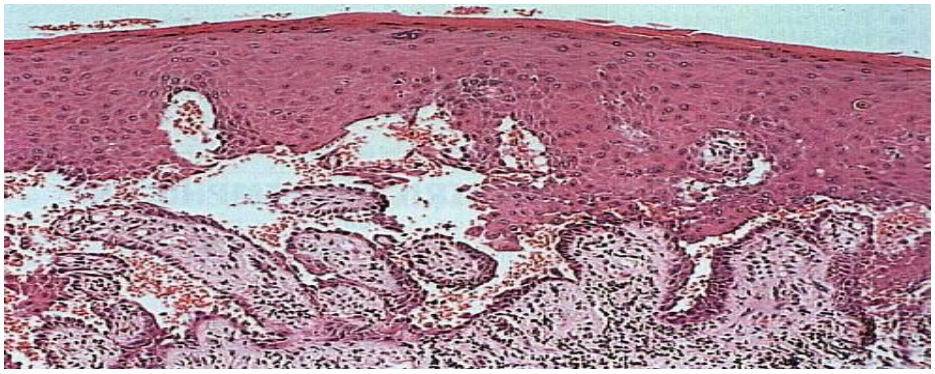

Treatment

Treatment is aimed to reducing pain and symptoms and preventing complications like infection. It involves one or more drugs including Corticosteroids and immune-suppressing drugs.

Mucous membrane pemphigoid (MMP)

Is a group of rare chronic autoimmune disorders characterized by blistering lesions that primarily affect the various mucous membranes of the body. The mucous membranes **of the mouth and eyes** are most often affected. The mucous membranes of the nose, throat, genitalia, and anus may also be affected. The term **cicatricial(scarring) pemphigoid** is sometimes used for this group of disease but particularly applies to **ocular involvement where scarring is prominent and impairs sight.**

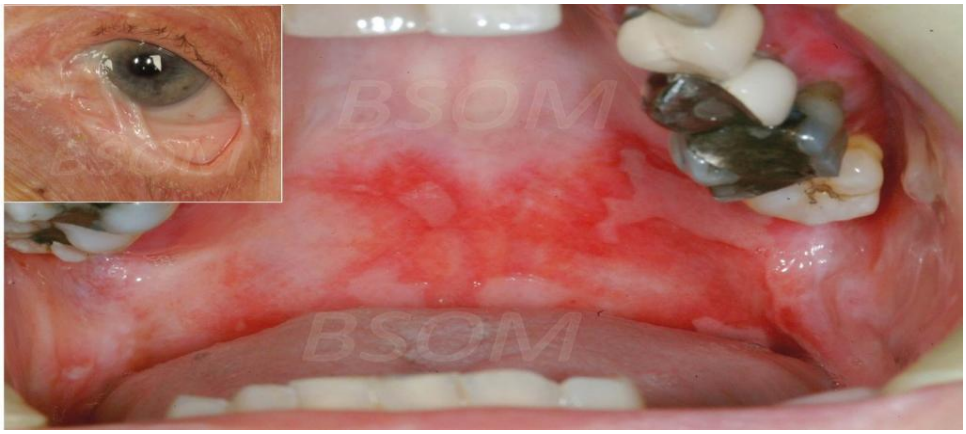

MMP is an autoimmune disease that is characterised by blistering lesions on mucous membranes. Areas commonly involved are the **oral mucosa** (lining of the mouth) and **conjunctiva** (mucous membrane that coats the inner surface of the eyelids and the outer surface of the eye). Other areas that may be affected include the nostrils, oesophagus, trachea and genitals. Sometimes the skin may also be involved where blistering lesions can be found on the face, neck and scalp.

Signs & Symptoms

Mucous membrane pemphigoid is predominantly a disease of the elderly with a peak incidence at around 70 years. However, childhood cases have been reported. It appears to be twice as common in women than men.

MMP is characterized by the development of recurring blistering lesions affecting the mucous membranes of the body. These lesions may result in **scarring** of the affected area. Specific symptoms and severity vary from person to person depending upon the specific sites involved.

The mucous membranes lining the **mouth and eyes are most commonly affected**. In some cases, the first sign of MMP is **a red and blistered mouth.** The gums (gingivae), roof of the mouth (palate), and the mucous membrane lining the inner cheek (buccal mucosa) may be affected. Involvement of the gums usually results in very red, tender gums that bleed easily(**Desquamative gingivitis**), Blistering lesions may spread to affect the (esophagus) as well as the (larynx) potentially resulting in difficulty swallowing **(dysphagia) and hoarseness**. In many cases of **MMP**, the mucous membranes lining the eyes (conjunctiva) may be involved. Inflammation of conjunctiva **(conjunctivitis)** or erosions forming on the conjunctiva may be the initial signs of ocular involvement in **MMP**.



In approximately 20-30 percent of cases, the skin may become involved. In these patients, the skin of the head and neck is usually affected. Skin lesions may be either fluid-filled blisters (bullous) or reddish (erythematous) plaques, which may bleed or itch. Eventually they scar upon healing. Scarring may result in areas of discoloration of the skin **(known as hyperpigmentation when it is darkened patches and hypopigmentation when it is light patches)**. Involvement of the scalp may lead to patchy areas of **hair loss (alopecia).**

MMP usually has a long duration with frequent remissions and recurrence.

Treatment

The primary aim of treatment is to stop blister formation, promote healing and prevent scarring. Systemic therapy for severe disease usually involves a combination

of **systemic corticosteroids** (sometimes in high dose), and **immunosuppressive agents**, with topical use of corticosteroid creams or ointment and eye drops.

Oral mucosal lesions Associated with dermatological diseases

Lichen Planus (LP): Is relatively a common chronic dermatological disease of skin and mucous membranes found in 1-2% of population. Lichen planus is a long-term condition that affects the skin and mucus membranes. When it affects the mouth it is called **oral lichen planus**, and appears as **white patches or web-like threads inside the cheeks.**

Causes

Lichen planus is a **T cell-mediated autoimmune disorder** in which inflammatory cells attack an unknown protein within the skin and mucosal keratinocytes.

The cause of lichen planus is usually not known, although possible causes include:

- The main etiological factor of lichen planus is Physical and emotional stress.
- Localised skin disease such as herpes zoster

- **Hepatitis C**, a virus that attacks the liver
- Certain medicines (**oral lichenoid drug reaction**), including some drugs used to treat high blood pressure, diabetes, heart disease, and malaria.
- An autoimmune reaction
- Genetics and immunity may be involved.
- Reactions to metal fillings in the teeth(**Lichenoid reaction to metallic fillings**)

Oral lichenoid lesions



Lichenoid drug reaction



Lichenoid reaction to amalgam

Clinical Features

Occurs predominantly in females with a female: male ratio of 4:1and in the age group of third to seventh decade in life. It is seen frequently in all regions of the oral mucosa, mostly noticed **in buccal mucosa, gingiva and tongue**. They are present **bilaterally** in most cases.

Classically present as six types cinically: **Reticular** (**fine white striae Wickham's striae**, cross each other in the lesion), **Atrophic**, **papular type, bullous type, plaque type, erosive or ulcerative type.** The reticular type of oral lichen planus is often **asymptomatic**,only can be seen clinically. Ulcerative type in which erythematous areas are seen surrounded by reticular elements.

Oral lichen planus is classically present as lesion with radiating **whitish gray lines thread like papules, Bilateral in presentation**. They can be lacy or reticular, patches or strings. The occurrence and distribution of lesion in the oral mucosa is **80% in the buccal mucosa**, 65% in the tongue, 20% lips, <10% seen in floor of mouth and palate. Vesicle and bulla are seen in the oral lesions of lichen planus. **The disease manifests in the oral cavity several weeks before the skin lesions.** The **reticular form** has a better prognosis as 40% of cases has spontaneous remission,the **erosive type** being long standing and with frequent exacerbations and **severe pain and complications.**

Types of LP

Lichen planus can appear in the mouth in several different patterns.

1- Reticular pattern, is commonly found on the **cheeks as lacy web-like, white threads that are slightly raised**. These lines are sometimes referred to as **Wickham's Striae**. The name lichen comes from a plant that is often seen growing on rocks with its mossy, web-like appearance.

- Symmetrical white lace-like pattern on **buccal mucosa** (inner aspects of cheeks)
- There may be **no symptoms** or discomfort and soreness.
- May affect tongue or gums.
- May ulcerate



2- Erosive pattern can affect any mucosal surface, including the cheeks, tongue, and gums. This form often appears **bright red**. **Painful and persistent erosions and ulcers** , individuals with erosive lichen planus are

uncomfortable when eating and drinking, particularly with extremes of temperature, acidic,coarse,or spicyfoods. In severe cases, ulceration can develop. Individuals affected by ulcerations may experience pain even when not eating or drinking.

- **Red lesions** often with a **whitish border**
- My **cause erosions** (superficial ulceration)
- Most often affects the **gums (gingiva) and lips**
- Can be **very painful**
- May be associated with erosive lichen planus affecting genital sites



3- Plaque like lichen planus :A less common form of lichen planus which appears as a **dense thickening of the mucosal tissue** .

- Usually seen in **smokers**
- Confluent **white patches** similar to oral keratoses



Other uncommon types

4- Papular type

5- Atrophic type **6. Bullous type**

Histological Features

The three classical histological feature of oral lichen planus are:

- Liquefaction degeneration of basal layer
- Overlying keratinization
- Lymphocytic infiltrate within the connective tissue that is dense and resembles a band.

Typical histopathological examination from the lesional biopsy reveals **Rete-ridges characteristically are "saw tooth" in appearance**. Mononuclear infiltration of **the T-lymphocytes cells and histiocytes form a typical band like an appearance subepithelially**. The intraepithelial band-like T- Lymphocyte cells and degenerating keratinocytes form the **Colloid bodies** or **Civattes bodies(apoptotic keratinocytes)** which are homogeneous globules that are eosinophilic in nature .



Epidermolysis Bullosa

Is a group of rare **hereditary or genetic medical conditions** that result in easy blistering of the skin and mucous membranes. Blisters occur with minor trauma or friction and are painful. Its severity can range from mild to fatal. Those with mild cases may not develop symptoms until they start to crawl or walk. Complications may include esophageal narrowing, squamous cell skin cancer. There are four main types: epidermolysis bullosa simplex (EBS), dystrophic epidermolysis bullosa (DEB), junctional epidermolysis bullosa (JEB), and Kindler syndrome.

Clinical Features

The feature common to all subtypes of epidermolysis bullosa is **bulla formation** from minor trauma, usually over areas of stress such as the elbows and the knees. Onset of disease is seen during infancy or early childhood for the hereditary forms, Blisters may be widespread and severe and may result in scarring and atrophy. Nails may be dystrophic in some forms of this disease. Oral manifestations include bullae that heal with scar formation, and **hypoplastic teeth** .

There is no cure for the condition. Management involves wound care, pain control, controlling infections, nutritional support, and prevention and treatment of complications.