White Lesions

Lesions of the oral mucosa, which are white, result from the scattering of light through a thickened layer of keratin , epithelial hyperplasia(increased cell numbers), intracellular epithelial edema, and/or reduced vascularity of subjacent connective tissue. White or yellow-white lesions may also be due to fibrinous exudates covering an ulcer, submucosal deposits, surface debris, or fungal colonies.

Focal (Frictional) Hyperkeratosis

Etiology: Focal (frictional) hyperkeratosis(thickening) is a white lesion that is related to **chronic rubbing or friction** against an oral mucosal surface. This results in a presumably protective hyperkeratotic white lesion that is analogous to a callus on the skin.

Clinical Features

Friction-induced hyperkeratoses occur in areas that are commonly traumatized, such as the lips, lateral margins of the tongue, buccal mucosa along the occlusal line, and edentulous alveolar ridges. Chronic cheek or lip chewing may result in opacification (keratinization) of the affected area. Chewing on edentulous alveolar ridges produces the same effect.



Diagnosis

Careful history taking and examination should indicate the nature of this lesion. If the practitioner is clinically confident of a traumatic cause, no biopsy may be required. Patients should be advised to discontinue the causative habit or the offending tooth or denture should be smoothed. The lesion should resolve or at least should be reduced in intensity over time,

confirming the clinical diagnosis. Resolution of the lesion would allow unmasking of any underlying lesion that may not be related to trauma. If the clinical diagnosis is in doubt, a biopsy should be taken.

Treatment : Observation is generally all that is required for simple frictional hyperkeratotic lesions. Control of the habit causing the lesion should result in clinical improvement. No malignant potential exists.

White Lesions Associated With Smokeless Tobacco

The clinical results of long-term exposure to smokeless tobacco include the development of oral mucosal white patches with a slightly increased malignant potential, dependence, alterations of taste, acceleration of periodontal disease, and significant amounts of dental abrasion.

Clinical Features

White lesions associated with smokeless tobacco develop in the immediate area where the tobacco is habitually placed. The most common area of involvement is the mucobuccal fold of the mandible in the incisor or the molar region. **The mucosa develops a granular to wrinkled appearance**. In advanced cases, a heavy, folded character may be seen. Less often, an erythroplakic or red component may be admixed with the white keratotic component. The lesions are generally painless and asymptomatic, and their discovery is often incidental to routine oral examination.



Treatment and Prognosis

With discontinuation of smokeless tobacco use, some lesions may disappear after several weeks. It would be prudent to perform a biopsy on persistent lesions. A long period of exposure to smokeless tobacco increases the risk of transformation to verrucous or squamous cell carcinoma, although this risk is probably low.

Nicotine Stomatitis

Etiology: Nicotine stomatitis is a common tobacco-related form of keratosis. It is typically associated with pipe and cigar smoking, with a positive correlation between intensity of smoking and severity of the condition. The importance of the direct topical effect of smoke can be appreciated in instances in which the hard palate is covered by a removable prosthesis, resulting in sparing of the mucosa beneath the appliance and hyperkeratosis of exposed areas. The combination of tobacco carcinogens and heat is markedly intensified in reverse smoking (lit end positioned inside the mouth), adding significant risk for malignant conversion.



Clinical Features

The palatal mucosa initially responds with an erythematous change followed by keratinization. Subsequent to opacification or keratinization of the palate, red dots surrounded by white keratotic rings appear. The dots represent inflammation surrounding the minor salivary gland excretory ducts.

Treatment and Prognosis

This condition rarely evolves into malignancy, except in individuals who reverse smoke. Although the risk of carcinoma

development in the palate is minimal, nicotine stomatitis is a marker or indicator of intense tobacco use and hence may indicate increased risk of epithelial dysplasia and neoplasia elsewhere in the oral cavity, oropharynx, and respiratory tract. Therefore, nicotine stomatitis should be viewed as a potential indicator of significant epithelial change at sites other than the hard palate.

Leukoplakia

(leuko-white; plakia-patch) ♦ Oral leukoplakia is defined by the WHO as "**a white patch or plaque that cannot be scrapped off or characterized clinically or pathologically as any other disease**". Leukoplakia is different from other causes of white patches such as thrush or lichen planus because it can eventually develop **into oral cancer**. Within 15 years, about 3% to 17% of people with leukoplakia will develop **squamous cell carcinoma**, a common type of skin cancer.

The likelihood of developing cancer from leukoplakia depends on the size, shape, and appearance of abnormal cells.

Etiology

1. Chemical: alcohol, tobacco
2. mechanical: sharp tooth or crown margins, irritating denture clasps
3. Premalignant epithelial changes : Candida Albicans ,Ultraviolet radiation ,Trauma Tooth paste or mouth rinses .
4. Acute candidiosis :Thrush , Acute antibiotic stomatitis .
5. Chronic : Denture induced stomatitis , Chronic hyperplasia or mucocutaneous candidiosis , Erythematous candidiosis .
6. Some cases of leukoplakia have no known cause (this is called idiopathic leukoplakia).

7- Nutritional factors have been cited as important, especially relative to iron deficiency anemia and development of **sideropenic dysphagia (Plummer-Vinson or Paterson-Kelly syndromes)**(**A disorder marked by anemia caused by iron deficiency, and a web-like growth of membranes in the throat that makes swallowing difficult**. Most cases occur in men who are between the ages of 40 and 70. Fewer than 1% of cases are in patients under the age of 30.

Clinical Features of Leukoplakia

Affects 1.5 – 12% of total population. It usually affects people over the age of 40 years (average age is 60 years). The Prevalence increases rapidly with age particularly in males, Approximately 8 % of the males

over the age of 70 years are reportedly affected. , **4-5% may develop squamous cell carcinoma**, in smokers it rises to 16% Sites of predilection, the most common sites are ♦ **Lateral and ventral tongue ♦ floor of the mouth ♦ alveolar ridge mucosa ♦ corner of the mouth ♦ less frequently: soft palate and lips.**



The symptoms of leukoplakia are **one or more white patches on the surface of the tongue, underneath the tongue, or insides the cheeks.** The patches cannot be rubbed off and cannot be traced to any other cause. **No pain** or other symptoms are present.

Some research has shown that patches on the floor of the mouth and the underside or sides of the tongue are more likely to be cancerous. However, not all studies agree that location is an important factor. The size of a patch has no link to whether it may become cancerous.

Factors that are strong indicators of **leukoplakia transforming to cancer include the appearance of:**

- Nodules.
- White and red masses.
- Ulceration.
- Increased firmness.
- Bleeding.

Clinical Forms ♦ Homogenous ♦ Non Homogenous (speckled)

1. **Homogenous ♦ Uniform flat appearance** that may exhibit shallow cracks and has a **smooth**, plaque like, wrinkled or corugated surface with a consistent texture throughout.



2. **Non Homogenous** ♦ A predominantly white or white and red lesion **(erythroleukoplakia).** ♦ Area of redness and ulceration ♦ Irregularly flat, **nodular thickening** and exophytic ♦ Nodular lesions have raised, rounded red and or white excrescences.



Leukoplakia: A **Premalignant or Precancerous Lesion** ♦ Although leukoplakia is not associated with a specific histopathologic diagnosis, it is considered to be a premalignant lesion for the risk of malignant transformation is greater in a leukoplakic lesion than that associated with normal or unaltered mucosa. Malignant Transformation Potential ♦ **Homogenous - 0%** ♦ **Non Homogenous - 26%.**

3-Proliferative verrucous leukoplakia (PVL) (also called florid papillomatosis) is a rare but **especially aggressive form of oral leukoplakia.** Studies show it is strongly associated with the **presence of Epstein-Barr virus**, a type of herpes virus. **Nearly all cases will eventually become cancerous at a number of different sites**. PVL is usually diagnosed late in the development of leukoplakia, as it takes time to **spread to multiple sites**. It also has a high rate of recurrence.



4- **Oral hairy leukoplakia,** which also happens as a result of having the **Epstein-Barr virus**, which stays the body throughout life. People with weak immune systems, **like people with HIV/AIDS**, can **develop oral hairy leukoplakia**. This condition looks like its name—**white hairy patches,** often with folds so it looks like hair is growing out of the folds. These spots mostly happen on the **tongue**, but might be found in other parts of the mouth. **Oral hairy leukoplakia doesn't become cancer**, but if you have it, you will probably want to talk to your provider about **checking for HIV/AIDS**.

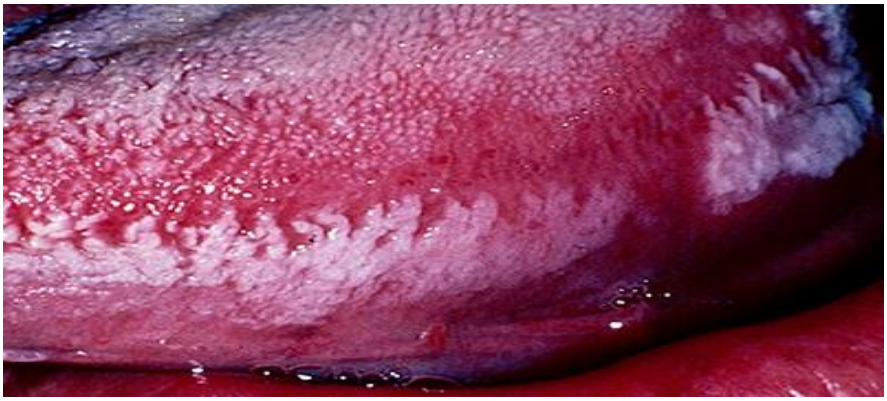

HISTOPATHOLOGY

The characteristic microscopic feature of **hairy leukoplakia** is the presence of : **1- Viral inclusions (presence of EBV within cells).** And also presence of **2- Candida albicans hyphae** are often seen extending into the superficial epithelial cell layers.

Treatment of leukoplakia

The main goal of treating leukoplakia is to prevent it from becoming cancer. However, treatment is a challenge and results are often mixed. Treatment may remove the lesions, but a fair number of them return.

Medical management:

- Stop using tobacco and alcohol.
- Eat a diet rich in fruits and vegetables.
- Retinoids (vitamin A-based treatments used to treat acne and psoriasis) taken by mouth may help reduce lesions
- Isotretinoin supplements have been found to be more effective in preventing cancerous changes.
- For cosmetic reasons, patients may request treatment of their lesions. Responses to acyclovir (Antiviral), ganciclovir, famciclovir, tretinoin, have been reported.
- Approximately 10% of individuals with diagnosed hairy leukoplakia have AIDS at the time of diagnosis, and an additional 20% develop this disease in the following year. The probability that AIDS will develop in untreated HIV-positive individuals with HIV-associated hairy leukoplakia is approximately 50% within 1.5 years; within 2.5 years the probability is 80%.

Surgical management:

- Removing lesions with surgery.
- Removal of lesions by laser.
- Cryotherapy (use of freezing to remove lesions).
- Electrocauterization (use of an electrically heated needle or other instrument to remove lesions).

Linea alba*(white line)*

Linea alba is a **horizontal, asymptomatic white linear lesion seen on the buccal mucosa at the level of the occlusal plane of the teeth**. is a horizontal streak on the buccal mucosa (inner surface of the cheek), level with the occlusion (biting plane). It usually extends from the commissure to the posterior teeth, and can extend to the inner lip mucosa and corners of the mouth.

The linea alba is a common finding and most likely associated with pressure, frictional irritation, or trauma from the facial surfaces of the teeth.

Clinical considerations

The linea alba is usually present bilaterally

- It is restricted to dentulous areas (i.e., in areas where there are missing teeth the line will be absent - unless a denture is worn)

- It presents an asymptomatic, linear elevation, with a whitish colour, at the level of the occlusal line of the teeth
  - Linea alba is caused by **chronic irritation of the teeth against the buccal mucosa along the plane of** occlusion and is considered as a frictional keratosis. Additional causes include orthodontic appliances, frictions of the dentures, uneven teeth, and aggressive oral hygiene

Treatment : Treatment is not required.

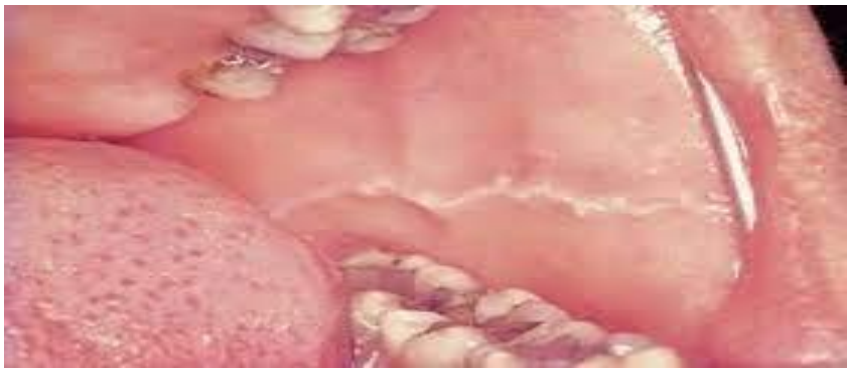

Pre-Neoplastic Lesion

Actinic cheilitis

Also known, **farmer's lip, or sailor's lip**, is a reaction to long-term **sun exposure on the lips**, primarily **the lower lip**. The lip is especially susceptible to **UV radiation** because it has a thinner epithelium and less pigment. Some believe actinic cheilitis represents a type of **premalignant.** Others believe it is a form of in-situ **squamous cell carcinoma**. Actinic, or solar, cheilitis represents accelerated tissue degeneration of the vermilion (dry mucous membrane) of the lips, especially the lower lip, as a result of chronic exposure to sunlight; it is considered to represent a potentially **premalignant condition**. This condition occurs almost exclusively in whites and is especially prevalent in those with fair skin.

Clinical Features

The affected vermilion of the lips takes on an atrophic, pale to silvery gray, glossy appearance often with fissuring and wrinkling at right angles to the cutaneous-vermilion junction. bilateral swelling of the

lower lip is common. as well as superficial scaling, cracking, erosion, ulceration, and crusting.



Treatment

Because of the positive relationship between exposure to UV light and carcinoma, lip protection is indicated. The use of lip balm containing a sunscreen agent such as para-aminobenzoic acid (PABA) or its derivatives is indicated during periods of sun exposure in high-risk patients.

Actinic Keratoses (Solar Keratoses)

Actinic keratoses of the skin, **the cutaneous counterpart of actinic cheilitis**, are epithelial changes noted typically in light-complexioned individuals who have had long-term exposure to sunlight. A small percentage of these lesions develop into squamous cell carcinoma.

Clinical features

Oval plaques, usually smaller than 1 cm in diameter, are typically found on the forehead, cheeks, temples, ears, and lateral portions of the neck. The color may vary from yellow-brown to red, and the texture is usually rough and sandpaper-like.

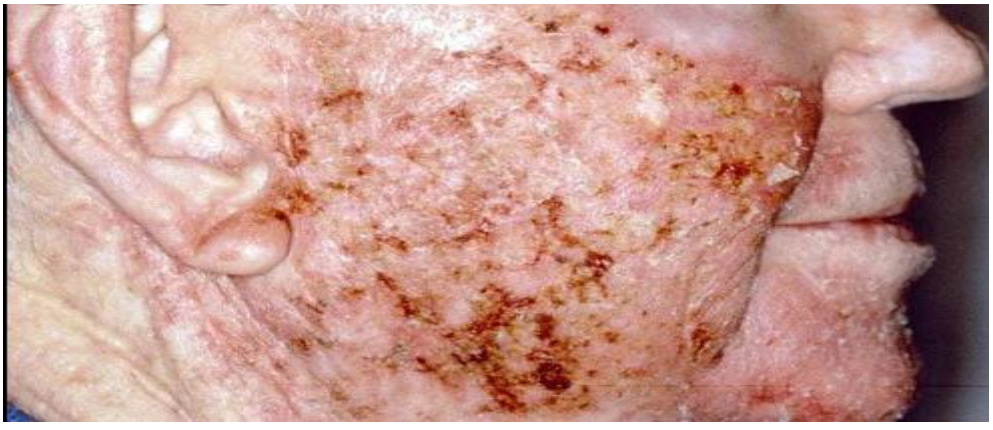

Erythroplakia

Is a clinical term to describe any **erythematous (red)** area on a mucous membrane is defined as a brighter red plaque on the oral mucosa which cannot be categorized clinically or pathologically as being due to any other conditions, erythroplakic lesions may be homogeneous with a well-defined but irregular outline, or may be intermingled with patches of leukoplakia-such lesions are often called **speckled leukoplakia or erythroleukoplakia,** histologically erythroplakia may represent carcinoma in situ or even invasive carcinoma.



Erythroplakia is analogous to the term leukoplakia which describes white patches. Together, these are the 2 traditionally accepted types of premalignant lesion in the mouth, When a lesion contains both red and white areas, the term "speckled leukoplakia" or "eyrthroleukoplakia" is used. Although oral erythroplakia is much less common than leukoplakia, erythroplakia carries a significantly higher risk of containing carcinoma in situ, and of eventually transforming into invasive squamous cell carcinoma.

The most common areas in the mouth where erythroplakia is found are the floor of the mouth, buccal vestibule, the tongue, and the soft palate. It appears as a red macule or plaque with well-demarcated borders.

Causes

Erythroplakia has an unknown cause but researchers presume it to be similar to the causes of squamous cell carcinoma. Carcinoma is found in almost 40% of erythroplakia. It is mostly found in elderly men around the ages of 65 - 74. It is commonly associated with smoking,Alcohol and tobacco use have been described as risk factors.