Salivary Gland Diseases and Tumors

The **salivaryglands** in mammals are exocrineglands that produce saliva through a system of ducts. Humans have three paired major salivary glands (parotid(stensens duct), submandibular(whartons duct), and sublingual (bartholins duct)), as well as hundreds of minor salivary glands. The functional unit of salivary glands is the secretory acinus and related ducts and myoepithelial cells. Acini may be serous, mucous, or mixed. In humans, between 0.5 and 1.5 litres of saliva are produced every day. Normal function & health of the mouth depend on normal secretion of the saliva by the major & minor salivary glands.Failure of salivary secretion causes a dry mouth which promotes oral infections. Both the major & minor glands are composed of parenchymal elements which are supported by C.T. The parenchyma derived from the oral epithelium consists of terminal secretary units leading into ducts that open into the oral cavity. The C.T. forms a capsule around the gland & extends into it. The blood & lymph vessels & nerves that supply the gland are contained within the C.T.

The most important function of S.G. is the production of saliva which contains various organic & inorganic substances & help in the mastication, deglutition & digestion of food.

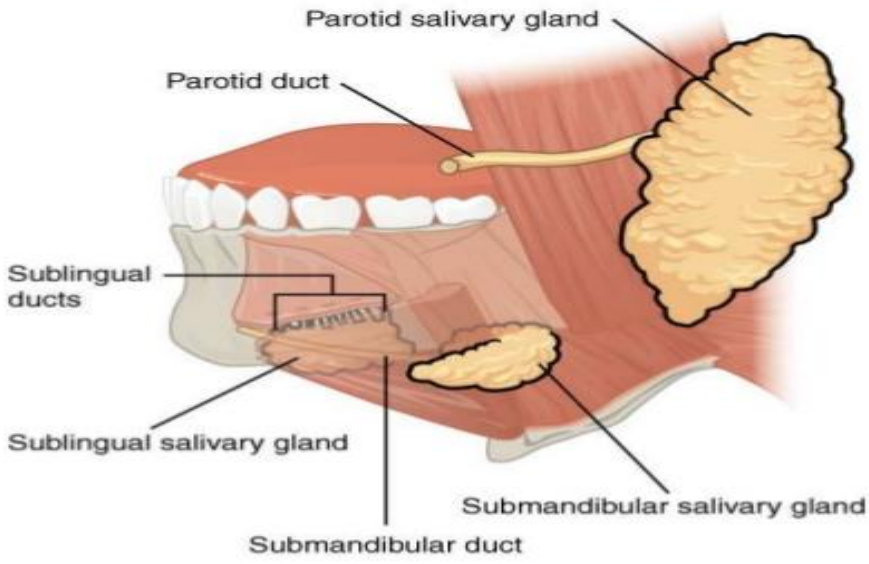

Salivary gland infection (Sialadenitis)

Sialadenitis : is inflammation of salivary glands, usually the major ones, the most common being the parotid gland, followed by submandibular and sublingual glands. It should not be confused with **sialadenosis (sialosis)** which is a non-inflammatory enlargement of the major salivary glands (such as in diabetes mellitus, alcoholism, endocrine disorders, pregnancy, drugs, eating disorders, idiopathic, ect.)

Causes of sialadenitis are varied, including **bacterial** (most commonly ***Staphylococcus aureus***), **fungal and viral.** The most common viral infection is mumps, although a number of other viruses also can involve the salivary glands, including Coxsackie A, ECHO, choriomeningitis, parainfluenza, and cytomegalovirus (CMV) (in neonates).

Sialadenitis can be further classed as acute or chronic. **Acute sialadenitis** is an **acute** inflammation of a salivary gland which may present itself as a **red, painful swelling that is tender to touch. Chronic sialadenitis** is typically **less painful** but presents as recurrent swellings, usually after meals, without redness.

Clinical Features

Acute bacterial sialadenitis is most common in the parotid gland and is bilateral in 10% to 25% of cases. The affected gland is **swollen and painful**, and the overlying skin may be warm and erythematous. An associated low-grade fever and trismus may be present. A purulent discharge often is observed from the duct orifice when the gland is massaged the main organisms involved being *Streptococcus pyogenes and staphylococcus aureus*, less commonly *Haemophilus species*. Recurrent or persistent ductal obstruction (most commonly caused by sialoliths) can lead to a chronic sialadenitis. Periodic swelling and pain occur within the affected gland, usually developing at mealtime when salivary flow is stimulated. Sialography often demonstrates sialectasia (ductal dilatation) proximal to the area of obstruction In chronic parotitis, Stensen's duct may show a characteristic sialographic pattern known as "sausaging," which reflects a combination of dilatation .

Acute sailadenitis

- painful swelling
- reddened skin
- edema of the cheek, periorbital region and neck

- low grade fever
- malaise
- raised ESR, CRP (***C-reactive protein***), leucocytosis
- purulent exudate from duct .



Chronic Sialadenitis

Chronic sialadenitis causes intermittent, recurrent periods of tender swellings. Chronic sclerosing sialadenitis is commonly unilateral and can mimic a tumour.

Clinical Feature

- unilateral
- mild pain / swelling
- common after meals
- duct orifice is reddened and flow decreases
- may or may not have visible/palpable stone.

HISTOPATHOLOGIC FEATURES

In patients with acute sialadenitis, accumulation of ***neutrophils*** is observed within the ductal system and acini. Chronic sialadenitis is characterized by scattered or patchy infiltration of the salivary parenchyma ***by lymphocytes and plasma cells***. Atrophy of the acini is common, as is ductal dilatation. If associated fibrosis is present, then the term ***chronic sclerosing sialadenitis*** is used.

TREATMENT AND PROGNOSIS

The treatment of acute sialadenitis includes appropriate **antibiotic** therapy **and rehydration** of the patient to stimulate salivary flow. Surgical drainage

may be needed if there is abscess formation. Although this regimen is usually sufficient, a 20% to 50% mortality rate has been reported in debilitated patients because of the spread of the infection and sepsis. The management of chronic sialadenitis depends on the severity of the condition and ranges from conservative therapy to surgical intervention.

Salivary calculi (sialoliths)

Sialoliths are calcified structures that develop within the salivary ductal system. A stone can form from salts contained in the saliva. Stones are particularly likely to form when people are dehydrated or take drugs that decrease saliva. Production.About 25% of people with stones have more than one Salivary stones create problems when they block the tube (duct) that carries saliva from the gland to the mouth. Blockage makes saliva back up inside the duct, causing the salivary gland to swell painfully. A blocked duct and gland filled with stagnant saliva may become infected with bacteria.

A typical symptom of a blocked salivary duct is swelling and pain over the gland that is affected. The pain and swelling worsen after eating, particularly when people eat something that stimulates saliva flow (such as a pickle or lemon juice) because when the duct is blocked, the saliva has no place to go and the gland swells. The swelling may go down after a few hours, and the duct may release a gush of saliva. Some stones do not cause any symptoms.



Sialoliths most often develop within the **ductal system of the submandibular gland**; the formation of stones within the parotid gland system is distinctly less frequent. The long, tortuous, upward path of the submandibular (Wharton's) duct and the thicker, mucoid secretions of this gland may be responsible for its greater tendency to form salivary calculi. Sialoliths also can form within the minor salivary glands, most often within the glands of the upper lip or buccal mucosa. Salivary stones can occur at almost any age, but they are most common in young and middle-aged adults. Major gland sialoliths most frequently cause

episodic pain or swelling of the affected gland, especially at mealtime. The severity of the symptoms varies, depending on the degree of obstruction and the amount of resultant backpressure produced within the gland.
Sialoliths typically appear as radiopaque masses on radiographic examination.

MUMPS (EPIDEMIC PAROTITIS)

Mumps :

Is a glandular viral disease usually affecting the **parotid gland.** The sub mandibualr & sub lingual gland may also be affected. Mumps is due to paramyxo virus (mumps virus), children are mainly affected, the incubation period of about 21 days, the infection start with high fever followed by a painful swelling behind the ear, the papilla of parotid (stensen's) duct may be swollen & secretion of the parotid are less so the mouth may be dry.

The pain subsides but the swelling persist for 5 days &then decrease. Permanent nerve deafness & meningitis are possible complication. In adult complications of mumps may develop orchitis.

After an attack immunity is long lasting, with wide use of immunization childhood mumps is becoming infrequent & mumps in adult may take a typical form.



TREATMENT AND PROGNOSIS

The treatment of mumps is palliative in nature. Frequently, non aspirin analgesics and antipyretics are administered. In an attempt to minimize orchitis, bed rest is recommended for males until the fever breaks. Avoidance of sour foods and drinks helps to decrease the salivary gland discomfort. As with measles and rubella, the best results come from prior vaccination, thereby preventing the infection.

Sjogren's syndrome

This is a condition characterized by a triad of **keratoconjuctivitis sicca (dry eye), xerostomia (dry mouth) & rheumatoid arthritis.** Sjogren's syndrome is divided into:

1. Primary Sjogren's syndrome: also called sicca syndrome which consist of **xerostomia & xerophthalmia.**

2. secondary sjogren's syndrome: there is an associated rheumatoid arthritis or other connective tissue disease cyst (lupus erythromatosis, scleroderma) The etiology is thought to be auto immune.

Clinical features:

1- Occur predominantly in middle-aged women.

2- Dryness of the mouth & eyes as a result of the hypofunction of the salivary & lacrimal glands.

3-The oral mucosa is obviously dry, red, shiny & wrinkled & sticks to the fingers or mirror during examination.

4-The tongue appears red, atrophy of the papillae & the dorsum becomes lobulated.

5- With diminished saliva secretion the oral flora changes & candidal infection are common.

Histopathology:

A labial biopsy is characterized by **atrophy of the acini & replacement by lymphocytes mainly T-lymphocytes.**

Sjögren Syndrome

- It is the expression of an autoimmune process that principally results in
  - Rheumatoid arthritis
  - Dry eyes (keratoconjunctivitis sicca)
  - Dry mouth (xerostomia)
  - Lymphocytic replacement of lacrimal and salivary glands



Diagnostic aspect

Normal salivary flow is between 1&2 ml/min:

1. Diminished mixed salivary flow rate May be reduced to 0.5 ml/min or less.
2. Labial salivary gland biopsy showing periductal lymphocytic infiltrate.
3- Sialectasis on sialography .

Treatment:

The treatment of patient with Sjogren's syndrome is mostly supportive

1-Periodic use of artificial tears for the dry eye.
2-Artificial saliva for xerostomia & because of increase risk of dental caries.
3- Daily fluoride application may be indicated in dentulous patients; also antifungal therapy is often needed to treat secondary candidiasis.
Malignant lymphoma can develop in Sjogren's syndrome.

Mikulicz syndrome: is a chronic condition characterized by the abnormal enlargement of glands in the head and neck, including those near the ears (parotids) and those around the eyes (lacrimal) and mouth (salivary). The tonsils and other glands in the soft tissue of the face and neck may also be involved. Although the disorder is almost always described as benign, it always occurs in association with another underlying disorder such as tuberculosis, leukemia, syphilis, Hodgkin's disease, lymphosarcoma, Sjögren syndrome, or lupus (SLE). People who have Mikulicz syndrome are at heightened risk for developing lymphomas.
Some people with Mikulicz syndrome may experience recurring fevers. The fever may be accompanied by dry eyes, diminished tear production (lacrimation), and inflammation of various parts of the eyes (uveitis). Lacrimal gland enlargement, parotid gland enlargement, dry mouth and dry eyes are the classic signs.

The exact cause of Mikulicz syndrome is not known. Some scientists believe that Mikulicz syndrome should be considered a form of Sjögren syndrome.



Causes

The exact cause of Mikulicz syndrome is not known, although it is suspected to be an autoimmune disorder. Autoimmune disorders are caused when the body's natural defenses against "foreign" or invading organisms (e.g., antibodies) begin to attack healthy tissue for unknown reasons.

The symptoms of Mikulicz syndrome may occur due to the excessive accumulation of certain white blood cells (lymphocytes) into many glands of the face, mouth, and/or neck.

Signs & Symptoms

Mikulicz syndrome is characterized by the sudden onset of extreme dryness in the mouth (xerostomia) that may lead to difficulty swallowing and tooth decay. Other symptoms include enlarged tear glands (lacrimal glands), leading to absent or decreased tears; enlarged glands in the neck (parotid glands); hard, painless swellings (tumefactions) of the saliva glands (salivary glands) of the mouth and those near the ears (parotid). Glands near the jaw (submaxillary) may also become swollen. Symptoms may persist for long periods of time or come and go with frequent recurrences. The symptoms of Mikulicz syndrome are very similar to those of Sjögren syndrome and some researchers suspect that they may be the same disorder. Mikulicz syndrome affects more females than males and most often presents during the middle adult years.

It often occurs in combination with Sjögren syndrome. Some scientists have speculated that Mikulicz Syndrome and Sjögren Syndrome may actually be the same disorder.

Mucocele

Oral mucocele also called **mucous extravasation cyst** is a salivary gland cyst, which contains mucous content. It usually arises from the **minor salivary glands**. The cyst forms due to the retention of mucus within the gland, because of the rupture of the gland or obstruction of the cyst. It is most usually found on the lower lip, but also occurs frequently on the buccal mucosa (over the cheeks) or the floor of the mouth, where it is called a ranula. Ranulas occur mostly in young adults and even more commonly in late childhood. Mucous extravasation phenomenon is a swelling of connective tissue consisting of a collection of fluid called mucus. This occurs because of a ruptured salivary gland duct usually caused by local trauma (damage) in the case of mucous extravasation phenomenon. The mucocele has a bluish translucent color, and is more commonly found in children and young adults.

Although these lesions are often called cysts, **mucoceles are not true cysts** because there is no epithelial lining.Rather, they are polyps.



The size of oral mucoceles vary from 1 mm to several centimeters and they usually are slightly transparent with a blue tinge. On palpation, mucoceles may appear fluctuant but can also be firm. Their duration lasts from days to years, and may have recurrent swelling with occasional rupturing of its contents.

Types
There are several variants:

- Mucus extravasation cyst: this is the most common type of mucocele and is caused by salivary gland secretion spilling out of the gland into the surrounding tissue, forming a swelling which has no epithelial capsule but is surrounded by granulation tissue
- Mucus retention cyst is due to the duct of the gland becoming blocked, and therefore has an epithelial lining. These are found in older people, between 50 and 60 years.

Clinical features

- A mucocele appears as a distinct painless swelling of the mucosa, which has a fluctuant feel indicating fluid contents. It is usually less than a centimeter across, though cases in which it was several centimeters in diameter have been reported.
- They appear bluish and have a translucent appearance, especially when superficial. Deep mucoceles resemble mucosal bumps and sometimes are bright red because of bleeding into the cyst. Sometimes the occurrence is preceded by recent or past trauma, or even simple biting.



Treatment

Surgical removal is done by excising the whole accessory salivary glands. However, large cysts are best marsupialized, or unroofed, and left open to the oral cavity, to prevent the risk of nerve injury by deep dissection or creating a deep crater. Complete excision involves removal of the accessory gland ducts and glands which could otherwise cause recurrence. In addition to surgery, laser, cryosurgery, and electrocauterization have been explored to remove mucoceles.

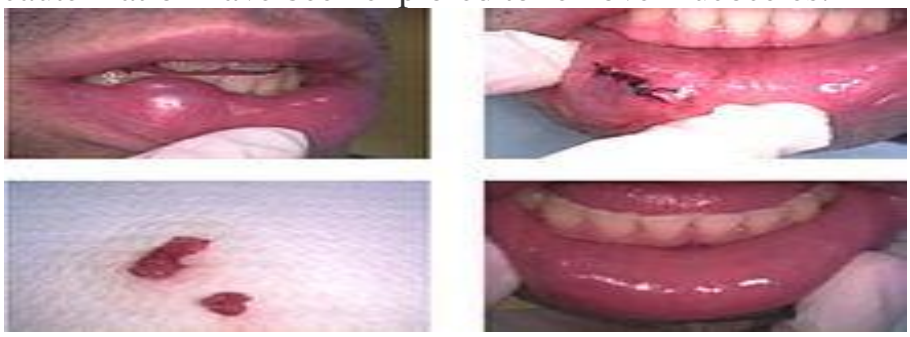

Ranula

A **ranula** is a mucus extravasation cyst involving a **sublingual gland** and is a type of mucocele found on the floor of the mouth. Ranulae present as a swelling of connective tissue consisting of collected mucin from a ruptured salivary gland caused by local trauma. If small and asymptomatic further treatment may not be needed, otherwise minor oral surgery may be indicated. The Latin word *rana* means "frog" (ranula = "little frog").



Signs and Symptoms

A ranula usually presents as a translucent, blue, dome-shaped, fluctuant swelling in the tissues of the floor of the mouth. If the lesion is deeper, then there is a greater thickness of tissue separating from the oral cavity and the blue translucent appearance may not be a feature. A ranula can develop into a large lesion many centimeters in diameter, with resultant elevation of the tongue and possibly interfering with swallowing (dysphagia). The usual location is lateral to the midline**,** ranulae may rupture and then cause recurrent swelling. Ranulae may be asymptomatic, although they can fluctuate rapidly in size, shrinking and swelling, making them difficult to detect. Minor trauma to the floor of the mouth is thought to damage the delicate ducts that drain saliva from the sublingual gland into the oral cavity. **The lesion is a mucous extravasation cyst (mucocele) of the floor of mouth.**

Treatment

Treatment of ranulae usually involves removal of the sublingual gland. Surgery may not be required if the ranula is small and asymptomatic. Marsupialization may sometimes be used, where the intra-oral lesion is opened to the oral cavity with the aim of allowing the sublingual gland to re-establish connection with the oral cavity.