Salivary Gland Tumors

Salivary gland tumors are abnormal cells growing in the salivary gland or in the tubes (ducts) that drain the glands.

Salivary gland tumors can be noncancerous (benign) or cancerous (malignant). Although most salivary gland tumors are benign, some are malignant. It's also possible for benign tumors to become malignant over time if left untreated.

Malignant salivary gland tumors are relatively rare, making up only 6 percent of head and neck cancers. The most common type of salivary gland tumor (~80% of all salivary gland tumors) is a slow-growing benign tumor in the parotid gland. Minor salivary gland tumors are rare.

Benign salivary gland tumor

Pleomorphic adenoma (benign mixed tumor)

Pleomorphic adenoma (PA), also known as benign mixed tumor, is the most common salivary tumor, constituting up to two-thirds of all salivary gland neoplasms . Mostly, PA is located in the **parotid glands (85%)**, minor salivary glands (10%), and the submandibular glands (5%) .In the majority of cases, tumors originate in the superficial lobe. However, occasional cases may involve the deep lobe of the parotid gland and the parapharyngeal space. Minor salivary gland tumors are frequently encountered on the palate, followed by the lip, cheek, tongue and floor of the mouth**,** It is the most common type of salivary gland tumor and the most common tumor of the parotid gland. It derives its name from the architectural Pleomorphism (variable appearance) seen by light microscopy.

Clinically:

The most common site is the parotid gland, typically present as a painless size slowly reaching to several cm, there is no fixation to the deeper tissue or to the overlying skin, the skin rarely ulcerated.

Pleomorphic adenoma is also the most common intraoral salivary gland tumor, its usual location is the palate, when it presents as a smooth surface swelling resemble a fibroma, the upper lip is the next common site.

The lesion can occur at any age but is most common in young adults between the age of 30&50 years. There is a slight female predilection.



Histopathological features:

A pleomorphic adenoma is a circumscribed encapsulated tumor characterized by its pleomorphic or mixed appearance. The capsule may be incomplete or show infiltration by tumor cells.

The lesion shows a great variation in appearance, some area show:

1. Cuboidal cells arranged in tubes or duct like structure which may contain an easinophilic coagulum.
2. The tumor epithelial cells may be arranged in sheets or strands about these tubular structures. Some time the cells may assume a stellate, polyhydrate or spindle form.
3. Squamous epithelial cells are relatively common & there may be keratin pearls form.
4. Loose myxoid material can be seen.
5. The hyaline, mucoid, cartilage or even bone is a common finding.

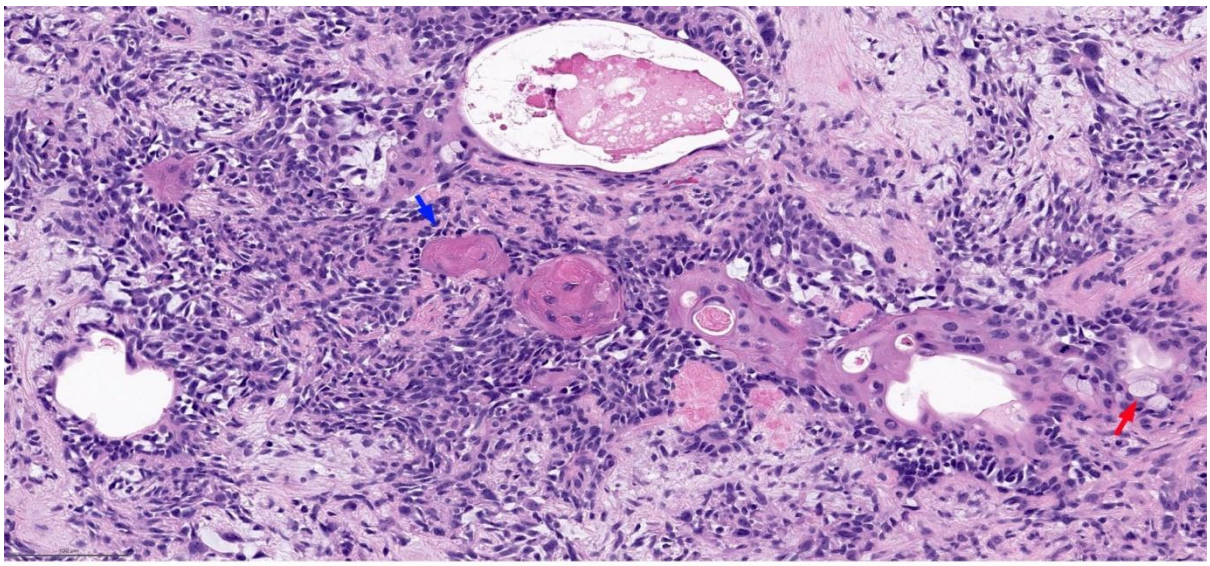

Pleomorphic adenoma can show squamous metaplasia with keratinization (blue arrow) and mucinous metaplasia with mucocytes (red arrow)

Treatment:

Is by wide excision, in the parotid gland, the tumor & the involved lobe should be removed, recurrent rate in this position is high because of difficult surgical complete removal of tumors from the parotid, where the facial nerve is present. The recurrence rate is low in skilled hands.

Lesion of the minor salivary gland of the palate should be excised with the overlying mucosa, while those in the lip, soft palate & buccal mucosa treated successfully by encapsulation.

The tumors are radio resistant. Recurrence may occur due to incomplete resection or incomplete encapsulation.

Benign pleomorphic adenoma may undergo malignant changes either to a carcinoma, adenocarcinoma or cylindroma.

Warthins tumor: (Adenolymphoma, papillary cystadenoma lymphomatosum).

Is a benign neoplasm of the parotid gland. It accounts 9% of all parotid tumors. The pathogenesis of these tumors is uncertain, it is thought that they arise from heterotopic salivary gland tissue found within parotid lymph nodes.

It has also been suggested that these tumors may develop from a proliferation of SG ductal epithelium that is associated with secondary formation of lymphoid tissue, besides these several studies demonstrated a strong association between the development of this tumor and smoking.

Clinically:

This tumor present as slowly growing, painless, nodular mass of the parotid gland. It is most frequently occur in the tail of parotid near the angle of the mandible.

This tumor has a tendency to occur bilaterally but most of these bilateral tumors do not occur simultaneously but are occurring at different times, most common in man usually middle aged.



Histopathological features:

The tumor is composed of a mixture of **ductal epithelium & lymphoid stroma.** The epithelium is oncocytic in nature, forming uniform rows of cells surrounding cystic spaces. The cells have abundant, finely granules, eosinophilic cytoplasm & are arranged in two layers.

The inner terminal layer consists of tall columnar cells with centrally placed pyknotic nuclei. Beneath this, is a second layer of cuboidal or polygonal cells with more vesicular nuclei. The lining epithelium demonstrates multiple papillary projections into the cystic spaces. The epithelium is supported by a lymphoid stroma.

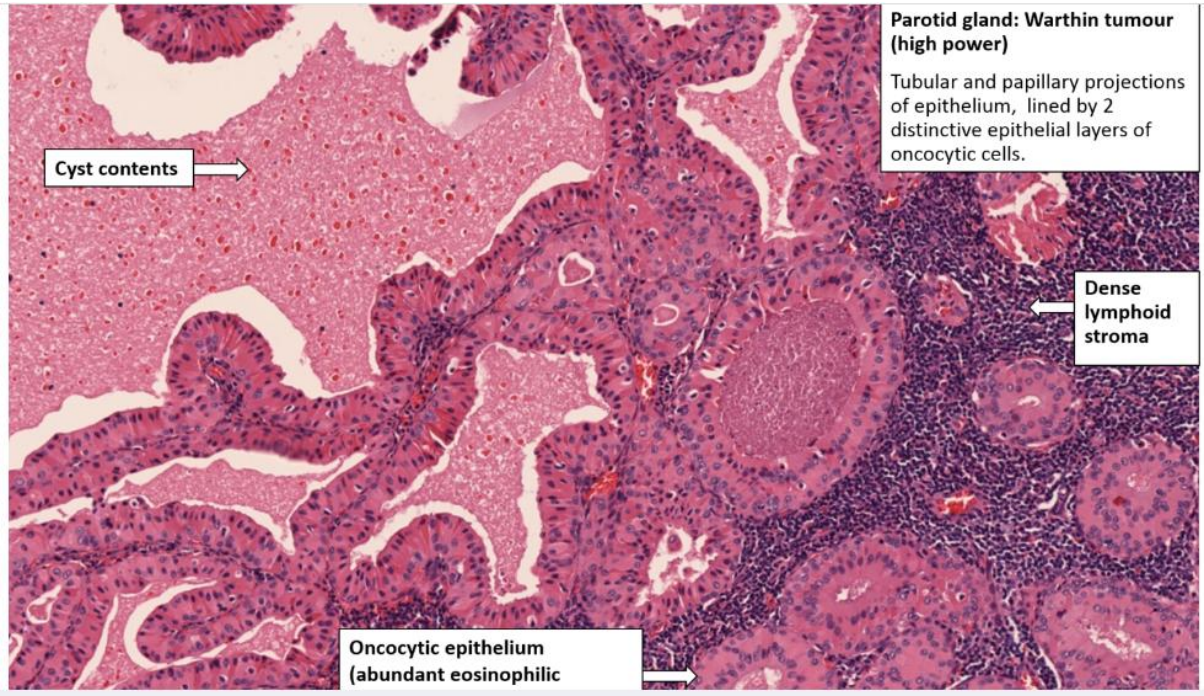

Treatment:

Surgical removal, these tumors are well encapsulated & **seldom reoccur after removal.**

Malignant tumors of salivary gland

Malignant tumors of salivary gland are relatively uncommon, accounting for about 1 per cent or less of all malignancies and about 5 percent of malignant tumors in the head and neck region.

Malignant tumors of salivary gland arise most frequently in major glands especially parotid.

Mucoepidermoid carcinoma

The **mucoepidermoid carcinoma** is one of the most common salivary gland malignancies. Because of its highly variable biologic potential, it was originally called **mucoepidermoid tumor.** The term recognized one

subset that acted in a malignant fashion and a second group that appeared to behave in a benign fashion with favorable prognosis. However, researchers later recognized that even low-grade tumors occasionally could exhibit malignant behavior; therefore, the term *mucoepidermoid carcinoma* is the preferred designation.

Clinical features

The tumor occurs fairly evenly over a wide age range, extending from the second to seventh decades of life. Rarely is it seen in the first decade of life, The mucoepidermoid carcinoma is most common in the parotid gland and usually appears as an asymptomatic swelling. Most patients are aware of the lesion for 1 year or less, although some report a mass of many years' duration. Pain or facial nerve palsy may develop, usually in association with high-grade tumors

Minor gland tumors

also typically appear as asymptomatic swellings, which are sometimes fluctuant and have a blue or red color that can be mistaken clinically for a mucocele. Although the lower lip, floor of mouth, tongue, and retromolar pad areas are uncommon locations for salivary gland neoplasia.

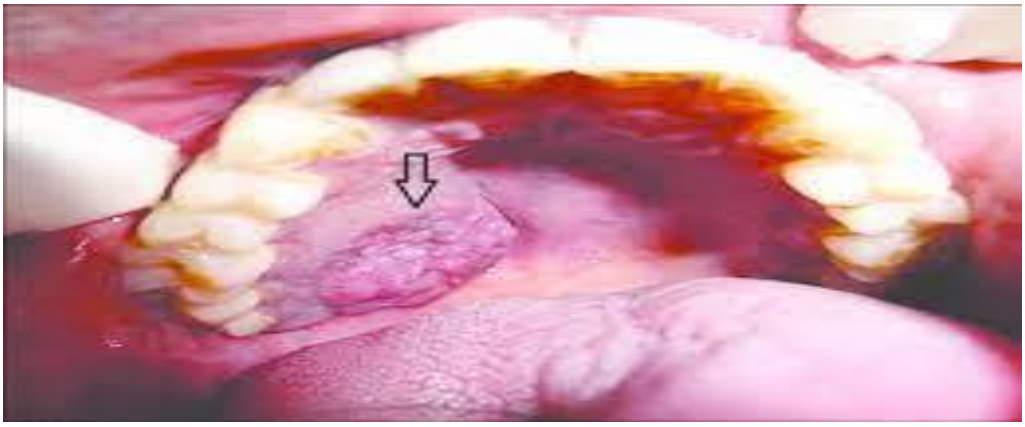

Histopathological features :

From its name the mucoepidermoid CA is composed of a mixture of mucous –producing cells and epidermoid or squamous cells .

If the mucous – secreating cells are mainly predominant then the tumor tend to be cystic, if mainly epidermoid the tumor is solid and then more aggressive.

There is no well-defined capsule, and is invasive and occasionally metastasise.

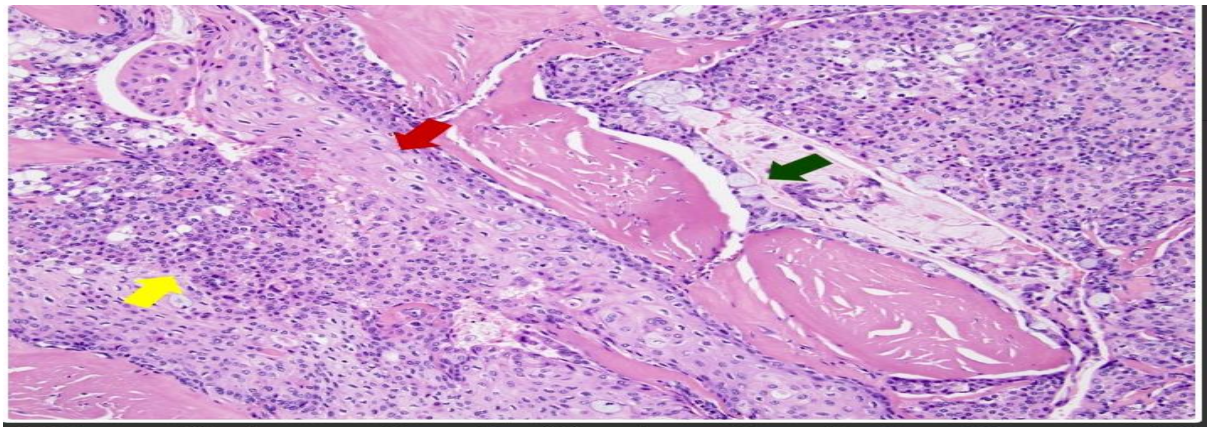

Solid areas of the tumor are formed by different proportions of epidermoid (squamous) cells (red arrow), mucus cells (green arrow) and intermediate cells (yellow arrow) (histopathology, H&E stain, 10x).

Treatment: is by wide excision but the tumor may recur.

ADENOID CYSTIC CARCINOMA

usually grows slowly but usually shows distinct infiltrative spread. The tumor cells are of two types, duct lining cells and cells of myoepithelial type. It occurs most frequently in the minor salivary gland of the palate, the parotid, submandibular and accessory gland in the tongue is also involved.

The lesion is most common in middle –aged adult equal sex distribution. It present as slowly growing mass, there is early local pain, facial paralysis may develop with parotid tumors; palataltumors can be smooth-surfaced or ulceration and may show radiographic evidence of bone destruction.

Histopathology:

1. Composed of small, deeply staining uniform cells resemble basal cells, which are commonly arranged in anastamosing cords or duct like pattern with mucoid material in the center. This produce a **typical cribriform pattern (honey comb or Swiss cheese appearance).**

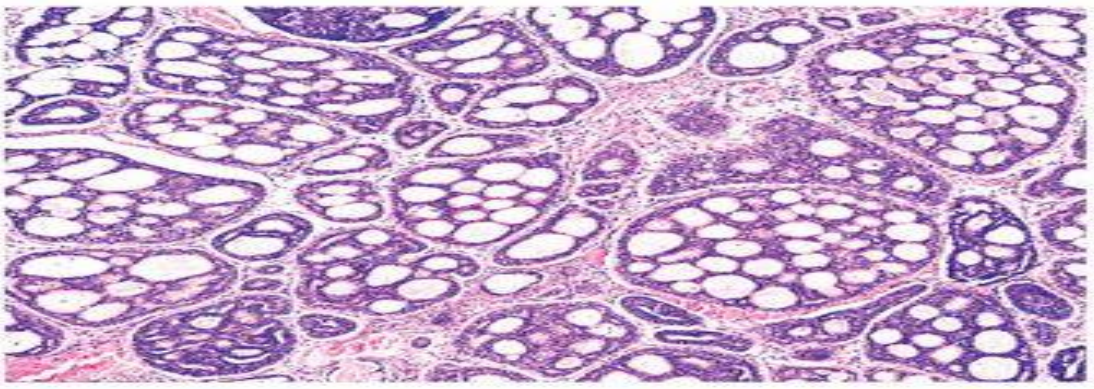

FIGURE 20.38 The classic cribriform pattern of adenoid cystic carcinoma.

2- In the tubular pattern, the tumor cells are similar but occur as multiple small ducts or tubules within a hyalinized stroma.

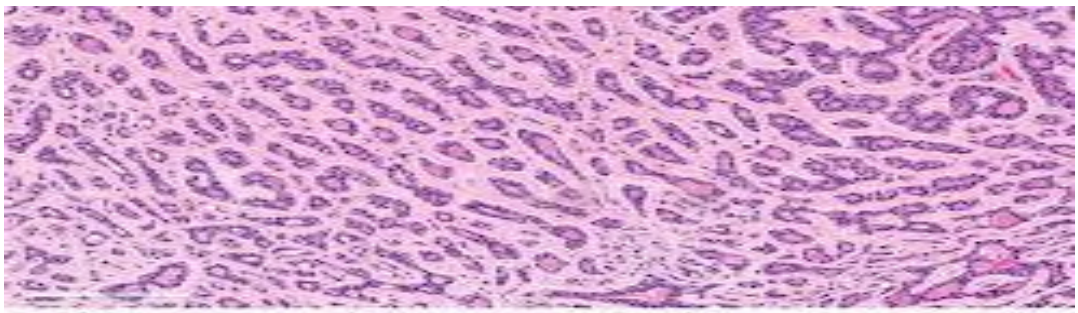

Tubular pattern is composed of inner ductal and outer myoepithelial cells. The ductal cells are cuboidal with eosinophilic cytoplasm. The myoepithelial cells are angulated and basaloid.

3-The solid form consist of larger islands or sheets of tumor cells which show little tendency toward duct or cyst formation.

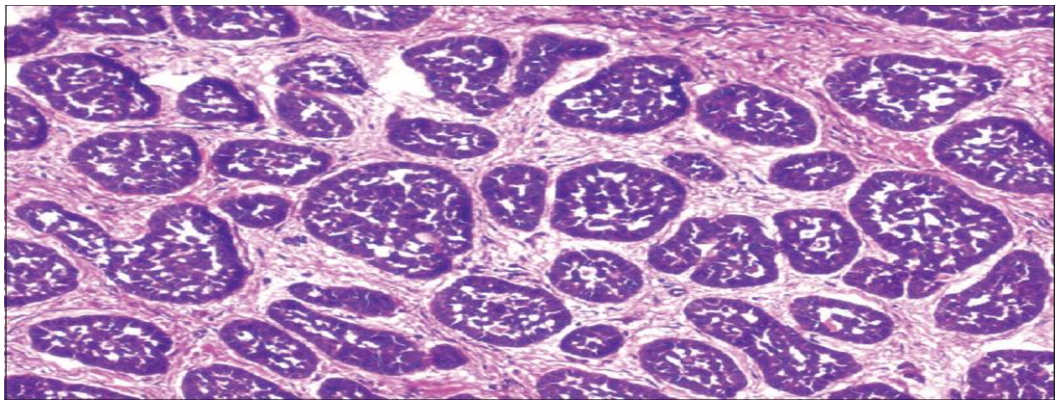

Treatment:

Surgical removal with radiation. Metastasis occurs late in the course of the disease.