Squamous cell carcinoma (SCC)

Epidemiology Squamous cell carcinoma accounts for 90 percent or more of all oral malignant neoplasms. The incidence of oral cancer varies enormously around the world, In both the United Kingdom and the USA oral cancer accounts for less than 4 percent of all cancers, but in India and South east Asia it accounts for up to 40 per cent of all malignant tumors. It is a malignant neoplasm of stratified squamous epithelium that is capable of locally destructive growth and distant metastasis. OSCC is often begin as epithelial dysplasia and progressing until the dysplastic epithelial cells reach the basement membrane and invade into the underlying connective tissue.

OSCC most commonly occurs in middle aged and older individuals, although a disturbing number of these malignancies also being documented in younger adults

From an epidemiological and clinicopathological perspective, OSCC can be divided into three categories:

- Carcinoma of the oral cavity
- Carcinoma of the lip vermilion
- Carcinoma arising in the oropharynx

Intraoral and oropharyngeal tumors are more common among men than women, with a male: female ratio of over 2:1.

Aetiological factors in oral cancer

Tobacco smoking: Much indirect clinical evidence implicates the habit of

tobacco smoking in the development of oral squamous cell carcinoma. The proportion of smokers (80%) among patients with oral carcinoma is two to three times greater than the general population.

Pipes Smokeless (spit) tobacco. Smokeless or "spit" tobacco use in Western cultures may increase a chronic user's risk for oral carcinoma .

Reverse smoking

In reverse smoking, the burning end of a handmade cigar or cigarette is held inside the mouth . This habit considerably elevates one's risk for oral cancer.

Where reverse smoking is practiced as many as 50% of all oral malignancies are found on the hard palate, a site usually spared by this disease.

Smokeless tobacco

Snuff dipping, tobacco sachets and tobacco chewing, betel chewing, betel quid, areca nut:

The betel or paan quid is a compound of natural substances (i.e., areca palm nuts, betel leaf. slaked lime. perhaps tobacco leaf) chewed for their

Psycho stimulating effects , This habit is also associated with significant development of precancers, such as leukoplakia ,Alcohol,_Spirits, Wines and beers and tobacco synergism

This habit does However appear to be a significant potentiator or promoter for other causative factors especially tobacco and its effects are significant when it is understood that most heavy drinkers are also heavy smokers.

Diet and nutrition iron deficiency and vitamins A and C

deficiency Dental factors

Poor oral hygiene, faulty restoration, sharp edges of teeth, and ill-fitting dentures have been incriminated in the aetiology of oral cancer

Ultraviolet light and Radiation

The effects of ultra violet radiation on the lips, x-irradiation, decrease immune reactivity and produces abnormalities in chromosomal material. It should not seem surprising that radiotherapy to the head and neck area increases the risk of the later development of a new primary oral malignancy either a carcinoma or a sarcoma.

Viruses

Herpes simplex viruses

Human papilloma viruses

Epstein-Barr virus

Clinical presentation

In the oral cavity, the majority of cancers are concentrated in the lower part of the mouth, **particularly lateral border of the tongue, the adjacent floor of the mouth and the lingual aspect of the alveolar margins**, forming a U-shaped area extending back towards the oropharynx. Two major factors help to explain why this region is at such a high risk:

First- any carcinogen may mix with saliva, pool in the floor of the mouth, and constantly bathe these anatomic sites

Second-these regions of the mouth are covered by a thin non keratinized mucosa which provides less protection from carcinogens

Less frequently, the gingival and alveolar ridge is the site of origin, the buccal mucosa especially above the occlusal line is seldom involved. Compare with other intra oral sites, carcinoma arising on the hard palate and dorsum of the tongue are relatively rare

Early lesions are usually asymptomatic. Common modes of presentation are a white patch, a small exophytic growth which in the early stages may show no ulceration or erythema, a small indolent ulcer, or an area of erythroplakia pain is seldom present.

Clinical features which should arouse suspicion of an early carcinoma are persistent ulceration, induration, and fixation of affected tissue to underlying structures induration is rubbery hardness caused by invasion of the carcinoma resulting in loss of the normal elasticity and compliance of the oral mucosa.

Fixation is caused by the carcinoma infiltrating through and binding together (tethering) different natural tissue planes.

Underlying bone destruction may also be detected in the case of carcinomas arising from the alveolar mucosa.

Lymph node involvement may occur early in oral carcinomas, but enlarged regional nodes do not necessarily indicate metastatic spread as they may show only non-specific changes of reactive hyperplasia.



Carcinoma developing on the vermilion border of the lip is clearly visible and so may be noticed at an early stage as a slightly raised swelling or a crusty, inconspicuous lesion resembling delayed healing of herpes labialis

An advanced lesion may present as a broad-based, exophytic mass with a rough, nodular, warty, hemorrhagic, or necrotic surface or as a deeply destructive and crater like ulcer with raised, rolled everted edges. Infiltration of the oral musculature may result in functional disturbances particularly if the tumor involves the tongue or floor of mouth. Because of reduced mobility of the tongue patients may complain of impaired speech or of difficulty in swallowing. Pain may be a feature of an advanced lesion. Bone invasion may be detected on radiographs and may be suggested clinically by mobility of teeth, and in the mandible, by altered sensation over the distribution of the mental nerve, or pathological fracture. It is important to note that the size of the surface lesion does not indicate the extent of underlying invasion.

Histopathology

It is customary to grade squamous cell carcinoma into well differentiated, moderately differentiated, and poorly differentiated types.

In *well-differentiated tumors*, the neoplastic epithelium is obviously squamous in type and consists of **masses of prickle cells** with a limiting layer of basal cells around, the periphery. Intercellular bridges are readily recognizable ***Keratin pearls*** are often found within the masses of infiltrating cells, each pearl consisting of a **central area of keratin** surrounded by **whorls of prickle cells**. Nuclear and cellular pleomorphism is not prominent and there are **relatively few mitotic.**

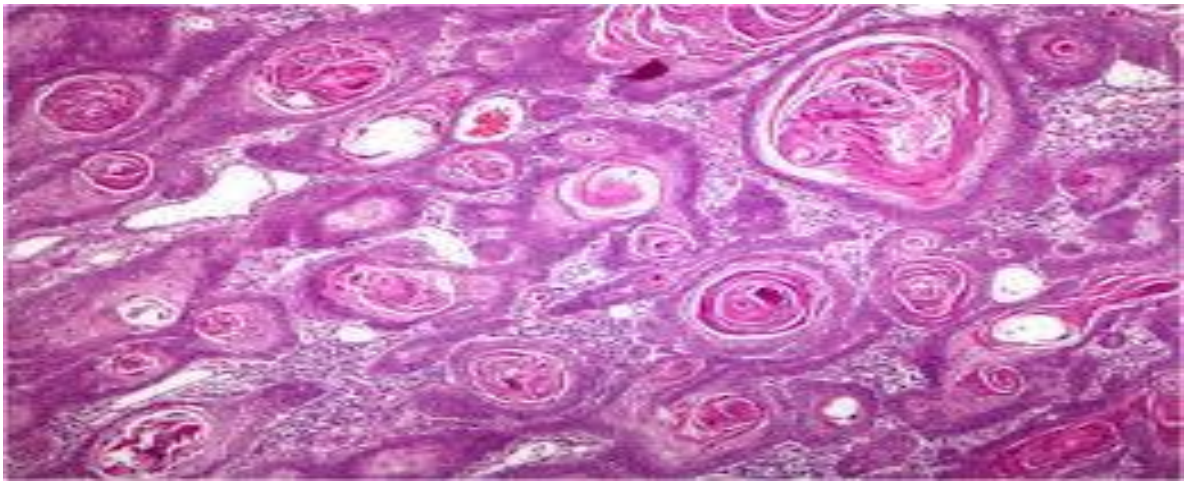

***Moderately differentiated* tumors show less keratinization and more nuclear and cellular pleomorphism and mitotic activity**, but are still readily identified as squamous in type.

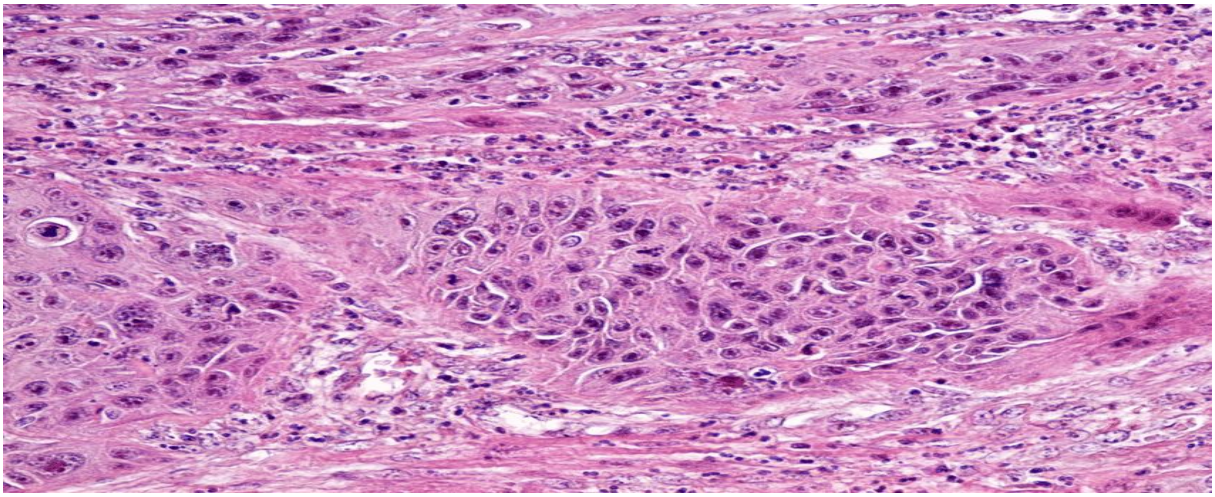

In contrast, in ***poorly differentiated* tumors keratinization is usually *absent* and the cells show prominent nuclear and cellular pleomorphism and abundant, often bizarre, mitoses**.

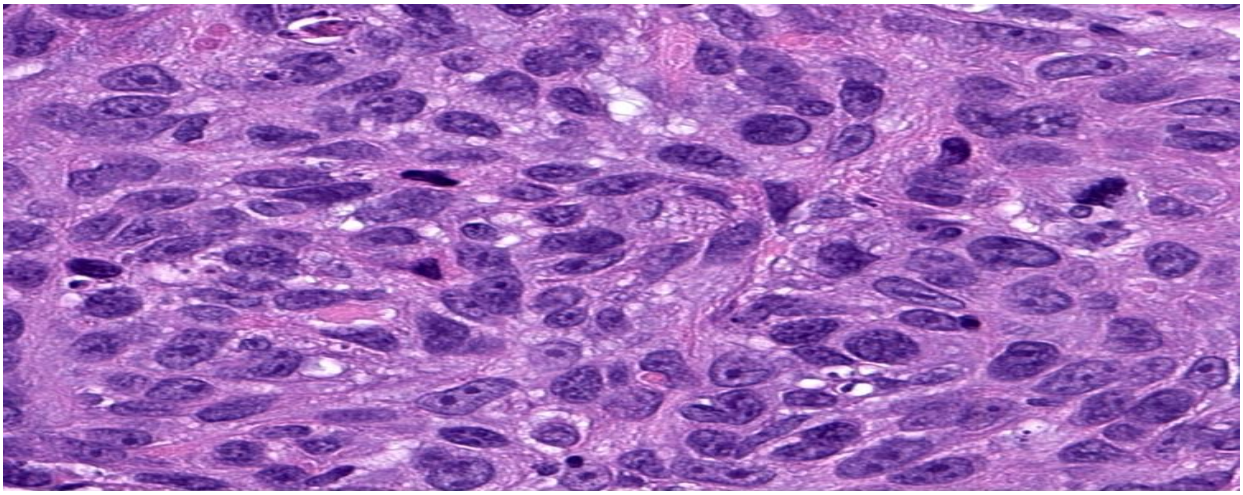

It must be appreciated that the assessment of grade is entirely subjective process and that a degree of overlap between them is inevitable, depending on the area of the tumor sampled and the individual pathologist's criteria for evaluation. Moreover, clinical staging seems to correlate much better with the prognosis than microscopic grading.

In some poorly differentiated tumors the cells may be so abnormal as to hardly be recognizable as epithelial cells.

There is variable ***lymphocytic and plasma cell infiltration*** in the stroma supporting the invasive malignant epithelium, which probably represents a reaction by the host immune system to tumor antigens as well as a response to tumor necrosis and ulceration. The lymphatic spread to the regional lymph nodes is a variable feature, but the frequency of cervical metastasis tend to increase with increasing size of the primary tumor.

As the metastatic carcinoma destroy and replaces the nodal lymphoid tissue it may also invade through the capsule of the node into the surrounding tissue, resulting in fixation of the node on clinical examination, extracapsular spread is an important which a has an adverse effect on prognosis, blood borne metastases occur later in the clinical course of the disease **.**

Verrucous carcinoma

This is an uncommon but distinctive pathological variety of ***low-grade squamous cell carcinoma*** which presents as slow growing, thick, white, warty plaque of heaped-up tissue.

Verrucous carcinoma. Large, exophytic, papillary mass of the maxillary alveolar ridge.



Histologicaliy,

It is a very well differentiated, heavily keratinizing squamous cell carcinoma with little or no cytological atypia. It is predominantly an exophytic tumour but also has a slowly advancing, pushing, cohesive invasive front causing local destruction. It has a good prognosis and is said not no metastasize.

Verrucous carcinoma. Low-power photomicrograph showing marked epithelial hyperplasia with a rough, papillary surface and keratin plugging.

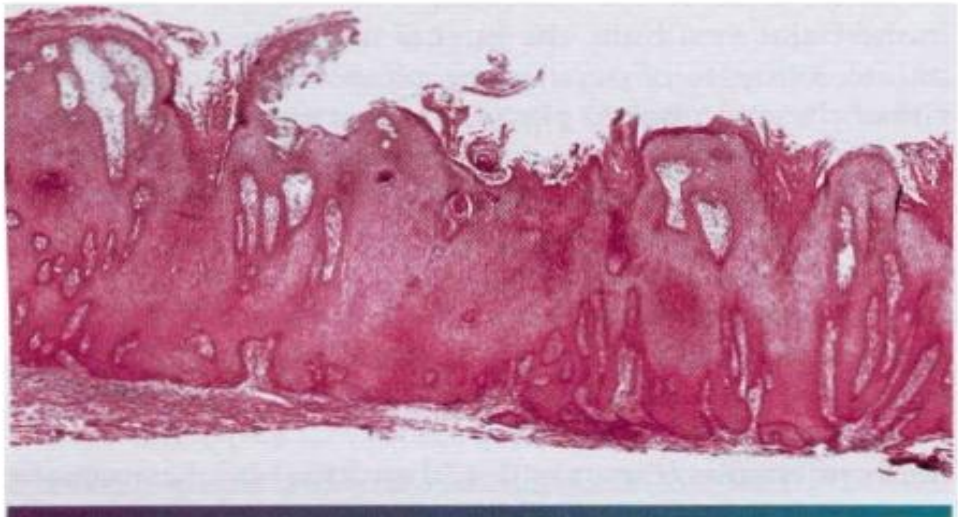

The diagnosis of verrucous carcinoma is difficult and strict criteria must be adopted. The tumor must be differentiated from a well-differentiated papillary squamous cell carcinoma or from leukoplakic lesions with warty surfaces variously called verrucous hyperplasia or verrucous leukoplakia.

Treatment

Because **metastasis is an extremely rare event in verrucous carcinoma**, the treatment of choice is surgical excision without radical neck dissection. The surgery generally need not be as extensive as that required for routine squamous cell carcinoma of a similar size. With this treatment, 90% of patients are disease free after 5 years. Although some patients will require at least one additional surgical procedure during that time.

Basal cell carcinoma (rodent ulcer) This is a common **neoplasm of the skin of the face**, particularly in elderly patients with a history of long exposure to

ultraviolet radiation, occasionally, basal cell carcinoma presents on the **lips**, but many are probably skin tumors that have spread to involve the vermilion. Multiple nevoid basal cell carcinoma arising at a younger age and on non-exposed sites are a characteristic feature of the nevoid basal cell carcinoma syndrome

The typical basal cell carcinoma presents as a slow-growing nodule that eventually ulcerates centrally. Histologically it consist of cytologically malignant basaloid cells, arranged in a variety of patterns, invading adjacent tissue.



