The finishing line of the preparation

Lecture 3

Prepared By :

Dr Maitham Yahya Altufaili

Board Speciality (MSc) In Restorative Dentistry

Dr.maitham_altufaili

@DR.MAITHAM_ALTUFAILI

University of Hilla
Dentistry college

Crown and bridge department

15-11-2025

Third stage

- **The finishing line of the preparation** (or "The preparation margin") is the final margin that separates between the prepared and the unprepared tooth structure.
- This line should be smoothly continuous from one surface to another; otherwise, it will interfere with the seating of the crown.
- The margin between the prepared and unprepared tooth structure is a very critical area as most failures start from this margin.





Types of finishing line according to its design or configuration

1. *Knife edge*
2. *Chamfer*
3. *Heavy chamfer*
4. *Shoulder*
5. *Radial shoulder*
6. *Shoulder with bevel*

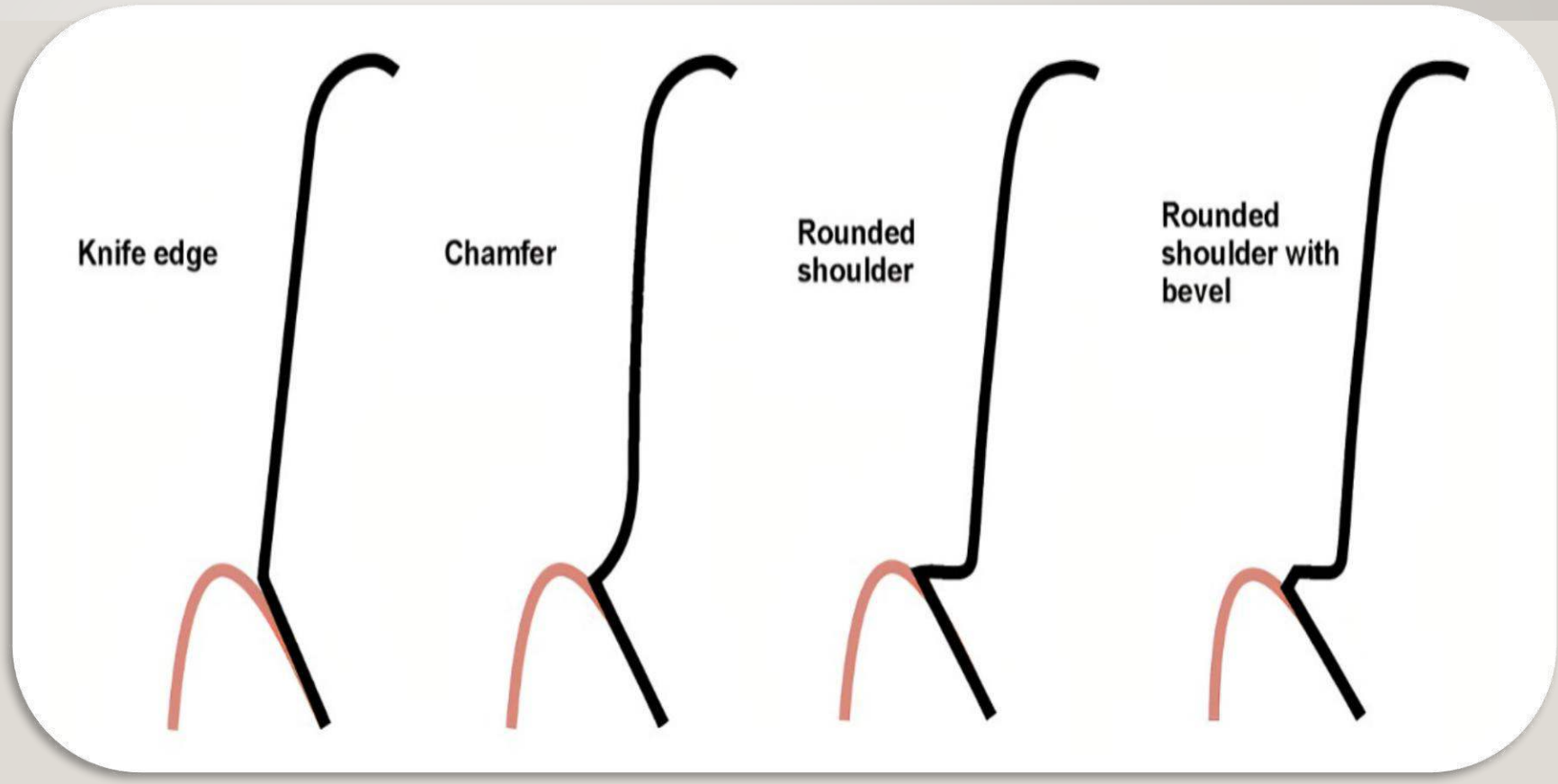

Advantages of knife edge finishing line

1. It is the most conservative type of finishing line.
2. It is easy to prepare.
3. It is a burnishable type of finishing line.

Burnishing is the further adaptation of the **margin** of restoration to the tooth structure.

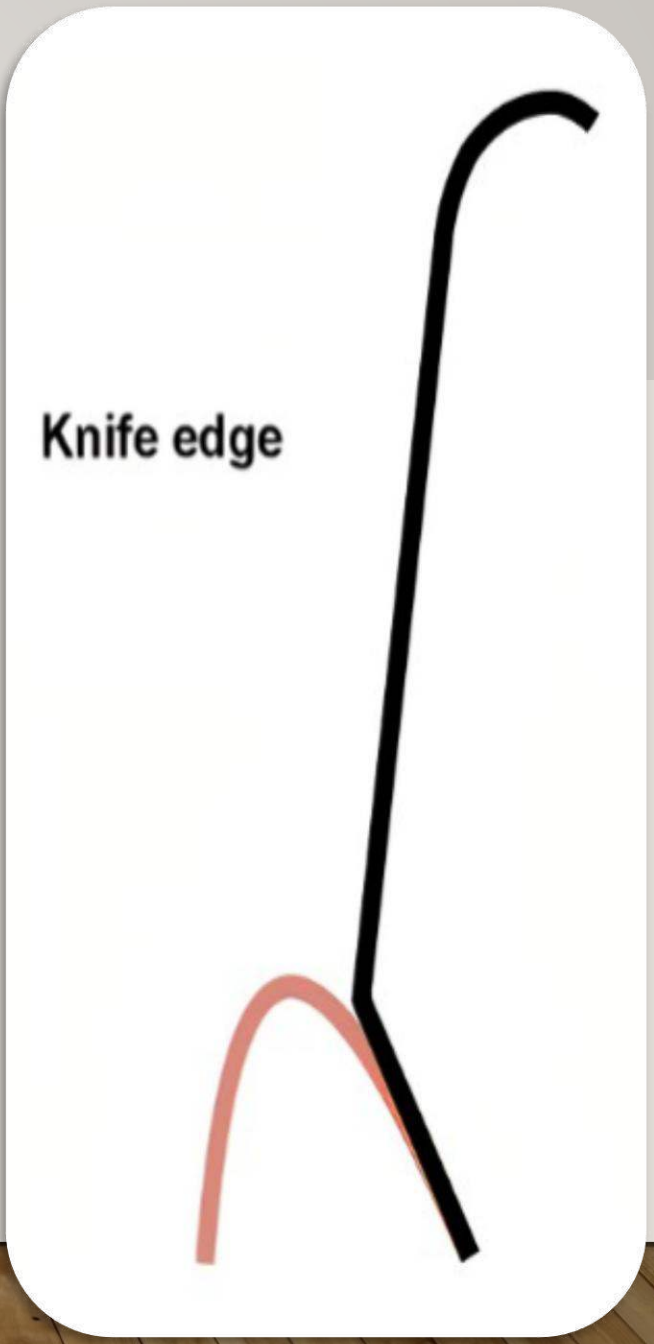

Indications of knife edge finishing line

- It is mainly used for:

1. Full Metal Crown (All the surfaces).

2. The lingual and proximal surfaces of full veneer crown, three-quarter crown and post crown.

2. Chamfer finishing line

- It is similar to a knife edge finishing line **except** that the cut is made deeper.
- It forms a 130-160° cavo-surface line angle.
- A **rounded tapered fissure bur** is used to obtain this preparation margin.
- It provides adequate space at the cervical region; so it can make the contour of the crown restoration within the contour of the natural tooth without contouring the final restoration.
- However, the restoration margin obtained with this type of finishing line is thick, so it is **unburnishable type**.





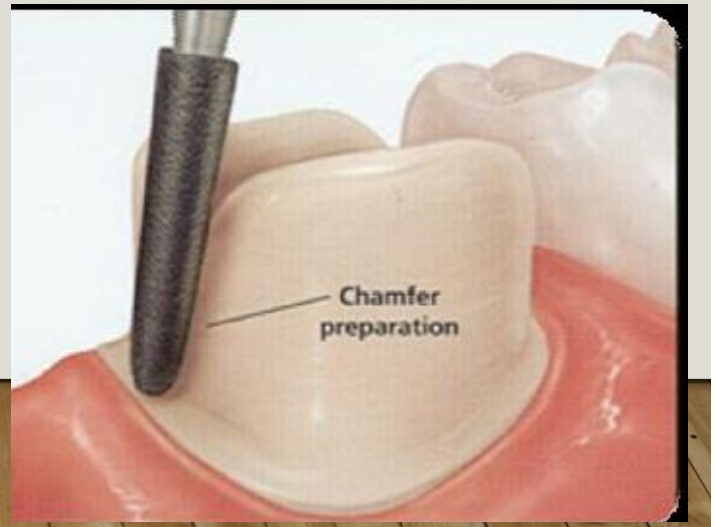



Indications of Chamfer Finishing Line

1. Full Metal Crown (All the surfaces).

2. The lingual and proximal surfaces of the full veneer crown, three-quarter crown and post crown(endocrown).

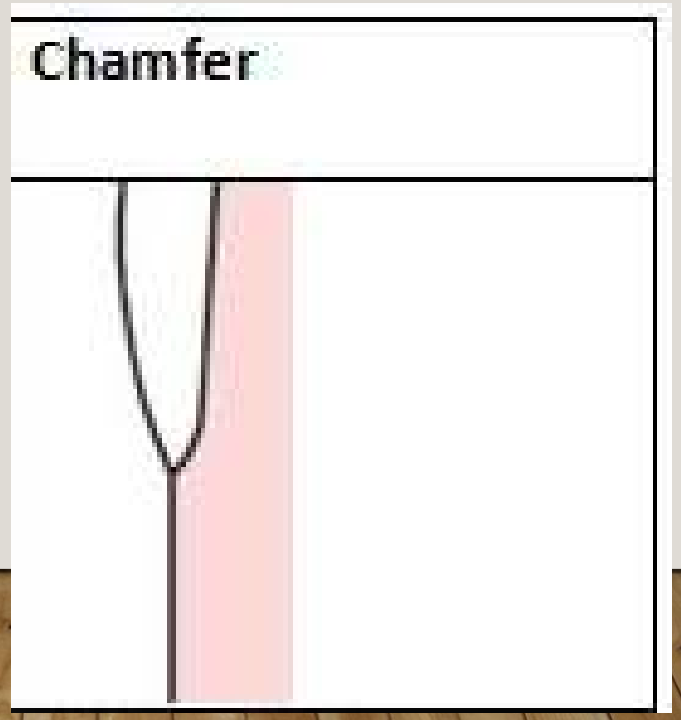

3. Heavy chamfer finishing line

- This type of finishing line provides a **90°** cavo-surface line angle with a large radius internal angle, so it provides better support for the ceramic crown.
- It can be used with porcelain fused to metal (PFM) crown and All Ceramic crowns.

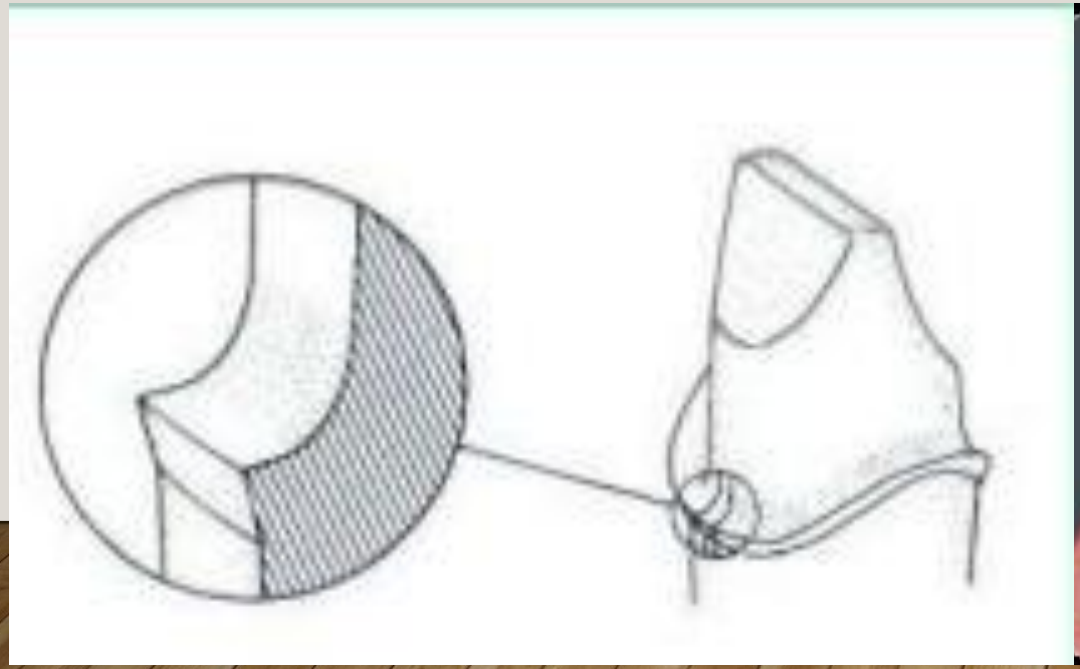



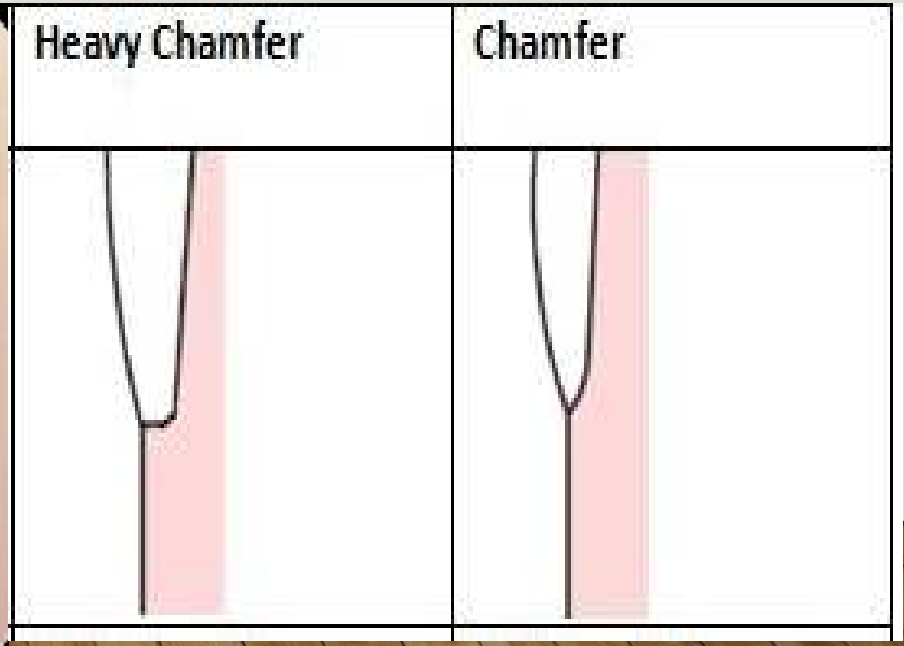

4. Shoulder finishing line (Butt shoulder)

- Shoulder finishing line is the least conservative type of finishing line due to the excessive amount of tooth structure removed to obtain this type of finishing line.
- In the shoulder finishing line, the axial walls meet the finishing line at a right angle.
- A **flat-end tapered fissure bur** is used to obtain this finishing line.



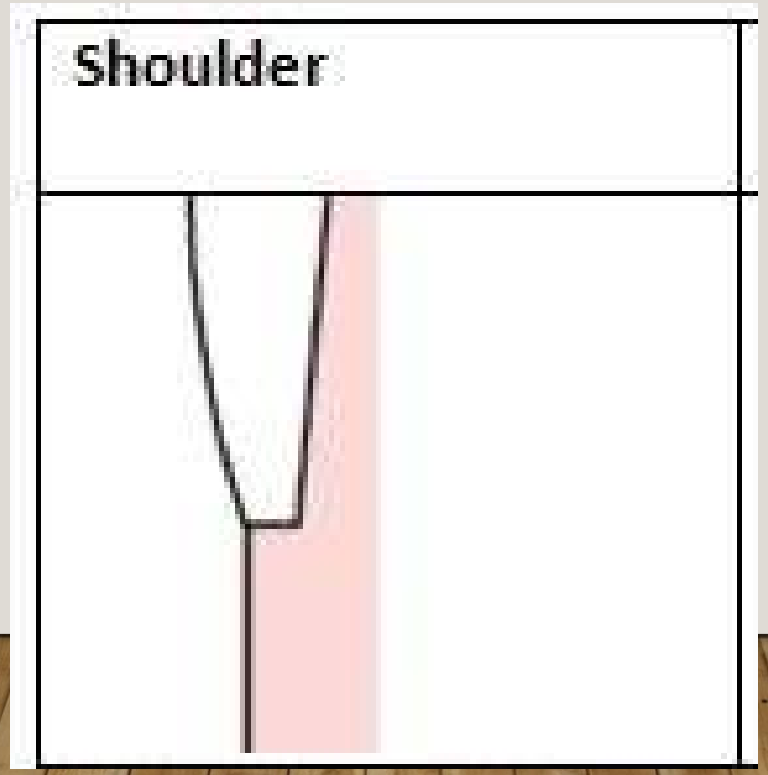

- This type of finishing line is used when the bulk is required for strength or esthetic, that's why it is almost used with **jacket crowns** since jacket crown is made of either porcelain or acrylic resin, which are brittle materials and require enough thickness to withstand the occlusal forces without fracture.
- On the other hand, the increased thickness provides better shade of the material and so better esthetics.

6. Shoulder with bevel finishing line

- Shoulder with bevel is another modification of the shoulder finishing line by adding a bevel to the shoulder.
- The bevel is at 45° angle.
- A **flat-end tapered fissure bur** and **flam-shaped burs** are used to obtain this finishing line.



Objectives of adding a bevel to the shoulder finishing line

1. To provide a burnishable margin for the metal that may extend subgingivally
2. To provide enough space for shape and contour.
3. To reduce marginal discrepancies.
4. To remove unsupported enamel.

Indications of the shoulder with bevel finishing line

1. It is indicated when we use a combination of the metal with facing porcelain (PFM) as in a full veneer crown for the labial surface.

2. Shoulder with a bevel is recommended for **extremely short walls**.

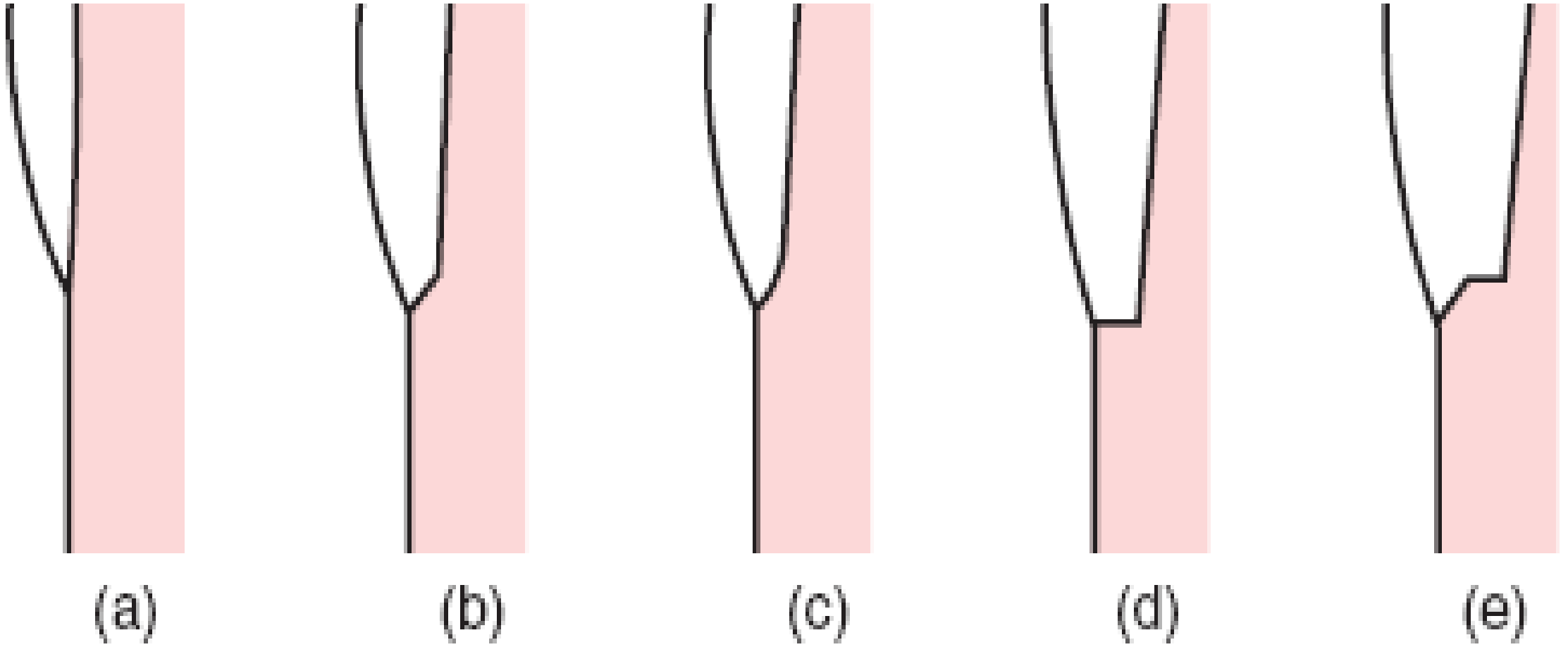
(a)
(b)
(c)
(d)
(e)



Biomechanical Principles of Tooth Preparation

Lecture 4

Prepared By :

Dr. Maitham Yahya Altufaili

Board Speciality (MSc) In Restorative Dentistry

dr_maitham_altufaili

University of Hilla
Dentistry college

Restorative department

30-10-2024

Fifth stage

Biomechanical Principles of Tooth Preparation

Lecture 4

Prepared By :

Dr Maitham Yahya Altufaili

Board Speciality (MSc) In Restorative Dentistry

Dr.maitham_altufaili

@DR.MAITHAM_ALTUFAILI

University of Hilla
Dentistry college

Crown and bridge department

15-11-2025

Third stage

- Full metal crown is a full crown covering all axial surfaces of the tooth as well as the occlusal surface and is made of metal.
- It is one of the most commonly indicated crown restorations for posterior teeth.
- It can be used as a single unit or as a retainer for an F.P.D., especially when we have a small abutment tooth with a long-span edentulous area to overcome the occlusal forces and prevent bridge displacement.
- Since it is a full crown, it has better retention and resistance than other crown restorations such as 3/4 Crown and 7/8 crown because all the axial walls and the occlusal surface are included.





Types of metal alloys used for full metal crown

1. High noble alloys (gold alloys).
2. Low noble alloys (silver-palladium and gold-palladium alloys).
3. Non-noble alloys (Nickel-chromium alloy).





Indications of a full metal crown

1. A tooth with extensive destruction due to caries or trauma to protect the remaining tooth structure from fracture.
2. A tooth with large amalgam restoration to protect the remaining tooth structure and amalgam from fracture.
3. Endodontically treated teeth.
4. When maximum retention and resistance are needed as in a tooth with a short crown.
5. Recontouring of the tooth as in a tooth receiving a clasp for a removable partial denture.
6. As a bridge retainer.
7. A patient with a high caries index.
8. Correction of the occlusal plane.



Contra-indications of full metal crown

1. If high esthetic need is demanded.
2. When less than maximum retention and resistance necessary.
3. When a more conservative crown could be used such as 3/4 crown as in a tooth with intact buccal surface and very short span bridge.
4. When caries index is low.

Advantages of full metal crown

1. Greater retention and strength.
2. High resistance to deformation.
3. Modification of axial tooth contour is possible
4. More conservative than other types of full crown such as porcelain fused to metal and all ceramic crowns.

Disadvantages of full metal crown

1. Extensive tooth structure removal as compared with partial crown such as 3/4crown.
2. Difficulty to test the vitality of the tooth especially by electrical pulp tester.
3. May interfere with taste.
4. Display of metal.

- **Preparation steps:**

1. Occlusal surface preparation.
2. Buccal surface preparation.
3. Lingual surface preparation.
4. Proximal surfaces preparation.

- **Depth Orientation grooves (D.O.G)** are grooves prepared on the surface of the tooth to act as a guide to determine the amount of tooth structure removed by preparation.
- If the preparation is done without these grooves, under or over-preparation is possible.
- It is chamfer finishing line prepared by a **round-end tapered fissure** .
- Knife edge finishing line may also be used.



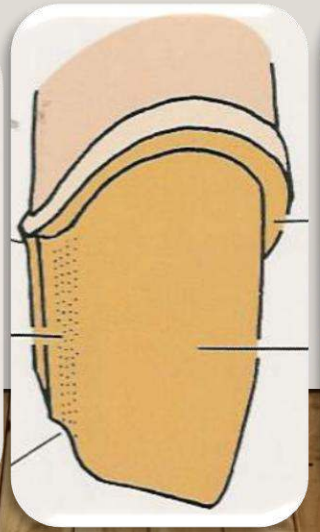

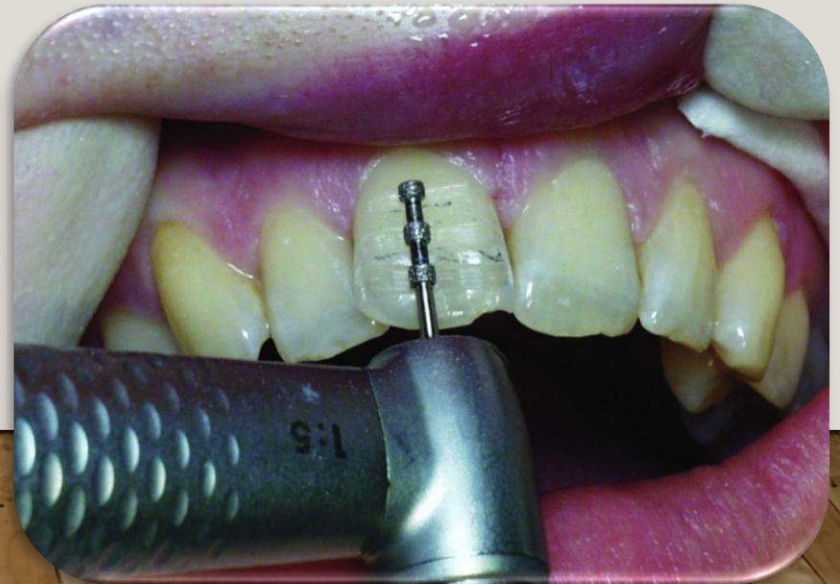

- The recommended tooth reduction for full metal crown is shown in the figure below:

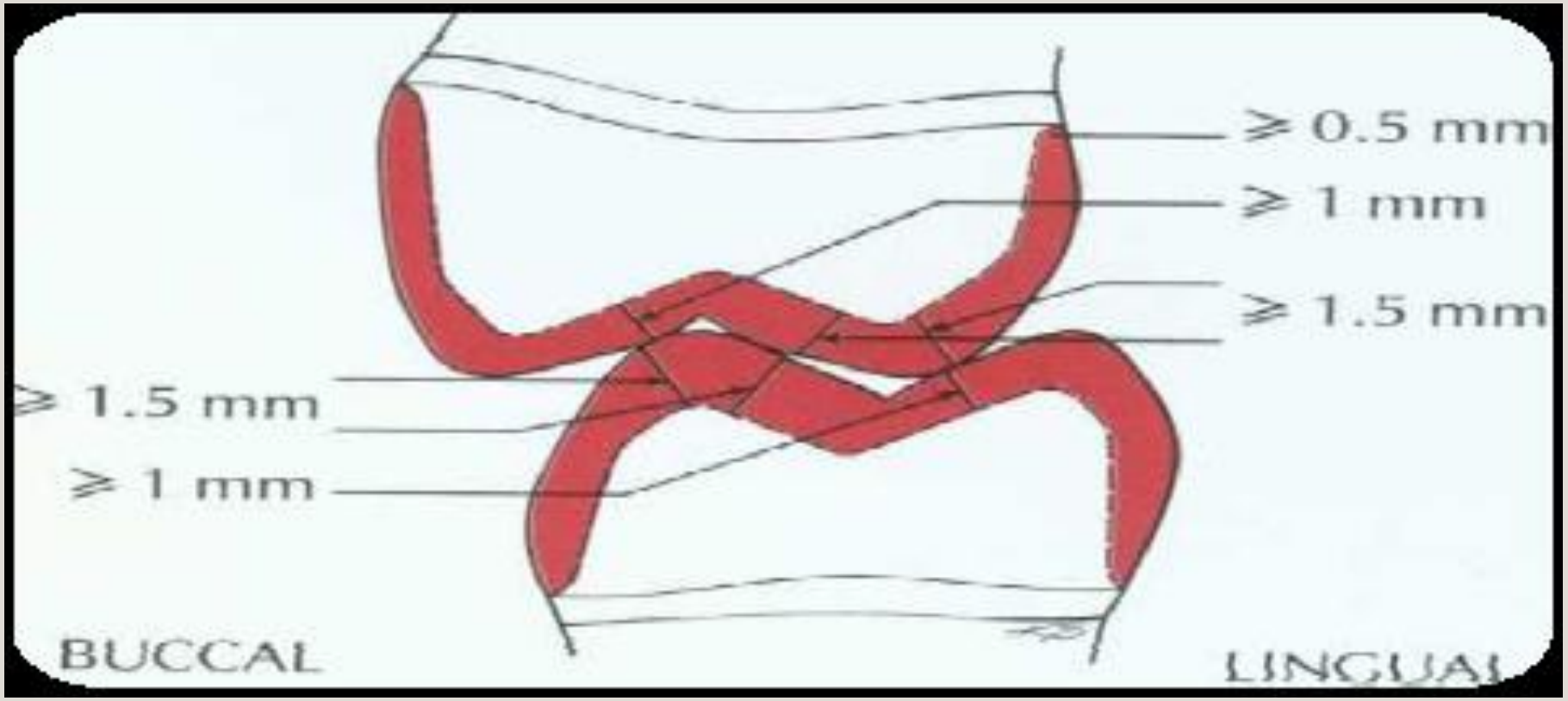

Occlusal surface preparation

- The aim of the occlusal surface preparation is to create 1.5mm occlusal clearance over the **functional cusps** and 1 mm over the **non-functional cusps.**
- Planar occlusal reduction (anatomical reduction) following the geometric inclined planes of the occlusal surface should be done for the following objectives:

  -To provide a restoration with uniform thickness.

  -To preserve the tooth structure (axial wall length).

  -To improve the retention- resistance features of the preparation.



The sequence of the occlusal surface preparation is as follows:

1. Depth orientation grooves (D.O.G) are prepared in the occlusal surface by a fissure bur to follow the inclines of the cusps.

- A D.O.G is prepared in each cusp extending from the cusp tip to the central groove, which represents the deepest part of the occlusal surface.
- The depth of each groove corresponds to the diameter of the fissure bur used. i.e. a fissure bur with 1.5 mm diameter is used to prepare D.O.G on the functional cusps, while a fissure bur with 1 mm diameter is used to prepare D.O.G on the non-functional cusps.

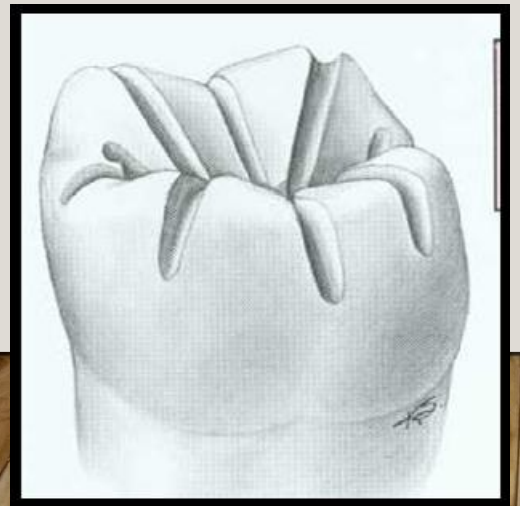

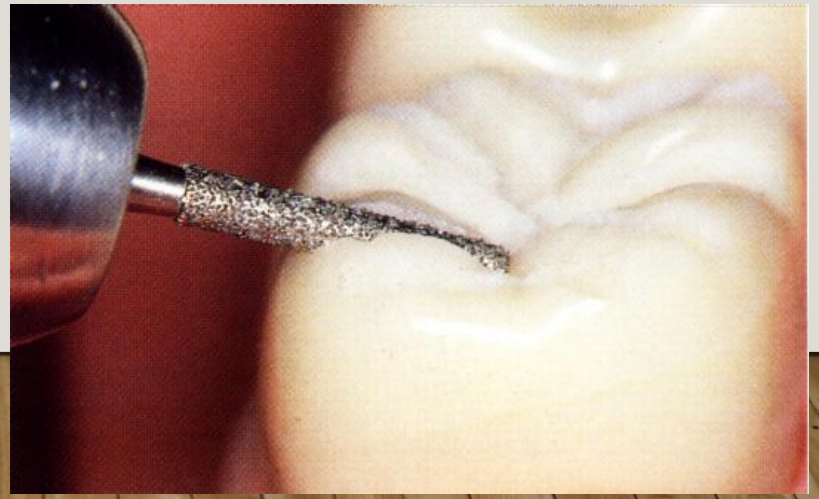

2. Any tooth structure between D.O.G should be removed following the normal contour of the cusps.

3. A wide bevel is placed on the functional cusps.

4. The occlusal clearance is then checked in centric & eccentric occlusal relations.

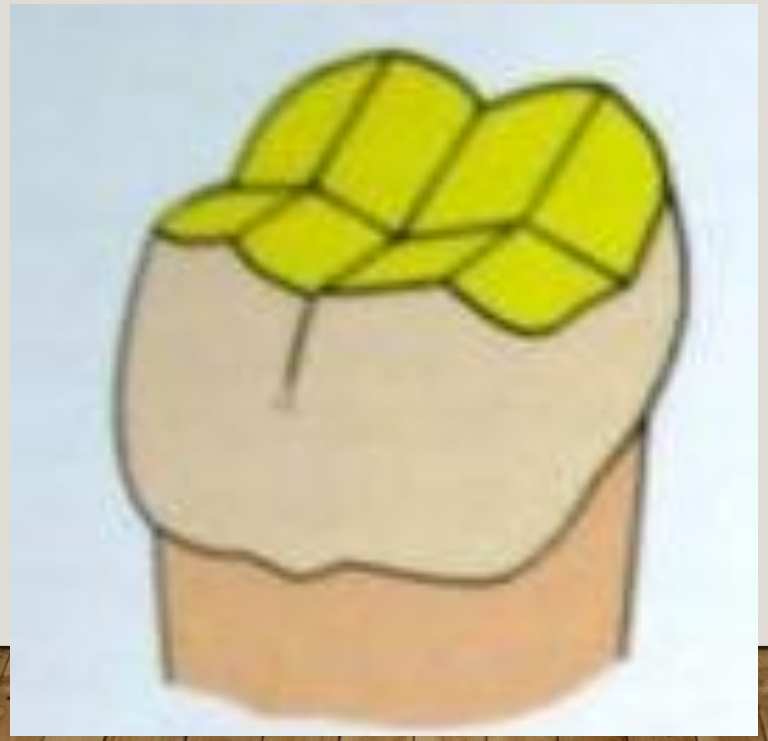

Buccal surface preparation

1. Three D.O.G with 1 mm depth are prepared in the buccal surface of the tooth, one placed in the center of the wall and one in each medial and distal transitional line angles.

- These grooves are prepared parallel to the long axis of the tooth.

2. Move the bur mesially and distally following the inclination of this surface to remove any islands of tooth structure between D.O.G.

- The gingival extent of the preparation will determine the position of the margin (whether to be placed supragingivally, which is preferable, or extend the finishing line sub-gingivally).
- A round-end tapered fissure bur is used during axial reduction to obtain chamfer finishing line.


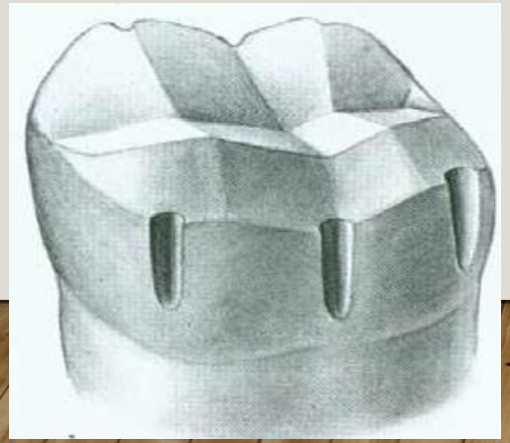



Lingual surface preparation

- The preparation of the lingual surface is the same as that of the buccal surface.

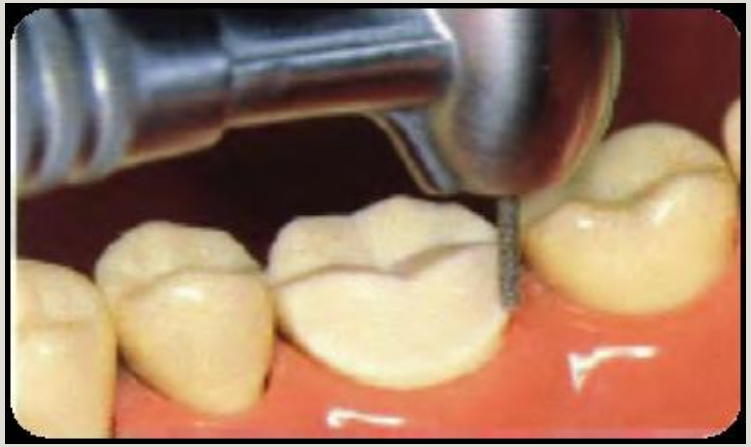



Proximal surfaces preparation

- Using a very thin long **pointed tapered diamond bur**, the contact is removed carefully with the bur rested on the prepared tooth (to prevent any damage to the adjacent tooth), moving the bur up & down, the contact will be opened bucco-lingually.
- Once the contact is opened, a **round-end tapered fissure bur** is used to plane the wall while forming a chamfer finishing line.

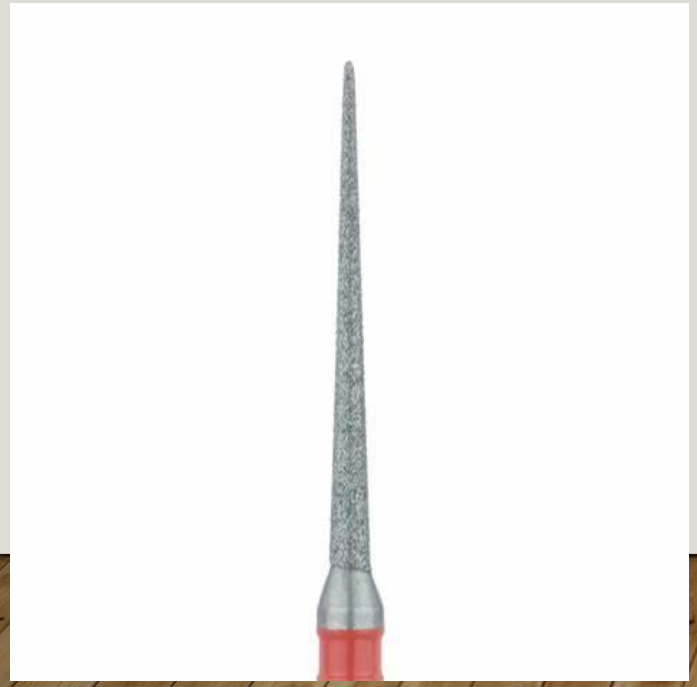





- Safe-sided disc can also be used during the proximal reduction in order to prevent any damage to the adjacent tooth.
- Placing a matrix band on the adjacent tooth can also help.
- After completing the preparation of the occlusal and axial surfaces, smoothening of all surfaces is done to remove sharp line and point angles because they act as stress concentration areas.





- A **seating groove** is finally placed in the buccal surface of the lower molar and the palatal surface of the upper molar.
- **The advantages of placing a seating groove are:**

1. It acts as a guide during the placement of the crown.
2. It prevents the rotation of the crown (by increasing the resistance).
3. It improves the retention.

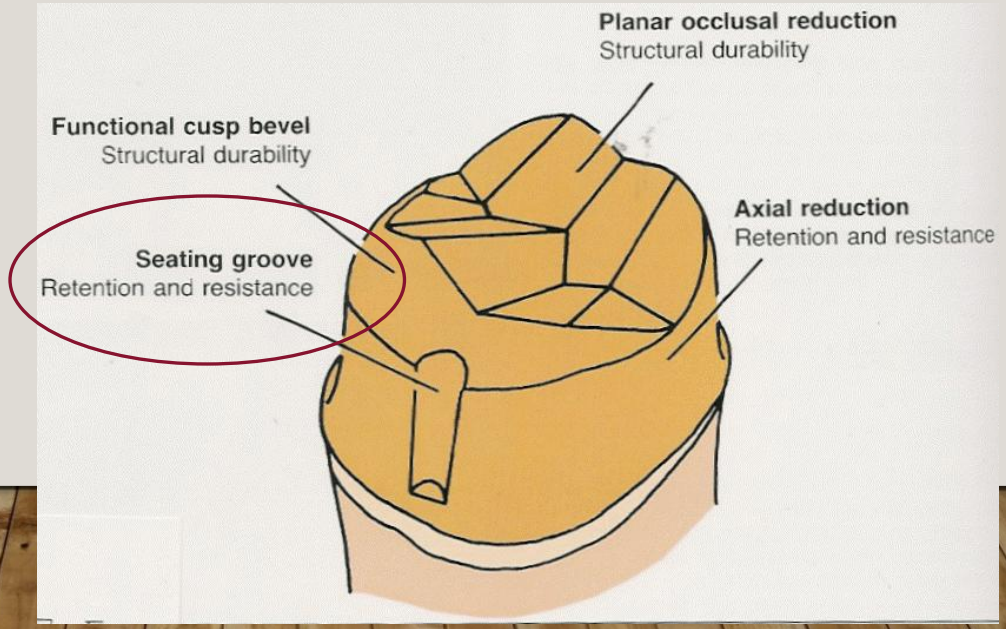


thank
you
FOR
LISTENING