Human Anatomy

The Orbital Region

The orbits are a pair of bony cavities that contain the eyeballs; their associated muscles, nerves, vessels, and fat; and most of the lacrimal apparatus. The orbital opening is guarded by two thin, movable folds, the eyelids.

The Orbit

The orbit is a pyramidal cavity with its base anterior and its apex posteriorly. The **orbital margin** is formed above by the frontal bone, the lateral margin is formed by the processes of the frontal and zygomatic bones, the inferior margin is formed by the zygomatic bone and the maxilla, and the medial margin is formed by the processes of the maxilla and the frontal bone.

Roof: Formed by the orbital plate of the frontal bone, which separates the orbital cavity from the anterior cranial fossa.

Lateral wall: Formed by the zygomatic bone and the greater wing of the sphenoid

Floor: Formed by the orbital plate of the maxilla, which separates the orbital cavity from the maxillary sinus

Medial wall: Formed from before backward by the frontal process of the maxilla, the lacrimal bone, the orbital plate of the ethmoid (which separates the orbital cavity from the ethmoid sinuses), and the body of the sphenoid

Openings into the Orbital Cavity

1. **Supraorbital notch (Foramen):** situated on the superior orbital margin. It transmits the supraorbital nerve and blood vessels.
2. **Infraorbital groove and canal:** Situated on the floor of the orbit in the orbital plate of the maxilla; they transmit the infraorbital nerve and blood vessels.
3. **Nasolacrimal canal:** Located anteriorly on the medial wall; it communicates with the inferior meatus of the nose. It transmits the nasolacrimal duct.

4. **Inferior orbital fissure:** Located posteriorly between the maxilla and the greater wing of the sphenoid; it communicates with the pterygopalatine fossa. It transmits the maxillary nerve and its Zygomatic branch, the inferior ophthalmic vein, and sympathetic nerves.
5. **Superior orbital fissure:** Located posteriorly between the greater and lesser wings of the sphenoid; it communicates with the middle cranial fossa. It transmits the lacrimal, frontal, and nasociliary branches of ophthalmic division of the trigeminal n., trochlear, oculomotor (upper and lower divisions), and abducent nerves, together with the superior ophthalmic vein.
6. **Optic canal:** Located posteriorly in the body of the sphenoid; it communicates with the middle cranial fossa. It transmits the optic nerve and the ophthalmic artery.
7. **Anterior ethmoidal foramen:** located between the frontal and ethmoidal bone and transmit the anterior ethmoidal nerve and vessels.
8. **Posterior ethmoidal foramen:** located between the frontal and ethmoidal bone and transmit the posterior ethmoidal nerve and vessels.
9. **Zygomatic foramen (1 or 2 openings):** located in the zygomatic bone and transmit the zygomatic branches.

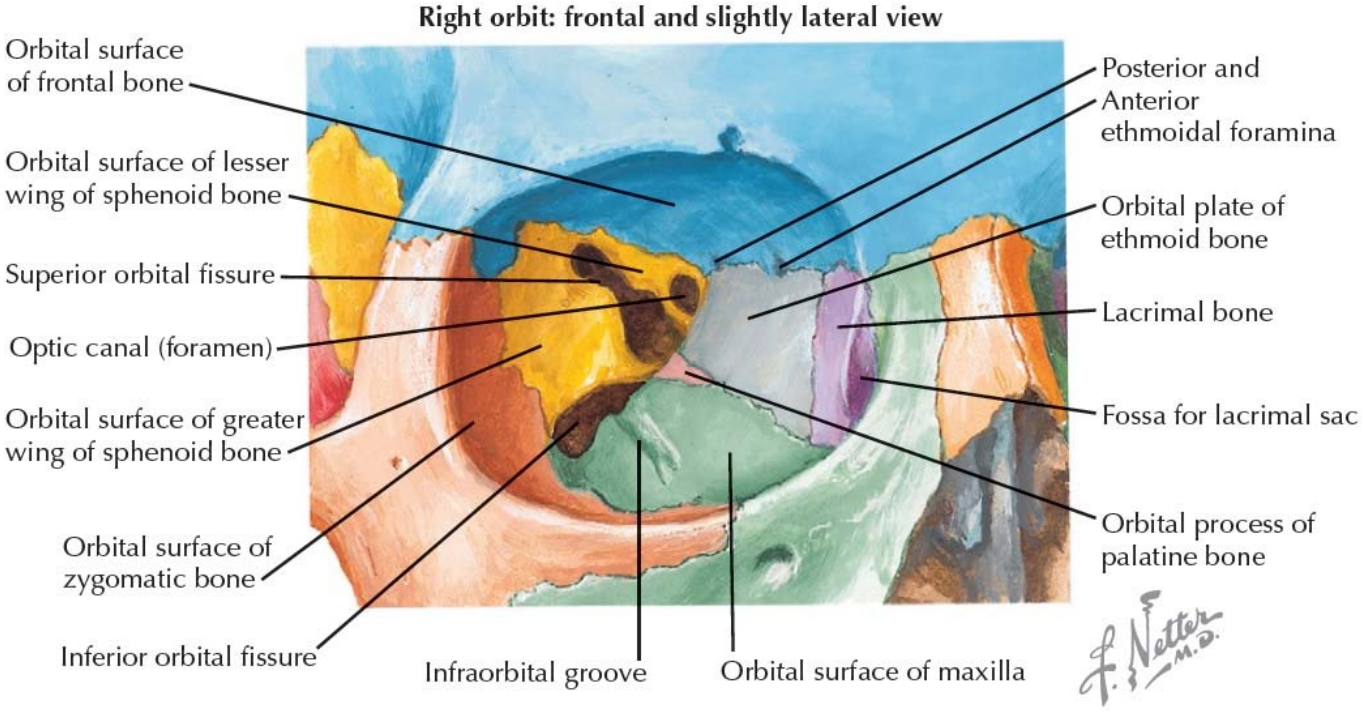

Nasal Cavity

The nasal cavity extends from the nostrils in front to the **posterior nasal apertures** or **choanae** behind, where the nose opens into the nasopharynx. The **nasal vestibule** is the area of the nasal cavity lying just inside the nostril. The nasal cavity is divided into right and left halves by the **nasal septum**. The septum is made up of the **septal cartilage,** the **vertical plate of the ethmoid,** and the **vomer.**

Walls of the Nasal Cavity

Each half of the nasal cavity has a floor, a roof, a lateral wall, and a medial or septal wall.

Floor

The palatine process of the maxilla and the horizontal plate of the palatine bone

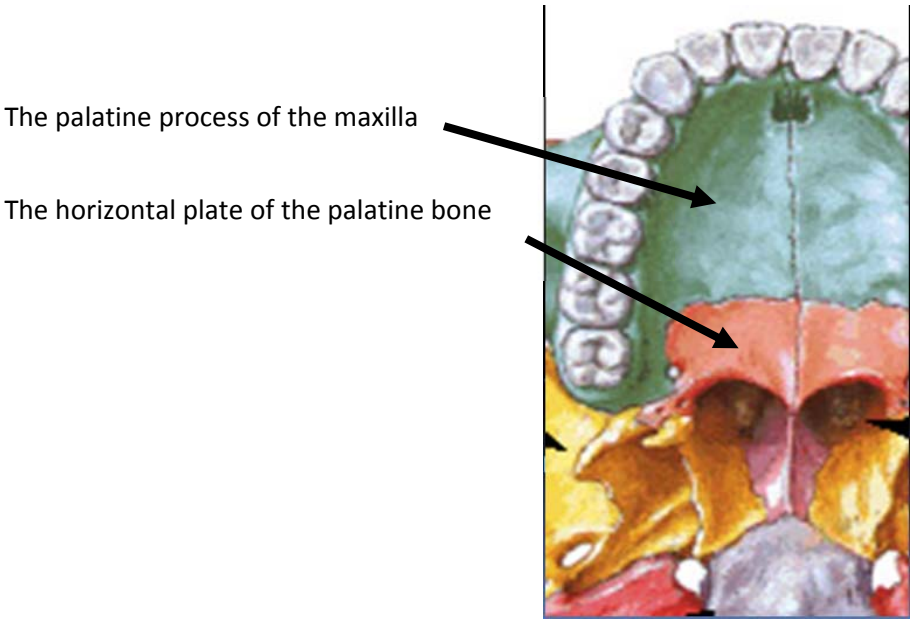

Roof

The roof is narrow and is formed anteriorly beneath the bridge of the nose by the nasal and frontal bones, in the middle by the cribriform plate of the ethmoid, located beneath the anterior cranial fossa, and posteriorly by the downward sloping body of the sphenoid.

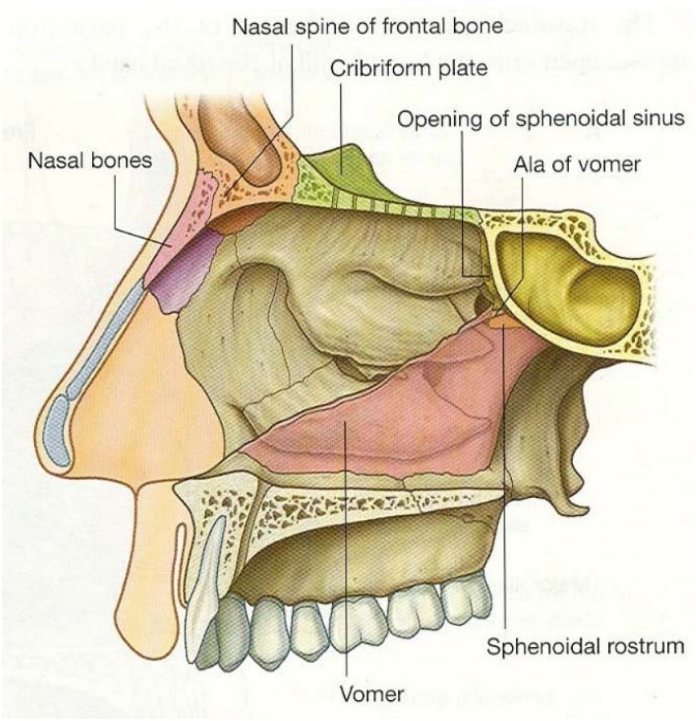

Lateral Wall

The lateral wall of each nasal cavity mainly consists of the

1-maxilla

2- palatine bone,

3- medial pterygoid plate

4- labyrinth of ethmoid

5- inferior concha

6- lacrimal bone

The paranasal sinuses are connected to the nasal cavity through small orifices called ostia

The lateral wall has three projections of bone called the **superior, middle,** and **inferior nasal conchae**. The space below each concha is called a **meatus.**

- **Sphenoethmoidal Recess:** The sphenoethmoidal recess is a small area above the superior concha. It receives the opening of the **sphenoid air sinus**.

- **Superior Meatus:** The superior meatus lies below the superior concha. It receives the openings of the **posterior ethmoid sinuses.**
- **Middle Meatus:** The middle meatus lies below the middle concha. It has a rounded swelling called the **bulla ethmoidalis** that is formed by the **middle ethmoidal air sinuses,** which open on its upper border. A curved opening, the **hiatus semilunaris,** lies just below the bulla. The anterior end of the hiatus leads into a funnel-shaped channel called the **infundibulum,** which is continuous with the **frontal sinus.** The **anterior ethmoidal sinuses** are also open into the **infundibulum.** The **maxillary sinus** opens into the middle meatus through the **hiatus semilunaris.**
- **Inferior Meatus:** The inferior meatus lies below the inferior concha and receives the opening of the lower end of the **nasolacrimal duct,** which is guarded by a fold of mucous membrane.

Figure 6.16b The Nasal Complex, Part I

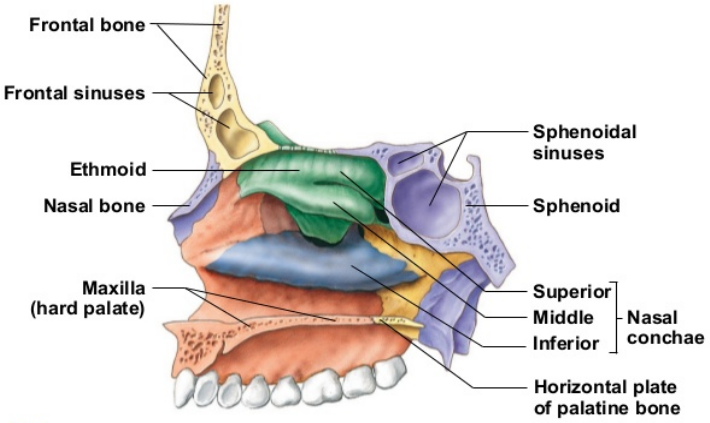

b Diagrammatic sagittal section with the nasal septum removed to show major features of the wall of the right nasal cavity

© 2012 Pearson Education, Inc.

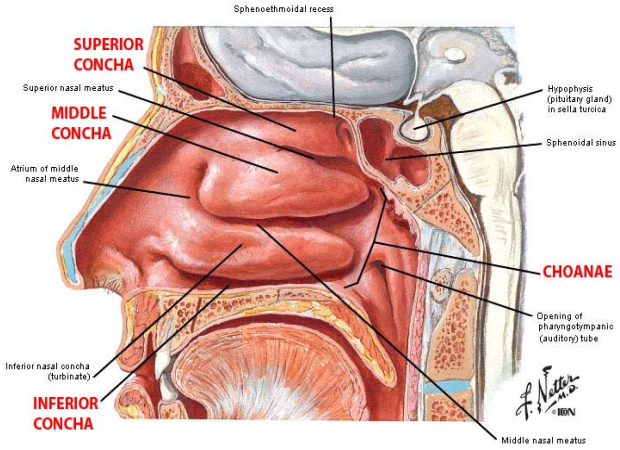

Medial Wall

The medial wall is formed by the nasal septum. The upper part is formed by the vertical plate of the ethmoid and the vomer. The anterior part is formed by the

septal cartilage. The septum rarely lies in the midline, thus increasing the size of one half of the nasal cavity and decreasing the size of the other.

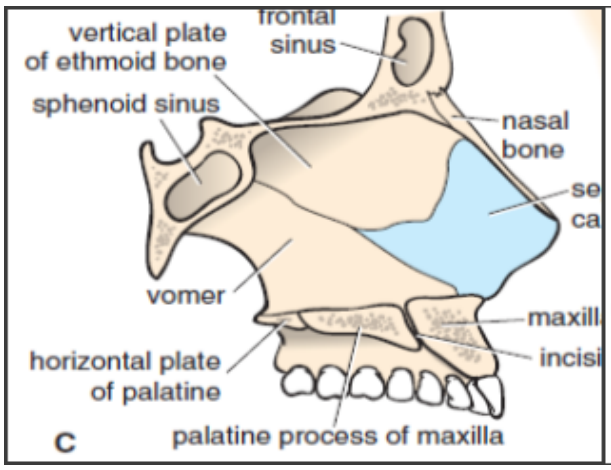

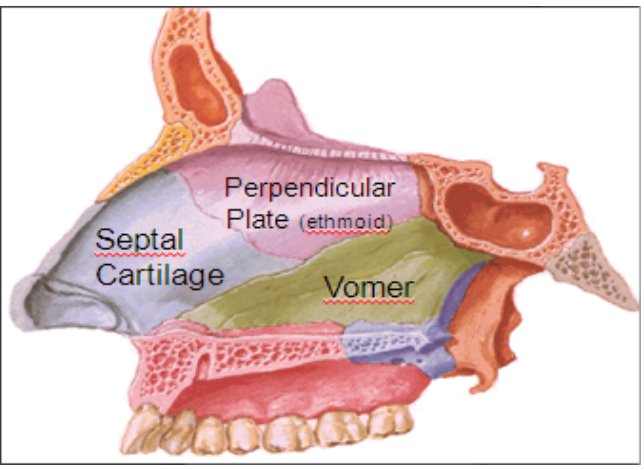

Paranasal Sinuses and Their Site of Drainage into the Nose

Sinus	Site of Drainage
Maxillary sinus	Middle meatus through hiatus semi-lunaris
Frontal sinuses	Middle meatus via infundibulum
Sphenoidal sinuses	Sphenoethmoidal recess
Ethmoidal sinuses	
Anterior group	Infundibulum and into middle meatus
Middle group	Middle meatus on or above bulla ethmoidalis
Posterior group	Superior meatus

☒ **Auditory ossicles** consist of three paired ossicles are the malleus, incus, and stapes.

- The **malleus** is the largest ossicle and possesses a head, a neck, a long process or handle, an anterior process, and a lateral process.

The head is rounded and articulates posteriorly with the incus. The neck is the constricted part below the head.

- The **incus** possesses a large body and two processes.

The body is rounded and articulates anteriorly with the head of the malleus. The long process descends behind and parallel to the handle of the malleus. Its lower end bends medially and articulates with the head of the stapes. The short process is attached to the posterior wall of the tympanic cavity by a ligament.

- The **stapes** has a head, a neck, two limbs, and a base.

The head is small and articulates with the long process of the incus. The two limbs diverge from the neck and are attached to the oval base.

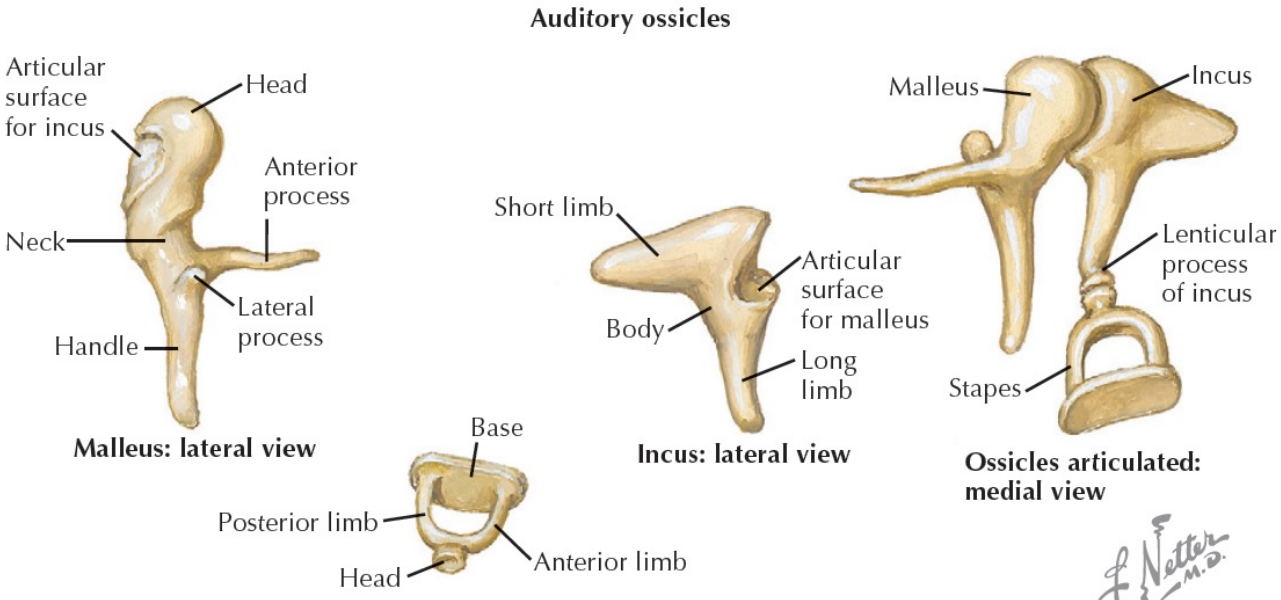

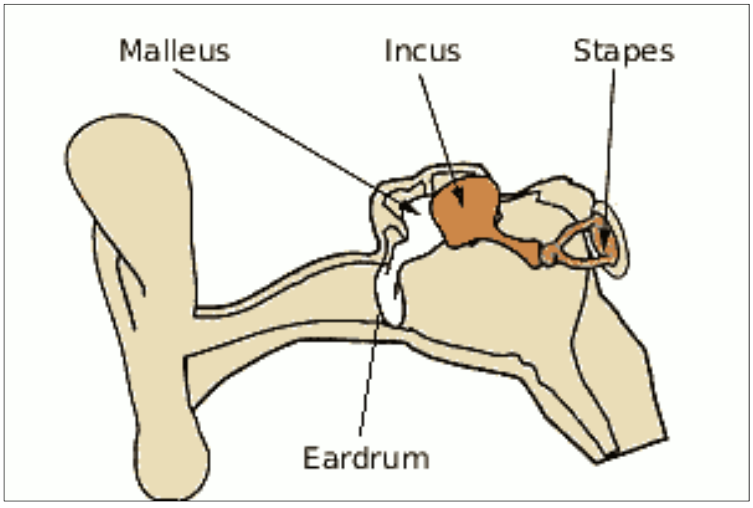

Hyoid bone

The hyoid bone is a mobile single bone found in the midline of the neck below the mandible and abides the larynx. It does not articulate with any other bones. The hyoid bone is U shaped and consists of a body and two greater and two lesser cornua. It is attached to the skull by the stylohyoid ligament and to the thyroid cartilage by the thyrohyoid membrane. The hyoid bone forms a base for the tongue and is suspended in position by muscles that connect it to the mandible (by digastric, geniohyoid and mylohyoid muscles), to the styloid process of the temporal bone (by stylohyoid muscle), to the thyroid cartilage (by thyrohyoid muscle), to the sternum (by sternohyoid muscle), and to the scapula (by omohyoid muscle).

