Mixed Dentition Stage (6–12 Years)

Mixed dentition stage is a transition stage when primary teeth are exfoliated in a sequential manner, followed by the eruption of their permanent successors. This stage spans from 6 years to 12 years of age, beginning with the eruption of the first permanent tooth, usually, a mandibular central incisor or a first molar. It is completed at the time, the last primary tooth is shed.

Significant changes in occlusion are seen in the mixed dentition period due to the loss of 20 primary teeth and the eruption of their successor permanent teeth. Most malocclusions are developed at this stage.

The mixed dentition stage can be divided into the following phases:

- **Early/1st transitional period**
- **Intertransitional period**
- **Late/2nd transitional period.**

Early Transitional Period (6–8 Years)

Early transitional period is concerned with the replacement of the primary incisors by their successors and the addition of four first permanent molars to the dentition. This usually occurs in the age range of 6–8 years

- **Emergence of the First Permanent Molars**

The first permanent molars erupt at 6 years of age with mandibular molar preceding the maxillary molars in most cases. The first molars are considered to play an important role in the establishment of occlusion in the permanent dentition and class I molar relationship is considered as the normal anteroposterior molar relationship. The location and relationship of first permanent molars are influenced by the presence of interdental spacing and the terminal plane relationship of the primary dentition.

The erupting first permanent molars are guided by the distal surfaces of the second primary molars as they erupt into occlusion. Thus, the terminal plane relationship of primary dentition largely determines the type of molar relationship in the permanent dentition, among other factors.

The effects of terminal plane relationships are described in Fig. 1.

- **Effects of Flush Terminal Plane**

Flush terminal plane usually develops into class I molar relationship in the permanent dentition. Some cases of flush terminal plane may also develop into class II molar relationship if forward mandibular growth is not sufficient.

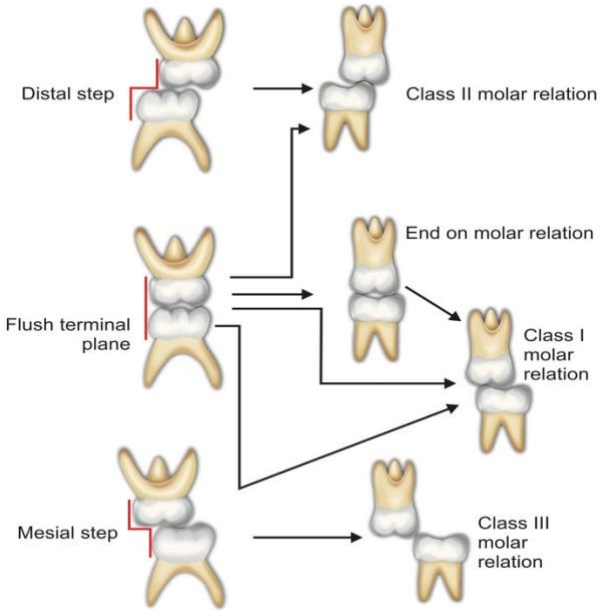

Figure 1 The possible effects of terminal plane relationship on permanent dentition

In the presence of flush terminal plane, the first permanent molars initially assume a cusp-to-cusp or end-on molar relationship, as they erupt distal to the second primary molars. The lower first permanent molar has to move 2–3 mm anteriorly in relation to the upper first permanent molar in order to transform the end-on relation to class I molar relation. This transformation from end-on to class I molar relation occurs in two ways:

1. Early mesial shift
2. Late mesial shift

1. Early mesial shift: Early mesial shift of lower permanent

first molar occurs by utilization of the physiologic spaces present between primary incisors and the primate spaces. The eruptive force of permanent molars pushes the deciduous molars forward into the spaces, thereby establishing a class I molar relationship. As this change occurs in early mixed dentition, the shift is called the “early mesial shift” (Fig. 2).

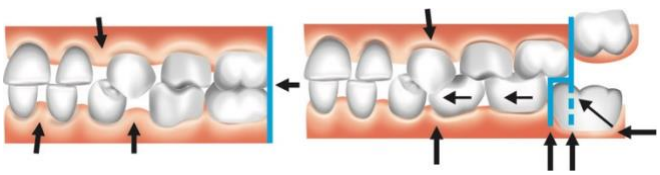

Fig. 2: Early mesial shift: Erupting lower permanent first molars shift mesially, utilizing the primate spaces in the early mixed dentition period to establish class I molar relationship

2. Late mesial shift: In the absence of sufficient developmental spaces in primary dentition, the erupting permanent first molars may not be able to establish a class I relationship in the early mixed dentition period. In such cases, a class I molar relationship can be established following the exfoliation of primary second molars; by utilizing Leeway space (Leeway space is explained later in this lecture). As this occurs in late mixed dentition, it is called the "**late mesial shift**" (Fig3).

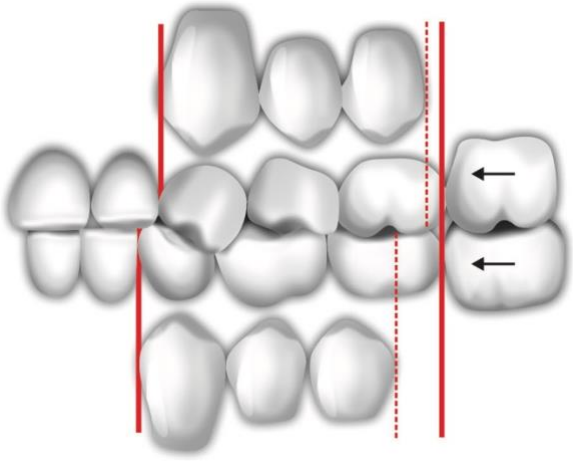

Fig. 3: Late mesial shift: In the case of primate space deficiency, class I molar relationship can be achieved in the late mixed dentition period following exfoliation of primary second molars, utilizing the leeway space

- **Effects of Mesial Step**

When deciduous second molars are in the mesial step, the first permanent molars directly erupt into a class I molar relationship. A few cases may also progress to class III molar relations if forward growth of the mandible persists.

- **Effects of Distal Step**

Distal step in primary dentition usually leads to Angle's class II molar relationships in the permanent dentition. A few cases may go into class I molar relationship.

Eruption of Permanent Incisors

Permanent incisors erupt lingual to the primary incisors and mandibular central are often the first to erupt. How the larger permanent incisor teeth are accommodated is described below:

- **Incisal liability**

It can be readily appreciated that the mesiodistal crown dimensions of permanent incisors is considerably greater than that of the primary incisors. This difference in the mesiodistal crown dimension between the primary and permanent incisors is termed an incisal liability by **Warren Mayne** (Box 1).

Box 1: Incisal liability by Warren Mayne

According to the average tooth size given by Black:

- **Incisal liability in maxillary arch is about, 7.6 mm—i.e., the maxillary permanent incisors are larger than their predecessors by 7.6 mm.**
- **Incisal liability in mandibular arch is about, 6.0 mm—i.e., mandibular permanent incisors are 6.0 mm larger than their predecessors**

Thus, the amount of space available in the arch following exfoliation of the primary incisors is far less than the amount of space needed for accommodation of their permanent successors. Some degree of transient crowding may occur due to incisal liability at about 8–9 years of age and persist until the emergence of canines when the space for teeth may again become adequate.

During the course of mixed dentition period, nature makes some adjustments to achieve the fit and maintain the dynamic balance

The incisal liability is overcome by the following factors:

- Utilization of interdental spacing between primary anterior: Incisal liability is partly compensated by the developmental spaces that exist in the primary dentition. Anterior crowding of permanent dentition may develop in the absence of interdental spacing.
- Increase in the inter-canine arch width: The continuing growth of the jaws often results in an increase in the intercanine arch width during the mixed dentition period. This may significantly contribute to the accommodation of the bigger permanent incisors in the arches.
- Change in incisor inclination: As stated previously, the deciduous incisors are more vertically positioned than the permanent incisors. Permanent incisors exhibit a more labial inclination, which tends to increase the dental arch perimeter. The change in the labiolingual inclination of incisors also contributes to overcome the incisal liability by adding 2–3 mm to the arch see figure 4

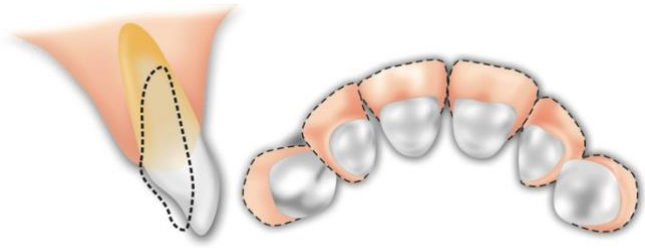

Figure 4 Relationship of primary and permanent incisors over basal bone: Deciduous incisors are vertically placed over basal bone while permanent incisors exhibit more labial inclination that tend to increase the dental arch perimeter.

Intertransitional Period

After first permanent molars and incisors establish occlusion, there is an interim period of 1–2 years before the commencement of second transitional period in which little changes in the occlusion is seen. This phase of mixed dentition stage is relatively stable with only minor changes taking place and is referred to as inter- transitional period.

Second Transitional Period (10–13 Years)

The second transitional period involves replacement of molars and canines by the premolars and permanent canines respectively and the emergence of second permanent molars. Exfoliation of mandibular primary canine at around 10 years of age usually makes the beginning of second transitional period.

- **Eruption of Permanent Canines**

Mandibular canines erupt following the eruption of the incisors at around 10 years, while the maxillary canines usually erupts after the eruption of one or both the premolars, at around 12–13 years.

Ugly Duckling Stage

A transient malocclusion with appearance of midline diastema and flaring of upper incisors is often observed to develop in the maxillary anterior region during 8–12 years of age. This corresponds to the eruption of permanent maxillary canines. Clinicians need to recognize it as a self-correcting malocclusion and the anxious parents and children may have to be reassured. The course of events in the development of ugly duckling stage is as provided in (Figs 5 A and B)

Broadbent described this stage of development as the ugly duckling stage as the children appear ugly with crooked teeth during this phase of development. The condition resolves by

itself as the continuously erupting canines shift the pressure from roots of lateral incisors to their crowns. By the time canines are fully erupted the midline diastema is closed and laterals are realigned along the arch.

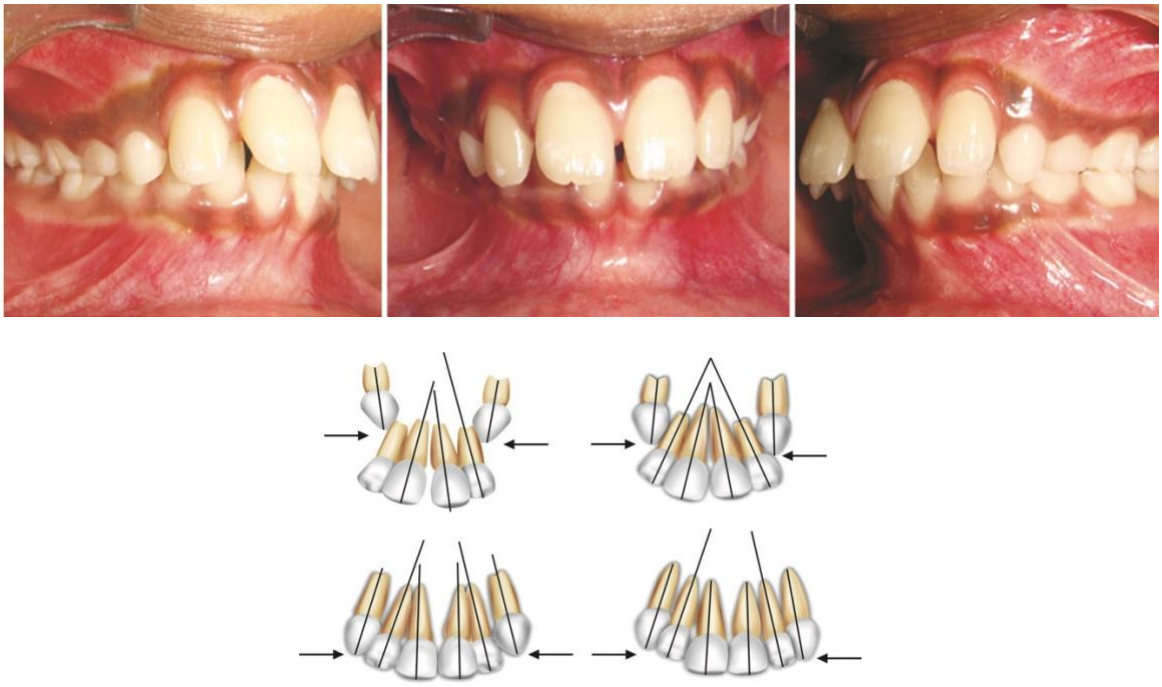

Figs 5 and B: Ugly duckling stage: clinical and schematic representation.

Table 1 describe the Broadbent phenomenon.

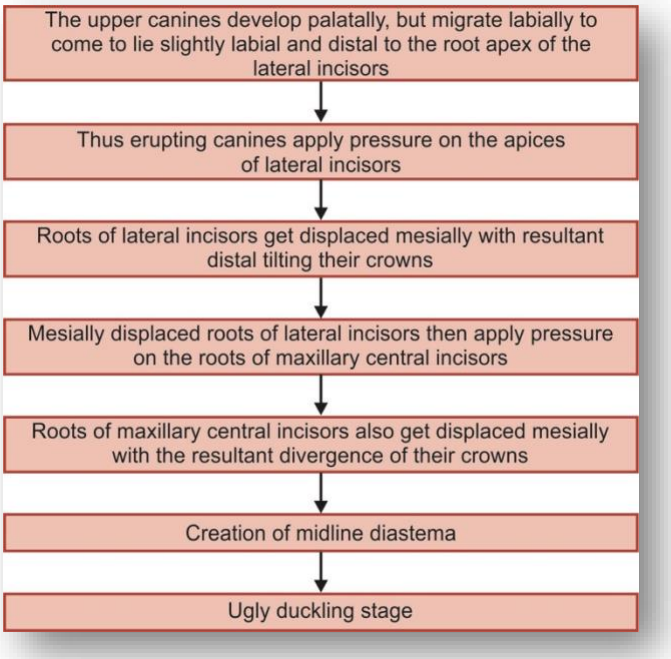

Eruption of the Premolars

The important portion of the dental arch in the development of occlusion is the premolar segment. This is because the erupting premolars are significantly smaller in mesiodistal dimension than the primary molars that they replace. Thus, major changes in occlusion are observed during the premolar emergence.

- ### Leeway Space of Nance

In general, the combined mesiodistal crown dimension of the primary canine and primary first and second molars is greater than the combined mesiodistal crown dimension of their successors namely permanent canine and first and second premolars. The amount of space gained by this difference in the posterior segments is termed as the Leeway space of Nance and is present in both the arches (Fig. 6.17).

Measurement of Leeway space for maxillary and mandibular arches is given in Box 2.

Box 2: Measurement of Leeway space for maxillary and mandibular arches

In maxilla

- **The leeway space in maxilla in each quadrant is about 0.9 mm.**
- **The total Leeway space in maxilla is 1.8 mm.**

In mandible

- **Leeway space in each quadrant of the mandible is about 1.7 mm.**
- **The total Leeway space in the mandible is 3.4 mm.**

Significance of Leeway Space of Nance

- Presence of excessive Leeway space is a favorable feature, which provides for the mesial movement of the permanent molars.
- Leeway space in the mandibular arch is more than that of the maxillary arch. This is because the primary mandibular molars are wider than the primary maxillary molars. The Leeway space differential between the two arches cause the mandibular first molar to move mesially relatively more than the maxillary first molar. Such an arrangement causes a change in the molar relationship from end-on in the early mixed dentition period to class I relation at the late mixed dentition period (late mesial shift).

- Leeway space deficiency may be seen in some individuals when size of unerupted premolars and permanent canine are larger than the space available.

Eruption of Permanent Second Molars

The emergence of second permanent molars ideally should follow the eruption of the premolars. If the second molars erupt before the premolars erupt fully, a significant shortening of the arch perimeter occurs and malocclusion may be more likely to occur.

Change in the Anteroposterior Molar Relationship in Mixed Dentition

To begin with, the newly erupted permanent first molars occlude in a cusp-to-cusp relation, especially when deciduous dentition exhibit flush terminal plane. Cusp- to-cusp/end-on molar relationship which is considered normal in early mixed dentition stage, changes into class I molar relationship, which is considered normal in permanent dentition stage by the following factors:

- Leeway space of Nance (Explained above in this lecture)
- Differential mandibular growth.

Differential Mandibular Growth

During growing period, both the maxilla and the mandible grow downward and forward.
However, the mandible grows relatively more forward than the maxilla during this developmental stage. Such differential mandibular growth is thought to contribute to the transition from end-on to class I molar relationship.

Permanent Dentition Stage (12 Years and Beyond)

Permanent dentition stage is pretty well established by about 13 years of age with the eruption of all permanent teeth except the third molars. Permanent successors develop from the lingual extension of the dental lamina (successional lamina) and the permanent molar develops from the posterior extension of the dental lamina. The permanent incisors develop lingual to the primary incisors and move labially as they erupt. The premolars develop below the divergent roots of the primary molars.
Permanent dentition begins to form at birth, at which time, calcification of the first permanent molars becomes evident.
Sequence of the eruption of permanent dentition is more variable than that of the primary dentition. In addition, there are significant differences in the eruption sequences between the maxillary and the mandibular arch.

Most Common Eruption Sequence in Maxilla
6-1-2-4-3-5-7-8 or 6-1-2-4-5-3-7-8

MostCommonEruptionSequenceforMandibularArch
(6-1)-2-3-4-5-7-8 or (6-1)-2-4-3-5-7-8

These are also the most favorable sequences for the prevention of malocclusion. It must be noted that there is a difference in eruption timing of the canines in the two arches. In the mandibular arch, the canines erupt before the premolars, whereas in the maxillary arch, the canines generally erupt after the eruption of premolars.
When second molars erupt before the premolars are fully erupted, significant shortening of the arch perimeter occurs due to mesial migration of permanent molars increasing the likelihood of malocclusion.

Characteristics of Occlusion in Permanent Dentition

Dental occlusion; some of the characteristics of the normal occlusion in the permanent dentition stage are listed below:

- **Overlap**

The maxillary teeth overlap the mandibular teeth, both in labial and buccal segments in centric occlusion (Fig. 6 A and B).



Figs 6 A and B: Normal incisal relationship: (A) overbite; (B) overjet

- **Intra-arch Tooth Contacts**

With the exception of the maxillary third molars and mandibular central incisors, each permanent tooth occludes with two teeth from the opposite arch. In other words, each permanent tooth has two antagonistic teeth.

- **Angulations**

Permanent teeth have buccolingual and mesiodistal angulations, whereas the primary teeth are generally vertically positioned in the alveolar bone.

- **Arch Curvatures**

The anteroposterior curvature exhibited by the mandibular arch is called the curve of Spee. The corresponding curve in the maxillary arch is called the compensating curve. The buccolingual curvature from one side of the arch to the other is called the curve of Monson/Curve of Wilson.

- **Incisor Relationship**

The vertical overlap between maxillary and mandibular incisors is called overbite and is about 1–2 mm and the horizontal overlap called the overjet is generally between 1–3 mm (Figs 6 A and B).

- **Molar Relationship**

In the permanent dentition stage, the class I molar relationship is the ideal relationship. In class I molar relationship, the mesiobuccal cusp of the maxillary first molar is in the buccal groove of the mandibular first molar (Figs 7 A and B).



Figs 7 A and B: Normal molar relationship