Lec. 7 : the tissues(Epithelial tissues)

BY : ASSIST. LEC. ENAS K. ALKHAZRAJI

Tissues

- Tissues are cells that are similar in structure and perform a common related function.

Functions of epithelial cells include secretion, selective absorption, protection, filtration, transport, and sensing.

There are four types of tissues:

- Epithelial tissue
- Connective tissue
- Muscle tissue
- Nerve tissue

Epithelial tissue

is a sheet of cells that:

1. Covering and lining epithelium: forms the outer layer or a body surface such as skin and lines open cavities such as digestive and respiratory systems.
2. Glandular epithelium: surrounds glands within the body.

Characteristics of epithelial tissue:

1– Polarity:

 all epithelia have an apical surface and a lower attached basal surface that differ in structure and function.

 Most apical surfaces have microvilli (small extensions of the plasma membrane) that increase surface area.

 Other epithelia have motile cilia (hair like projections) that push substances along their

free surface. Next to the basal surface is the basal lamina (thin supporting sheet). The basal lamina acts as a filter allowing and inhibiting certain molecules from passing into the epithelium

Characteristics of epithelial tissue:

2-Specialized contacts: epithelial cells fit close together and form continuous sheets, such as cell junctions (tight junctions, gap junctions and desmosomes).

3-Supported by connective tissue: For example, deep to the basal lamina is reticular lamina which forms the basement membrane for reinforces the epithelium and helps it resist stretching and tearing

4-Avascular: Epithelial layers contain no blood vessels.

5-Regeneration: epithelium has a high regenerative capacity and can reproduce rapidly as long as they receive adequate nutrition.

Classification of Epithelia

Based on the number of cell layers, epithelia can classify to simple and stratified.

- Simple epithelia: consist of a single cell layer (found where absorption, secretion, and filtration occur).
- Stratified epithelia: are composed of two or more cell layers.

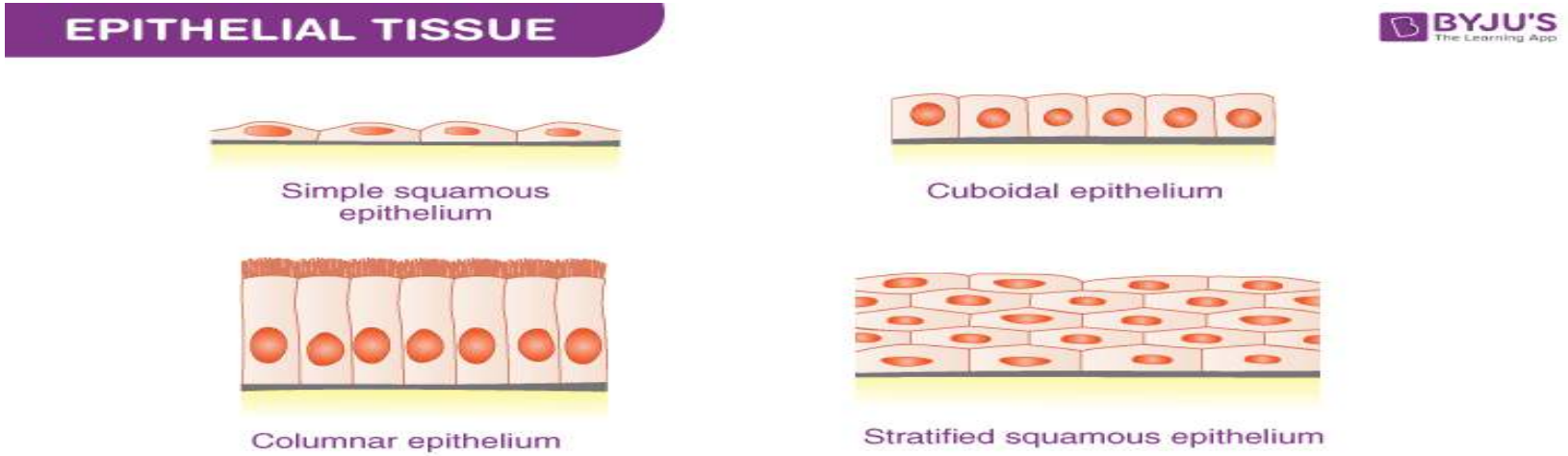

Classification of Epithelia

Depending on the shape of the cells, simple epithelial tissue classified to:

1-Simple squamous epithelium: flat, thin scale like cells with flattened nuclei and thin cytoplasm.

Location: Bowman's capsule in kidneys, lungs, endothelium of blood vessels.

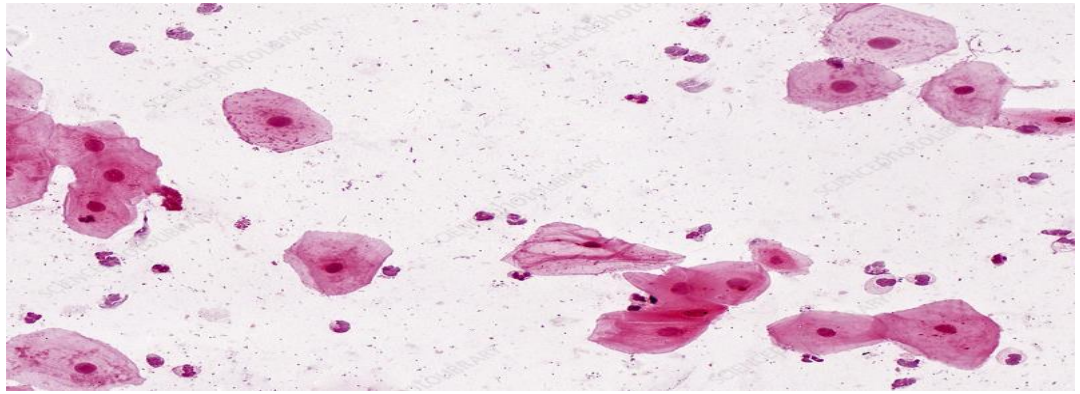

Classification of Epithelia

2-Simple cuboidal epithelium: consists of a single layer of cup- like cells with central nuclei and same height and width. Functions include secretion and absorption.

Location: In small ducts of glands (thyroid, salivary,pancreas), kidney tubules and ovary surface.

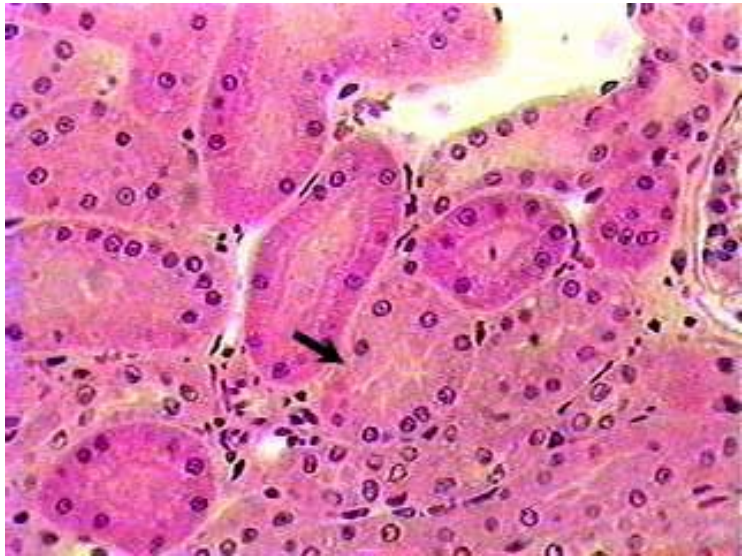

Classification of Epithelia

3-Simple columnar epithelium: is a single layer of tall cell with oval basal nuclei, closely packed cells that line the digestive tract from the stomach to the rectum. Functions include absorption and secretion. They contain dense microvilli and goblet cells.

Location: Digestive system and uterus



Classification of Epithelia

4-Pseudostratified columnar epithelium: It looks like composed of several layers of cells, because the cells have different heights, and gives the illusion of multiple cell layers. Most pseudostratified epithelia contain cilia on their apical surface and the goblet cells are found for secretion.

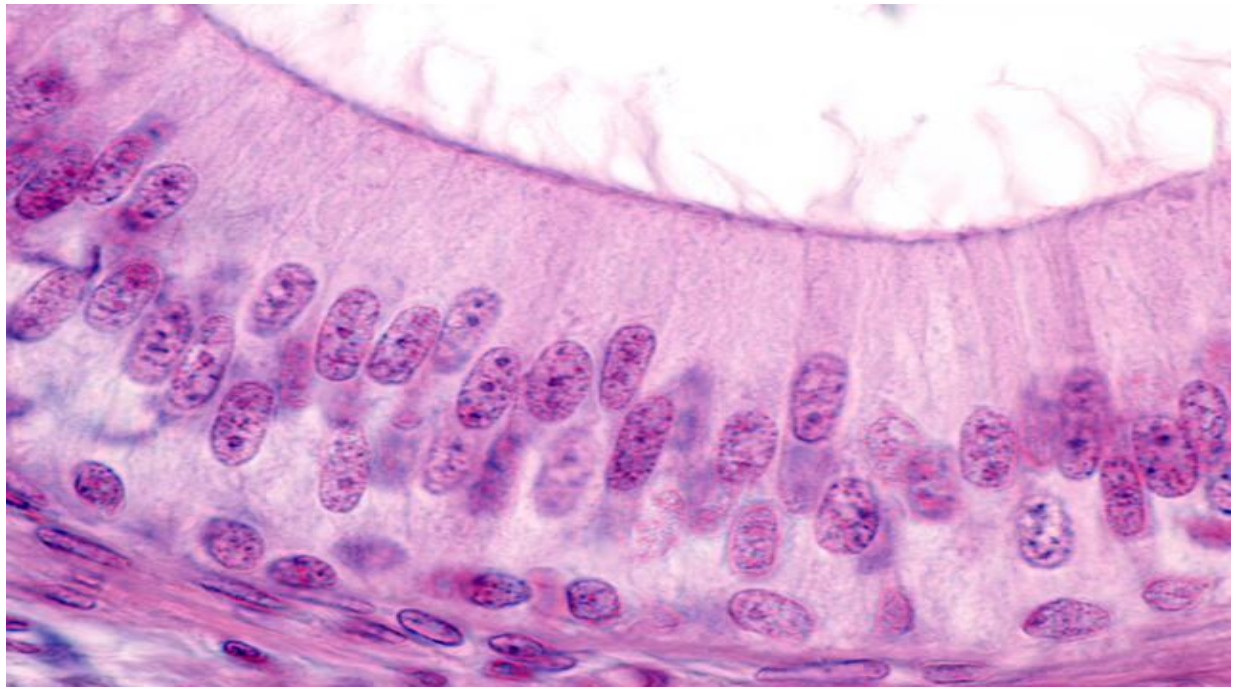

Classification of Epithelia

Stratified epithelial tissue: based on the shape of cells in the apical layer, stratified epithelia can classify to:

1- Stratified squamous epithelium

A- Non-keratinized Stratified squamous epithelium: It's composed of several layers and is perfect for its protective role. Its apical surface cells are squamous and cells of the deeper layer are either cuboidal or columnar while the intermediate cells are polyhedral.

Location: Oral cavity, esophagus, pharynx and vagina

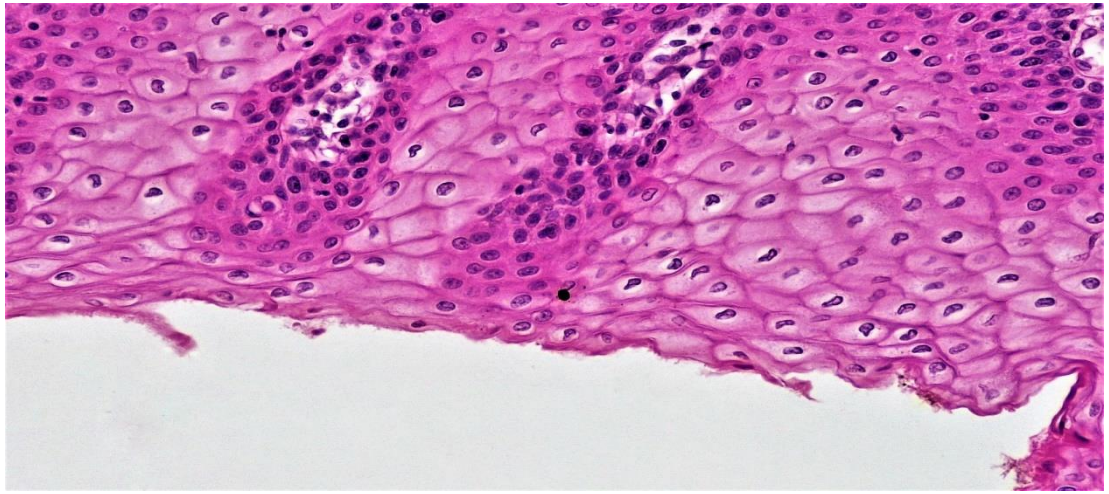

Classification of Epithelia

B– keratinized Stratified squamous epithelium : The surface cells are full with keratin, a protective protein and dead, basal cells are active in mitosis and produce the cell of the more superficial layers.

Location: epidermis of the skin

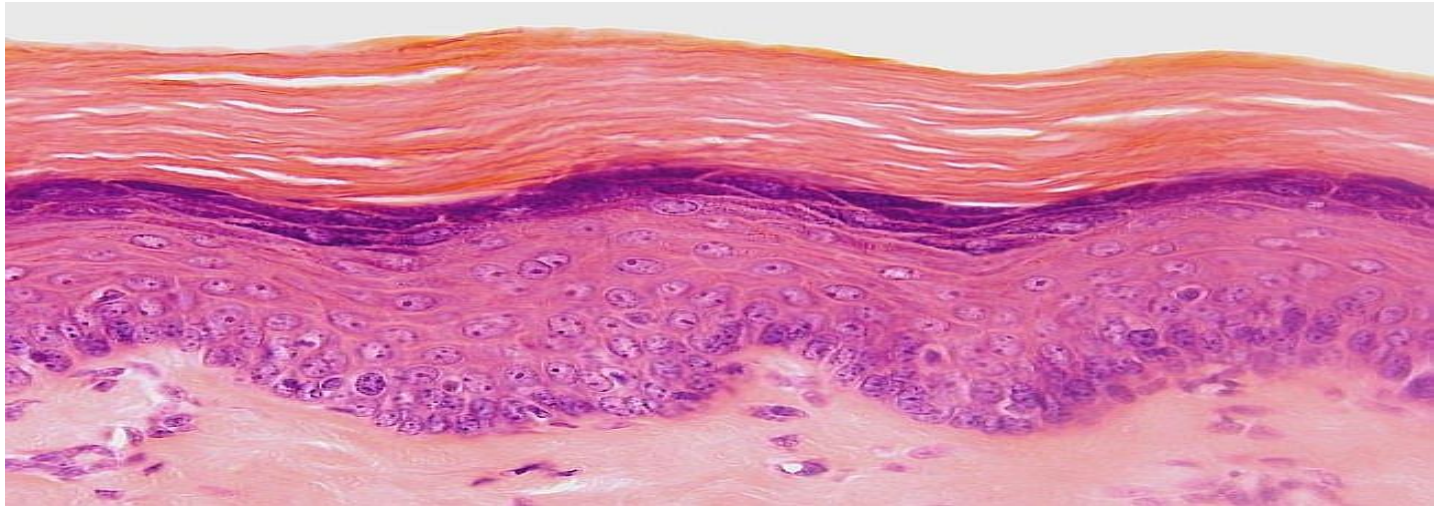

Classification of Epithelia

2-Stratified cuboidal epithelium: It is typically have two layers of cuboidal cells.

Location: It's mainly found in the ducts of glands (sweat glands, parotid gland and mammary glands)

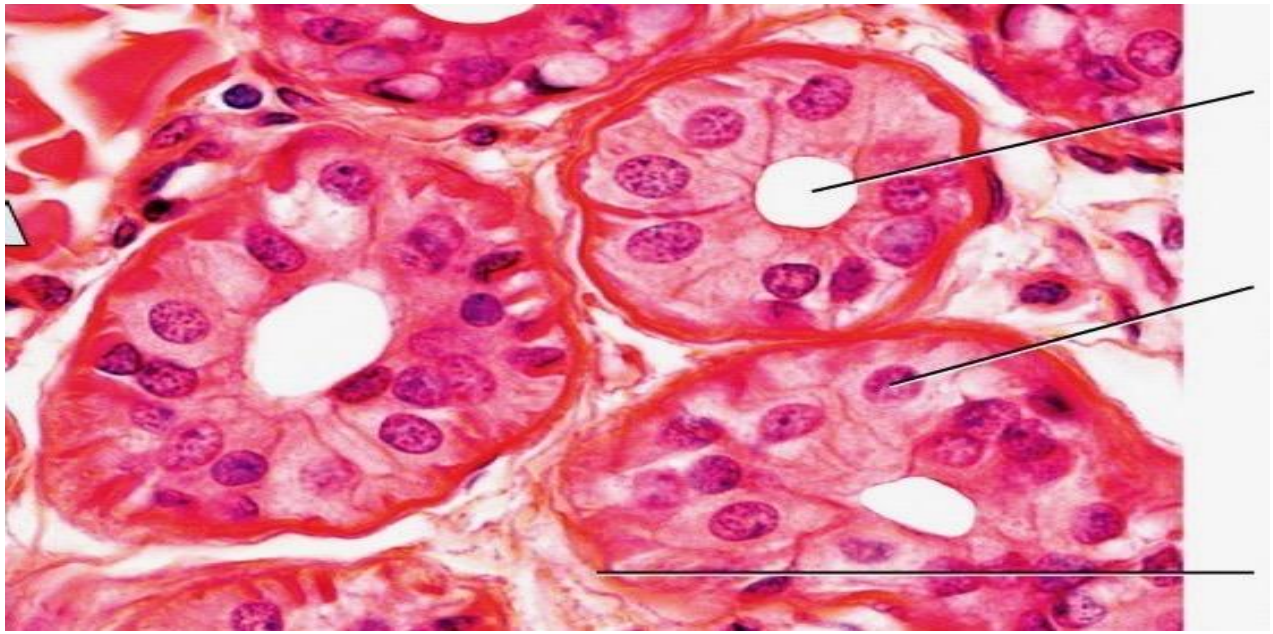

Classification of Epithelia

3- Stratified columnar epithelium: is also rare in the human body.

Location: pharynx, male urethra, and lining of some glandular ducts.

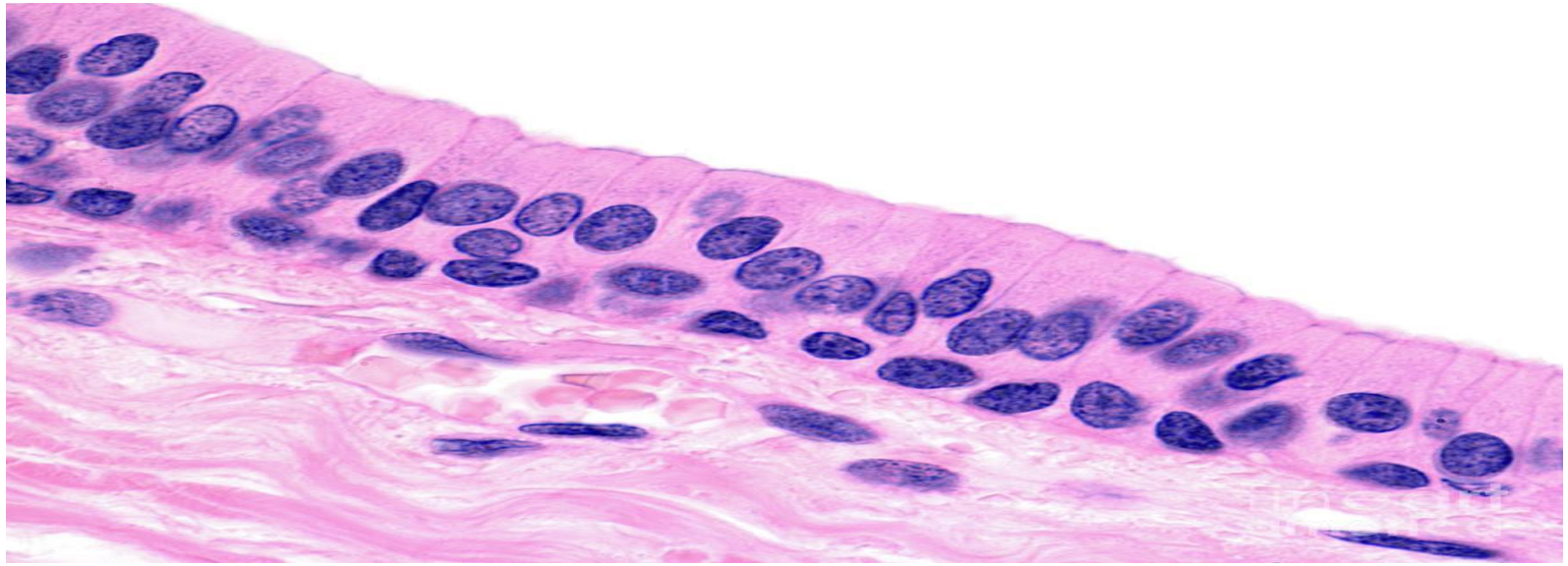

Classification of Epithelia

4- Transitional epithelium: forms the lining of hollow urinary organs, which stretch as they fill with urine. Cells in the basal layer are cuboidal or columnar. So the apical surface vary in appearance depending on the distension of the organ. When the organ is not stretched, the membrane is many layers and the superficial cells are rounded and dome shape. When the organ is distended with urine, the apical cells flatten and became squamous like.

Location: Lines the ureter, urinary bladder and part of urethra

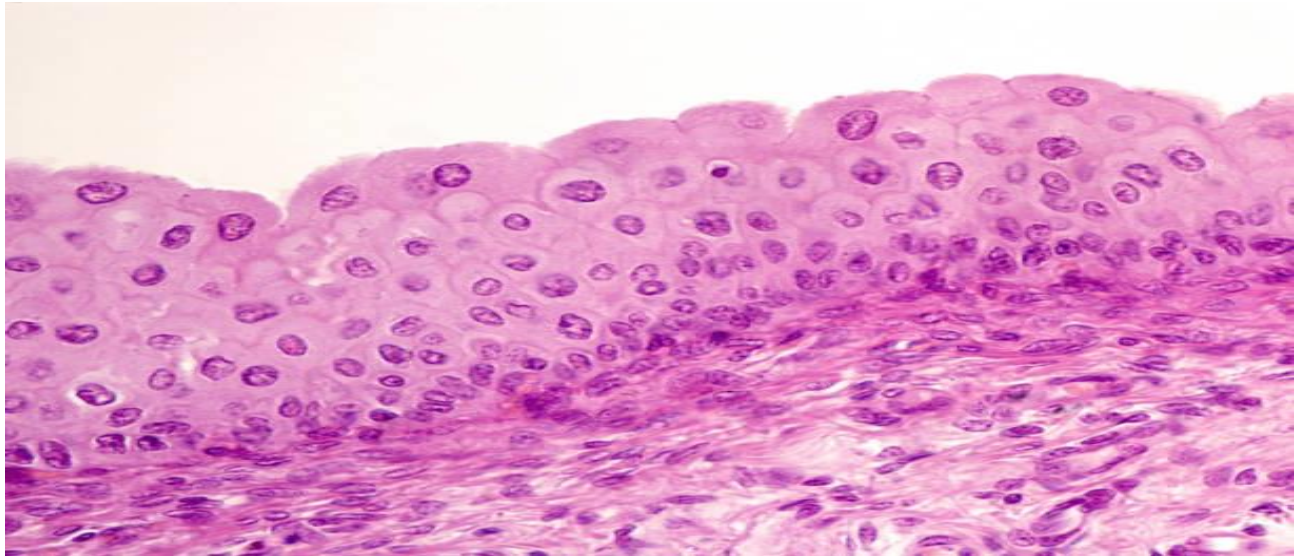


THANKS
FOR YOUR
ATTENTION