IMPROPER DENTAL RESTORATIONS

While restoring any tooth, it is important to restore the normal occlusal anatomy and proximal contours, to maintain normal intercuspation of the teeth and their mesiodistal dimension. Improper restoration of proximal contours may result in an increased arch length and occlusal irregularities. Possible consequences of improper dental restorations are listed in **Table 1**.

	Consequence of improper restoration
Over contoured proximal restorations	• Too tight proximal contact leading to elongation of restored tooth or adjacent teeth. • Over contoured restoration in a segment can cause increase arch length
Under contoured proximal restoration	• Loss of arch length due to drifting adjacent teeth into the space
Over fiiled occlusal restoration	• Functional occlusal prematurities • Intrusion of antagonistic tooth • pseudo class III
Under filled occlusal restoration	• Super-eruption of antagonistic tooth Functional occlusal disturbances

Ankylosis

The tooth is said to be ankylosed when a part or whole of its root surface is directly fused to the bone without intervening periodontal ligament Figure **1**. The term submerged teeth often refers to the ankylosed deciduous teeth. Deciduous second molars are the most affected. Ankylosis of deciduous teeth prevents their natural exfoliation and replacement by their successional permanent teeth. Once the adjacent permanent teeth erupt to their normal level, the ankylosed tooth appears to be submerged below the level of occlusion. This submersion occurs due to the Continued growth of the alveolar process in relation to adjacent permanent teeth, the smaller crown height of the deciduous tooth when compared to that of adjacent permanent teeth, and The antagonistic tooth may supra erupt leading to malocclusion.



Figure 1 ankylosis

ABNORMAL ERUPTIVE PATH

Malocclusions resulting from the abnormal eruptive path of the teeth are not uncommon. Some of the factors, causing delayed eruption of permanent teeth may also deviate their path of eruption, such as:

- Trauma to the tooth during development
- Presence of supernumerary teeth
- Prolonged retention of deciduous teeth
- Retained deciduous root fragments
- Deficiency of arch length and excess of tooth material.

Maxillary canine often shows an abnormal eruptive pathway possibly due to following factors: (figure 2)

- It has to travel a long distance from its developmental position near the floor of the orbit to its final position in the oral cavity.
- The sequence of its eruption is after the eruption of one or both of the maxillary premolars.
- After premature loss of primary canines, the premolars may migrate mesially depriving the canine of its erupting space.

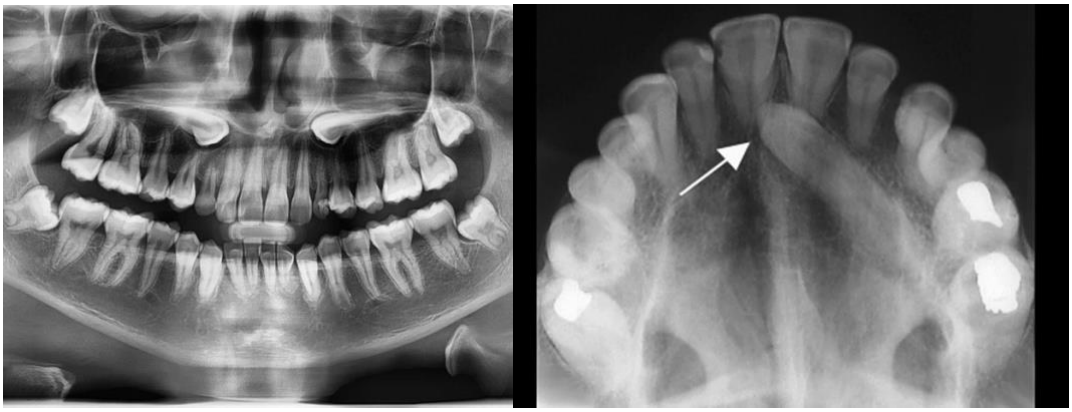

Figure 2 impacted canine

Abnormal eruptive path of one or more teeth can cause:

- Crowding in the arch
- Crossbite when more anteriors erupt palatally.

EXAM-ORIENTED QUESTIONS

Short Notes

1. How does ankylosis causes malocclusion?

2. How does dental caries causes malocclusion?

3. Prolonged retention of deciduous teeth.

4. How does premature loss of deciduous teeth causes malocclusion?

5. How does delayed eruption of permanent teeth causes malocclusion?

Best wishes.