Lecture.8

Thoracic cavity

Dr. Mustafa Fadhil
Ph.D. Anatomy & Histology

▪ Lungs

The lungs are situated so that one lies on each side of the mediastinum. They are therefore separated from each other by the heart and great vessels and other structures in the mediastinum.

Each lung has a blunt **apex,** which projects upward into the neck for about (2.5 cm) above the clavicle; a concave **base** that sits on the diaphragm; a convex **costal surface,**which corresponds to the concave chest wall; and a concave **mediastinal surface,** which is molded to the pericardium and other mediastinal structures.

At about the middle of this surface is the **hilum,** adepression in which the bronchi, vessels, and nerves thatform the **root** enter and leave the lung.

The **root of the lung** is formed of structures that are entering or leaving the lung. It is made up of the bronchi,pulmonary artery and veins, lymph vessels, bronchial vessels, and nerves.

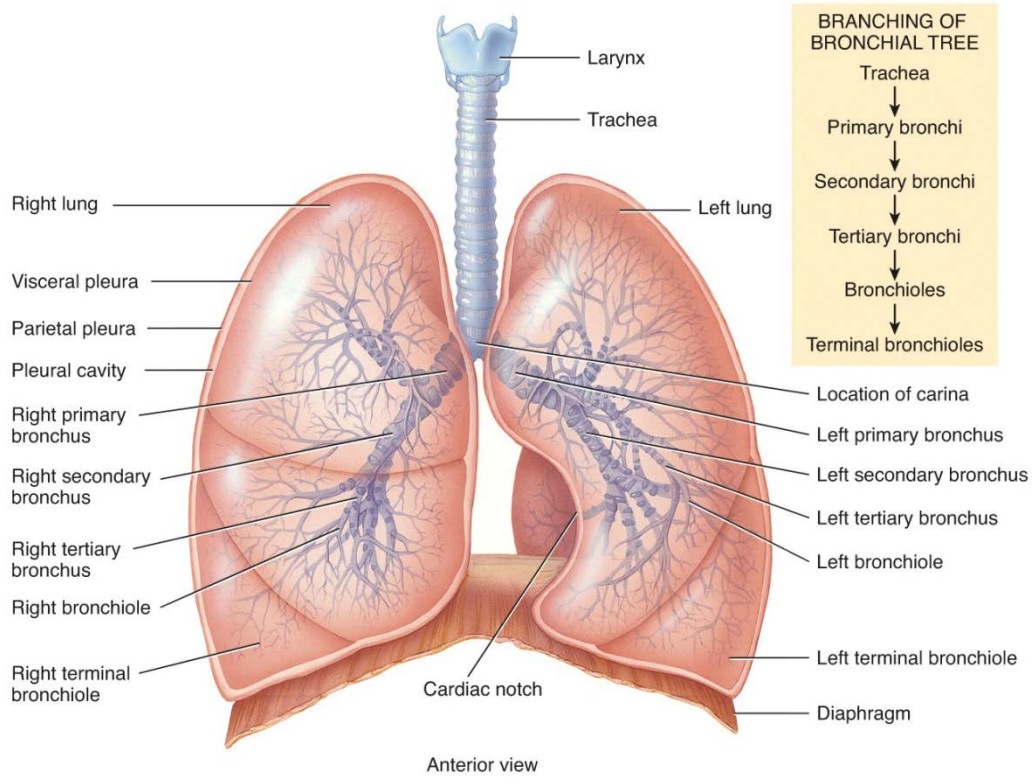

Lobes and Fissures

Right Lung

The right lung is slightly larger than the left and is dividedby the oblique and horizontal fissures into three lobes: the **upper, middle,** and **lower lobes**. The **obliquefissure** runs from the inferior border upward and backward.

Left Lung

The left lung is divided by a similar oblique fissure into two lobes: the **upper** and **lower lobes**. There is no horizontal fissure in the left lung.

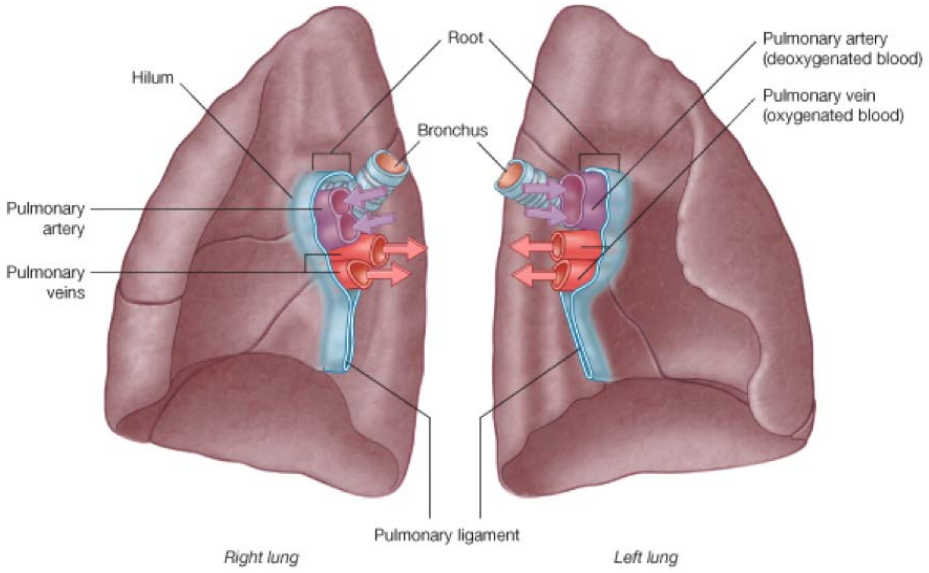

Bronchopulmonary Segments

The bronchopulmonary segments are the anatomic, functional,and surgical units of the lungs.The main characteristics of a bronchopulmonary segment may be summarized as follows:

■■It is a subdivision of a lung lobe.

■■It is pyramid shaped, with its apex toward the lung root.

■■It is surrounded by connective tissue.

■■It has a segmental bronchus, a segmental artery, lymphvessels, and autonomic nerves.

■■The segmental vein lies in the connective tissue between adjacent bronchopulmonary segments.

■■Because it is a structural unit, a diseased segment can beremoved surgically.

On entering a bronchopulmonary segment, each segmental bronchus divides repeatedly. The smallest bronchi divide and give rise to **bronchioles,** which are <1 mm in diameter. Bronchioles possess no cartilage in their walls.
The bronchioles then divide and give rise to **terminal bronchioles**, which show delicate out pouching from their walls, the **respiratory bronchiole,.** The diameter of a respiratory bronchiole is about 0.5 mm. The respiratory bronchioles end by branching into **alveolar ducts,** which lead into **alveolar sacs.** The alveolar sacs consist of several alveoli opening into a single chamber. Each alveolus is surrounded by a rich network of blood capillaries. Gaseous exchange takes place between the air in the alveolar lumen through the alveolar wall into the blood within the surrounding capillaries.

Blood Supply of the Lungs

The bronchi, the connective tissue of the lung, and the visceral pleura receive their blood supply from the **bronchial arteries**, which are branches of the descending aorta. The **bronchial veins** drain into the azygos and hemi azygos veins.

The alveoli receive deoxygenated blood from the terminal branches of the pulmonary arteries. The oxygenatedblood leaving the alveolar capillaries drains into the tributaries of the pulmonary veins, which follow the inter segmental connective tissue septa to the lung root. Two pulmonary veins leave each lung root to empty into the left atrium of the heart.

Nerve Supply of the Lungs

At the root of each lung is a **pulmonary plexus** composedof efferent and afferent autonomic nerve fibers. The plexusis formed from branches of the sympathetic trunk and receives parasympathetic fibers from the vagus nerve. The sympathetic efferent fibers produce bronchodilatationand vasoconstriction. The parasympathetic efferentfibers produce bronchoconstriction, vasodilatation, and increased glandular secretion.

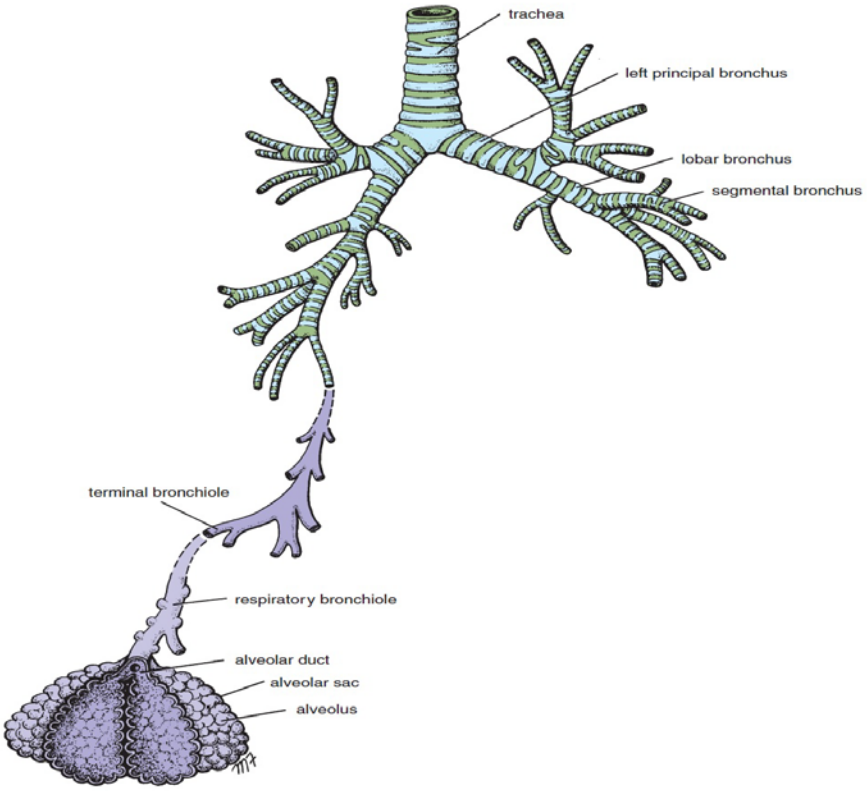

Trachea, bronchi, bronchioles, alveolar ducts, alveolar sacs, and alveoli. Note the path taken by inspired air from the trachea to the alveoli.

Pericardium

The pericardium is a fibro serous sac that encloses the heart and the roots of the great vessels. Its function is to restrict excessive movements of the heart as a whole and to serve as a lubricated container in which the different partsof the heart can contract. The pericardium lies within the middle mediastinum.

- **Fibrous Pericardium**

The fibrous pericardium is the strong fibrous part of the sac. It is firmly attached below to the central tendon of the diaphragm.

- **Serous Pericardium**

The serous pericardium lines the fibrous pericardium and coats the heart. It is divided into parietal and visceral layers.

The **parietal layer** lines the fibrous pericardium and is reflected around the roots of the great vessels to become continuous with the visceral layer of serous pericardium that closely covers the heart.

The **visceral layer** is closely applied to the heart and is often called the **epicardium.** The slit like space between the parietal and visceral layers is referred to as the **pericardial cavity**. Normally, the cavity contains a small amount of tissue fluid, the **pericardial fluid,** which acts as a lubricant to facilitate movements of the heart.

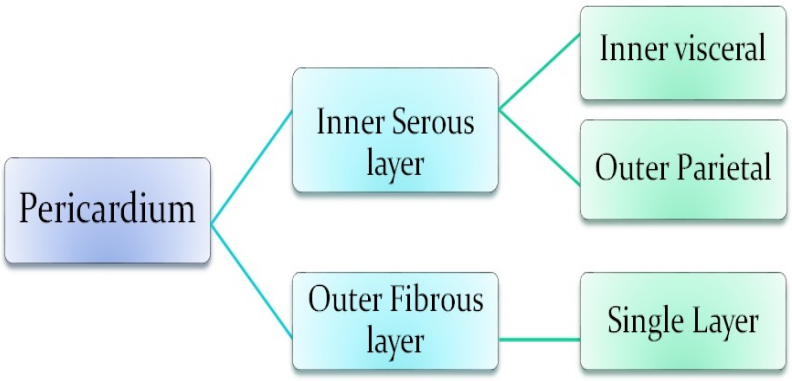

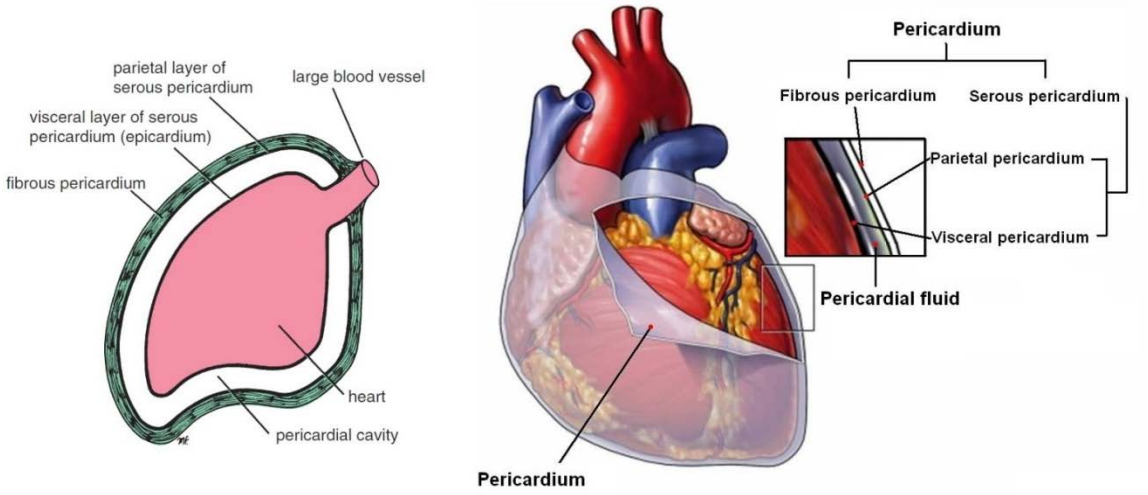

Heart

The heart is a hollow muscular organ that is some what pyramid shaped and lies within the pericardium in the mediastinum. It is connected at its base to the great blood vessels but otherwise lies free within the pericardium.

⇨ Surfaces of the Heart

The heart has three surfaces: sternocostal (anterior), diaphragmatic(inferior), and a base (posterior). It also has an apex.

Note that the base of the heart is called the **base** because the heart is pyramid shaped; the base lies opposite the apex.
The heart does not rest on its base; it rests on its diaphragmatic (inferior) surface.
On the interior, it is divided into four chambers. These divisions create grooves on the surface of the heart – these are known as sulci.
The **coronary sulcus** (or atrio ventricular groove) runs transversely around the heart – it represents the wall dividing the atria from the ventricles. The sinus contains important vasculature, such as the right coronary artery.
The **anterior** and **posterior inter ventricular** sulci can be found running vertically on their respective sides of the heart. They represent the wall separating the ventricles.

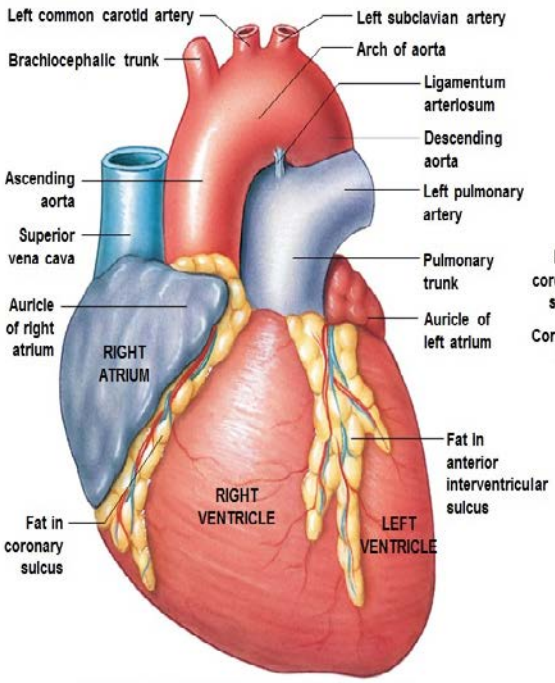

Anterior view of the heart and great vessels

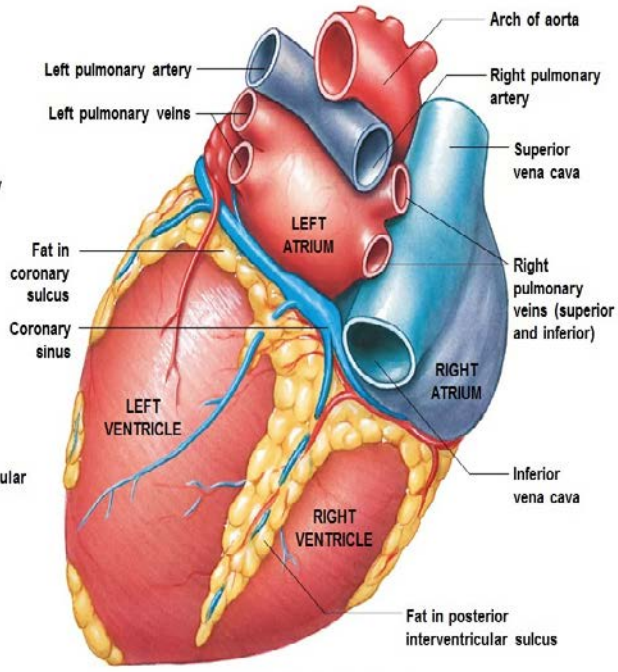

Posterior view of the heart and great vessels

⇨ Chambers of the Heart

The heart is divided by vertical septa into four chambers:The right atrium lies anterior to the left atrium, and the right ventricle lies anterior to the left ventricle.
The right side of the heart is composed of the right atrium and right ventricle. These chambers receive blood from the systemic circulation and pump it to the pulmonary circulation for gas exchange.The left atrium and left ventricle receive blood from the pulmonary circulation and pump it to the systemic circulation.

❖ Right Atrium

The right atrium consists of a main cavity and a small outpouching, the auricle. On the outside of the heart at the junction between the right atrium and the right auricle is a vertical groove, the **sulcus terminalis.**

Openings into the Right Atrium

1. The **superior vena cava** opens into the upper part of the right atrium; it has no valve. It returns the blood to the heart from the upper half of the body.
2. The **inferiorvena cava** (larger than the superior vena cava) opens into the lower part of the right atrium; it is guarded by a rudimentary, non functioning valve. It returns the blood to the heart from the lower half of the body.
3. The **coronary sinus,** which drains most of the blood from the heart wall. It is guarded by a rudimentary, nonfunctioning valve.
4. The **right atrioventricular orifice** is guarded by the tricuspidvalve.

Many small orifices of small veins also drain the wall of the heart and open directly into the right atrium.

❖ Right Ventricle

The right ventricle communicates with the right atrium through the **atrioventricular orifice** and with the **pulmonary trunk** through the pulmonary orifice.

The walls of the right ventricle are much thicker than those of the right atrium.

The **tricuspid valve** guards the atrioventricular orifice and consists of three cusps.

The **pulmonary valve** guards the pulmonary orifice and consists of three semilunar cusps.

❖ Left Atrium

Similar to the right atrium, the left atrium consists of amain cavity and a left auricle. The left atrium is situated behind the right atrium and forms the greater part of the base or the posterior surface of the heart.

Openings into the Left Atrium

1. The **four pulmonary veins**, two from each lung, open through the posterior wall and have no valves.
2. The **left atrio ventricular orifice** is guarded by the mitral valve.

❖ Left Ventricle

The left ventricle communicates with the left atrium through the **atrioventricular orifice** and with the aorta through the **aortic orifice**. The walls of the left ventricleare three times thicker than those of the right ventricle. (The left intra ventricular blood pressure is six times higher than that inside the right ventricle.)

The **mitral valve** guards the atrioventricular orifice. It consists of two cusps

The **aortic valve** guards the aortic orifice with three cusps.
Behind each cusp, the aortic wall bulges to form an **aortic sinus.** The aortic sinuses gives origin to the right and left coronary arteries

Structure of the Heart

The walls of the heart are composed of a thick layer of cardiacmuscle, the **myocardium**, covered externally with serous pericardium the **epicardium** and lined internally with a layer of endothelium, the **endocardium.**
The atrial portion of the heart has relatively thin walls and is divided by the **atrial (inter atrial) septum** into the right and left atria. The ventricular portion of the heart has thick walls and is divided by the **ventricular (inter ventricular) septum** into the right and left ventricles.

Conducting System of the Heart

The normal heart contracts rhythmically at about 70 to 90 beats per minute in the resting adult. The rhythmic contractile process originates spontaneously in the conducting system and the impulse travels to different regions of the heart, so the atria contract first and together, to be followed later by the contractions of both ventricles together. The slight delay in the passage of the impulse from the atria to the ventricles allows time for the atria to empty their blood into the ventricles before the ventricles contract.

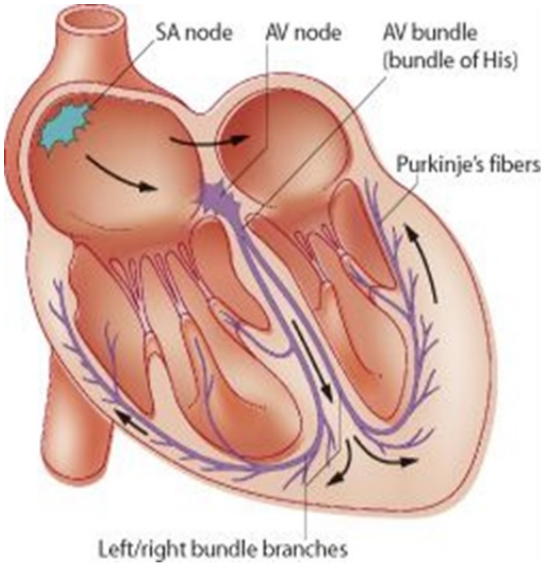

The conducting system of the heart consists of specialized cardiac muscle present in the **sinuatrial node,** the **atrio-ventricular node,** the **atrio-ventricular bundle** and its right and left terminal branches, and the subendocardial plexus of **Purkinje fibers** (specialized cardiac muscle fibers that form the conducting system of the heart).

Sinuatrial Node

The sinuatrial node is located in the wall of the right atriumin the upper part of the sulcus terminalis just to the right of the opening of the superior vena cava.

The node spontaneously gives origin to rhythmic electrical impulses that spread in all directions through the cardiac muscle of the atria and cause the muscle to contract.

Atrioventricular Node

The atrioventricular node is strategically placed on the lower part of the atrial septum just above the attachment of the septal cusp of the tricuspid valve.

From it, the cardiac impulse is conducted to the ventricles by the atrioventricular bundle. The atrioventricular node is stimulated by the excitation wave as it passes through the atrial myocardium.

Atrioventricular Bundle

The atrioventricular bundle (bundle of His) is the only pathway of cardiac muscle that connects the myocardium of the atria and the myocardium of the ventricles and is thus the only route along which the cardiac impulse can travel from the atria to the ventricles.

The atrioventricular bundle then descends to reach the ventricular septum.

At the upper border of the septum,it divides into two branches, one for each ventricle. The **right bundle branch (RBB)** passes down on the right side of the ventricular septum then it becomes continuous with the fibers of the Purkinje plexus. The **left bundle branch (LBB)** passes down on its left side which become continuous with the fibers of the Purkinje plexus of the left ventricle.

⇨ The Arterial Supply of the Heart

The arterial supply of the heart is provided by the **right and left coronary arteries**.

Venous Drainage of the Heart

Most blood from the heart wall drains into the right atrium through the **coronary sinus.** The remainder of the blood is returned to the right atrium by **cardiac veins**

⇨ Nerve Supply of the Heart

The heart is innervated by sympathetic and parasympathetic fibers of the autonomic nervous system via the **cardiac plexuses**. The sympathetic supply arises from the cervical and upper thoracic portions of the sympathetic trunks, and the parasympathetic supply comes from the vagus nerves.

Activation of sympathetic nerves results increase the heart rate, increased force of contraction of the cardiac muscle, and dilatation of the coronary arteries.

Activation of the parasympathetic nerves results in a reduction in the rate and force of contraction of the heart and a constriction of the coronary arteries.

Large Veins of the Thorax

1) Brachiocephalic Veins

- The **right brachiocephalic vein** is formed at the root of the neck by the union of the right subclavian and the right internal jugular veins.
- The **left brachiocephalicvein** has a similar originas it formed at the root of the neck by the union of the left subclavian and the left internal jugular veins.

2) Superior Vena Cava

The superior vena cava contains all the venous blood from the head and neck and both upper limbs and is formed by the union of the two brachiocephalic veins. It passes downward to end in the right atrium of the heart. The vena azygos joins the posterior aspect of the superior vena cava just before it enters the pericardium.

3) Azygos Veins

The azygos veins consist of the main azygos vein, the inferior hemiazygos vein, and the superior hemiazygos vein.

4) Inferior Vena Cava

The inferior vena cava pierces the central tendon of the diaphragm opposite the eighth thoracic vertebra and almost immediately enters the lowest part of the right atrium.

5) Pulmonary Veins

Two pulmonary veins leave each lung carrying oxygenated blood to the left atrium of the heart.

Large Arteries of the Thorax

➔ Aorta

The aorta is the main arterial trunk that delivers oxygenated blood from the left ventricle of the heart to the tissues of the body. It is divided for purposes of description into the following parts: ascending aorta, arch of the aorta,descending thoracic aorta, and abdominal aorta.

- **Ascending Aorta**

The ascending aorta begins at the base of the left ventricle and runs upward and forward to becomes continuous with the arch of the aorta. At its root, it possesses three bulges, the **sinuses of the aorta.**

Branches

The **right coronary artery** and **left coronary artery**

- **Arch of the Aorta**

The arch of the aorta is a continuation of the ascending aorta. It arches upward, backward, and to the left to become continuous with the descending aorta.

Branches

- The **brachiocephalic artery** divides into the right subclavian and right common carotid arteries.
- The **left common carotid artery.**
- The **left subclavian.**

Descending Thoracic Aorta

The descending thoracic aorta lies in the posterior mediastinumand begins as a continuation of the arch of the aorta it passes behind the diaphragm (through the aortic opening) continuous with the abdominal aorta.

➔ Pulmonary Trunk

The pulmonary trunk conveys deoxygenated blood fromthe right ventricle of the heart to the lungs. It leaves the right ventricle. It terminates by dividing into right and left pulmonary arteries.

Branches

- The **right pulmonary artery** runs the right lung.
- The **left pulmonary artery** runs to the left lung.