Orthognathic Surgery

Dr.Raad Salah Shyaa

Definition

- The simplest definition of orthognathic surgery is the alignment of the jaws to normalize the relationship between the jaws themselves and the rest of the craniofacial complex.

Causes of dentofacial deformities

- The general direction of normal growth of the face is downward and forward with lateral expansion. The maxilla and the mandible grow by remodeling or differential apposition and resorption of bone, producing changes in three dimensions.

Causes of dentofacial deformities

- Inherited tendencies; such as a familial tendency toward a prognathic or deficient mandible.

- Prenatal problems; such as intrauterine molding of the developing fetal head may result in a severe mandibular deficiency.

- Systemic conditions that occur during growth; such as fetal alcohol syndrome, which may result in hypoplasia of midface structures.

- Trauma; such as trauma to the temporomandibular joint in a growing child may result in alteration of growth causing deficient or asymmetric mandibular growth.

- Environmental influences; such as abnormal function after birth including abnormal tongue position and size, respiratory difficulty, mouth breathing, and abnormal lip postures.

Treatment objectives

- 1. Obtain functional occlusion with teeth in the most ideal position.
- 2. Correct underlying skeletal disharmony.
- 3. Obtain maximum esthetic results
- 4. Skeletal stability.

Evaluation of patients with dentofacial deformities

- General assessment

- Facial assessment
- The frontal view

❖Vertical and transverse proportions.

❖Canting of the maxillary occlusal plane.

❖Ear shape and position.


Vertical Fifths

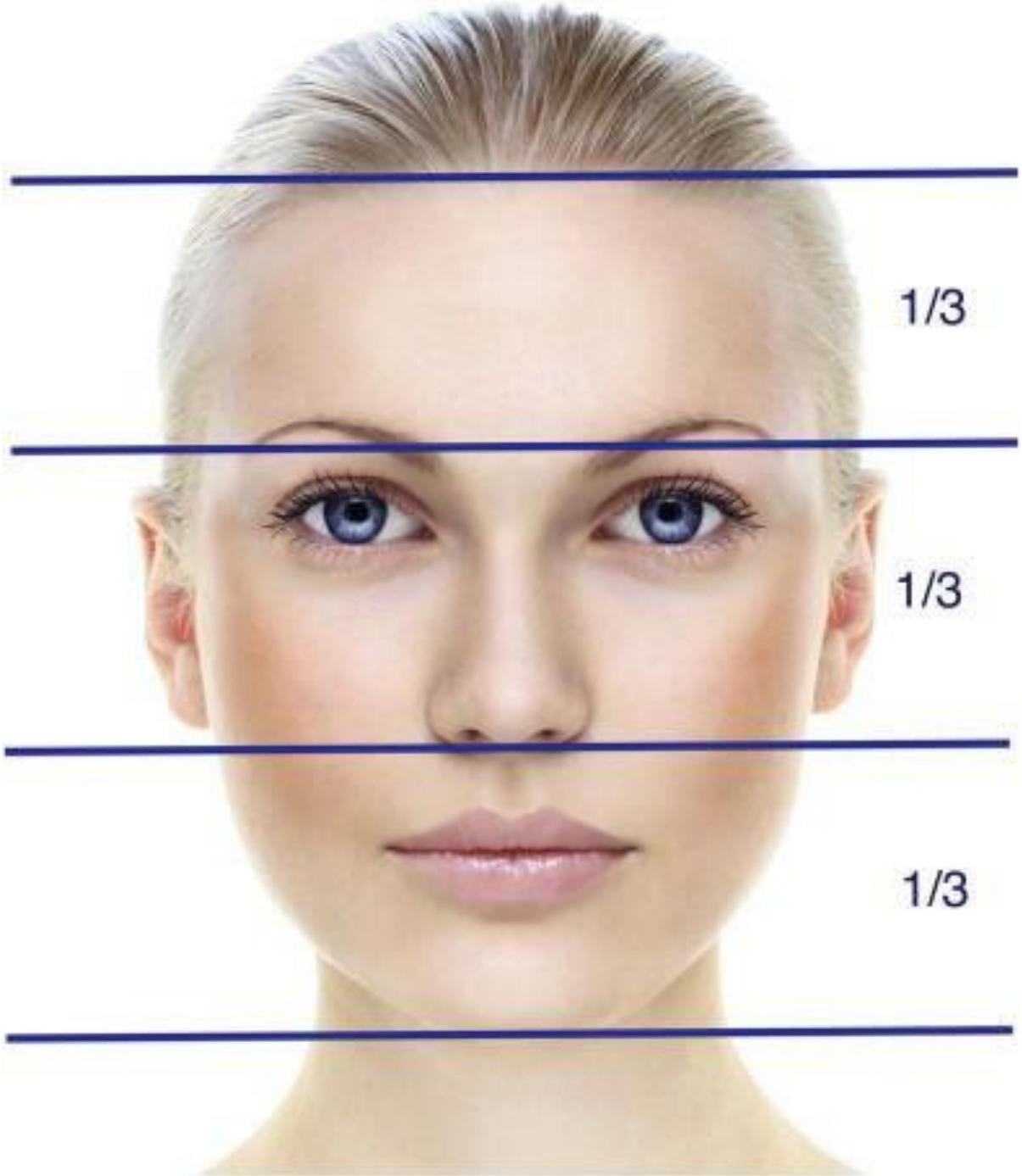
1/3
1/3
1/3

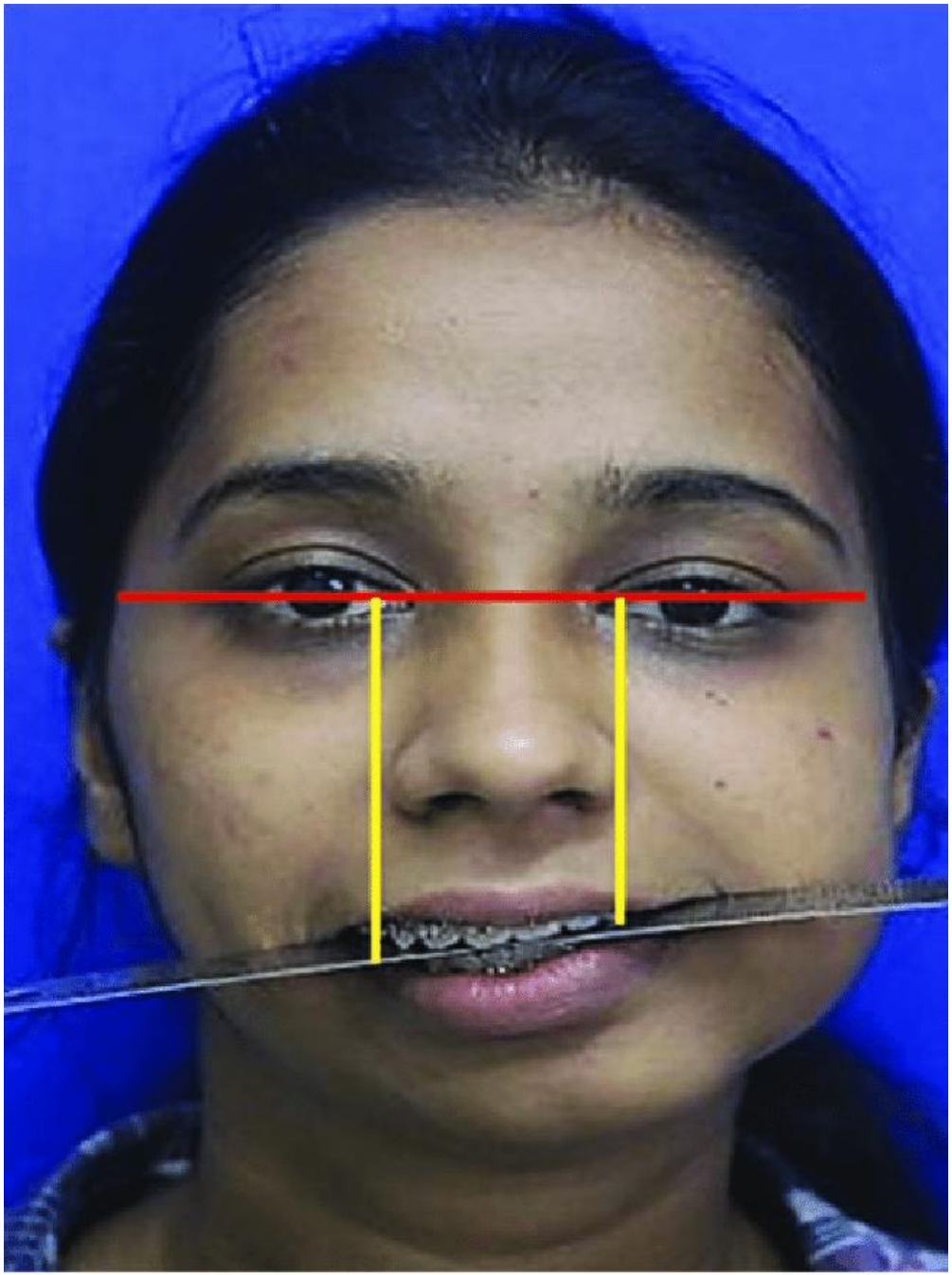

©Association of Oral and Maxillofacial Surgeons of India

- Scleral show and eyelid position.
- Upper incisor show.
- Lip form and symmetry.

The profile evaluation

- allows an assessment of the anteroposterior and vertical relationships of all components of the face including Jaw relationship and facial convexity, forehead, infraorbital rims, nose, paranasal regions, upper lip, lower lip and chin, lower lip to submental plane angle, and mandibular plane angle.

Intraoral assessment

- Assessment of dental arch form.
- Dental problems.
- Periodontal status.
- Tongue assessment.

- The muscles of mastication and TMJ function should also be evaluated.
- Impressions and a bite registration for dental cast construction and evaluation

Radiographic evaluation

- Panoramic and lateral cephalometric radiographs are routinely used in patient evaluation and are an important part of the initial assessment.

- Currently, cone-beam computerized tomography (CBCT) has become the state of the art for most radiographic examinations of facial bones to plan orthognathic surgery.

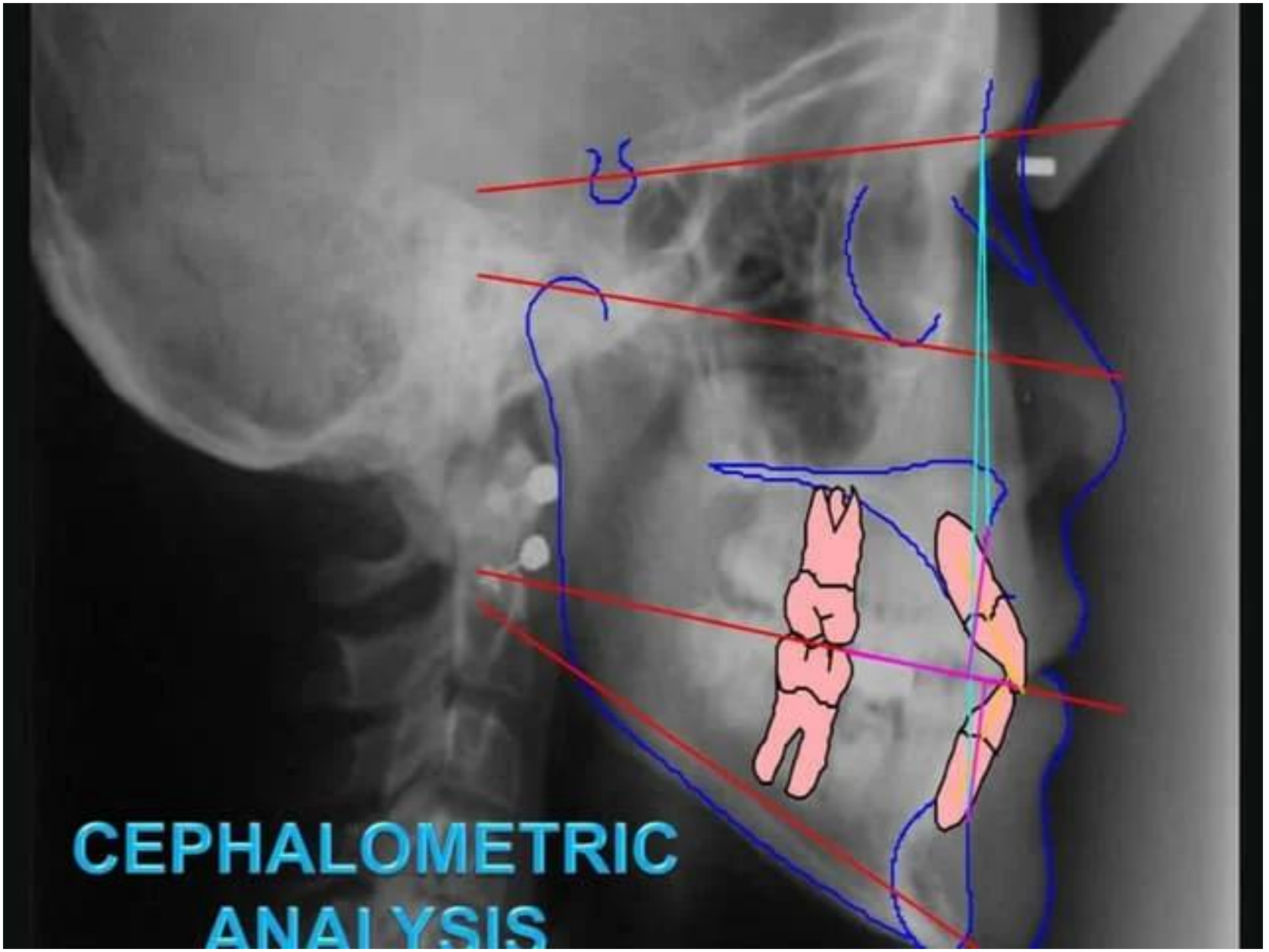
CEPHALOMETRIC
ANALYSIS

Skeletal classification

- Class I skeletal: The maxillary base is in a normal anteroposterior relationship to the mandibular base.

- Class II skeletal: The mandibular base is posterior to the maxillary base because of maxillary prognathism, mandibular retrognathism, or both.

- Class III skeletal: The mandibular base is anterior to the maxillary base because of maxillary retrognathism, mandibular prognathism, or both.

Pre-surgical treatment phase

- Periodontal considerations.
- Restorative considerations.
- Orthodontic considerations:

❖Decompensation of dentition

❖Alignment of arches

❖Coordinate arches

❖Leveling of arches.

Treatment Timing

- During growth
- After growth cessation; considered as definitive surgery.

Treatment planning

- 1. Determine the final post-surgical dental occlusion.
- 2. Demonstrate the post-surgical soft tissue facial appearance.
- 3. Determine the magnitude of skeletal hard tissue movement necessary at the time of surgery.

Objectives can be met by the following methods:

- Model planning
- Two-dimensional (2D) soft tissue profile prediction planning.
- Three-dimensional (3D) computerized surgical planning.

Surgical treatment phase

- Mandibular excess.
- The bilateral sagittal split osteotomy (BSSO)

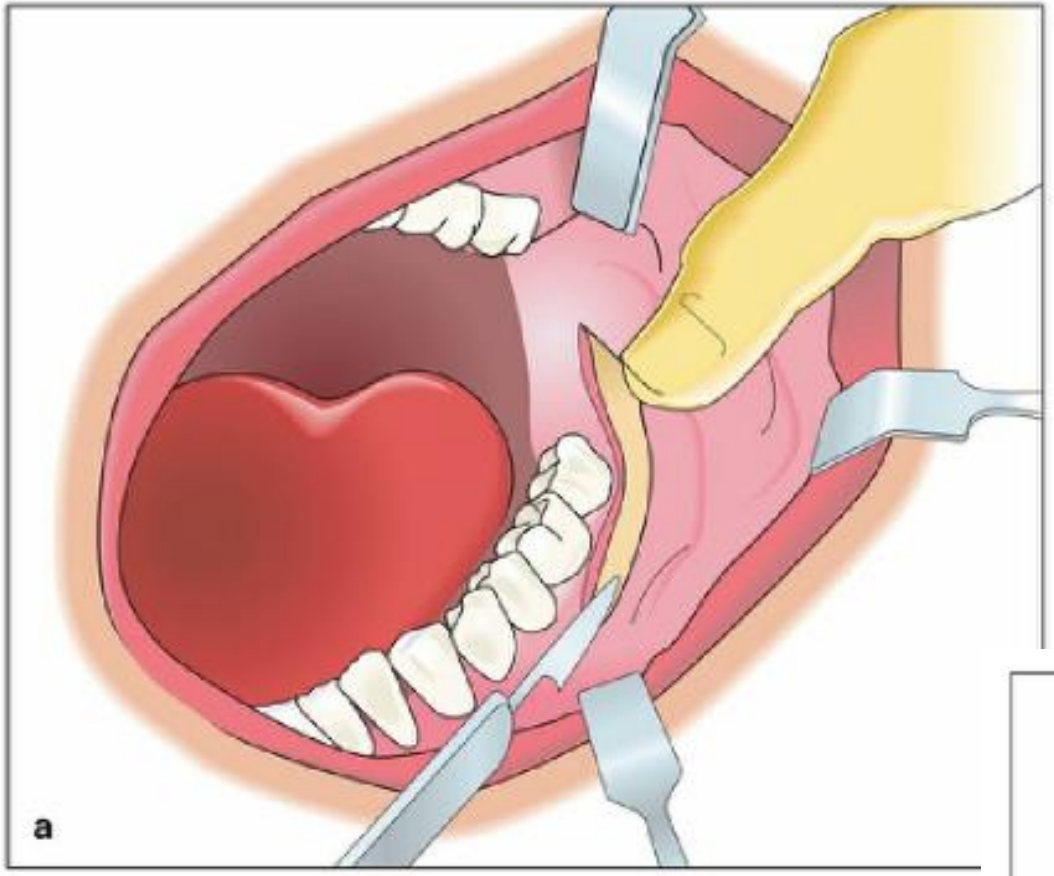
a

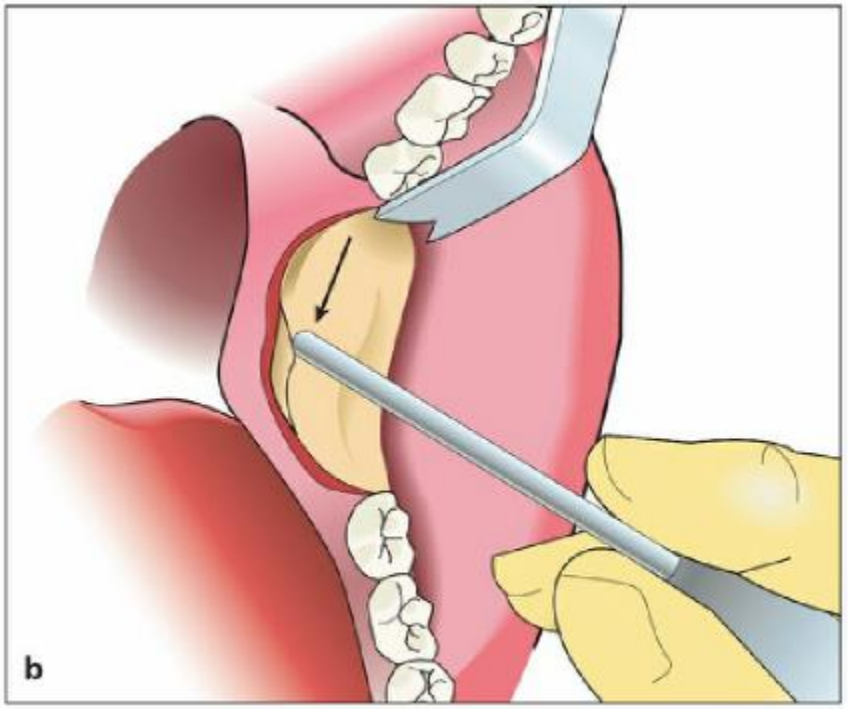
b

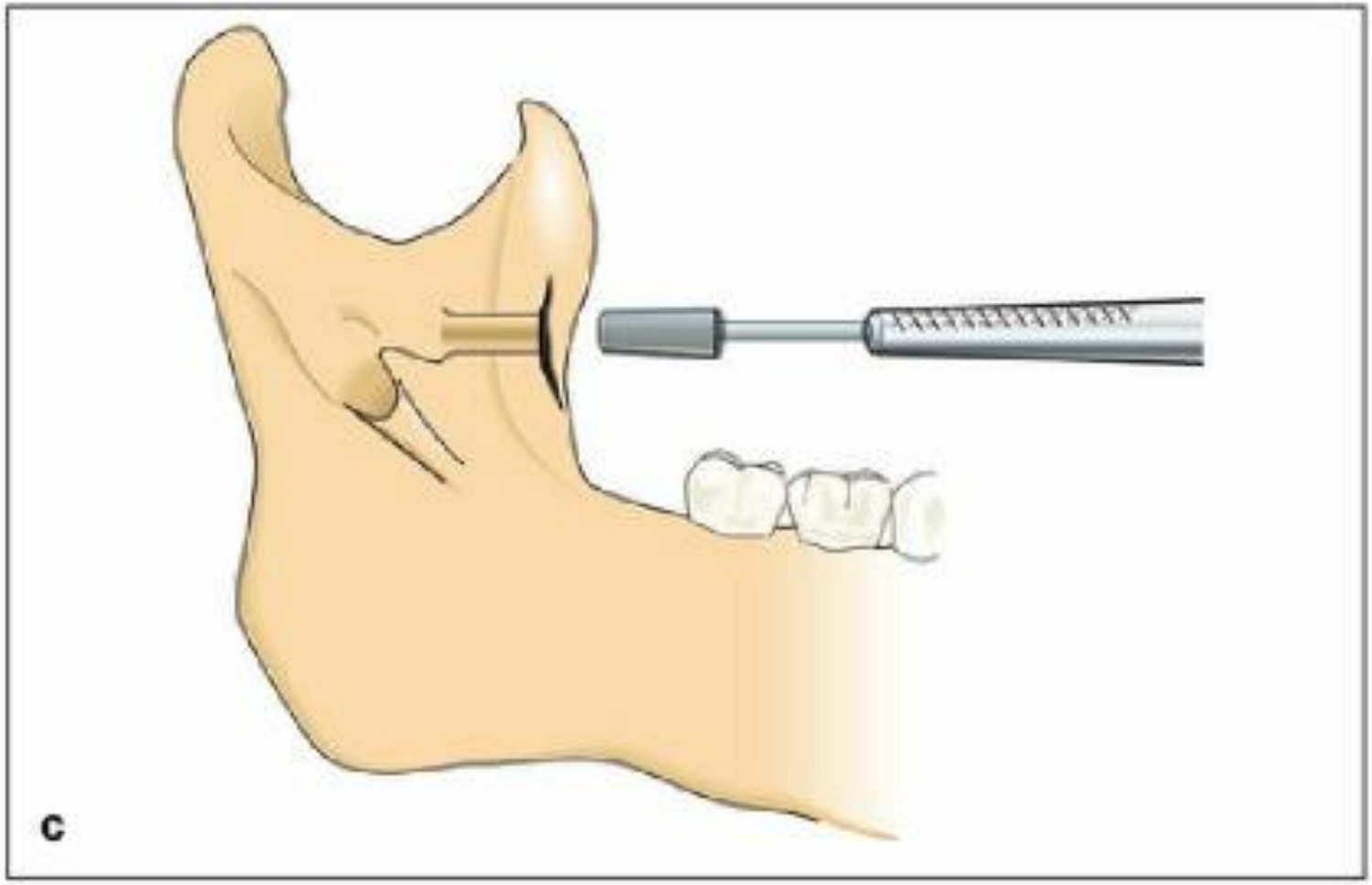
c

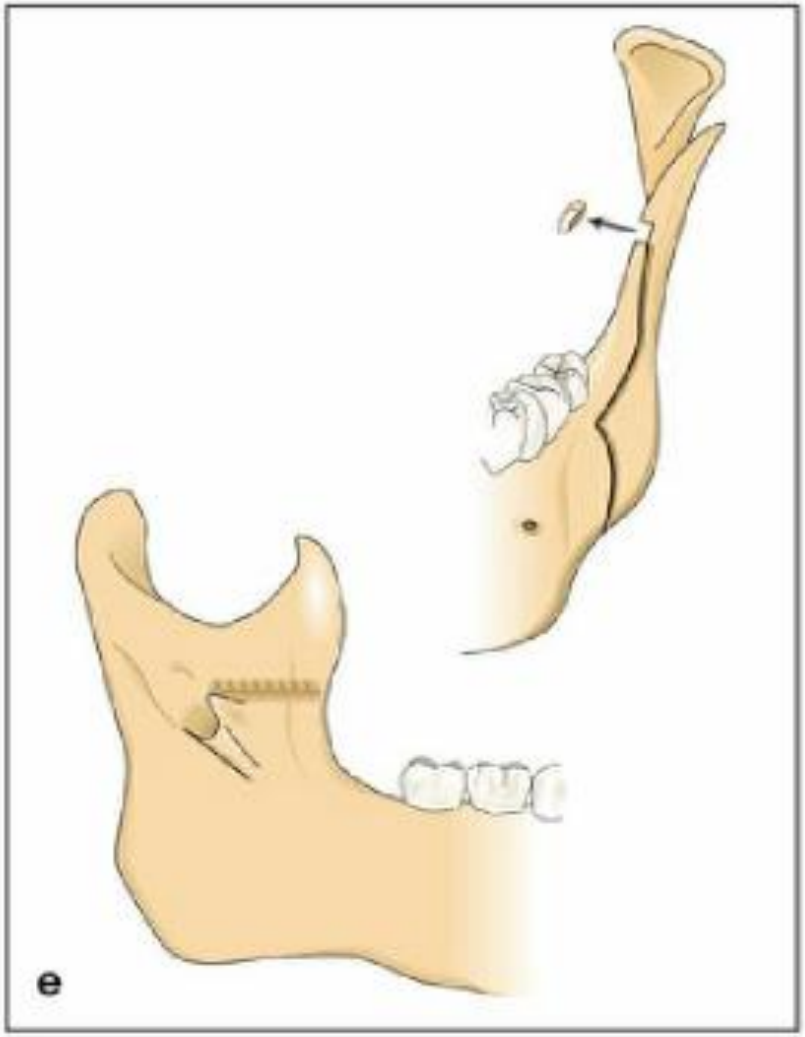
e

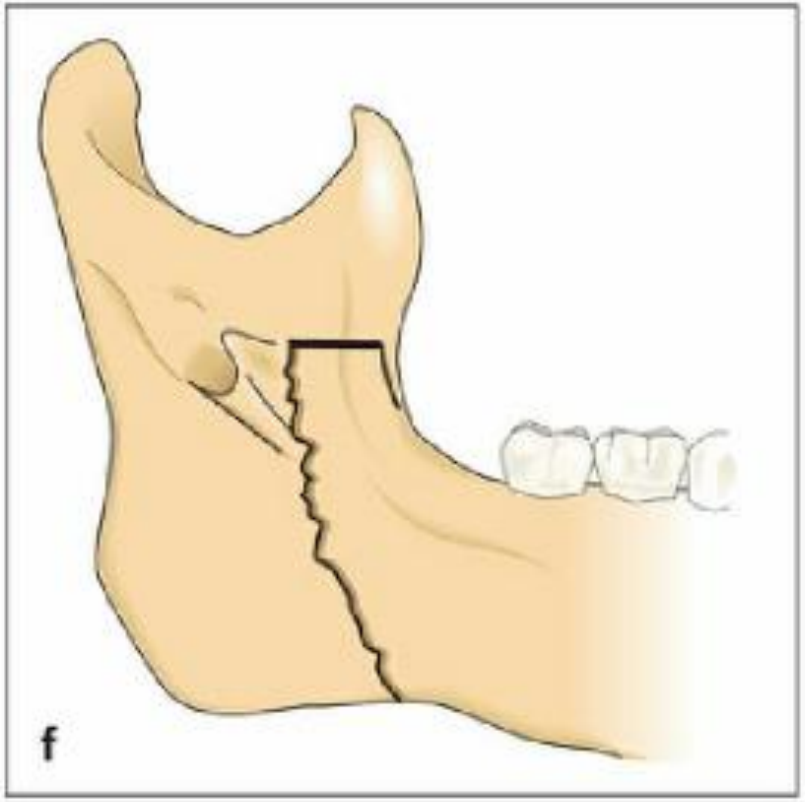
f

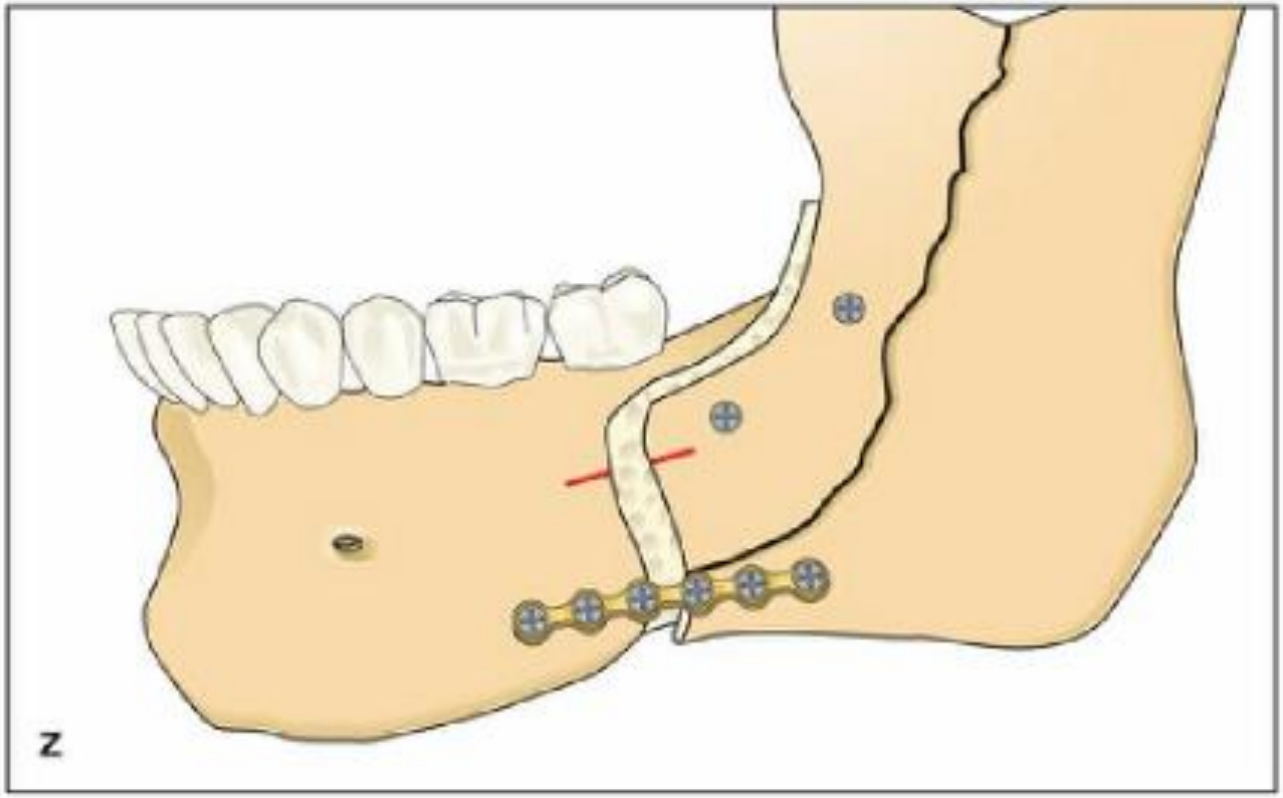
z

Complications

- Damage to the inferior alveolar nerve.
- Unfavorable split of the mandible (bad split).
- Pain, swelling, and limitation of mouth opening.
- Hematoma and infection.
- Immediate or delayed skeletal relapse.
- Worsening of preoperative TMJ symptoms.

Vertical ramus osteotomy

- Mandibular deficiency.
- Currently, the BSSO with mandibular advancement is the most popular technique for the correction of mandibular retrognathism.

- When a proper occlusal relationship exists or when anterior positioning of the mandible would not be sufficient to produce an adequate projection of the chin, a genioplasty with advancement may also be performed.

- Alloplastic materials can occasionally be used to augment chin projection; the material is onlayed in areas of bone deficiencies.

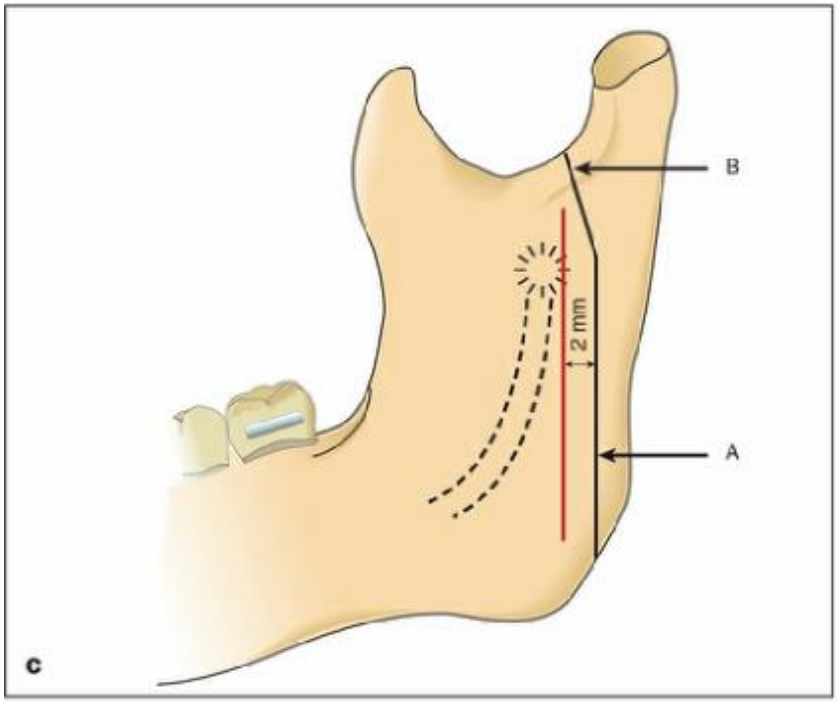
B
2 mm
A
c

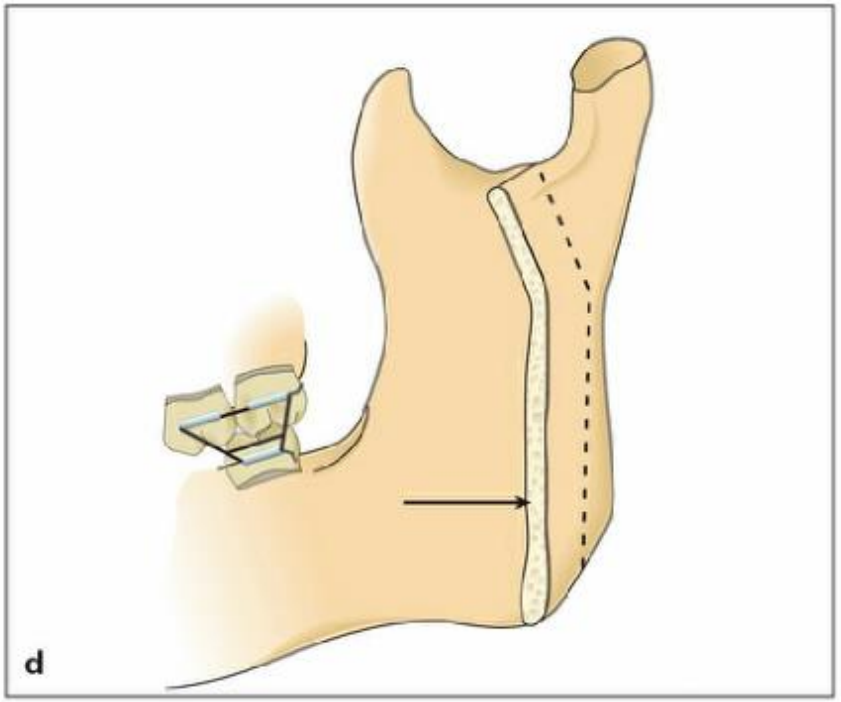
d

Maxillary excess

- Excessive growth of the maxilla may occur in the anteroposterior, vertical, or transverse dimensions.

- Vertical maxillary excess may result in associated facial characteristics, including elongation of the lower third of the face; a narrow nose, particularly in the area of the alar base; excessive incisive and gingival exposure; and lip incompetence.

Maxillary and midface deficiency

- Maxillary deficiency may occur in the anteroposterior, vertical, and transverse planes. The patient's clinical appearance depends on the location and severity of the deformity.

- In addition to the abnormal facial features, a class III malocclusion with reverse anterior overjet is frequently seen.

Le Fort I osteotomy

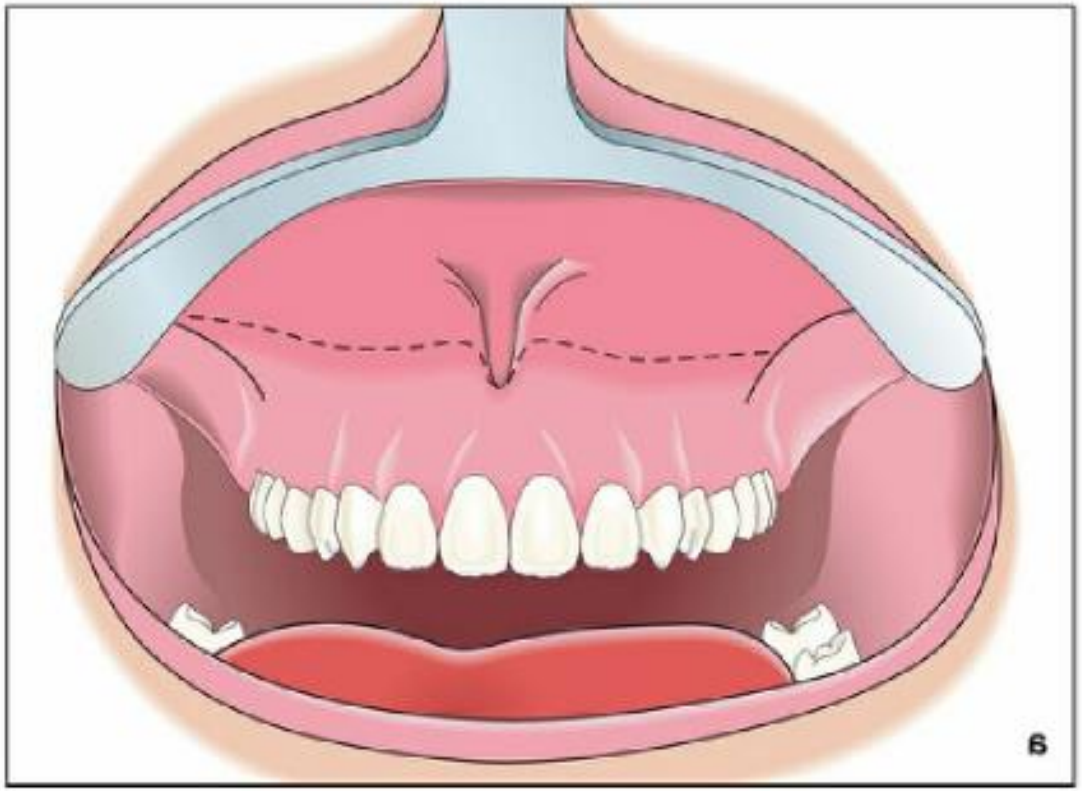

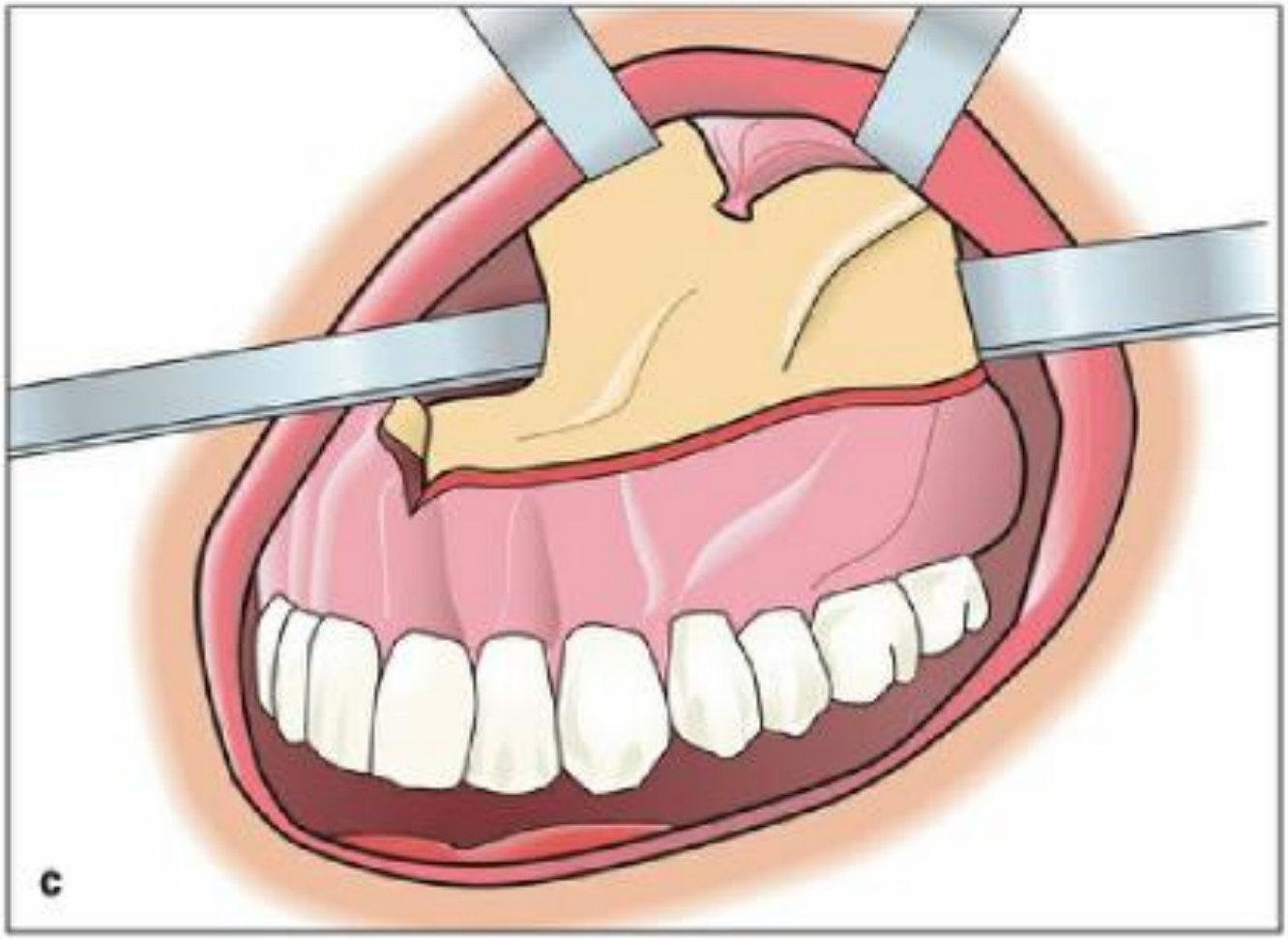
c

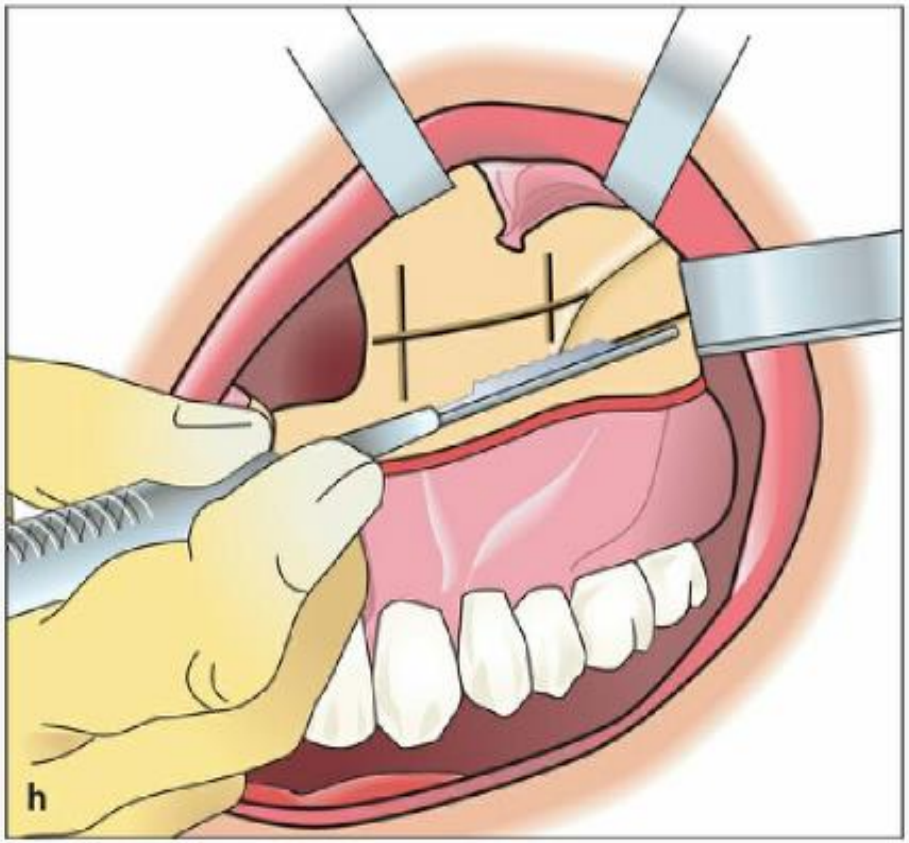
h

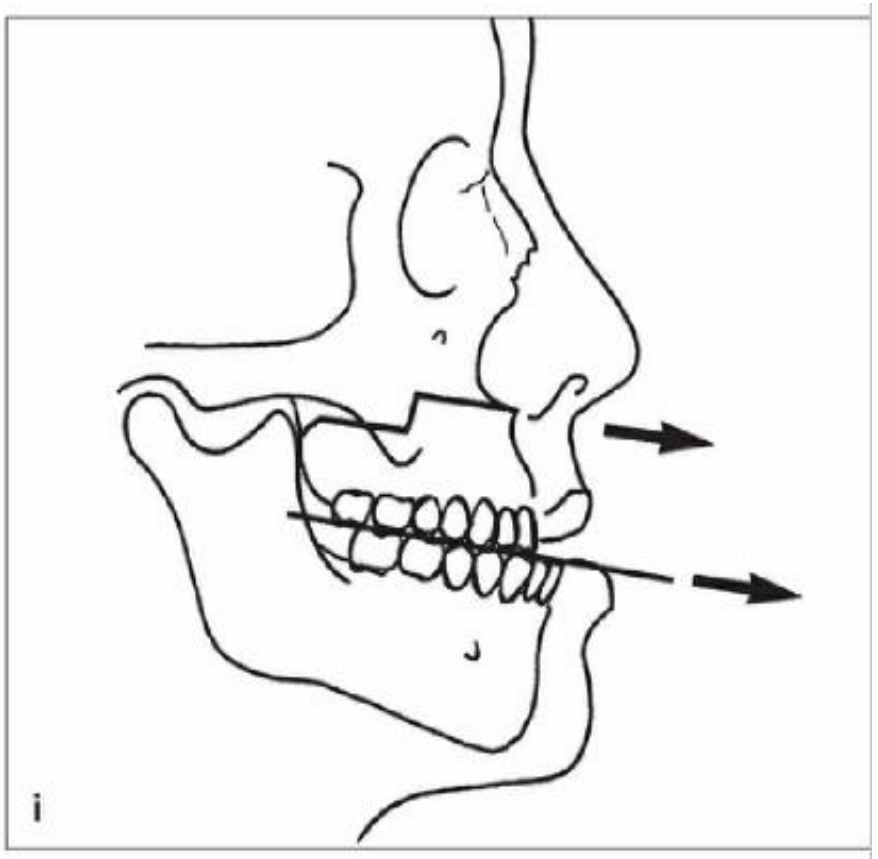
i

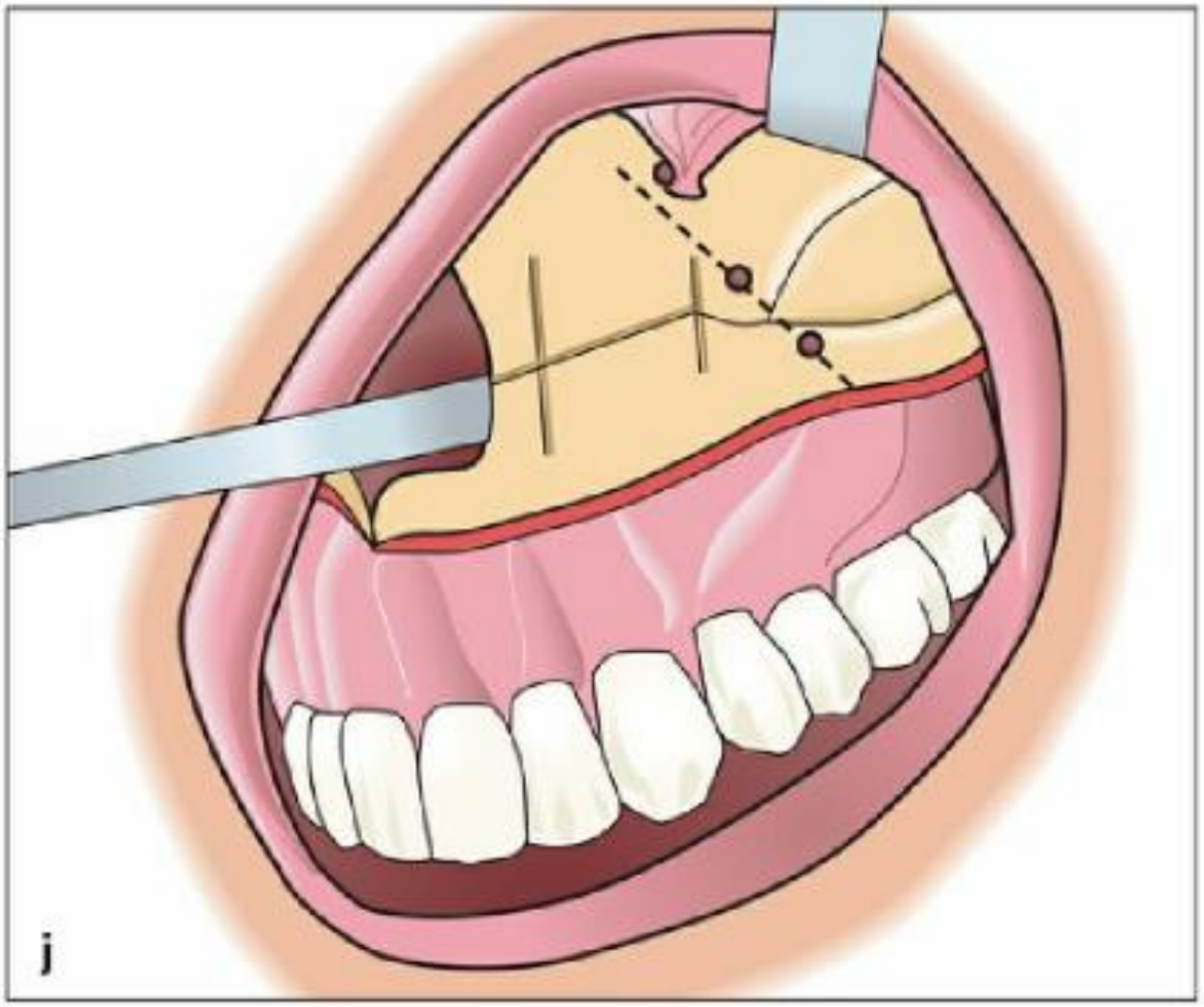
j

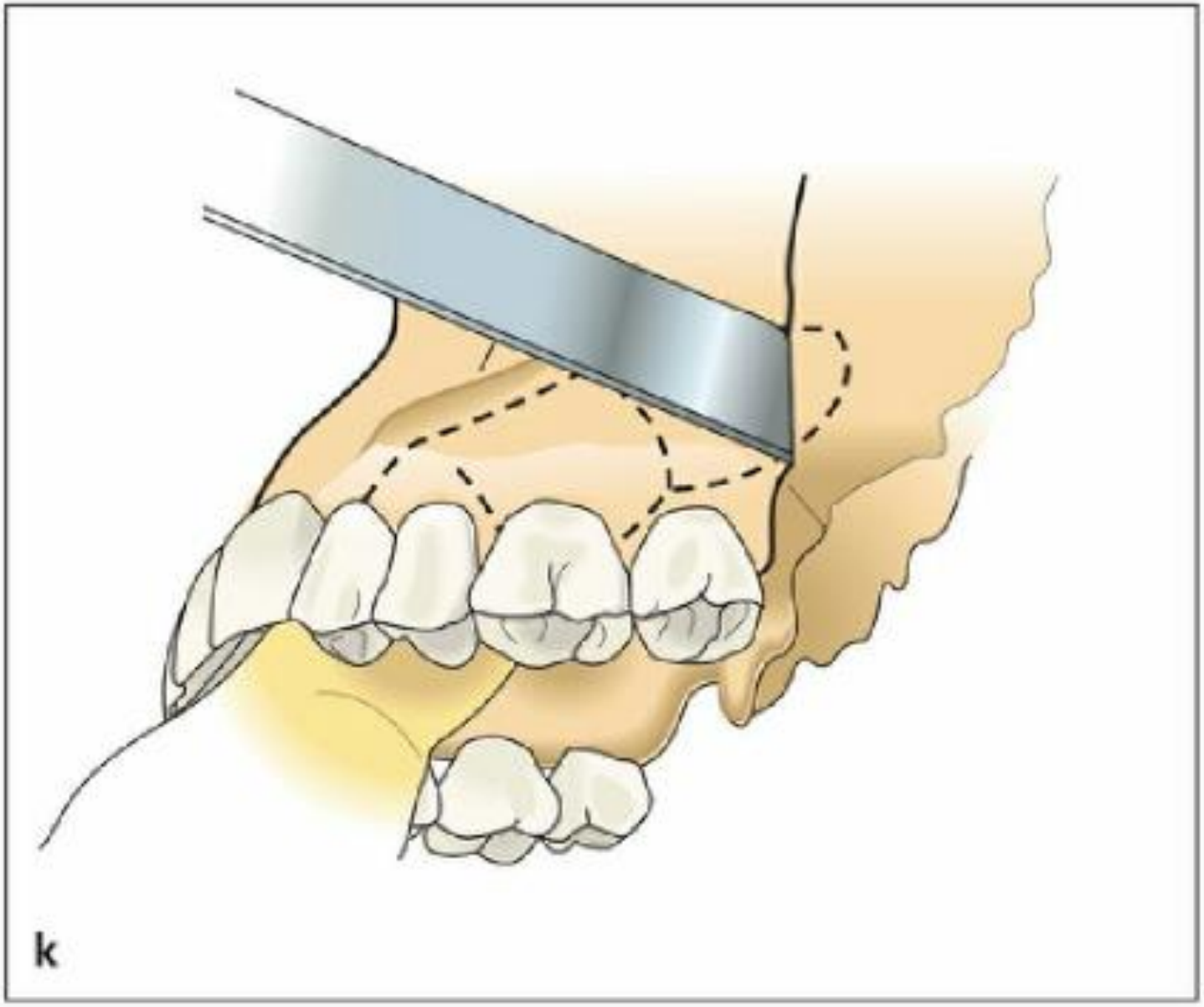
k


o

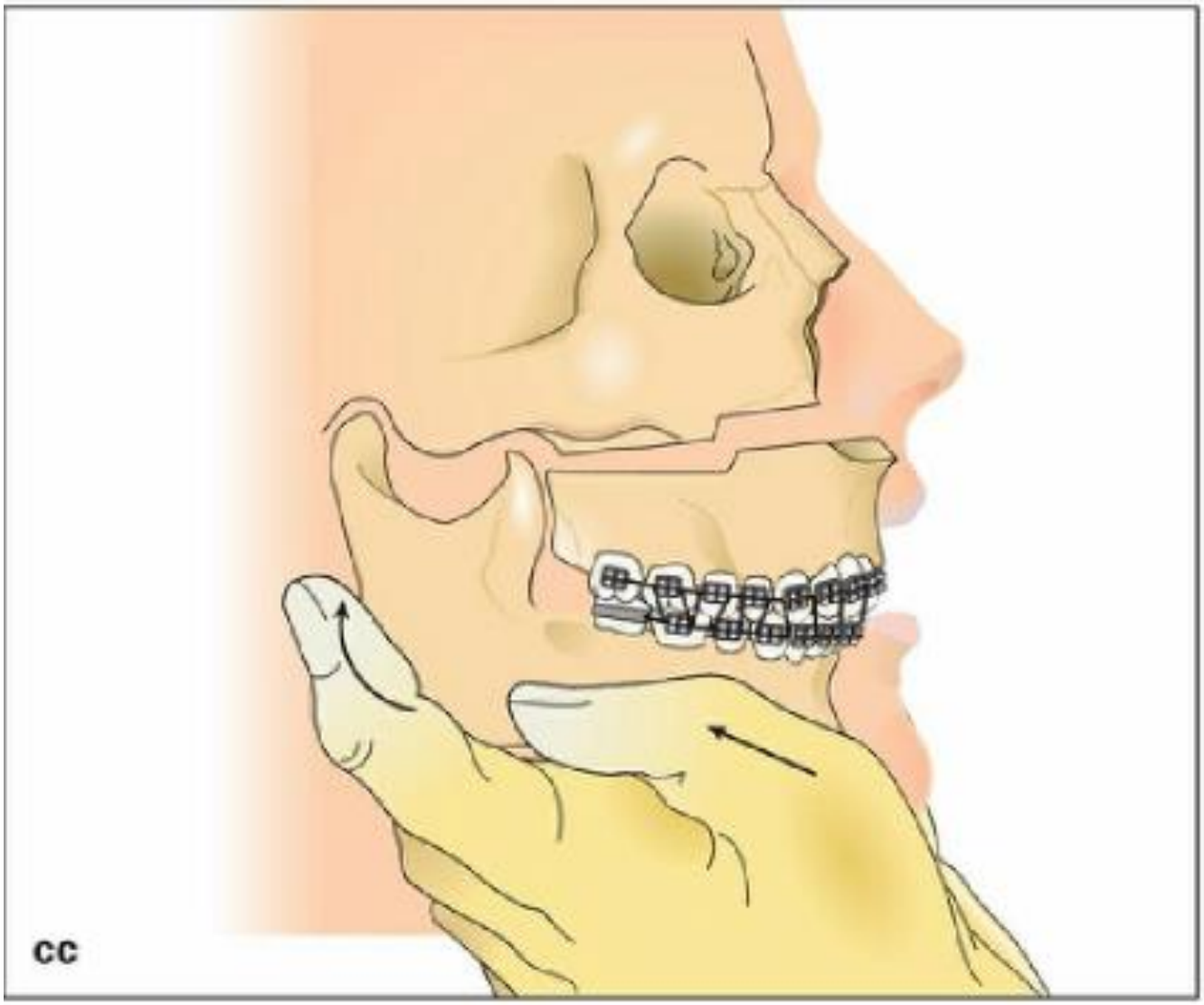
cc





inspire INSTRUMENTS

Complications

- Infraorbital nerve injury resulting in temporary paresthesia.
- Bleeding.
- Fibrous union.
- Acute and chronic maxillary sinusitis.
- Nasal obstruction.

- Other rare complications such as ischemic necrosis of the maxilla, ocular complications, and nasolacrimal apparatus dysfunction.

- Combination deformities and asymmetries.

- (Bimaxillary orthognathic surgery) to achieve the best possible occlusal, functional, and aesthetic results. The most common combination of maxillary and mandibular osteotomies performed is Le Fort I osteotomy and BSSO.

Postsurgical treatment phase

- 1. Final tooth alignment and root parallelism.
  2. Maximal interdigitation.
- 3. Ideal overbite and overjet.
- 4. Centric occlusion .

Advances in orthognathic surgery

- Diagnosis and treatment planning.
- Materials development.
- Patient management.

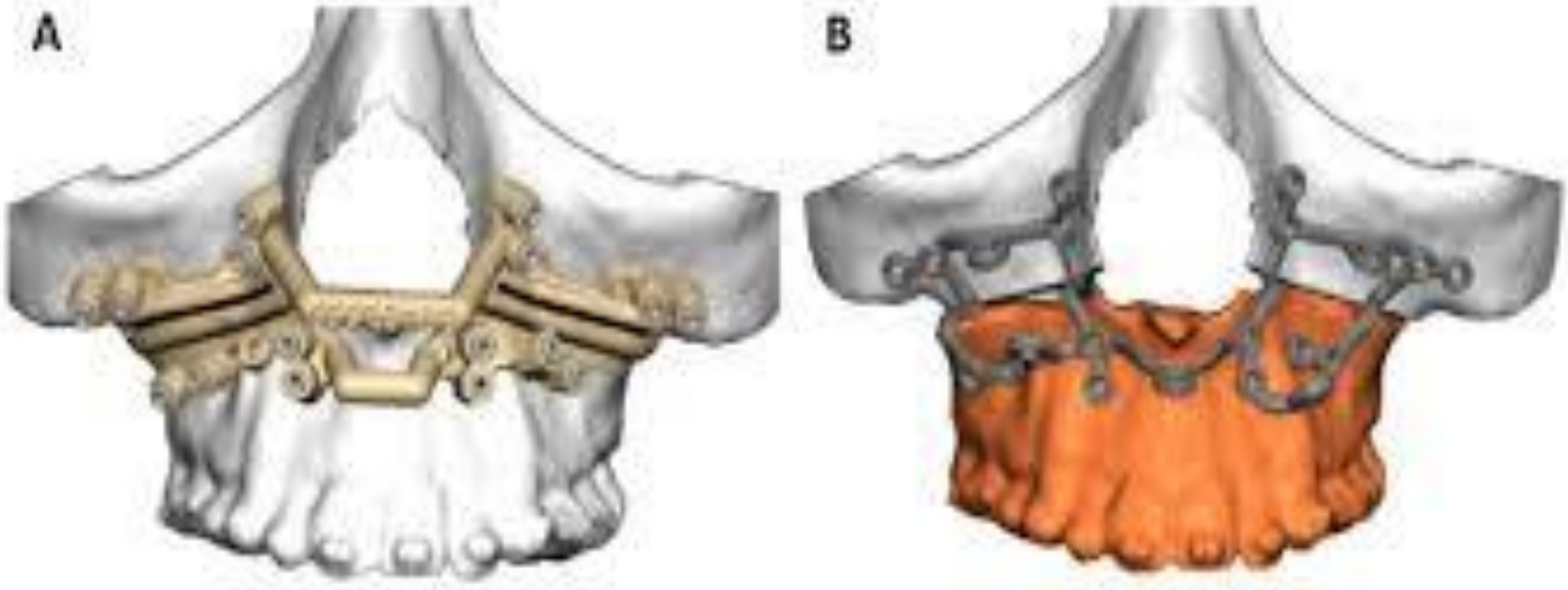
A
B

PSI and 3D printing





Distraction osteogenesis

- involves cutting an osteotomy to separate segments of the bone and the application of an appliance that will facilitate the gradual and incremental separation of bone segments.

- SARPE

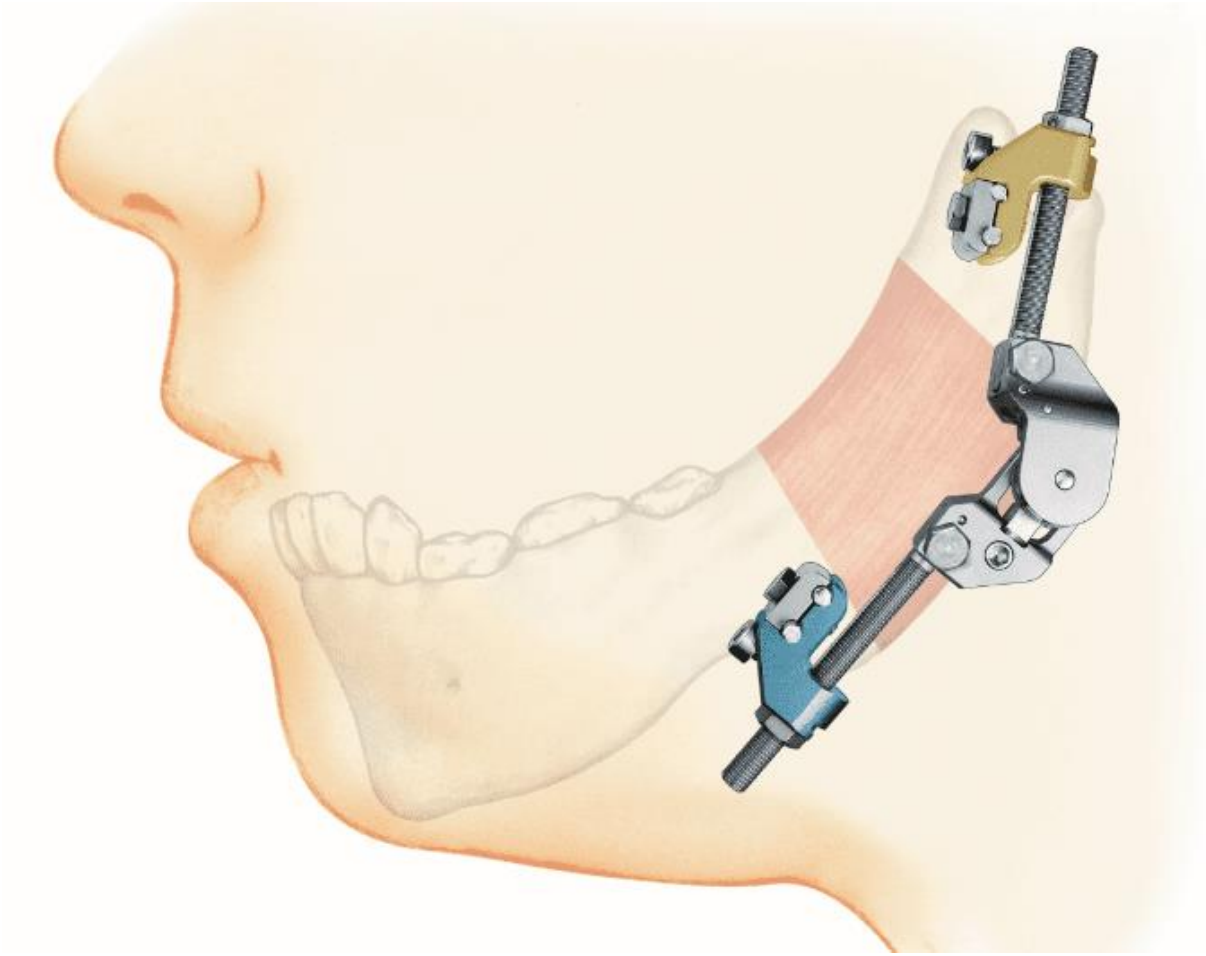

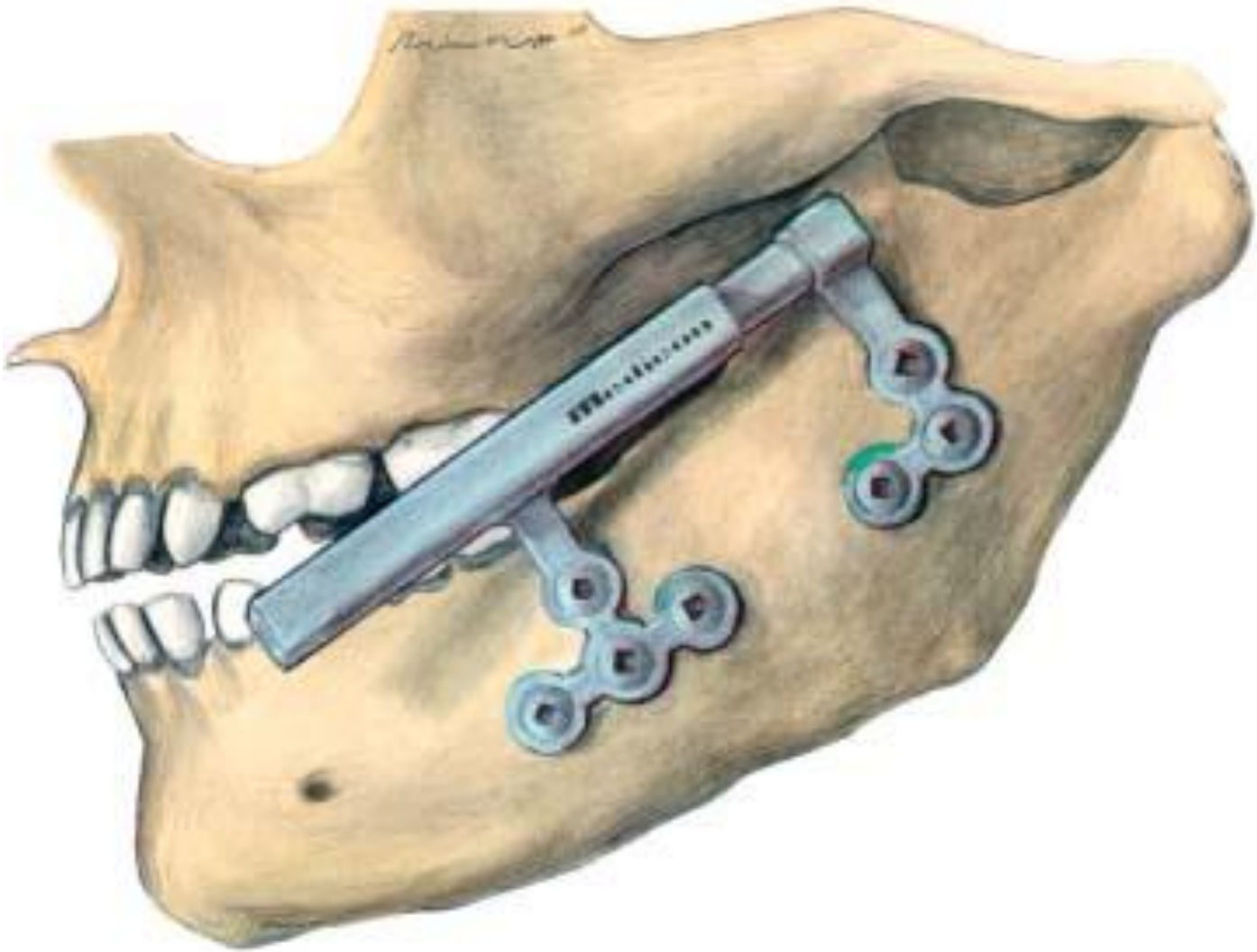






34

Phases of DO

- Surgical phase
- The latency phase
- The distraction phase
- The consolidation phase

Advantages of DO

- 1. Elimination of the need for bone grafts and the associated secondary surgical site.
- 2. Better long-term stability.
- 3. Less trauma to the TMJ.
- 4. Decreased neurosensory loss.

Disadvantages of DO

- 1. desired vector of bone movement is technique sensitive and sometimes results in less-than-ideal occlusal positioning.
- 2. The need for two procedures; placement and removal of the distractors.
- 3. Increased cost .
- 4. Longer treatment time.