Lec11: Radiographic appearance of dental anomalies د. هبة عزت بيرم

There are many developmental anomalies that can affect the teeth and facial skeleton. The diagnosis of these variations based on clinical and radiographic findings.

Classification of developmental anomalies: classified in to:

A. Anomalies of the teeth (Number, Structure, Size, Shape and Position).
B. Skeletal anomalies (Micrognathia, Macrognathia, Cleft lip and palate, Torus palatines, Torus mandibularis).

A. Anomalies of the teeth:

1. Number:

a) Hypodontia: patient has a missing teeth as a result of their failure to develop. The expression of developmentally missing teeth includes the absence of one or a few teeth (hypodontia), the absence of numerous teeth (oligodontia), and the failure of all teeth to develop (anodontia). It could happened in Ectodermal Dysplasia [lack of: hair, sweat glands, and teeth (partial anodontia)].



(A) Multiple missing teeth in a patient with oligodontia. *White arrows* show radiographic markers for planning dental implants. (B) Panoramic reconstruction of a cone beam computed tomography volume. *White arrow* shows a developmentally absent maxillary left canine.

b) **Hyperdontia:** as a result of excess dental lamina in the jaws are referred to as supernumerary or supplemental teeth, or parateeth. These additional teeth may be morphologically normal or abnormal. When supernumerary teeth have normal morphologic features, the term supplemental is sometimes used. The most common supernumerary tooth is a misodens (malposed, peg-shape that occur between the maxillary central incisors). Fourth and fifth molars that form behind the third molars are another kind of supernumerary teeth. It could be associated with **Cleidocranial Dysplasia** [an inherited disorder involving the cranium, face, clavicles, and supernumerary teeth].



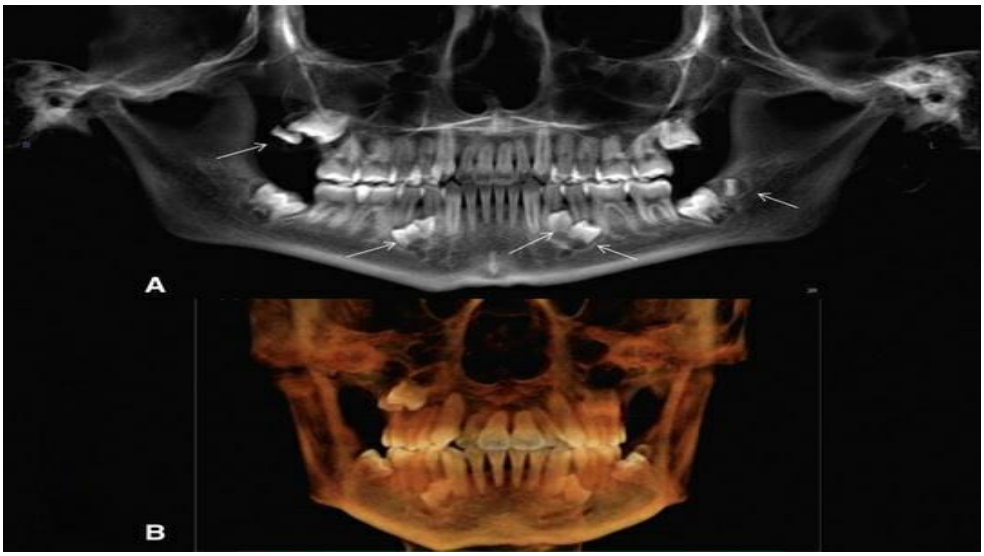

2. Structure:

a) Genetic defect:

- **Amelogenesis imperfecta**: is a genetic anomaly arising from mutations that may have occurred in one or more of four candidate genes that play some

role in enamel formation: amelogenin (*AMELX*), enamelin (*ENAM*), enamelysin (*MMP20*), and kallikrein 4 (*KLK4*). The dentin and pulp are usually normal.

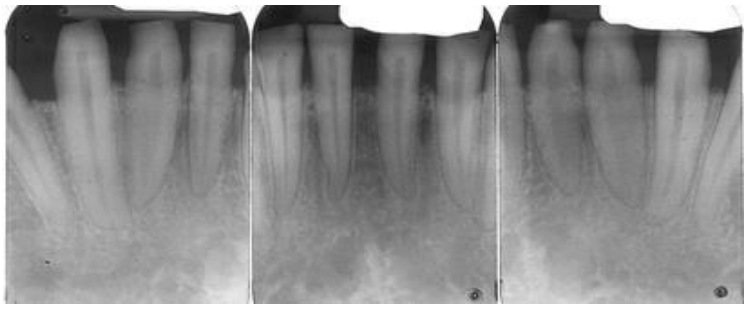

- **Dentinogenesis Imperfecta:** occurs with equal frequency in both genders. Both the deciduous and the permanent dentition may have this defect. There is pulp obliteration and short blunt roots.

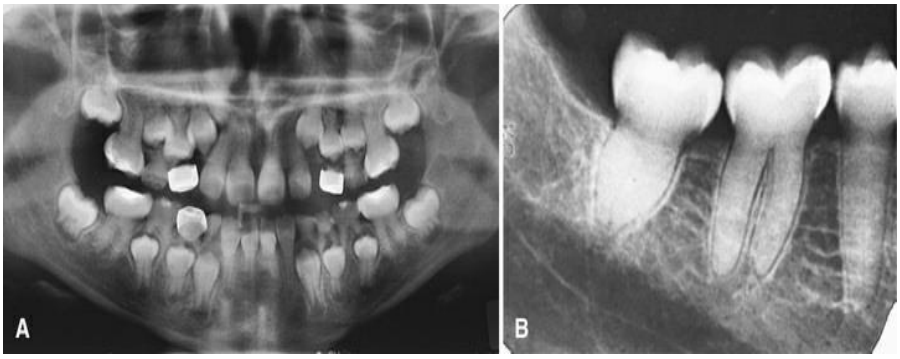

(A and B) Dentinogenesis imperfecta characteristically shows bulbous crowns, constriction of tooth at the cementoenamel junction, short roots, and a reduced size of the pulp chamber and root canals.

- **Odontodysplasia:** also called "ghost teeth," is a rare condition in which both enamel and dentin are hypoplastic and hypocalcified, with large pulp chamber.



b) Acquired defects:

- **Turner hypoplasia:** is a term used to describe a permanent tooth with a local hypoplastic enamel defect. This defect may have been caused by the extension of periapical inflammatory disease from its deciduous predecessor, by mechanical trauma transmitted through the deciduous tooth or a protracted systemic illness affecting tooth mineralization. If the insult occurs while the crown is forming, it may adversely affect the ameloblasts of the developing tooth, and result in some degree of enamel hypoplasia or hypomineralization.

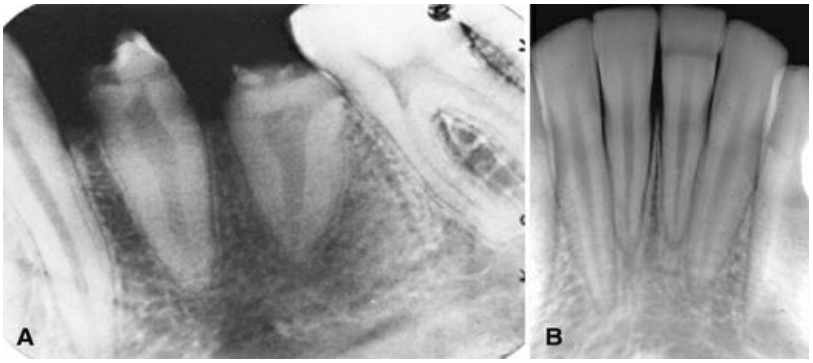

(A) Turner hypoplasia shown as an extensive malformation and hypomineralization of the crowns of both premolars. (B) Band of hypoplasia extending across the crown of the mandibular left central incisor.

- **Congenital syphilis:** Approximately 30% of individuals with congenital syphilis have dental hypoplasia that involves **the permanent incisors and first molars**. The affected incisors are called **Hutchinson incisors and the molars are called "mulberry molars"**. The changes characteristic of the condition seem to result from a direct infection of the developing tooth because the syphilitic spirochete has been identified in the tooth germ.



Congenital syphilis may induce a developmental malformation of the maxillary central incisors referred to as "Hutchinson incisors." The abnormal morphology is characterized by tapering of the mesial and distal surfaces toward the incisal edge with notching of the incisal edge.

3. Size:

a) **Macrodontia (large teeth):** also called **megadontism or megalodontia** in which the teeth are larger than normal; however, macrodontia rarely affects the entire dentition. It may involve all the teeth or be limited to a single tooth or group of teeth.

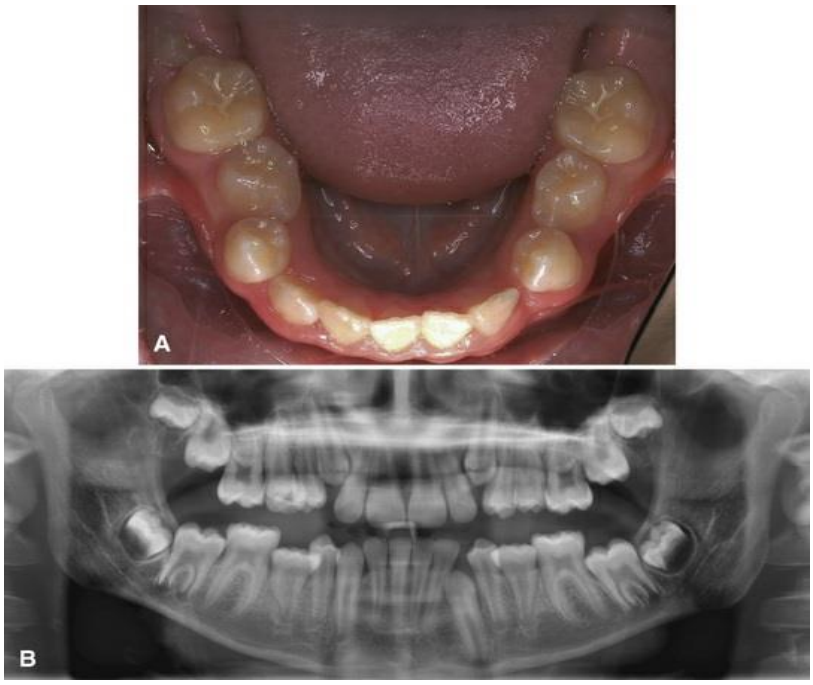

(A) Clinical photograph of mandibular second premolar macrodontia. (B) Panoramic image shows the greater mesial/distal widths of the tooth crowns compared with their respective first premolars.

b) **Microdontia (small teeth):** the teeth are smaller than normal. As with macrodontia, microdontia may: generalized form, involve all the teeth or localized form, limited to a single tooth or group of teeth. The most affected teeth are upper lateral incisors and third molars. The affected teeth may be of normal or abnormal morphology.

- **There are types of microdontia:**

1.True generalized microdontia.
2. Relative generalized microdontia.
3. Microdontia involving a single tooth.

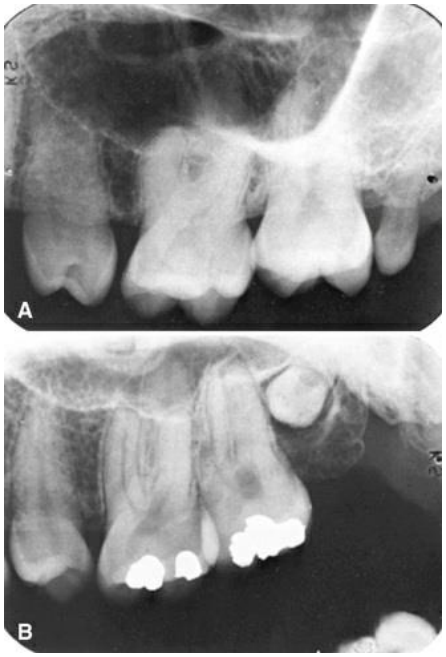

(A and B) Periapical images show a reduction in both the size and the number of cusps in microdontia of the maxillary third molars.



Peg-shaped deformity in microdontia of a maxillary lateral incisor.

4. Shape:

a) **Fusion:** two teeth joining together in to a single anatomic crown (union of two separated tooth germ).



b) Gemination: two teeth joined together arising from a single tooth germ (single root with 2 anatomic crowns).

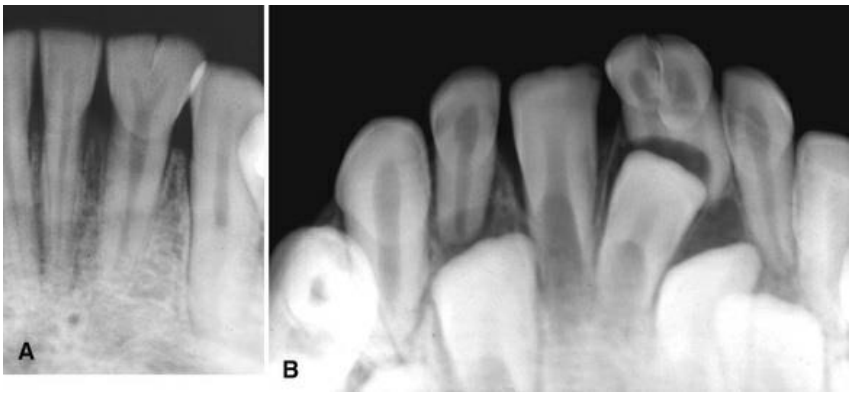

(A) Gemination of a mandibular lateral incisor showing bifurcation of the crown and pulp chamber. (B) Almost complete gemination of a deciduous lateral incisor.

c) Dilaceration: is a disturbance in tooth formation that produces a sharp bend or curve in the tooth anywhere in the crown or the root of a developed tooth of 90° or more.

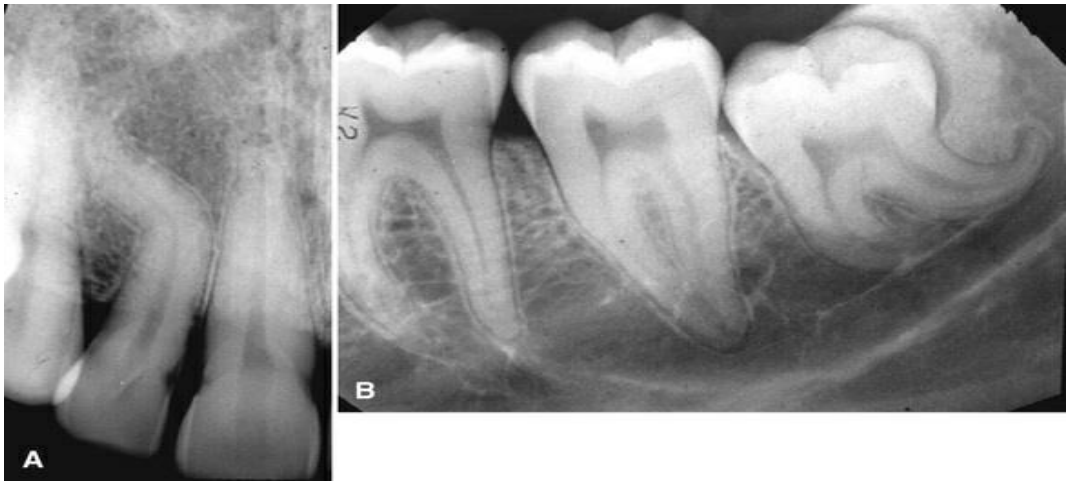

Dilaceration of the root of a maxillary lateral incisor (A) and mandibular third molar (B).

d) Dens invaginatus, Dens in Dente, and Dilated Odontome: represent varying degrees of invagination or infolding of the enamel surface into the interior of a tooth (dental papilla).

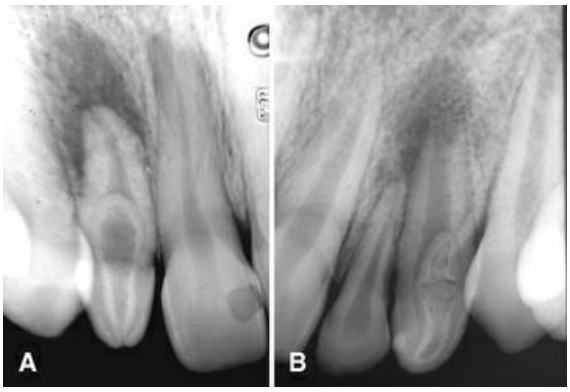

(A and B) Infolding of enamel is more severe in dens in dente as seen in these two periapical images. The invagination begins near the incisal edge of these abnormally peg-shaped lateral incisors.

e) **Dens evaginatus:** In contrast to dens invaginatus or dens in dente, dens evaginatus (or Leong premolar) is the result of an evagination or outpouching of the enamel organ. The resultant enamel-covered tubercle usually occurs in or near the middle of the occlusal surface of premolar or occasionally molar teeth. Lateral incisors are most commonly involved, whereas canines are rarely affected.



(A) Occlusal tubercle of dens evaginatus as seen in a mandibular premolar. (B) Periapical image of the specimen.

f) **Enamel pearl:** is a condition of teeth where enamel masses found in a root surface and found in 2% of population. They are usually found in the area between roots in the furcation area of molars. Enamel pearls are not common in teeth with a single root.

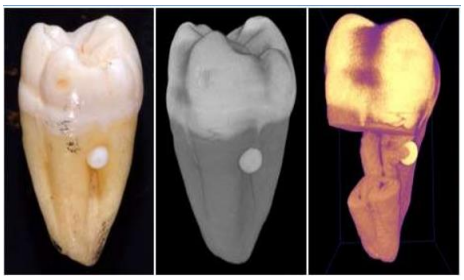

g) **Taurodontism:** The bodies of taurodont teeth appear elongated, and the roots are short. The pulp chamber extends from a normal position in the crown throughout the length of the elongated body, resulting in a more apically positioned pulpal floor. Taurodontism may affect any tooth in either the primary or permanent dentitions, and is usually fully expressed in the molars and less often in the premolars. Single or multiple teeth may show taurodont features.



Periapical images reveal enlarged pulp chambers and apically positioned furcations in permanent first molars (A), a primary first molar (B), and a permanent molar (C).

h) **Talon cusp:** "cusp-like" projections located on the inside surface of the affected tooth. Talon cusp is an extra cusp projecting from the cingulum area or CEJ of maxillary or mandibular anterior teeth.



5. Position:

The abnormalities in teeth position may be caused by:

a) **Local causes:**
- Loss of space
- Overcrowding
- Additional teeth
- Retention of deciduous predecessor

b) **Systemic causes:**
- Metabolic diseases
- Developmental disturbances
- Hereditary conditions

B. Skeletal anomalies (Micrognathia, Macrognathia, Cleft lip and palate, Torus palatines, Torus mandibularis).

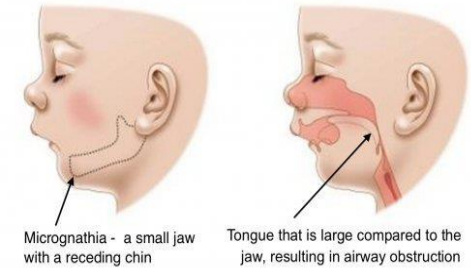

-abnormally large jaws

Factors that favor mandibular prognathism:
- Increased height of ramus
- Increased mandibular body length
- Increased gonial angle





