What is the cyst???

Cyst: is defined as a pathological cavity which may or may not be lined by epithelium and is filled with fluid, semi fluid or gaseous material.

- ✓ A cyst is an epithelium-lined cavity, containing gaseous, semisolid, or fluid material, but not pus .
- ✓ The cysts of the jaws may be divided into odontogenic and nonodontogenic cysts .
- ✓ The cysts have a tendency to expand due to the tension as a result of an osmotic imbalance .
- ✓ It occurs in anywhere in upper and lower jaws.

General clinical features of the cysts:

Cyst usually asymptomatic, but some symptoms may occur like:

- Swelling
- Displacement or loosening of teeth
- Pain (if infected)
- Eggshell cracking
- Fluctuance may be elicited

Radiological examination:

- ➢ For small cystic lesions,

intra-oral films may be all

that is needed for diagnosis.

- ➢ For larger lesions, more extensive radiography is appropriate (extraoral radiograph, CT scan …)

Radiological signs

- ➢ Well-defined round or ovoid radiolucencies, surrounded by sclerotic margins (white lines)

- 'Scalloped' margins are seen in larger lesions, particularly keratocysts.
- Infection of a cyst tends to cause loss of the well-defined margin.
- True locular (multiple cavities) is seen occasionally in odontogenic keratocysts.

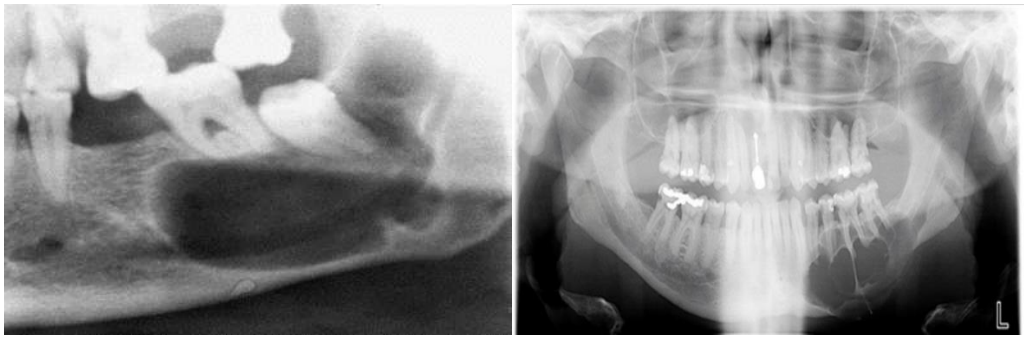

Classification of Jaw Cysts:

A. Epithelial lining:

1. ***Odontogenic cyst***
2. ***Non-Odontogenic cyst***

B. Non-Epithelial lining:

1. Odontogenic cyst:

A cyst in which lining of lumen is derived from epithelium produced during tooth development.

- **Odontogenic Inflammatory Cysts:**

1. Radicular cyst:

- 20-50 year-olds.
- Apex of any non vital tooth, Round and unilocular.
- Smooth ,well defined , well corticated and continuous with the lamina dura of the associated tooth.

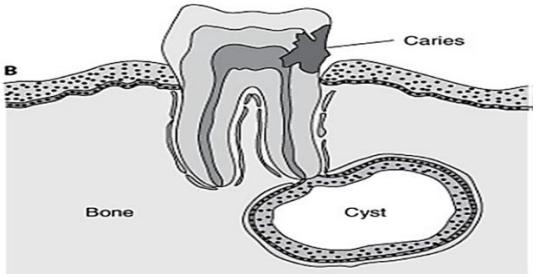

2. **Residual radicular cyst**:
   - Apical regions of the tooth-bearing portion of the jaws.
   - Round, unilocular, smooth, well defined, well corticated and uniformly radiolucent.
   - Treatment: Inoculation.



3. **Cementoma**
   - R .at apex of vital tooth, lower vital anterior teeth, and requires no treatment.
   - It is radiolucency in early stage then they undergo gradual transition to radiopacity (stage 2) & in about six years become completely radiopaque (stage 3).

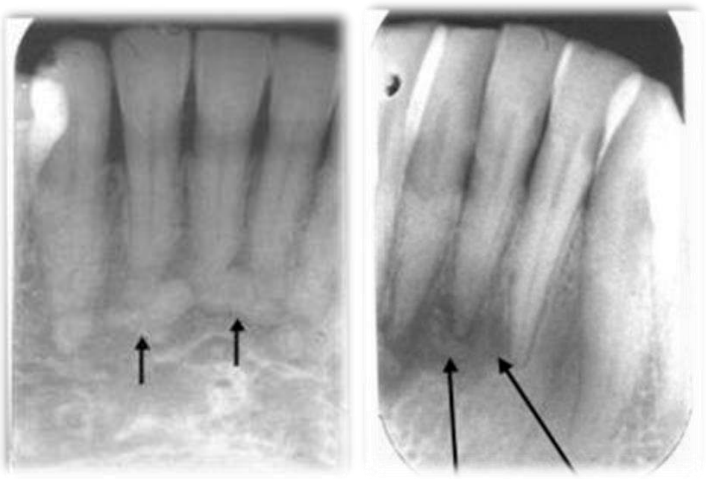

4. Radiolucent lesion associated with root canal filling & apical surgery:

R. that fit this description & in which there is <u>neither a draining fistula nor any other local symptoms of pain</u> represents an apical scar.

• Odontogenic Developmental Cysts:

1. Lateral periodontal cyst:

- ❖ Adult over 30 years old.
- ❖ Lateral surface of the roots of the vital teeth in the lower canine /premolar region or upper lateral incisor region.
- ❖ Small, less than 1 cm in daimeter.
- ❖ Unilocular, round or ovoid and very rare multilocular.
- ❖ Smooth, well defined and corticated.

2. Dentigerous cyst:

- ❖ Associated with the crown of an unerupted and displaced tooth , typically teeth where eruption is impeded, e.g. $\underline{3|3}$,$\overline{8|8}$.
- ❖ Very variable, from 3mm to several cm and extend up into ramus.
- ❖ Round or oval, unilocular.
- ❖ 3 varieties are described depending on the cyst /crown relationship: central, lateral, circumferential.

3. Eruption cyst:

- It is dentigerous cyst that begin to develop during active eruption phase of a tooth & is carried by the eruption into the soft tissue of the alveolar crest.
- Radiology: No distinct radiographical picture (soft tissue mass may be seen in high resolution radiograph).



4. Gingival Cyst of Adults:

- A great confusion between the gingival cyst of adults and the lateral periodontal cyst, both types have a predilection for occurrence in the canine and premolar area of the mandible
- Gingival cyst only soft tissue lesions of the gingiva with no bony involvement.
- The cysts are round to oval, well circumscribed swellings, usually less then 1cm in diameter and may occur in the attached gingiva or the interdental papilla.
- The adjacent teeth are usually vital.

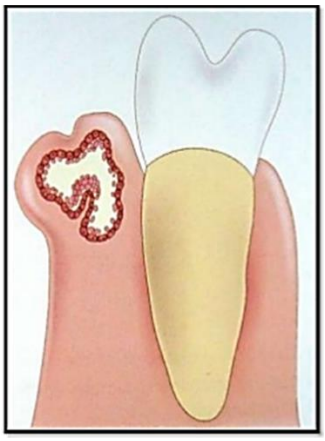

5. Gingival cyst of infants:

- It is soft tissue cysts on the alveolar crest of the gum pad of newborn arise from remnants of dental lamina and contain keratin.
- Clinical features:

➢ Appears as pearly white nodules 2-3mm in diameter on the alveolar ridge
➢ May be solitary or multiple
➢ Appears white in color due to presence of **keratin** within the cyst
➢ Similar lesion on mid palatine raphe are called **Epstein's pearls**
➢ Similar lesions on lingual, buccal aspect of alveolar ridge are called **Bohn's nodules**



6. Odontogenic Keratocyst OKC (primordial):

— The cyst develops from epithelium of dental lamina instead of normal tooth which is typically missing from the series. Smooth, well defined and often well corticated, radiolucent lesion.

— **Site:**

❖ **Posteriorly:** body/ angle of the mandible extending in to the ramus.

❖ **Anteriorly:** maxilla in canine region.



2. Non-Odontogenic cyst:

A cyst in which lining of lumen is derived from tissues other than those involved in tooth development.

A. Developmental Fissural Cysts:

Fissural cysts are non-odontogenic cysts, that arise from epithelial inclusions or entrapments in the lines of closure of the developing facial processes during the embryonic period of life.

1. Nasopalatine duct/ Incisive canal cyst:

- Midline ant. Max. just posterior to 1 | 1.
- Round or oval (superimposition of the nasal septum or anterior nasal spine may cause the cyst to appear heart shaped or resemble an inverted tear drop)
- Unilocular
- This cyst develops from epithelial remnants of nasopalatine duct or incisive canal.



2. Globulomaxillary Cyst:

— non-odontogenic in origin.

— Unilocular, inverted pear shaped, well circumscribed and cause root divergence.

— Between upper 2&3.

— Tooth is vital, causing displacement of tooth.



3. Nasolabial cyst:

—This is rare ((soft tissue)) cyst.
—Unilateral, occurs in the vestibule of upper 2 & 3 outside the bone in the nasolabial fold just below the ala_of nose. Teeth are vital and there is no displacement of teeth.
—Does not produce any radiolucency.
—Aspiration or radiopaque contrast media establish the diagnosis.
—Treatment by excision.



4. Median palatine cyst:

— It occurs in the midline of hard palate, posterior to the incisive canal.
— No signs and symptoms exist, unless the cyst becomes large, with expansion of bone.
— Teeth in the area are vital.
— Treatment by surgical excision.



5. Median mandibular cyst:

- Occurs in the midline of the mandible, may be created by proliferation and cystic degeneration of resting epithelial tissue that is left trapped within the substance of the bone during embryologic fusion of the two halves of the mandible, along the plane of fusion later termed the symphysis menti.
- Teeth are vital

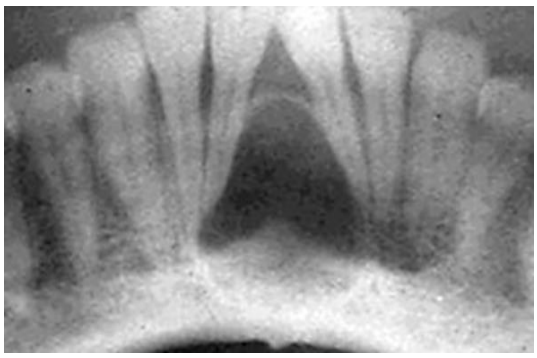

B. Non-Epithelial lining:

✓ Aneurismal or Traumatic Bone cyst (solitary also called simple or pseudocysts):

— According to the name, not categorized as cyst due to lake their epithelial lining.
— The etiology of this cyst is unknown but may be associated with trauma and this trauma causing intraosseous hemorrhage and this hematoma undergo liquefaction resulting in cystic defect.
— Body/ post. mand. Including the ramus
— Unilocular or multilocular, Faint internal trabeculation may produce a soap bubble appearance.

