Vascular Anomalies

Dr.Raad Salah Shyaa

Vascular anomalies include various diseases, which are classified into two distinct entities according to the International Society for the Study of Vascular Anomalies (ISSVA) classification:

- ✓ Vascular tumors (hemangioma) with proliferation of vascular endothelial cells.
- ✓ Vascular malformations characterized by the abnormal dilation of vessels without proliferation.

- **History and clinical examination**
- **Investigations :**

1. Magnetic resonance imaging (MRI)
2. Contrast-enhanced computed tomography (CT)
3. Grey-scale ultrasound and Doppler analysis
4. Angiography
5. Direct intralesional injection of contrast medium

Hemangioma

- It is the most common tumor in childhood affecting about 10% of neonates.
- The head and neck region is the most commonly involved site (60%).
- Most lesions are solitary (80%) and girls are more affected than boys (3:1).

Classification

Infantile hemangioma

Congenital hemangioma

Subdivided:

- Rapidly involuting congenital hemangioma.
- Non-involuting congenital hemangioma.
- Partially involuting congenital hemangioma.

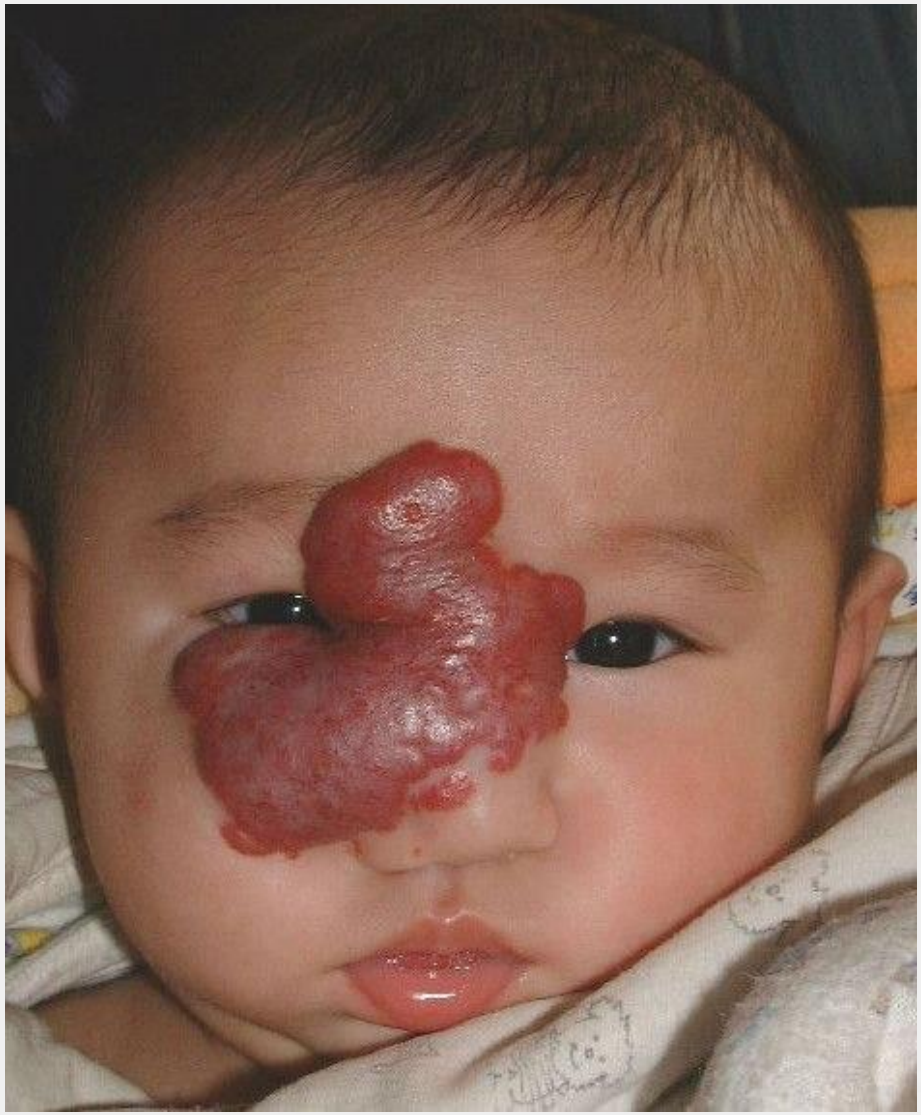



Superficial hemangiomas

Deep hemangiomas

Compound hemangiomas

Stages

1.Proliferative stage

2. Involutive stage

3. Involuted stage

Complications

Occur in 20% of the patients:

- ☐ Ulceration with or without secondary infection.
- ☐ Bleeding.
- ☐ Periocular lesions may result in amblyopia, strabismus or astigmatism.
- ☐ Airway obstruction in laryngeal lesions.
- ☐ Visceral involvement.
- ☐ Kasabach-Merritt syndrome

Treatment

In the proliferative phase the aim is to eradicate or stunt the growth

- Pharmacological treatment

☐ Systemic corticosteroid therapy

☐ Interferon α 2A and B

☐ Nonselective beta adrenergic receptor blocker propranolol

- **Laser therapy**

pulsed dye laser (PDL …. superficial lesions.

Nd:YAG laser for lesions in the late proliferative stage.

- **Surgery**

for the lesions that do not respond to the non-surgical treatment.

In the involutive stage treatment is aimed to improve **function and esthetics**.

- PDL and Nd:YAG laser for superficial lesions.
- Surgical resection for deep lesions.

Vascular Malformations

- These are errors of morphogenesis that are populated by stable mature vascular endothelium.
- Both sexes are equally affected
- They are always present at birth
- never proliferate or involute

Classification

According to the predominant vessel type:

1. Capillary.
2. Venous.
3. Arteriovenous.
4. Lymphatic.
5. Combined.

According to the hemodynamic properties into:

1. High-flow.

2. Low-flow.

They are made up of postcapillary venules within the papillary and superficial reticular dermis.

They present initially as flat pink macules but darken and thicken with age.

They are graded according to the degree of ectasia of the vessels into grades I–IV

The primary treatment of capillary malformation is the laser application.

An average of two to six treatments may be necessary and the response rate is variable.

The suggested etiology of the recurrence is that any abnormally innervated vessels in the superficial papillary plexus that were left behind would lead to recurrence



Venous malformations

They are characterized by an abnormal collection of veins, which do not have any demonstrable mitotic activity in endothelial cells and often lack a uniform smooth muscle layer.

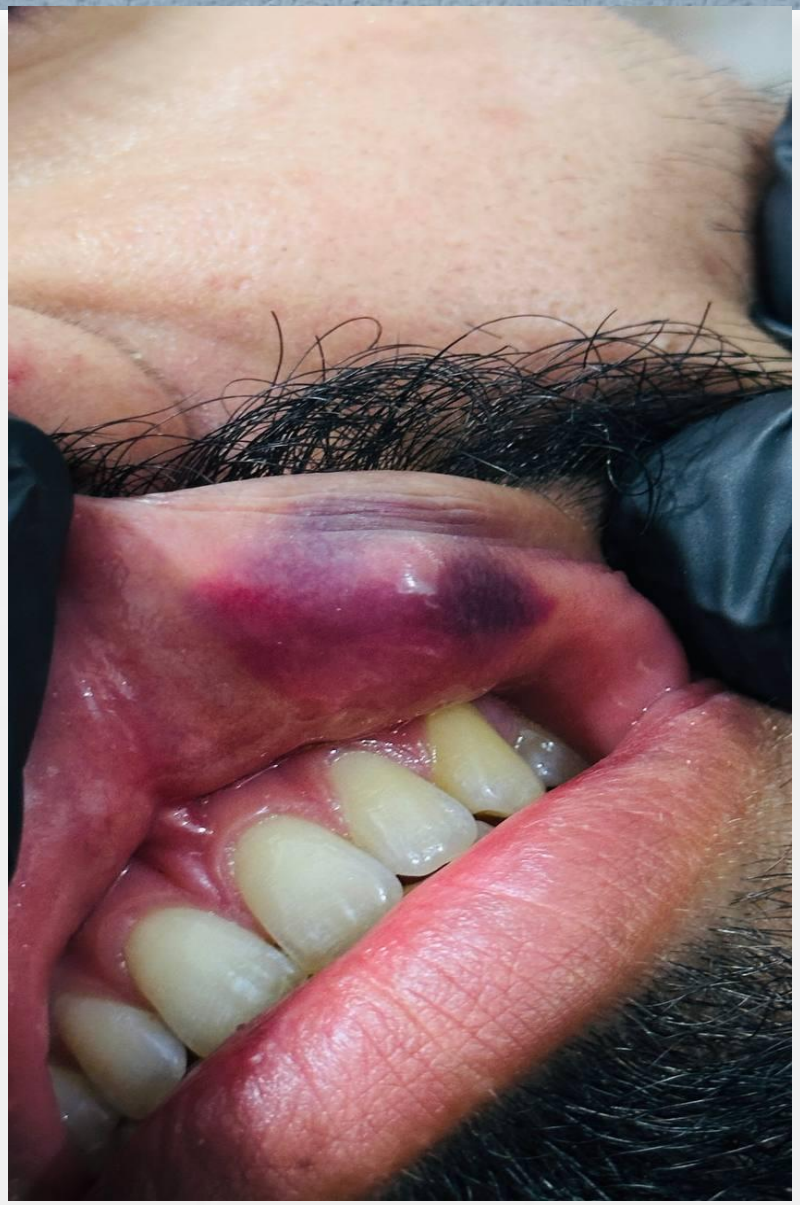





- They can be focal, multifocal or diffuse.
- Up to 60% of venous malformations are located in the head and neck area.
- The lesions are usually soft, compressible, and enlarge in size when venous pressure is increased.
- Phleboliths may be present.
- Changes in the adjacent skeleton, if present, often take the form of bony hypertrophy or distortion or both.


2
3
4
5
6
7
8
9
MOTRACE®
CE
NOVATECH S.A
1058, voie Antic

Treatment

Two different methods: sclerotherapy and surgery that occasionally could be combined.

Sclerotherapy is the most widespread method.

Sclerosing agents can be divided in the following groups:

- ☐Osmotic substances (hypertonicsaline/salicylates)
- ☐ Chemical substances (ethanol/iodine)
- ☐ Anticancer substances (bleomycin)
- ☐ Detergents (polidocanol/sodium tetradecyl sulfate/diatrizoate sodium)

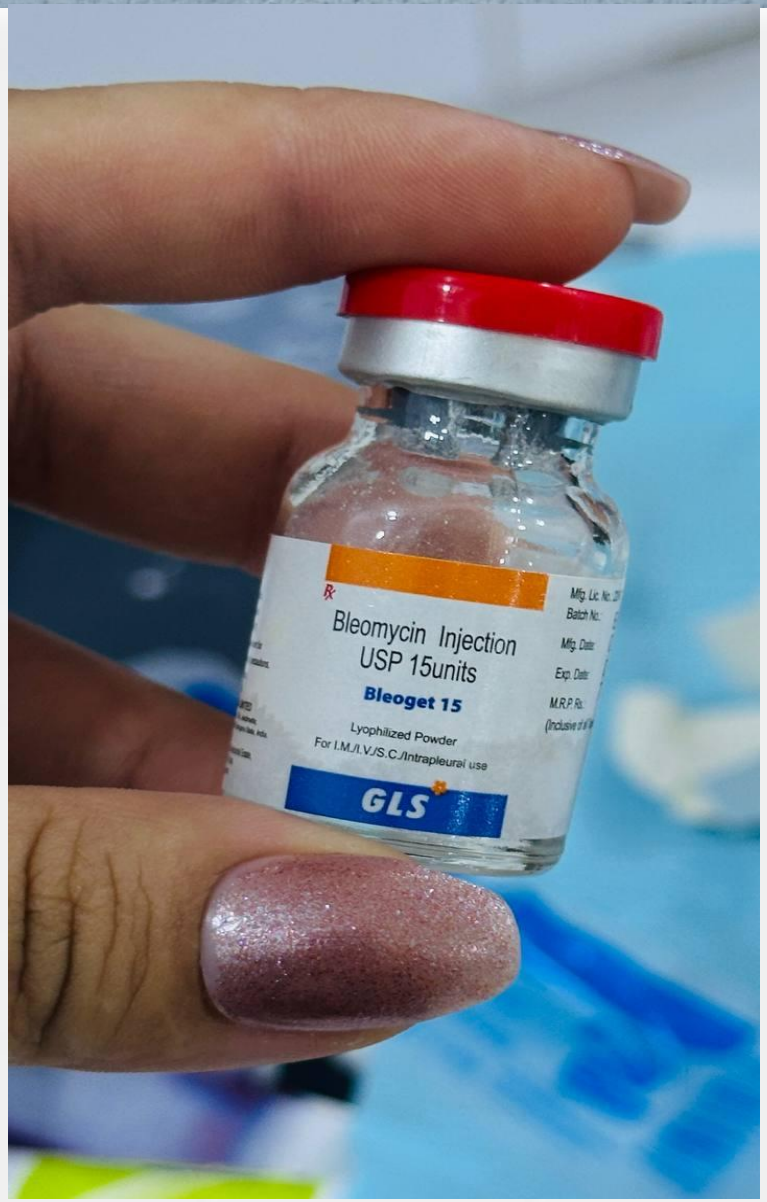
Bleomycin Injection
USP 15units
Bleoget 15
Lyophilized Powder
For I.M./I.V./S.C./Intrapleural use
GLS

Surgical treatment of venous malformation is indicated only for small, well-defined lesions that can be easily excised.

Larger or diffuse venous malformations requires a combination of sclerotherapy and surgical removal.

- **compartmentalization**



Lymphatic malformations

They constitute a spectrum of disorders that present in various ways, often in childhood and adolescence.

Lymphatic malformations are categorized into macrocystic (single or multiple cysts >2 cm3), microcystic (<2 cm3), and mixed forms.

Cervical lesions are usually of the macrocystic variety (cystic hygroma) and those involving the floor of the mouth, cheek, and tongue are more likely to be of the diffuse microcystic variety (lymphangioma



Complications include:

infection, bleeding, obstruction of the airway, disturbances of speech, and abnormal facial growth. Hypertrophy of both soft tissue and skeleton are common and occur in up to 80% of cases.

Treatment

Sclerosing agents that have been used for the therapy of lymphatic malformations are Picinabil (OK-432), bleomycin, doxycycline, acetic acid, alcohol, and hypertonic saline.

The surgical treatment includes the removal of the lymphatic malformation and the restoration of both the esthetic appearance and the function of the affected region.

Lymphatic malformations that cause abnormal facial growth, secondary orthognathic surgery is often required.

High-flow malformations

Arteriovenous malformations

They are the *least common* and the *most dangerous* subtype of the vascular malformations. They consist of a nidus composed of abnormally dilated capillaries with hypertrophied arteries and dilated veins resulting from increased flow across the nidus.

Treatment

Embolization is the transcatheter introduction of intravascular agent for hemorrhage control/devascularization/occlusion.

Various agents have been used for embolization which include gelfoam, polyvinyl alcohol, silicone fluid, isobutyl-2 cyanoacrylate (IBCA), coils, and balloons

- The surgical treatment is commonly performed in conjunction with preoperative embolization.

- Because collateral blood supply becomes established quickly, the surgical resection should be performed within 24 to 72 hours after embolization.

The clinical manifestations:

- may include facial asymmetry
- unexplained dental mobility or malposition
- discolorations of skin or intraoral mucosa, palpable thrill,
- spontaneous gingival bleeding,
- pain, or paresthesia.

Radiographically they appear as a radiolucency. The diagnostic tool of choice is arterial angiography.