1. Periapical radiographic techniques:

Periapical radiographs are taken of both anterior and posterior and are commonly used in dentistry to show the entire length of the tooth and the surrounding bone. It must show the full length of the roots and at least 2 mm of periapical bone. The name periapical is derived from the Greek peri, which means around, and apical, which means tip.

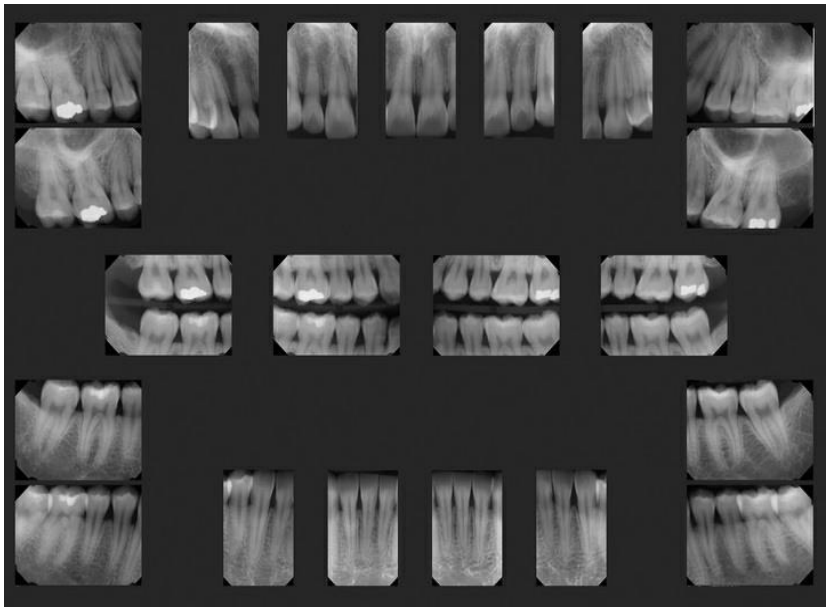

Indications

- Detection of apical infection/inflammation.
- Assessment of periodontal status after trauma to the teeth and alveolar bone.
- After trauma to assess the teeth and alveolar bone.
- Assessment of the presence and position of unerupted teeth.
- Assessment of root morphology before extractions.
- During endodontic therapy.
- Preoperative and postoperative assessment of apical surgery.
- Detailed evaluation of apical cysts and other lesions within the alveolar bone.
- Presurgical implant insertion bone evaluation.

Two intraoral projection techniques are commonly used for periapical radiography: (1) the paralleling technique and (2) the bisecting-angle technique. Both techniques can be applied to digital- and film-based imaging. The paralleling technique is preferred because it provides images with less distortion of the dentition.

A. Paralleling technique:

Paralleling technique is also called as extension cone paralleling technique (XCP), right angle technique, and long cone technique. As the name implies, this technique is based on the concept of parallelism. In this technique, the film is placed in the mouth parallel to the long axis of the tooth and the central x-ray beam is directed perpendicular or at a right angle to the long axis of the tooth and the film by using film holders.

Requirements of this technique:

1. Long cone should be used to make the target-object distance as long as possible.
2. It requires the X-ray strike the object (tooth) and the film at right angle (90°).
3. It requires the film to be placed in apposition parallel with the plane passing through the long axis of all teeth being examined.
4. A film holder must be used to keep the film parallel with the long axis of the tooth.

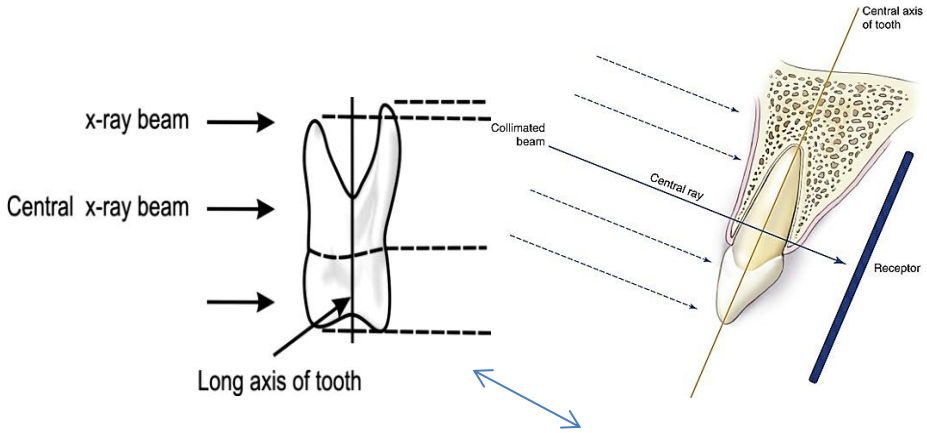

For the tooth and the film to be parallel they have to be positioned some distance apart.

Due to anatomic constraints, this parallel orientation places image receptor toward the middle of the oral cavity, away from the teeth. This increases the object-to-receptor distance and results in higher image magnification and poor geometric sharpness. To compensate for the resultant distortion and lack of sharpness, the paralleling technique is used with a relatively long source-to-object distance by using extended long cone of 16 inches.

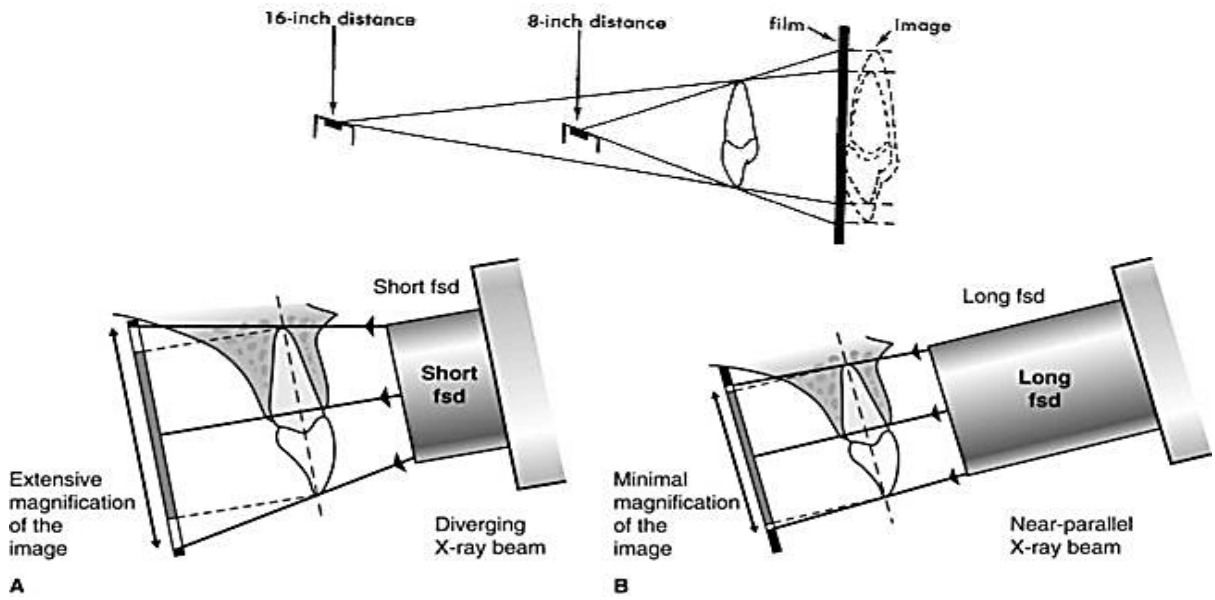

A film holder: is a device that is used to position an intraoral film in the mouth and retain the film in position during exposure.

Purpose of using film holder is:

1. to eliminate patient's hand exposure
2. when the patient has a broken arm
3. avoid cone cut the film
4. assist in identifying horizontal and vertical angulations





B. Bisecting-angle technique:

Bisecting angle technique is also called as bisecting technique, bisection-of-the-angle technique. This technique is performed by keeping the film as close to the

teeth as possible. The central x-ray beam is directed perpendicular to an imaginary bisector that bisects the angle formed by the long axis of the tooth and the film.

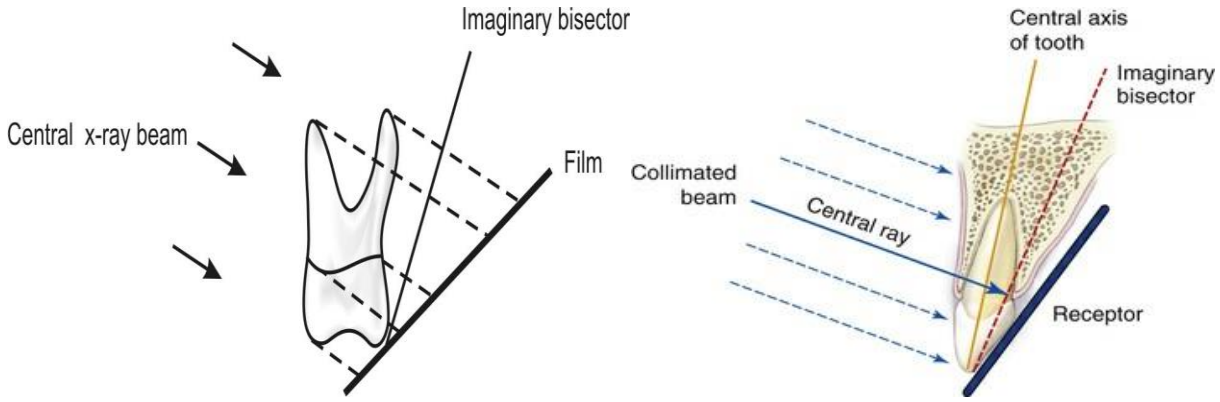

Requirements of this technique:

1. Operator envision an imaginary bisector of the angle formed by the long axis of the tooth and the long axis of the film, this angle formed where the film contacts the tooth crown.
2. Operator direct the central ray of the beam through the apex of the tooth so central ray strikes the bisector at 90° so the result is a tooth image that is exactly the length of the tooth.

In this technique, as a result of lack of parallelism between the tooth and the film since the film is in contact with the tooth crown, we have all the areas below the apex of the tooth as well as above are distorted and the degree of distortion can reduce by the use of long cylinder because the longer distance between the source of radiation and the object the more is the parallel will be the rays.

2. Bitewing film angulations and placemen:

Bitewing (also called **interproximal**) radiographs include the crowns of the maxillary and mandibular teeth and the alveolar crest on the same receptor. The beam is directed through the interproximal spaces and perpendicular to the buccal and lingual surfaces of the teeth being examined and is parallel to the occlusal plane. The vertical angulation used for tab bitewings ranges from 5° to 10° of the X-ray beam compensating for the curve of Monson. The most common error associated with bitewing radiography is horizontal overlap which can render the image non-diagnostic.

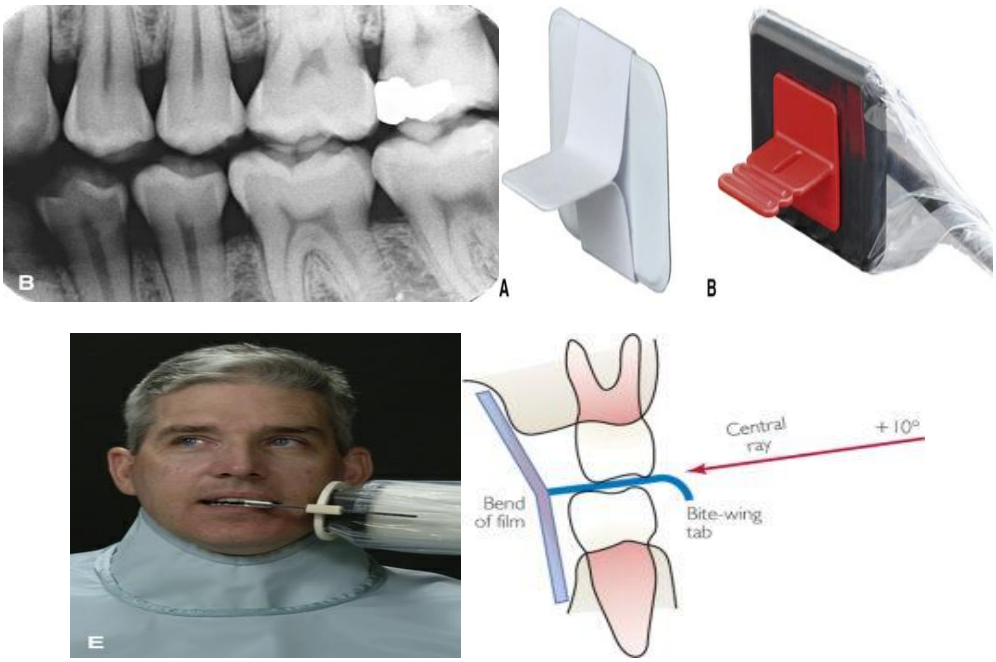

Indications for Bitewing Radiograph:

- ✓ In the diagnosis of interproximal caries
- ✓ To study the height of the pulp chamber
- ✓ In the diagnosis of secondary caries below restoration and to demonstrate the over hanged filling
- ✓ To study the height of the alveolar bone or assessment of bone loss
- ✓ In the diagnosis of pulp stone
- ✓ To study occlusion of the teeth
- ✓ Evaluating periodontal conditions.

Angulation of the Tube Head:

- **Horizontal angulation**

The central ray of the X-ray beam is directed in a horizontal plane directed perpendicular to the curvature of the arch and through the contact of the teeth.

- **Vertical angulation**

The central ray of the X-ray beam must be directed in a vertical plane perpendicular to the long axis of the tooth and the film in parallel technique or perpendicular to the imaginary line formed by the bisecting angle formed by the long axis of the tooth and the film in bisecting angle technique.

- **Plus vertical angulations:** when the beam is tipped down ward.
- **Minus vertical angulations:** when the beam is tipped upward.

Film placement and angulations for periapical films:
The anatomical area and the apex of the tooth under investigation should be shown, as well as 2-3mm of surrounding bone to enable an assessment of apical anatomy.

3. Occlusal Film Projection:

An occlusal radiograph displays a relatively large segment of a dental arch. It may include the palate or floor of the mouth. Occlusal radiographs also are useful when patients are unable to open wide enough for periapical image. Because occlusal radiographs are exposed at a steep angulation, they may be used with conventional periapical images to determine the location of objects in all three dimensions.

Diagnostic Objectives of Occlusal Radiography:

1- Useful when larger area to be visualized.
2- To aid in the localization of a foreign object.
3- To locate retained roots of extracted teeth.
4- To locate supernumerary, unerupted, or impacted teeth.
5- To evaluated the boundaries of the maxillary sinus.
6- To evaluate fractures of the maxilla or mandible.
7- To examine the area of a cleft palate.
8- To measure changes in the size and shape of the maxilla and mandible.

Theory of the occlusal technique:

1- The film is positioned with the white side facing the arch that is being exposed
2- The film is placed in the mouth between the occlusal surfaces of the maxillary and mandibular teeth. The film is stabilized when the patient gently bites on the surface of the film.

Individual Occlusal Projections:

1. **Maxillary occlusal projection:** (Upper standard occlusal, Upper oblique occlusal, Vertex occlusal).
2. **Mandibular occlusal projection:** (Lower 90° occlusal “true occlusal”, Lower standard occlusal, Lower oblique occlusal).

Maxillary occlusal projection:

A. Upper standard occlusal:



Image Field: Includes the anterior maxilla and its dentition and the anterior floor of the nasal fossa and teeth from canine to canine.

Technique involved:

1) The patient's head is aligned with the occlusal plane horizontal and parallel to the floor.
2) Film placed centrally in to the mouth on the occlusal surfaces of the lower teeth and ask the patient to close gently.
3) The X-ray beam positioned above the patient in the midline and directed downward through the tip of nose at 65°-70° to the film.

B. Upper oblique occlusal:



Image field: This projection shows half of the alveolar ridge of the maxilla, infero-lateral aspect of the antrum, the tuberosity and the teeth from the lateral incisor to the third molar.

Technique involved:

1) The patient's head is aligned with the occlusal plane horizontal and parallel to the floor.
2) Film placed on the occlusal surfaces of the lower teeth with the long axis anteroposteriorly to the side of the mouth under examination and ask the patient to close gently.
3) The X-ray beam positioned at the side of the patient face and directed downward through the cheek of at 65°-70° to the film.

C. Vertex occlusal:

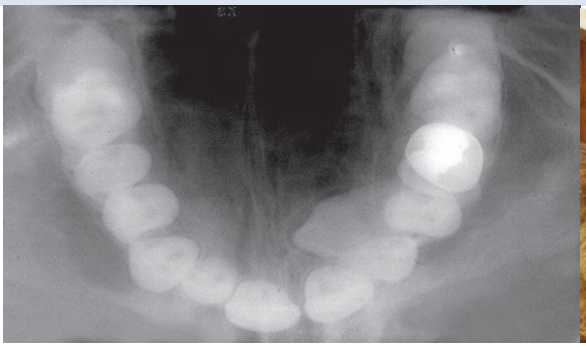


Image field: This projection produces an unusual horseshoe-shaped image, for it depicts all of the maxillary teeth bucco-palatally so it is useful in positioning of unerupted canine bucco-palatally.

Technique involved:

1) The patient's head is aligned with the occlusal plane horizontal and parallel to the floor.
2) Film placed on the occlusal surfaces of the lower teeth with the long axis anteroposteriorly and ask the patient to close gently.
3) The X-ray beam positioned above the patient in the midline and directed downward through the vertex.

Mandibular occlusal projection:

A. Lower 90° occlusal (True lateral):

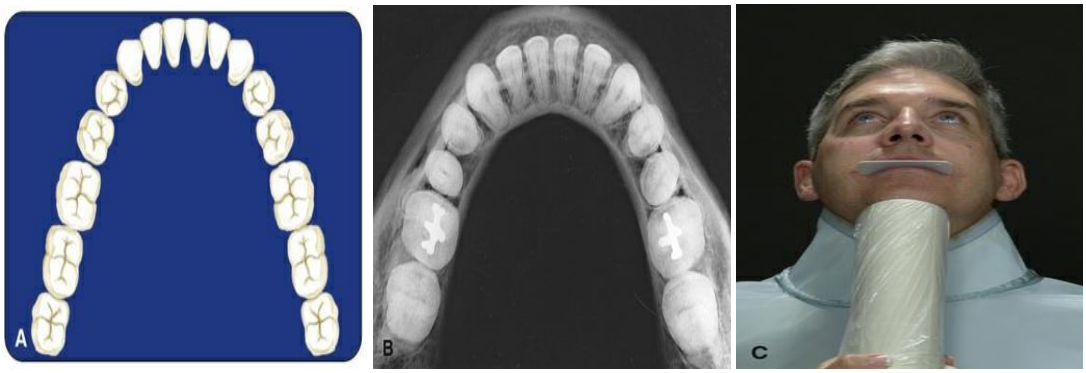

Image Field: This projection includes the soft tissue of the floor of the mouth and reveals the lingual and buccal plates of the mandible from second molar to second molar and also made to examine the floor of the mouth (e.g., for sialoliths).

Technique involved:

1) Patient tips his head backward as far as comfortable, where it is supported.
2) Film placed centrally in to the mouth on the occlusal surfaces of the lower teeth with the long axis crossways and ask the patient to close gently.
3) X- ray tube head placed below the patient's chin in midline centering on imaginary line joining the first molars at 90° to the film.

B. Lower standard occlusal:



Image Field: This projection includes the anterior portion of the mandible, the dentition from canine to canine, and the inferior cortical border of the mandible.

Technique involved:

1) Patient is seated with the head supported and occlusal plane horizontal and parallel to the floor.

2) Film placed centrally in to the mouth on the occlusal surfaces of the lower teeth with the long axis anterioposteriorly and ask the patient to close gently.
3) X- ray tube head placed in midline centering through the chin point at 45° to the film.

C. Lower oblique occlusal:

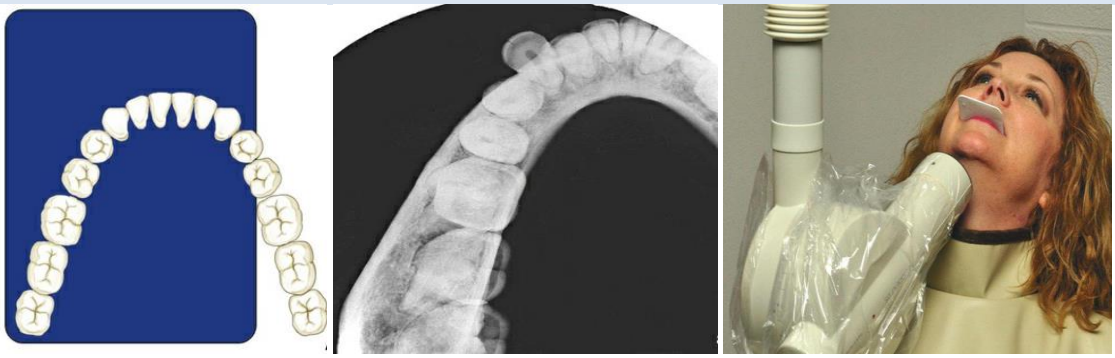

Image field: This projection shows the mandibular salivary gland on the side of the interest.

Technique involved:

1) The patient head is supported and rotated away from the side under investigation and the head is raised.
2) The film placed on the occlusal surfaces of the lower teeth over to the side under investigation with long axis anterioposteriorly then ask the patient to bite gently.
3) X- ray tube directed upward and forward toward the film from below and behind the angle of the mandible and parallel to the lingual surface of the mandible.

Localization technique:

Standard intraoral periapical and bitewing images show the teeth and bone in only two planes: **superoinferior and anteroposterior (mesio-distal) planes**.

However, many clinical situations require a proper radiographic diagnosis to establish the position of structures in the **buccolingual plane**. These are methods used to locate the position of a tooth or an object in the jaws.

Indications:

1) Foreign bodies.
2) Impacted teeth.
3) Unerupted teeth.
4) Retained roots.
5) Salivary stones.
6) Jaw fractures.
7) Broken needles and instruments.
8) Root positions.
9) Filling materials.

Types of localization technique:

1. Right-angle technique
2. Tube shift principle
3. Definition evaluation
4. Use of radio-opaque media (Contrast media)

1. Right angle technique:

Two projections are taken at right angles to each other, which helps to localize an object in the maxilla or mandible.

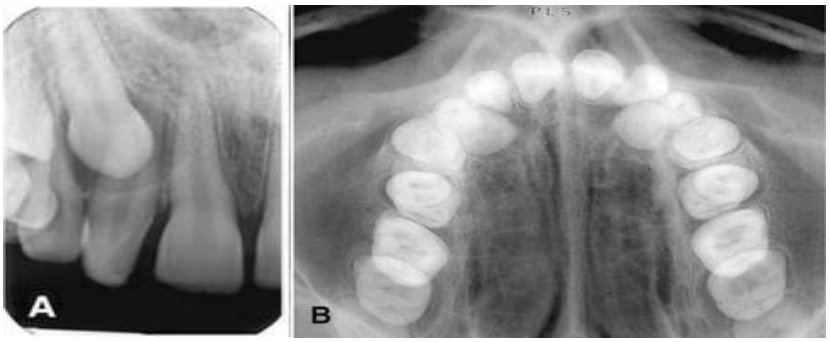

(A) Periapical radiograph shows impacted canine lying apical to roots of lateral incisor and first premolar. (B) Maxillary cross-sectional occlusal view shows that the canine lies palatal to the roots of the lateral incisor and first premolar.

Method:

A **periapical radiograph** is taken to show the position of the object superio-inferior and mesiodistal relationships. Next, an **occlusal radiograph** is taken which will show the mesiodistal and bucco-lingual relationships. The two radiographs when studied together help to localize the object in all three dimensions.

2. Tube shift technique:

Other names for this procedure are the **buccal-object rule, slob rule, and Clark's rule** (Clark described this method in 1910)**, in the horizontal plane**.

Its advantage to the practitioner is that it can be accomplished by using a standard periapical technique to determine the relative **buccolingual relationship between two structures** that appear radiographically superimposed, a second radiograph is taken with a different horizontal angulation (or a horizontal tube shift). All factors remain the same for the second exposure, except that the tube is shifted about **20 degrees** either mesially or distally.

If the tube is shifted mesially by changing the horizontal angulation, the buccal object appears to have moved distally. Conversely, a distal shift results in the more buccal object moving mesially. Furthermore, if on the second radiograph the object does not appear to move after the tube is shifted horizontally, the object is said to be situated in the middle of the jaw.

Now, apply the buccal-object rule. The key phrase is "same lingual, opposite buccal;" the acronym is SLOB. This procedure can also be applied to objects for use in the superior inferior plane.

Method:

In the first radiograph, the object is superimposed over the apex of the second premolar. The x-ray tube head is then shifted and directed from a more 20 degrees mesial angulation. In the resultant radiograph, the image of the object in question has moved mesially with respect to the apex of the second premolar. ***When an object lies lingual to the reference object, its image appears to move in the direction of the tube shift.***

The application of this principle can be easily remembered by the acronym ***SLOB***: *s*ame *l*ingual, *o*pposite *b*uccal. Thus, if the object in question appears to move in the ***same*** direction with respect to the reference structures as does the x-ray tube, it is on the *lingual* aspect of the reference object; if it appears to move in the ***opposite*** direction as the x-ray tube, it is on the *buccal* aspect. If there is not any significant movement of the object, the object is positioned in the middle of the jaw and will not appear to have moved at all.

For example, the mental foramen is often superimposed over the apex of the adjacent premolar, and may mimic a periapical radiolucency. However, the projection of the adjacent radiograph, taken at a different angle, will demonstrate movement of the radiolucency away from the apex, and allows it differentiation from a true periapical radiolucency.



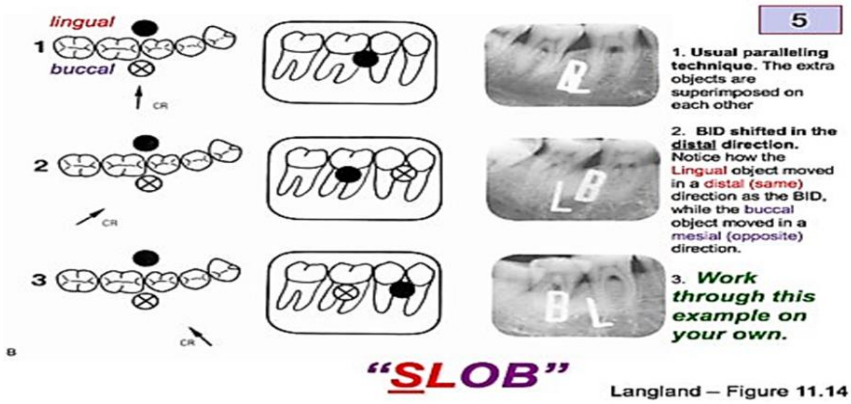

3. Definition Evaluation

Structures that lie closer to the receptor have better radiographic definition than those that are farther from the receptor. This is true for both intraoral and extraoral films.

Because an intraoral receptor is positioned lingually in the patient's mouth, the superimposed structure that is more sharply defined is positioned lingually in relation to the other structures.

An advantage of this technique, when compared with the others that follow, is that it requires no further x-ray exposures of the patient.

It is, however, the least reliable of the techniques mentioned and is not recommended.

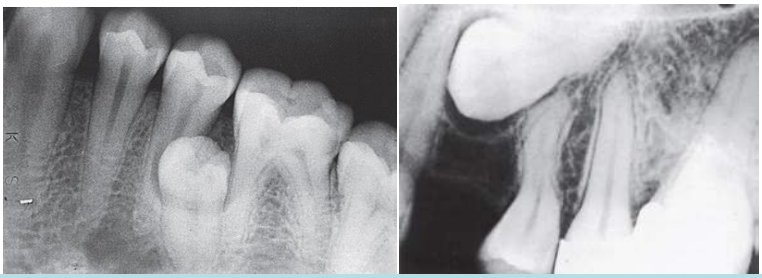

- Localization by definition.
- Is the impacted supernumerary tooth more clearly defined than the rest of the teeth?
- If yes, it is probably positioned lingually.
- If not, it is probably positioned buccally.

4. Use of radio-opaque media *(Contrast media)*:

Barium sulfate, lipiodol and dionosil can be used to demonstrate cavernous areas with hard and soft structures. After the injection of the radio-opaque media (mostly lipiodol) in cyst for example, processed and viewed to see the extension of the cyst. Radio-opaque media used in sialogram to demonstrate salivary glands and their ducts.

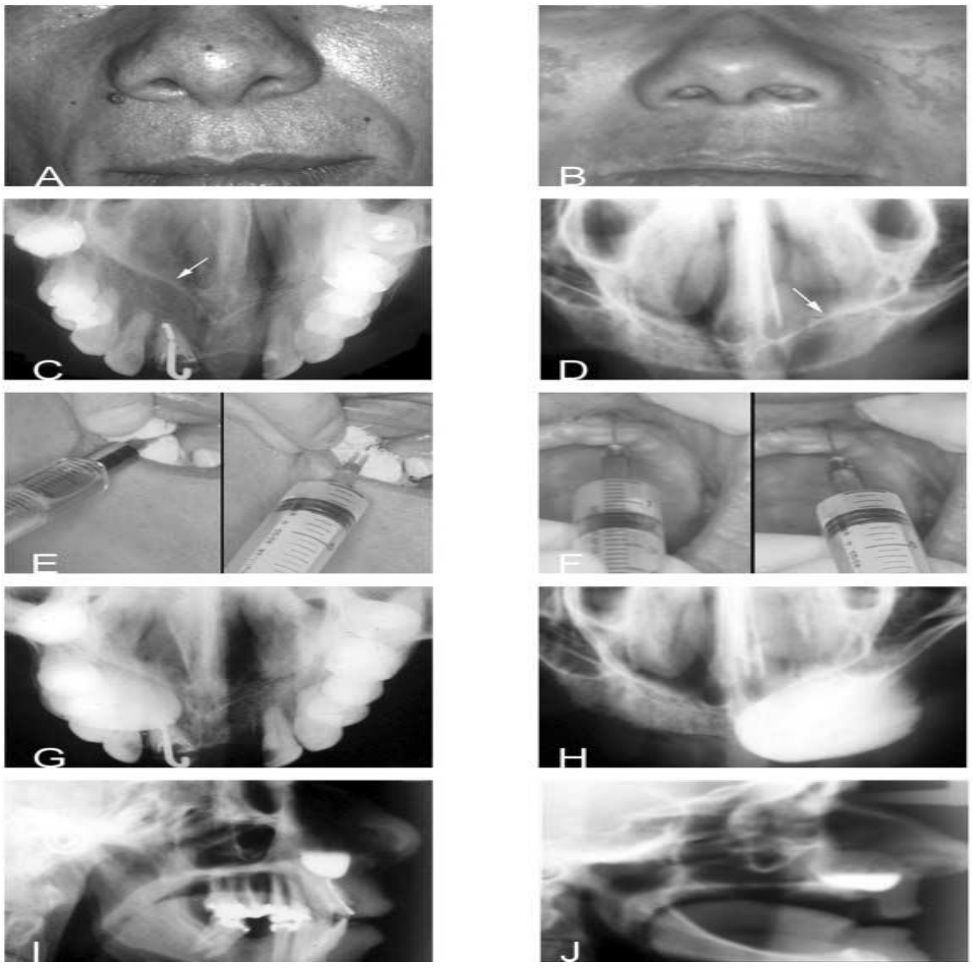

(A) Clinical view of Case 1 with a slight elevation on the right nasal alae. (B) Clinical view of Case 2 with swelling in the region of the left nasolabial fold. Occlusal radiographs with a distortion of the curves of (C) the right and (D) the left anterior lateral wall of nasal cavity (arrow) of Cases 1 and 2, respectively. Clinical manoeuvere of the cystic fluid aspiration and injection of the radiographic contrast medium in Cases (E) 1 and (F) 2. (G, H, I, J.) Radiographic images of the nasolobial cyst with radiographic contrast medium in occlusal and cephalomeric views. A radiopaque oval and kidney shaped image is observed in Cases 1 and 2, respectively.