THE SKULL

Is composed of a number of separate bones united at immobile joint called **sutures. The** connective tissue between the bones is called **sutural ligament.** The mandible is an exception to this rule, for it is united to the skull by the mobile temporomandbular joint. The bone of the skull may be divided into those of the **cranium** & those of the face, the v**ault** is the upper part of the cranium, & the **base of the skull** is the lower part of the cranium. The skull bone are made up of the external & internal tables of compact bone, separated by a layer of spongy bone , called the **diploe. The internal** table is thinner & more brittle than the external table. The bone are covered on the outer and inner surfaces with periosteum; the outer layer is referred to as the **pericranium** , the inner covering as the **endocranium.**

The cranium consists: frontal bone, parietal bone, temporal bone, occipital bone, sphenoid bone & ethmoid bone.

The facial bone consists: zygomatic bone, maxillae, nasal bones, lacrimal bones, vomer, palatine bone inferior conchae and mandible.

Anterior View of the Skull

The frontal bone curve downward to make the upper margins of the orbit. The **supercilliary arches (ridge)** can be seen on either side & the **supraorbital notch** o**r foramen** , medially the frontal bone articulates with the **frontal processes of the maxillae** & with the nasal bones laterally , the frontal bone articulate with the zygomatic bone . The **orbital margins** are bounded by frontal bone superiorly, the zygomatic bone laterally, the maxilla inferiorly, the processes of the maxilla & frontal bone ,medially .within th**e frontal bone**, just above the **orbital margins** ,are two hollow spaces lined with mucous membrane, called the **frontal air sinuses** . The two nasal bones form the bridge of the nose.

Their lower borders, with the maxillae, make the **anterior nasal aperture. The** nasal cavity is divided into two by the bony nasal septum, which is largely formed by the vomer. The **superior and middle conchae** jut into nasal cavity from the ethmoid on each side; the **inferior conchae**

are separate bone .**The two maxillae** form the upper jaw , the anterior part of the hard palate , part of the lateral walls of the nasal cavities, and part of the floors of the orbital cavities . The two bones meet in the midline at the **intermaxillary suture &** form the lower margin of the nasal aperture. Below the orbit the maxilla is perforated by the **infraorbital foramen**. The **alveolar process** projects downward & together with the fellow of the opposite side forms the alveolar arch, which carries the upper teeth. Within each maxilla is large pyramid shaped cavity lined with mucous membrane, called the **maxillary sinus.**

The zygomatic bone forms the prominence of the cheek & part of the lateral wall and floor of the orbital cavity. Medially, it articulates with the maxilla, and laterally, it articulates with the zy**gomatic process of** the temporal bone to form the **zygomatic arch** .

The zygomatic bone is perforated by two foramen for the **zygomatic facial** & **zygomaticotemporal nerve**.
The mandible, consist of a horizontal body & two vertical **rami;** the body joins the **ramus at** angle of the mandible. The **mental foramen** open onto the anterior surface of the body of the mandible below the **second premolar tooth,** the upper border of the mandible, the alveolar part, caries the **lower teeth**.

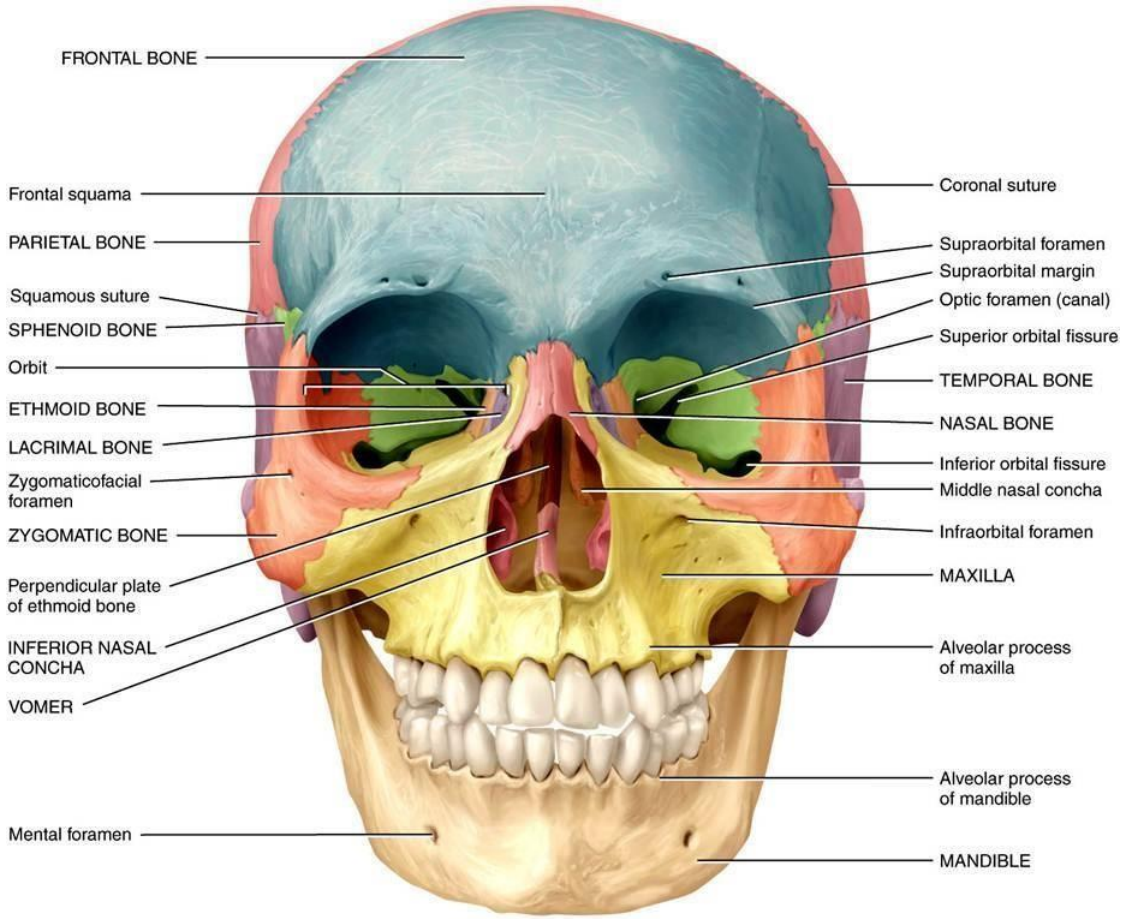

(a) Anterior view

Figure 07.02a Tortora - PHA 11/e
Copyright © John Wiley and Sons, Inc. All rights reserved.

Lateral view of skull

The **frontal bone** forms the anterior part of the side of the skull & articulate with **parietal bone** at **coronal suture.**The **parietal** bone form the sides & roof of the cranium & articulate with each other in the midline at the **sagittal suture** . they articulate with occipital bone behind , at the **lambdoid suture.** The skull is completed from the side by the **squamous part** of the **occipital bone**; part of the **temporal bone**, namely, the **squamous, tympanic, mastoid process, styloid process , & zygomatic process; & great wing of sphenoid bone**

.pterion;the thinnest part of the lateral wall of the skull is where the anterio-inferior corner of the parietal bone articulates with great wing of sphenoid ; clinically the pterion is very important area since it overlies the anterior division of the middle meningeal artery & vein . Its

lies about 1 inch behind the frontal process of zygomatic bone & about 1.5 inch above the zygomatic arch.

The **superior & inferior tempor**al lines which begin as a single line from the posterior margin of the **zygomatic process** of the frontal bone & diverge as the arch backward . **temporal fossa** lie below **the inferior** t**emporal** line the lower limit of the te**mporal fossa** is the **infra-temporal** crest of the great wing of sphenoid bone ,which is level with the upper border of the **zygomatic arch** . The **inferatemporal fossa lies** below the inferatemporal crest on the greater wing of the sphenoid .

The **pterygomaxillary fissure** is a vertical fissure that lies within the fossa between the **ptrerygoid** process the sphenoid bone & back of the maxillait lead medially into the **pterygopalatine fossa.**

The **inferior orbital fissure** is a horizontal fissure between the great wing of the sphenoid bone and the maxilla. It leads forward into the orbit. The **pterygopalatine fossa** is a small space behind & below the orbital cavity.

It communicates laterally with inferatemporal fossa through the pterygomaxillary fissure, medially with the nasal cavity through the sphenopalatine foramen, superiorly with the skull through the **foramen rotundum**, & anteriorly with the orbit through the **inferior orbital fissure.**

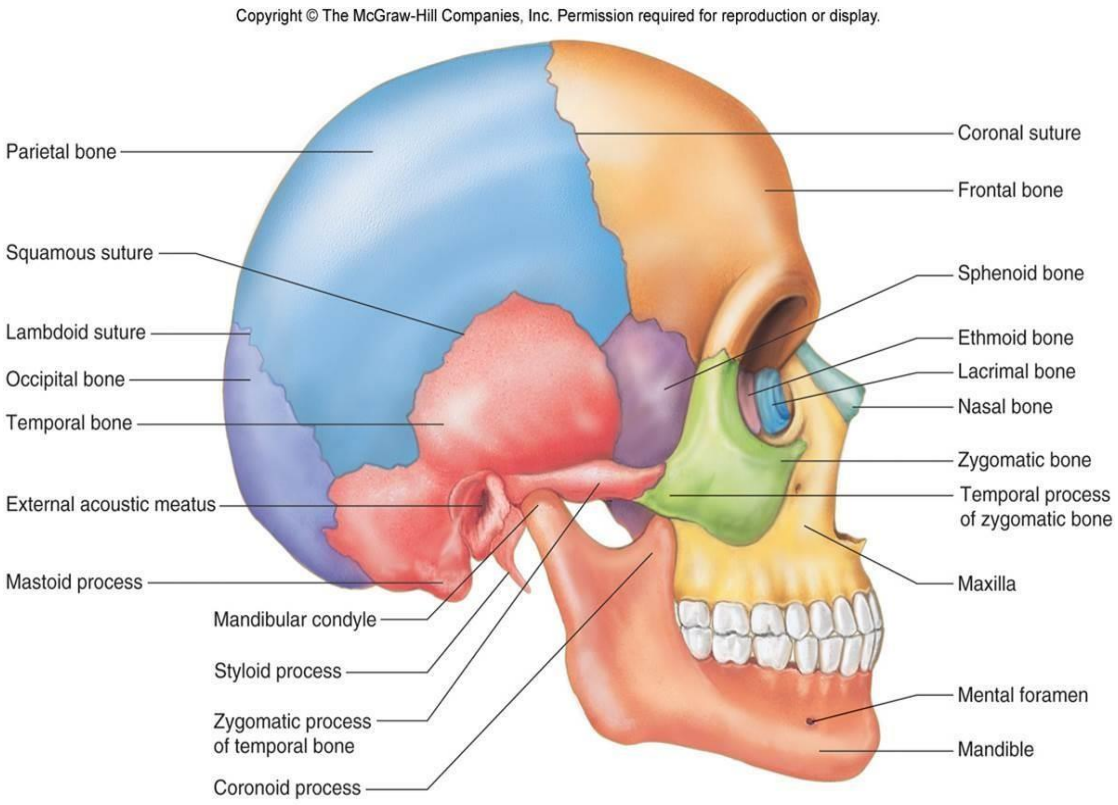

Posterior View of Skull

The posterior parts of the two parietal bone with the intervening**sagittal suture** are seen above. below, the parietal bones articulate with the squamous part of the occipital bone at the **lambdoid suture . on each** side the occipital bone is a roughened elevation called the **external occipital protuberance ,**which give attachment to muscle & ligamentum nuchae . On either side of the protuberance the **superior nuchal lines** extend laterally toward the temporal bone.

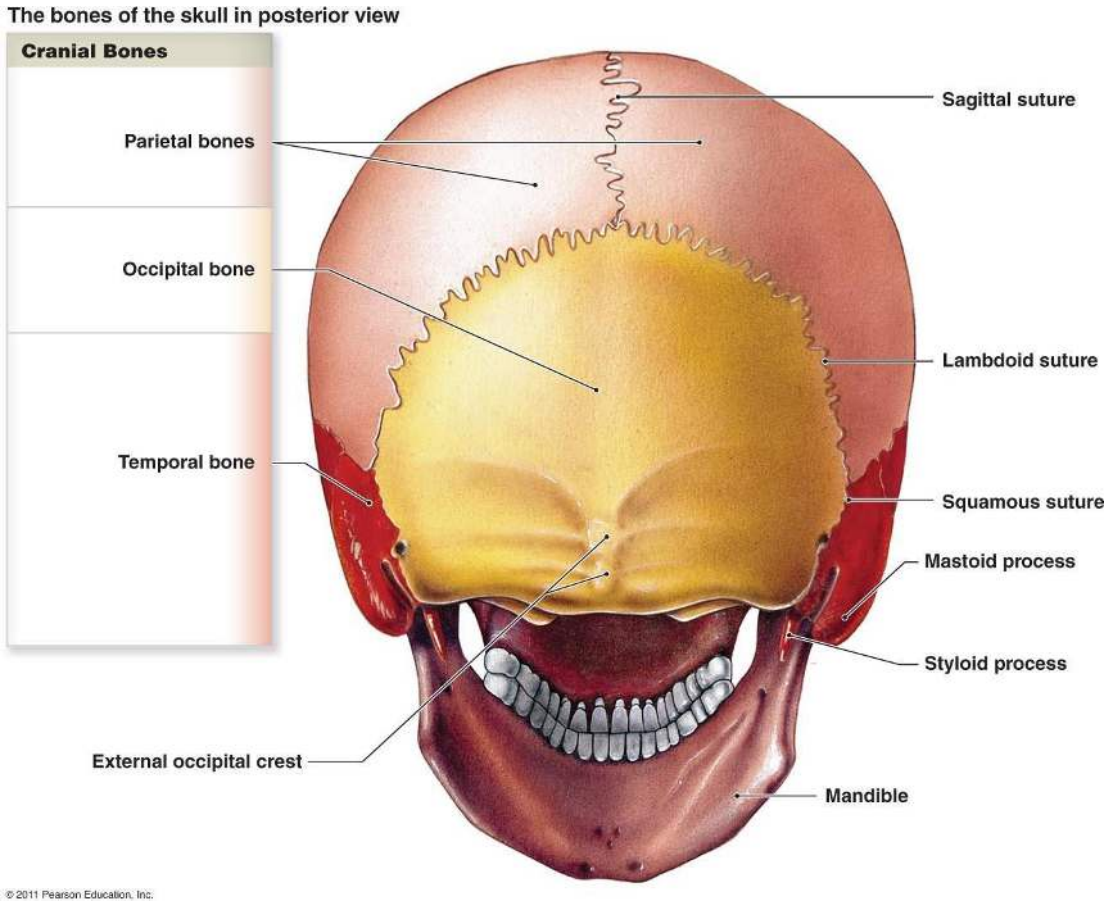

Superior View of Skull

Anteriorly, the frontal bone articulates with two parietal bones at the **coronal suture, occasionally**, the two halves of the frontal bone fail to fuse, leaving a midline **metopic suture.** Behind the two parietal bones articulate in the midline at the **sagittal suture .**the center of the parietal *bone forms a small eminence , the* ***parietal eminence .***

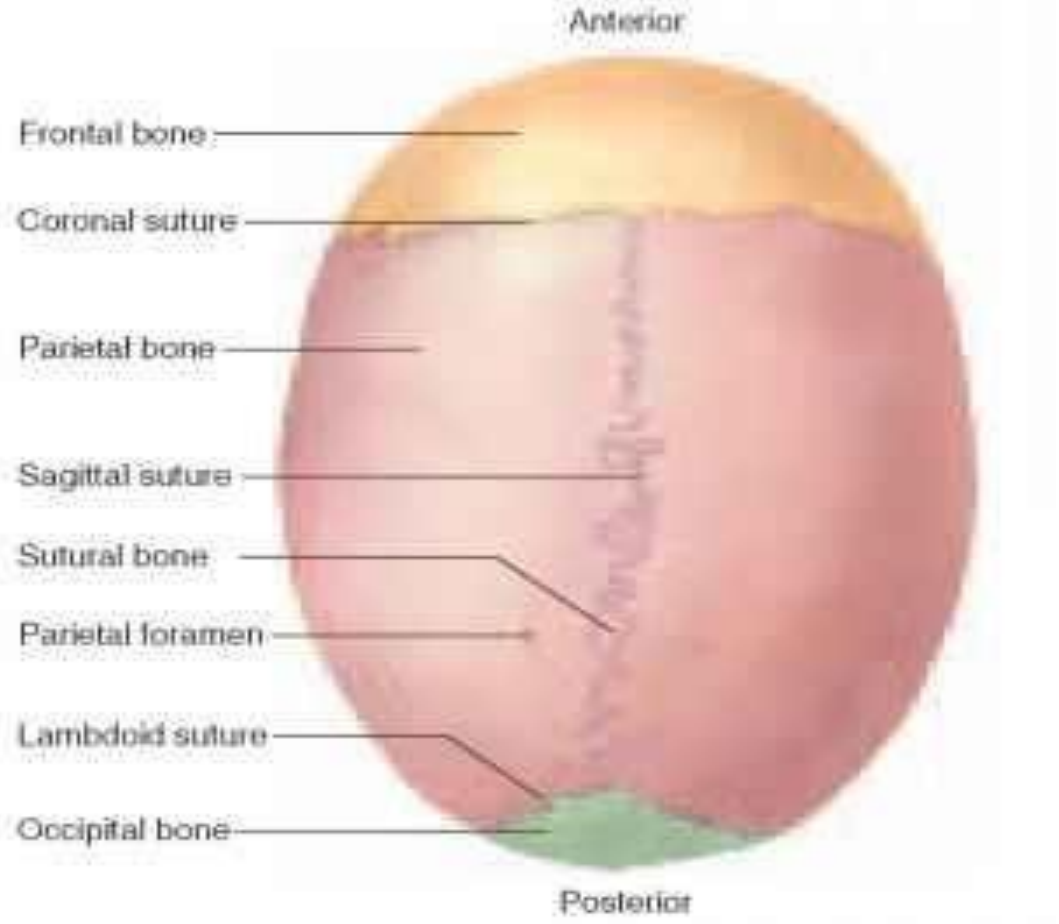

Reference, snell clinical