- **PATIENTS ON RADIOTHERAPY AND CHEMOTHERAPY**
- Cancer could affect any organ of the body such as breast, lung, G.I.T., urinary system, bone, prostate, skin, oral cavity, endocrine system.
- ❖ **Lines of Treatment of Cancers:**
- 1- Surgery
- 2- Radiotherapy
- 3- Chemotherapy
- 4- Combination of The Above Lines.
- 5- Cytotoxic Drugs, Endocrine Drugs.
- **PATIENTS ON RADIOTHERAPY**
- The primary goal of radiotherapy is to destroy and damage the tumor cells, but in fact the normal cells which lies at the line of radiation will be destroyed also and the area that exposed to radiation will be compromised. Radiotherapy of the head and neck region has a direct relation with our job as dentists.

Radiation Effects on Normal Tissues in the Path of the External Beam:

1. MUCOSA (mucositis)

• Epithelial changes (atrophy), causing mucositis.

Mucositis defined as an inflammation of the oral mucosa, results from the direct cytotoxic effects of radiation on rapidly dividing oral epithelium. It develops more often in non keratinized mucosa (buccal and labial mucosa, ventral tongue) and adjacent to metallic restorations by the end of the second week of radiation therapy.







- **2. MUSCLE**
- • Muscular dysfunction; it’s a late complication of radiotherapy it results from Fibrosis and vascular damage of muscles of mastication and limitation in the mouth opening, which should be maintained through physiotherapy.

- The patient also should perform daily stretching exercises to relieve trismus and apply local warm moist heat.

- One exercise is for the patient to place a given number of tongue blades in the mouth at least three times a day for 10-minute intervals. By slowly increasing the number of tongue blades, muscle stretching will occur, and more normal function will ensue








S+M
Surgical & Medical Products
High Quality Wooden
TONGUE DEPRESSORS
250

3. BONE

• Decreased numbers of osteocytes and osteoblasts, decreased blood flow and the patient becomes more susceptible to develop an osteoradionecrosis.

Osteoradionecrosis (ORN) results from radiation-induced (hypocellularity, hypovascularity, and ischemia) in the jaws. **Most cases result from damage to tissues overlying the bone rather than from direct damage to the bone**. Accordingly, soft tissue necrosis usually precedes ORN and is variably present at the time of diagnosis.

Risk is greatest in posterior mandibular sites for patients whose jaws have been treated with in excess of 6500 cGy, and who have undergone a traumatic procedure (e.g., extraction).

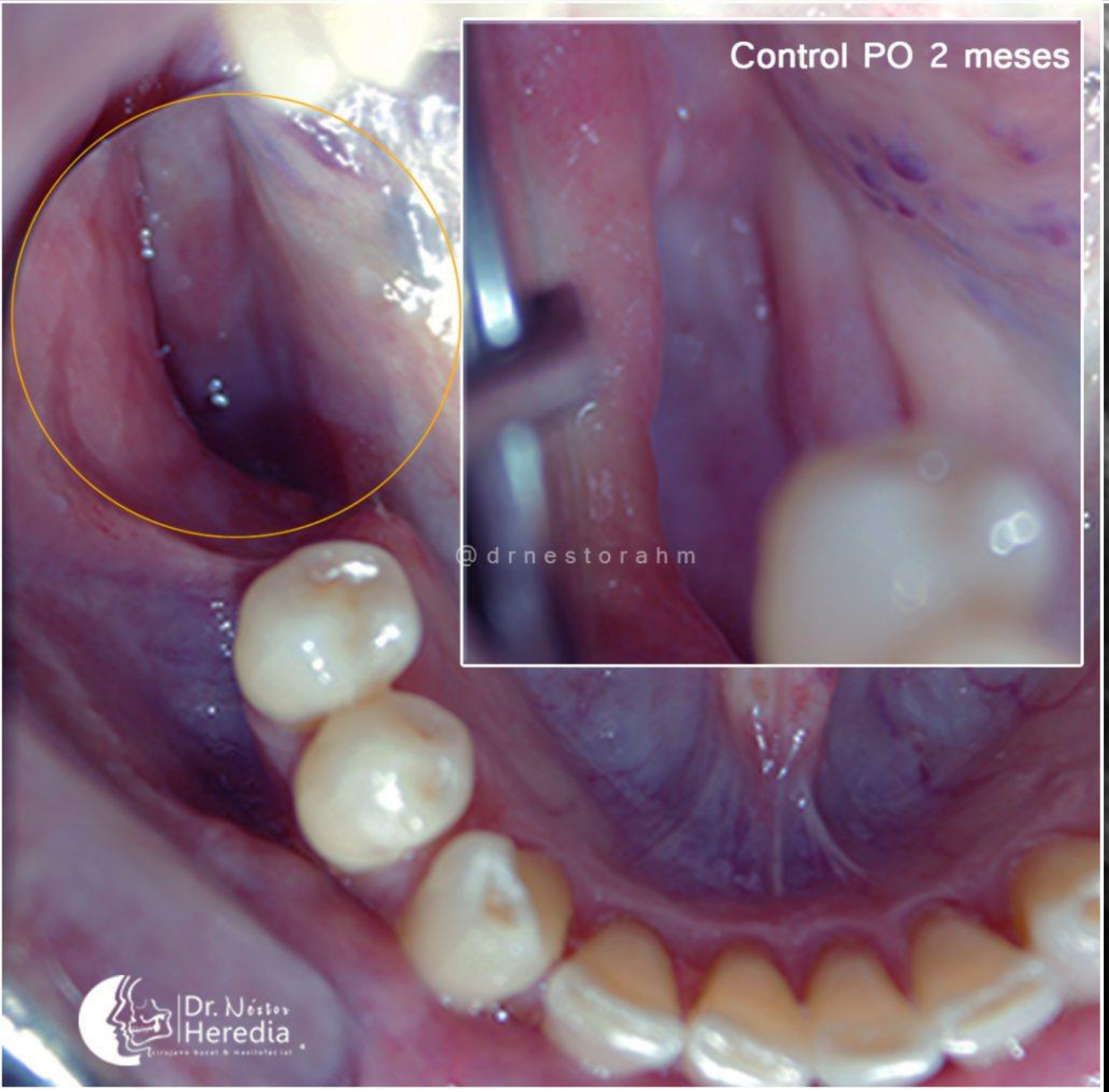
Control PO 2 meses
@drnestorahm
Dr. Néstor Heredia

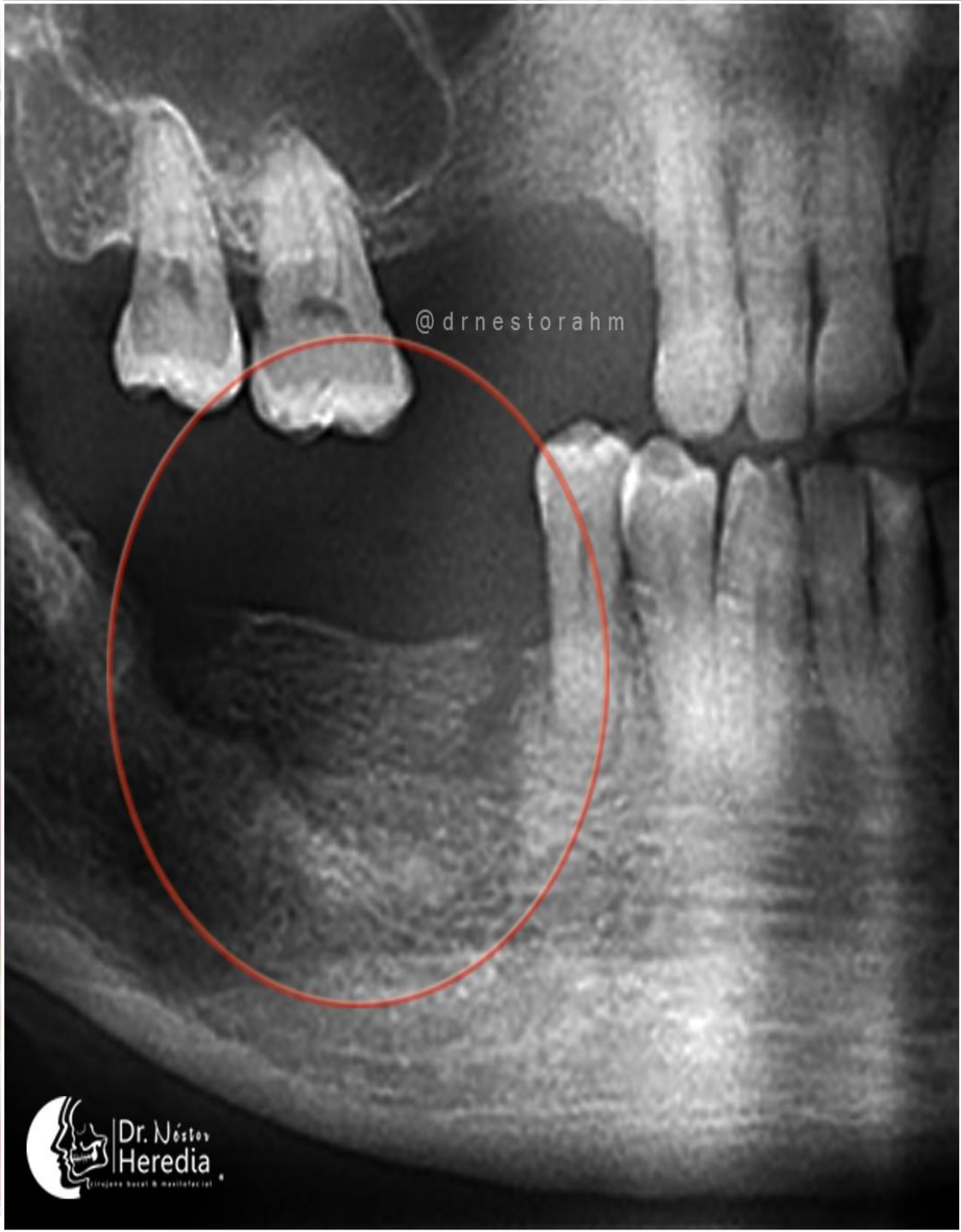
@drnestorahm
Dr. Néstor Heredia

- Risk is greater for dentate patients than for edentulous patients, and periodontal disease enhances risk. Spontaneous ORN also occurs.

- This risk continues throughout a patient's life time.
- **Note:** (the amount of radiation absorbed by the tissue is **called the radiation dose.**



4. SALIVARY GLANDS

• Atrophy of acini, vascular changes and chronic inflammation, fibrosis, leading to xerostomia, due to head and neck radiation therapy. **Management by frequent drinking of water, using salivary substitutes, sugarless chewing gum, lozenges and drugs like parasympathomimetic drugs to stimulate salivary flow**.





5. TEETH

Radiation caries: Radiation caries is estimated to occur 100 times more often in patients who have received head and neck radiation than in normal individuals due to hyposalivation.

It can progress within months, advancing toward pulpal tissue and resulting in periapical infection that extends to surrounding irradiated bone. Extensive infection and necrosis may result.

Management required patient education, oral hygiene instruction, fluoride application and frequent dental visits and early restoration of the teeth. Sensitivity of the teeth increased due to hypo salivation.








b

6. SECONDARY INFECTION

Occurs as a result of immunosuppression and reduced salivary flow, when the WBC count falls below 2000 cell/ml the immune system is less able to manage these infections.





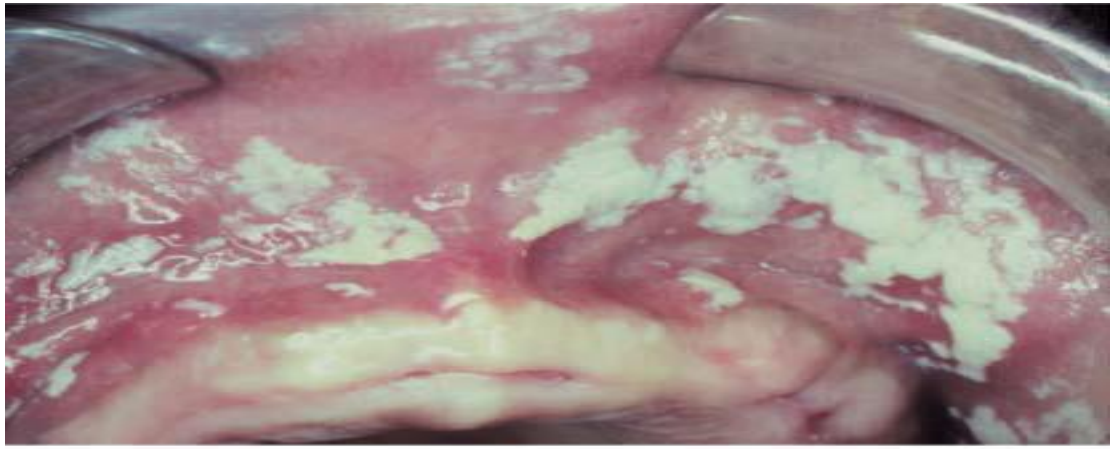

A

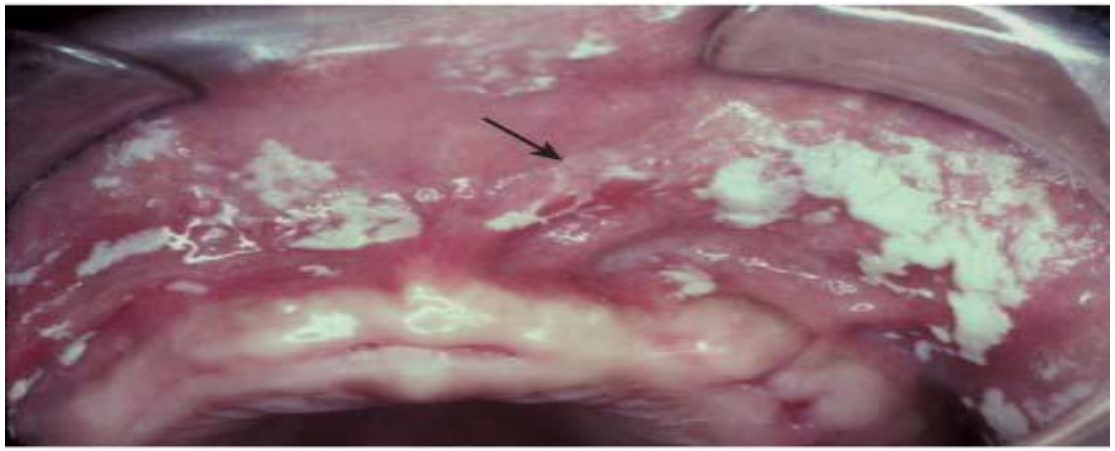

B

- Other effects of radiation include loss of taste result from damage of the microvilli of taste cells, the patient complain of bitter test, most of the patient will restore taste within 3-4 months after therapy.

- Zinc supplementation is reported to improve taste sensation (zinc sulfate).

DENTAL MANAGEMENT:

A. Prior to Radiotherapy:

1. **Symptomatic non vital teeth should be endodontically treated** at least 1 week before initiation of head and neck radiotherapy. However, dental treatment of asymptomatic teeth even with periapical involvement can be delayed.

2. Teeth which are indicated for extraction should be extracted

- **Indications of extraction:**
- i. Non restorable teeth with poor or hopeless prognosis, acute infection, or severe periodontal disease that may predispose the patient to complications (e.g., sepsis, osteoradionecrosis) should be extracted.
- ii. **Presence of periapical inflammation**
- **iii. Broken-down, non-restorable, non-functional, or partially erupted tooth in a patient who is noncompliant with oral hygiene measures.**
- **iv. Patient lack of interest in saving tooth/teeth**
- **v. Inflammatory (e.g., pericoronitis), infectious, or malignant osseous disease associated with questionable tooth**

3. The Guidelines for extraction of teeth:

- Perform extraction with minimal trauma
- At least 2 weeks, ideally 3 weeks before initiation of radiation therapy to get enough time for healing.
- Trim bone at wound margins to eliminate sharp edges
- Obtain primary closure.
- Avoid intra-alveolar hemostatic packing agents that can serve as a nidus of microbial growth.

4. Teeth **scaling and prophylaxis** should be provided before radiotherapy is initiated.

5. Patients who will be retaining their teeth and undergoing head and neck radiation therapy must be **informed about problems** associated with decreased salivary function, which include xerostomia, the increased risk of oral infection, including radiation caries, and the risk for osteoradionecrosis.

B. During Radiotherapy:

1. Symptomatic treatment of mucositis: The treatment of mucositis involve:

1) Oral mucositis can be reduced by using oral cryotherapy, low-level laser therapy, systemic analgesics, and supplemental zinc.

2) Eliminate any irritating factor such as a sharp edge; and establish good oral hygiene.

3) Recommend a salt and sodium bicarbonate mouthwash

4) Topical anesthetics (viscous lidocaine 0.5%) and/or an antihistamine solution [Tantum rinse], diphenhydramine [Benadryl], promethazine [Phenergan]) to provide pain control

5) Antimicrobial rinses such as chlorhexidine 0.12% mouth wash.

- 6) Prescribe anti-inflammatory agents (e.g., topical steroids).
- 7) Avoid tobacco, alcohol and irritating foods.
- 8) Oral lubricants and lip balms with a water base, beeswax base, or vegetable oil base
- 9) Humidified air (humidifiers or vaporizers);
- 10) Follow a soft diet; maintain hydration.
- 11) Consider systemic antimicrobials, if severe.

2. Management of xerostomia:

Recommend sugarless lemon drops, sorbitol-based chewing gum, buffered solution of glycerine, salivary substitutes and plenty of water and other fluids (sip drinks constantly to keep the oral mucosa moist; such drinks should not be products containing a fermentable carbohydrate or carbonic acid) and avoid the diuretics such as coffee or tea.

3. Prevention of trismus by having the patient place tongue blades or Mouth blocks each day to maintain mouth opening.

4. Diagnosis and treatment of secondary infections that developed during radiation. Because of the quantitative decrease that occurs in actual salivary flow, and because of compositional alterations in saliva, several organisms (bacterial, fungal, and viral) may opportunistically infect the oral cavity.

Candidiasis is best managed with the use of topical oral antifungal agents, these include nystatin (oral suspension 100,000 international units [IU]/mL 4 to 5 times daily) and clotrimazole (Mycelex lozenges 10 mg five times a day).

Prophylactic use of antifungal agents may be required in patients undergoing chemotherapy who have frequent recurrent infections. Ketoconazole (Nizoral), fluconazole (Diflucan), or itraconazole (Sporanox) may be used if systemic therapy is warranted or if patients develop unusual oral fungal infections.

Recurrent herpes simplex virus (HSV) eruptions are infrequent during radiation therapy.



DOSAGE: Each troche must be slowly dissolved in the mouth.

See Package Insert for Complete Prescribing Information.

Dispense in tight, child-resistant container as defined in the USP/NF.

Store at 20° to 25°C (68° to 77°F). [See USP Controlled Room Temperature.]

Avoid freezing.

NDC 0054-**4146**-22 70 Troches

Clotrimazole Troche (lozenges) USP

10 mg

Each troche contains 10 mg clotrimazole USP.

[1-(o-chloro-α, α-diphenylbenzyl) imidazole].

℞ only

WEST-WARD
A HIKMA COMPANY

Distr. by: **West-Ward Pharmaceuticals Corp.**
Eatontown, NJ 07724

N 3 0054-4146-22 7

10001775/07







5. Fluoride application to prevent sensitivity of teeth and to prevent caries.

6. Instruct the patient for **oral hygiene measures.**

7. Dentures should not be worn until the acute phase of mucositis has resolved. Dentures should be cleaned and soaked with an antimicrobial solution daily for the prevention of infection.

C. Following Radiotherapy:

1. Consultation with the physician to determine whether the patient is cured or in remission or is completing palliative care.

2. The patient should be examined every 1 to 3 months during the first 2 years, every 3 to 6 months thereafter and after 5 years examined at least once per year, to check the oral hygiene and treatment of initial caries and management of xerostomia.

3. Management of xerostomia as mentioned before. **The manifestations of salivary hypofunction in patients having undergone radiation therapy for head and neck cancer include severe salivary hypofunction (unstimulated salivary flow <0.2 mL/min), mucositis, cheilitis, glossitis, fissured tongue, glossodynia, dysgeusia, dysphagia, and a severe form of caries called radiation caries.**

4. Prevention of osteoradionecrosis:

A. Avoid the extraction of teeth as much as possible

Endodontic therapy is preferred over extraction (assuming the tooth is restorable).

B. If the extraction is unavoidable, then it should be done **with the following precautions**:

I. It is better to use local anesthesia **without adrenaline**.

II. Give the patient a **prophylactic dose** of antibiotic before and after the extraction i.e amoxicillin 2g one hour before extraction, then continue with amoxicillin 500mg 3-times daily for one week.

III. **Atraumatic procedure**.

- Follow atraumatic surgical technique.
- Avoid periosteal elevations in order to maintain a good blood supply to the bone.
- Limit extractions to two teeth per quadrant per appointment.
- Irrigate with saline, obtain primary closure, and eliminate bony edges or spicules.

IV. The use of **hyperbaric oxygen therapy** before and after the tooth extraction.

Hyperbaric oxygen therapy is administration of oxygen under pressure to the patient, this process will increase the local tissue oxygenation and vascular ingrowth into the hypoxic tissue

- **The usual protocol for such treatments is to have 20 hyperbaric oxygen therapy dives before extraction and 10 more dives immediately after extraction.**
- **The patient usually undergoes one hyperbaric oxygen therapy each day, therefore it takes 4 weeks before surgery and 2-weeks of treatment after surgery.**





Contraindications to Hyperbaric Oxygen Therapy

Chronic sinusitis
Congenital spherocytosis
Emphysema with CO_2 retention
History of optic neuritis
History of reconstructive ear surgery
History of spontaneous pneumothorax
History of thorax surgery
Pulmonary lesions in routine X-ray or CT scan
Seizure disorders
Sickle cell anemia
Uncontrolled high fever
Upper respiratory infections
Viral infections

http://www.aurorahealthcare.org/services/hyperbaric/faq.asp

5. Maintain **good oral hygiene.**

- Use oral irrigators.
- Use antimicrobial rinses (chlorhexidine)
- Use daily fluoride gels.
- Eliminate smoking.
- Attend frequent postoperative recall appointments

6. If the patient developed osteoradionecrosis:

Once necrosis occurs, conservative management usually is indicated. Exposed bone should be irrigated with a saline or antibiotic solution, and the Bony sequestra should be removed to allow for epithelialization. If swelling and suppuration are present, broad-spectrum antibiotics are used.

Severe cases benefit from hyperbaric oxygen (60- to 90-minute dives 5 days per week, for a total of 20 to 30 dives). Cases that do not respond to conservative measures may require surgical resection of involved bone.

- **PATIENTS ON CHEMOTHERAPY:**

- Chemotherapeutic drugs used in treatment of malignancies, based on their ability to destroy or retard the division of rapidly proliferating tumor cells, unfortunately, normal host cells that have a high mitotic index are also adversely affected, especially the epithelium of the G.I.T. (including the oral cavity) and the cells of the bone marrow.

- **The Effect Of Chemotherapy On Normal Tissues:**

- **1. Oral Mucosa**
- It reduces the turn over rate of oral epithelium, this leads to atrophic and ulcerative mucosal surface.
- **2. Hematopoietic system**
- Myelosupression, appear within two weeks and that manifested by:
- I. leucopenia and, neutropenia, that leads to the development of an opportunistic infections as viral, bacterial, fungal(candida). Systemic infections are responsible for about 70% of deaths in patients receiving chemotherapy.

II. Thrombocytopenia, so that Gingival bleeding and submucosal hemorrhage as a result of minor trauma (e.g., tongue biting, tooth brushing) can occur when the platelet count drops to below 50,000 cells/mm^3.

Palatal petechiae, purpura on the lateral margin of the tongue, and gingival bleeding/oozing are common features.

Gingival hemorrhage is aggravated by poor oral hygiene.








Petechiae
(1 – 2 mm)
Purpura
(≥ 3 mm)
Ecchymosis
(> 1 – 2 cms)





- Recurrent herpes simplex virus infection presenting as a large ulcer on the palate of a patient undergoing chemotherapy.

DENTAL MANAGEMENT:

I. Prior to chemotherapy:

A thorough clinical and radiographic examination, and all sources of oral infection should be eliminated, as follow:

1. Symptomatic nonvital teeth should be endodontically treated at least 1 week before initiation of chemotherapy.

2. Teeth which are indicated for extraction should be extracted

(indications of extraction)

i- Non-restorable teeth with poor or hopeless prognosis, acute infection, or sever periodontal disease that may predispose the patient to complications (e.g., sepsis) should be extracted.

ii- Partially erupted or Tooth is associated with an inflammation(e.g., pericoronitis).

iii- Patient has no interest in saving tooth/teeth

3. The guidelines for extraction of teeth:

- Perform extraction with minimal trauma
- Ideally one week before initiation of chemotherapy
- Trim bone at wound margins to eliminate sharp edges
- Obtain primary closure
- Avoid intra-alveolar hemostatic packing agents that can serve as a nidus of microbial growth.

4. Tooth scaling and prophylaxis should be provided before chemotherapy is initiated.

5. In children undergoing chemotherapy, mobile primary teeth and those expected to be lost during chemotherapy should be extracted, and gingival opercula should be evaluated for surgical removal to prevent entrapment of food debris and causes an infection.

6. Orthodontic bands should be removed before chemotherapy is began.

II. During the chemotherapy:

1- The dentist should be familiar with the patient's WBC count and platelet status before providing dental care. In general, emergency dental procedures can be performed if the **granulocyte count is greater than 2000/mm3**, and the **platelet count is greater than 50,000/mm3**. and the **patient feels capable of withstanding dental care**.

2- Provide routine care 17- 20 days after chemotherapy or few days before the start of the second chemotherapy cycle. and you have to avoid routine dental care during the chemotherapy

- **if the patient needs an emergency treatment, it can be done taking these points in consideration:**
- a. If urgent care is needed and the platelet count is below 50,000/mm 3, consultation with the patient's oncologist is required. Platelet replacement may be indicated if invasive or traumatic dental procedures are to be performed.
- b. If urgent dental care is needed and the granulocyte count is less than 2000 cells/mm 3, consultation with the physician is recommended and antibiotic prophylaxis should be provided.
- This prophylaxis starting at least 1 hour before any invasive procedure that involves bone, pulp, or periodontium i.e amoxicilline 2g one hour before extraction, then continue with amoxicilline 500mg 3-times daily for at least 3 days.

3- Topical therapy that includes the use of pressure, thrombin, microfibrillar collagen, and splints may be required.

4- Treatment of oral infections:

The organism that most frequently opportunistically infects the oral cavity in individual undergoing cancer therapy (who have hyposalivation and immunosuppression) is Candida albicans.

Candidiasis is best managed with the use of topical oral antifungal agents. These include nystatin (oral suspension 100,000 international units [IU]/mL 4 to 5 times daily).

Recurrent herpes simplex virus (HSV) eruptions occur often during chemotherapy if antiviral agents are not prophylactically prescribed.

A daily dose of at least 1 g acyclovir/equivalent is needed to Suppress HSV recurrences.


HEMATOLOGY TEST RESULT
Acyclovir
Medication
800 mg
For oral use
28
tablets
Rx only
PHARMACIST: dispense with patient information leaflet provided separately


Valaciclovir
film-coated tablets
POM
1000 mg
For Oral Use
TAJ PHARMA


RelonChem
Aciclovir 5% w/w Cream 10g
Contains 5% w/w aciclovir


Acyclovir 5%

- **III. After chemotherapy:**
- After chemotherapy has been provided, consultation with the physician is recommended to determine whether the patient is cured or not, if cancer therapy has been completed and remission or cure is the outcome, the patient with cancer should be placed on an oral recall program.
- Usually, the patient is seen once every 1 to 3 months during the first 2 years and at least every 3 to 6 months thereafter. After 5 years, the patient should be examined at least once per year.

This recall program is important for the following reasons:

- **A patient with cancer tends to develop additional lesions**
- **Latent metastases may occur**