4th Grade **Prosthodontics**

Preparation of the Mouth to Receive a RPD

Evaluation of a patient's existing intraoral conditions for a removable partial denture prosthesis is an essential part of treatment planning.
The patient needs may be divided into the primary disciplines of dentistry: Surgery, Periodontics, Endodontics, Prosthodontics, and Orthodontics.
Surgically, the teeth, bone, and soft tissues should be evaluated to determine the need for surgical intervention.
Surgical considerations include:
(1) Structurally compromised teeth that may require extraction,
(2) Malposition or supraerupted teeth that may require extraction,
(3) Enlarged tuberosity that may require soft - or hard - tissue reduction,
(4) Exostoses and tori that may require removal or alveoloplasty, and
(5) Displaceable tissue, hyperplastic tissue, or an epulus that may require excision.
The periodontal status of the patient should be evaluated with regard to periodontal disease and plaque control. Periodontal disease control should be initiated when appropriate prior to the initiation of the definitive prosthodontic treatment.

As part of the evaluation process of the remaining teeth, a decision should be made with regard to the appropriateness of salvaging teeth through the use of endodontics. For example, an extruded or supraerupted tooth may be saved from extraction through endodontic therapy, reduction of the occlusal surface to realign the tooth into the proper plane of occlusion, and a crown.

Evaluate the mouth from a prosthodontic perspective, including caries detection and identifying defective restorations, structurally compromised teeth, occlusal plane discrepancies, malocclusion, and need for modification. Occasionally teeth may need to have crowns placed to correct these problems. In addition, during the surveying process of treatment planning for removable partial denture design, teeth should be evaluated for

acceptable crown contours, and the need for enameloplasty to correct tooth contours, create rest seats, and develop guide planes.

Tooth modification may be both subtractive as well as additive.
In addition to the tooth modification discussed above, surveyed crowns may be fabricated from gold and metal ceramic materials that have the desired modifications incorporated in them.
Preparation of mouth for RPD. It forms the second phase of treatment, the term of mouth preparation includes all procedure done to modify the existing oral condition of the patient to facilitate proper placement and functioning of the prosthesis.
Preparation of mouth for RPD include two parts

1. Preprosthetic mouth preparation: - done to remove any hindrance into the prosthetic treatment. Also done along with diagnosis and treatment planning.
2. Preprosthetic mouth preparation: is done to facilitate prosthetic treatment and done after partial denture design.

PREPROSTHETIC PROCEDURES

a. Relief of pain & infection.
b. Oral surgical procedures.
c. Conditioning of abused & irritated tissue
d. Periodontal therapy.
e. Correction of occlusal plane.
f. Orthodontic correction.
g. Splinting weakened teeth.
h. Reshaping teeth.
i. Preparation of rest and guiding planes

The Relief of pain & infection, the following condition should be treated in this phase of mouth preparation:

- Potential emergency condition like acute pain,abscess etc.
- Carious teeth with pain and discomfort.
- Asymptomatic teeth with deep carious lesions are excavated and filled with an intermediate restorative materials.

- Gingival disease like ANUG, AHGS, Gingival abscess etc.
- Calculus and plaque accumulation should be removed and preventive dental hygiene programs should be initiated and mentioned.

Oral surgical preparation.

The longer the time between surgery and impression procedure, the more complete the healing and consequently the more stable the denture bearing area. A variety of oral surgical technique can prove beneficial to the clinician in preparing the patient for pre prosthetic replacements.

The most common oral condition or changes in which surgical intervention indicated are:

- Extraction of teeth with poor prognosis
- Removal of residual roots.
- Extraction of impacted teeth **:**All impacted teeth should be considered for removal .this applies equally to the impaction in edentulous area ,as well as to those adjacent to abutment teeth
- Severely mal posed teeth the loss of individual teeth or group of teeth may lead to extrusion, mesial drifting, or combinations of mal positioning of remaining teeth. In most instances the alveolar bone supporting extruded teeth will be carried occlusaly as the tooth continues to erupt. Orthodontics may be useful in correction many occlusal discrepancies. But for some patients, such treatment may not be practical because of lack of teeth for anchorage of the orthodontics appliance or for other reasons. In such a situation individual teeth or groups of teeth and their supporting alveolar bone can be surgically repositioned. This type of surgery can be accomplished in an outpatient setting and should be given serious consideration.

EXTRACTION OF TEETH

- ❖ Planed extractions should occur early.
- ❖ Each tooth must be evaluated concerning its strategic importance and its potential contribution to the success of the RPD.
- ❖ The extraction of non-strategic teeth that would present complications or those whose presence may be detrimental to the design of the partial denture is a necessary part of the overall treatment plan.

Removal of Residual roots

- Generally, all retained roots or root fragments should be removed .This is particularly true if they are in close proximity to the tissue surface or if there is evidence of associated pathology.
- Residual roots adjacent to abutment teeth may contribute to the progression of periodontal pockets and compromise the result from sub sequent periodontal therapy

Indication for extraction:-

a. Where teeth can complicate /compromise the treatment.
b. Orthodontic treatment cannot correct mal alignment.
c. When teeth interfere with placement of a major connector.

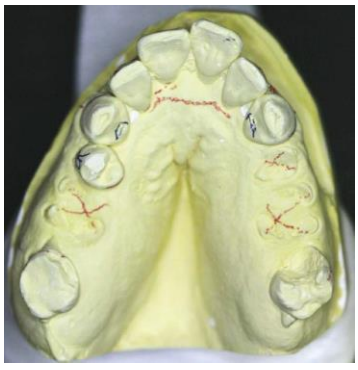

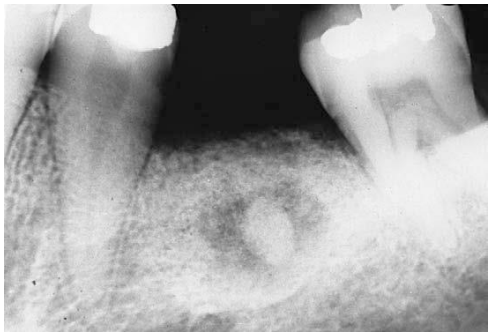

Cyst and odontogenic tumor.

The diagnosis may appear obvious from clinical and radiographic examinations the dentist should confirm that diagnosis through appropriate consultation and if necessary biopsy the area and submit the biopsy to pathologist.

Exostosis and tori.

Ordinarily the mucosa covering bony protuberance (Exostosis and tori) is extremely thin and friable. Patients' denture components in proximity to this type of tissue may cause irritation and chronic ulceration. Although





modification of denture design can, at time, accommodate for exostosis more frequently this result in additional stress to the supporting elements and compromised function. Surgical removal of tori bony exostosis can be done.

Hyperplasic tissue.

Hyperplasic tissues are seen in the form of fibrous tuberosity, soft tissue, fold of redundant tissue in the vestibule or floor of the mouth and palatal pappilomatosis. All these forms of excess tissue should be removed surgically .Always some form of surgical stent considered for these patients so that the period of healing will be more comfortable.



Muscle attachment and freni

As a result of the loss of alveolar bone height, muscle attachments may insert in or near the alveolar crest. The mylohyoid, buccinators, mentalis and genioglossus muscle are those most likely to introduce problem of this nature beside that the attachments of the muscles themselves, the mentalis and genioglossus muscles occasionally produce bony protuberance at their attachment that may also interfere with partial denture design .The comfort and function of the RPD can enhanced through repositioning of attachment especially mylohyoid muscle however repositioning of genioglossus muscle is more difficult to reposition. The maxillary labial and lingual freni are more probably to most frequent source of frequent interference with denture design.

Bony spine and Knife edge ridge

Sharp bony spicules should be removed and knife like crest gently rounded. These procedures should be carried out with minimum bone loss if, however, the correction of a knife edge alveolar crest results in insufficient ridge support for the denture base, the dentist should restore the vestibular deepening for correction of the deficiency polyps, papillomas and All abnormal soft tissue lesions should be excised and submitted for pathologic examination before the fabrication of RPD.

Hyperkeratosis, erythroplasia and ulceration

All abnormal white, red, or ulcerative lesions should be investigated regardless of their relationship to proposed denture base framework.

Dentofacial-deformity

A patient with Dentofacial deformity may have multiple missing teeth. Correction of the jaw deformity can simplify the dental rehabilitation. Surgical correction can be made in horizontal, sagittal or facial planes.

Mandible and maxilla may be positioned anteriorly or posteriorly, and their relationship to the facial planes may be surgically altered to achieve improved appearance. Replacement of missing teeth and development of a harmonious occlusion are very difficult in treating those patients

Osseo integrated devices

A number of implant device for replacement of teeth have been introduce. Titanium implant was designed to provide a direct titanium-to bone interface(Osseo integrated).The implant are placed using clean &controlled oral surgical procedure and are allowed to heal before surgical exposure and fabrication of a dental prosthesis.







Augmentation of alveolar bone

Hydroxyl appetite has been used as a material for augmentation of deficient alveolar bone, this material display a lack of toxicity and demonstrates no inflammatory or foreign body responses. This material provide increase in ridge width and height and also provide a matrix for new bone formation .it also non resorbable.

Conditioning of abused and irritated tissues

Should be treated before impression making → the tissue contour may change according to tissue healing.

<u>Causes</u>

a. ill-fitting dentures,

b. nutritional disturbances,

c. Diabetes

d. Blood dyscrasia.

Symptoms

→ Inflammation and irritation of soft tissues in the denture bearing areas.

→ Distortion of normal anatomical structures like incisive papillae, rugae, and retromolar pads.

→Burning sensation in the residual ridge, tongue, cheeks and lips

These conditions are usually associated with ill-fitting or poorly occluded RPD. So these conditions should be treated before relining or making a new RPD.





<u>The treatment procedure includes good home care by:</u>

- Rinsing the mouth three times daily with prescribed saline solutions
- Massaging the residual ridge area, palate and tongue with a soft tooth brush
- Removing the prosthesis at night
- Using a prescribed therapeutic multiple vitamins along with a prescribed high protein low carbohydrate diet.

MAXIMIUM BENEFIT FROM USING TISSUE CONDITIONING MATERIAL By:-

- Eliminating deflective or interfering occlusal contact of old dentures

- Extending denture base to proper form to enhance support, retention and stability.
- Relieving the tissue side of denture base sufficiently (2mm) to provide space for even thickness and distribution of the material.
- Applying the material in amount sufficient to provide support and a cushioning effect.
- Following manufacturer directions.

The conditioning procedure should be repeated until the supporting tissue display an undistorted and healthy appearance

Uses of tissue conditioning material

These are elastopolymers that continue to flow for extended period of time permitting distorted tissue to rebound and assume their normal form, these materials apparently have a smoothing effect on irritated mucosa and because they are soft, occlusal forces are probably more evenly distributed

Periodontal preparation

This procedure is over formed simultaneously with the oral surgical procedure It should completed before restorative procedure, because the success of this restoration depend on the health and integrity of the supporting structure of the remaining teeth .therefore ,the periodontal health of the teeth especially the abutments must be evaluated and corrective measures taken before RPD construction

Abutment teeth preparation

After several steps of mouth preparation of RPD construction (surgery, periodontal treatment, endodontic and tissue conditioning). The abutment teeth may be prepared to provide support, stabilization. Reciprocation and retention for RPD.

Classification of abutment teeth preparation

- Those abutment teeth that require only minor modification to their coronal portion.

- Those that are to have restoration other than crowns.
- Those that are to have crowns.

<u>The sequences of abutment tooth preparation on sound enamel or existing restoration are as follow:-</u>

- Proximal surface parallel to the path of placement should be prepared to provide guiding planes.

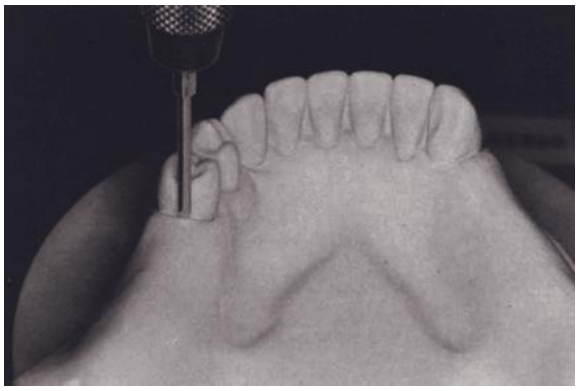



- tooth contours should be modified, lowering the height of contours so that:
  - The origin of circumferential clasp arm may be placed well below the occlusal surface, preferably at the junction of the middle and gingival thirds.
  - The retentive clasp terminals may be placed in the gingival third of the crown for better esthetic and better mechanical advantages.
  - Reciprocal clasp arm may be placed on and above a height of contour that is no higher than the cervical portion of the middle third of the After alterations of axial contours are accomplished and before rest seat preparation are instituted, an impression of the arch should be made in an irreversible hydrocolloid and a cast poured in a fast setting stone. This cast can be returned to the surveyor to determine the adequacy of axial alterations before proceeding with rest seat preparation. If axial surface require additional axial recontouring. it

can be performed during the same appointment and without compromise.

- Occlusal rest areas should be prepared that will direct the occlusal force along the long axis of the abatement
- crown of the abatement teeth.

<u>The procedure of rest seat preparation on sounds enamel surface:-</u>

- Round bur No.8 used to lower the marginal ridge and established the out line of the rest seat.
- Round bur No.6 used to slightly deepen the floor of the rest seat of the rest seat inside this lowered marginal ridge. This provides for an occlusal rest that satisfied the requirements that the rest be placed so that any occlusal force will be directed axially and that there will be the least possible interference to occlusion with the opposing teeth.
- The floor of the rest seat should incline towered the center of the tooth so that the occlusal forces are centered over the root apex.
- The marginal ridge must be lowered so that the angle formed by the occlusal rest with the minor connector will with stand above the occlusal surface of the abutment tooth as little as possible and above interface with opposing teeth. Simultaneously sufficient bulk must be provided to prevent a weakness in the occlusal rest at the marginal ridge. The marginal ridge must be lowered and yet not be deepest part of the rest preparation. To permit occlusal stress to be directed towered the center of the abutment tooth, the angle formed by the floor occlusal rest with the minor connector should be less than 90 degree. In other ward the floor of the occlusal rest should incline slightly from the lowered marginal ridge towered the center of the tooth

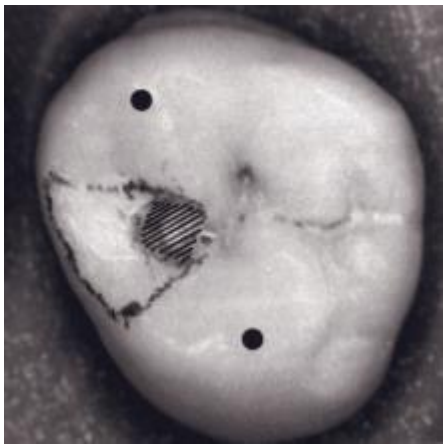

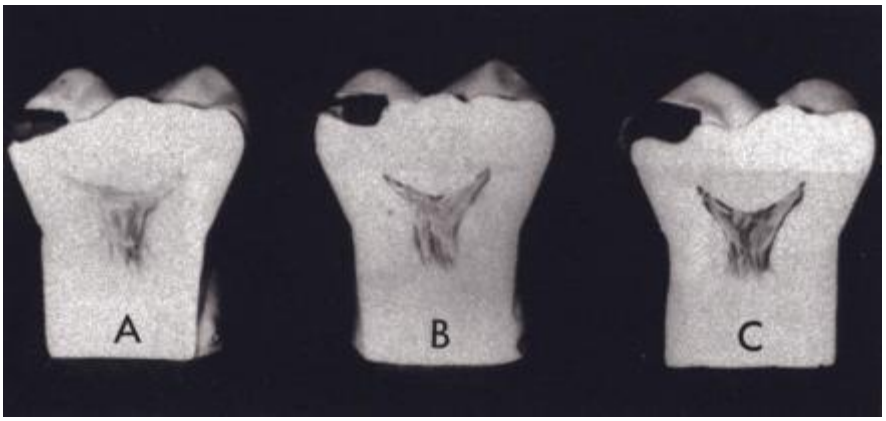



a b

The cingulum rest seat preparation requires a prominent cingulum. The preparation is a chevron or inverted “ V ” - shape mesiodistally (a), and a concave “ V ” - shape buccolingually (b).