Muscular Tissue

Muscle tissue is composed of differentiated cells containing contractile proteins. The structural biology of these proteins generates the forces necessary for cellular contraction, which drives movement within certain organs and the body as a whole.

Embryonic origin: Most muscle cells are of mesodermal origin

Three types of muscle tissue in mammals can be distinguished:

1. **Skeletal muscle** is composed of bundles of very long, cylindrical, multinucleated cells that show cross-striations.
2. **Cardiac muscle** also has cross-striations and is composed of elongated, branched individual cells that lie parallel to each other. At sites of end-to-end contact are the **intercalated disks,** structures found only in cardiac muscle.
3. **Smooth muscle** consists of collections of fusiform cells that do not show cross-striations.

Yousif Yasear

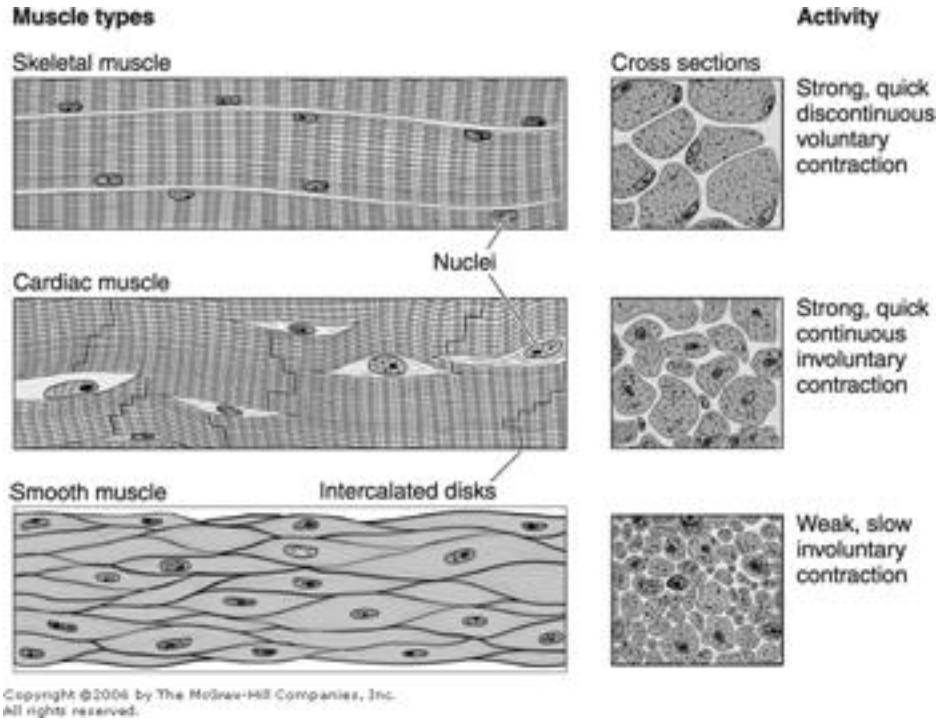

Copyright ©2006 by The McGraw-Hill Companies, Inc.
All rights reserved.

Characteristics of skeletal muscle

Skeletal muscle cells are elongated or tubular. They have multiple nuclei and these nuclei are located on the periphery of the cell. Skeletal muscle is striated. That is, it has an alternating pattern of light and darks bands.

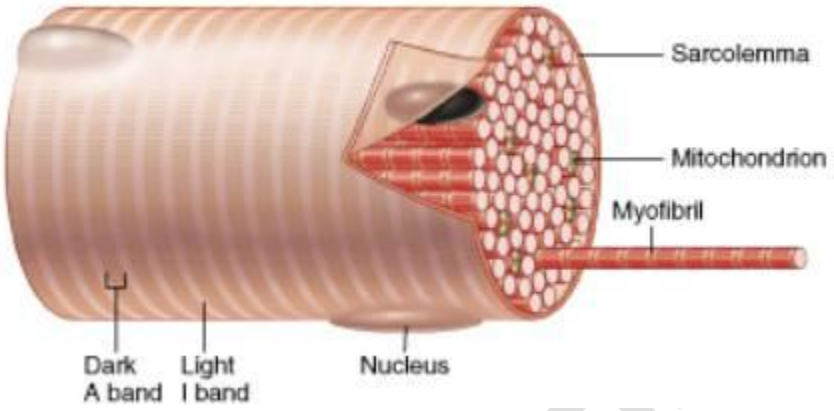

Characteristics of Cardiac muscle

Cardiac muscle cells are not as long as skeletal muscles cells and often are branched cells. Cardiac muscle cells may be mononucleated or binucleated. In either case the nuclei are located centrally in the cell. Cardiac muscle is also striated. In addition cardiac muscle contains intercalated discs. Which not only provide points of anchorage for the myofibrils but also permit extremely rapid spread of contractile stimuli from one cell to another.

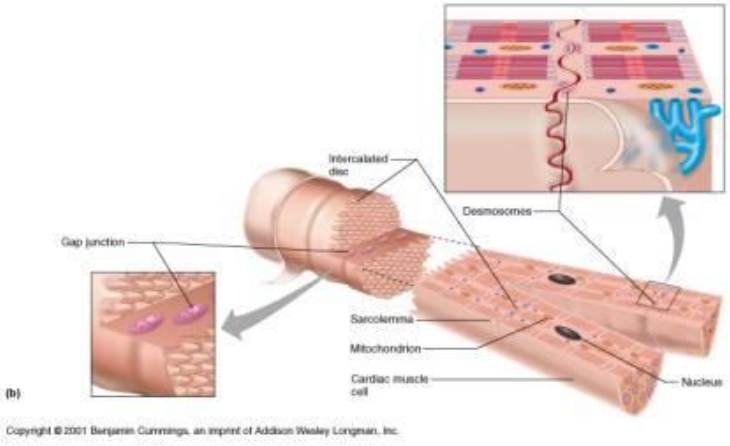

Intercalated discs are specialized transverse junctions between cardiac muscle cells at sites where they meet end to end; they always coincide with the Z lines.

Cardiac muscle cells contain numerous mitochondria, which occupy 40% or more of the cytoplasmic volume. By comparison, only about 2% of skeletal muscle fiber is occupied by mitochondria.

Cardiac muscle

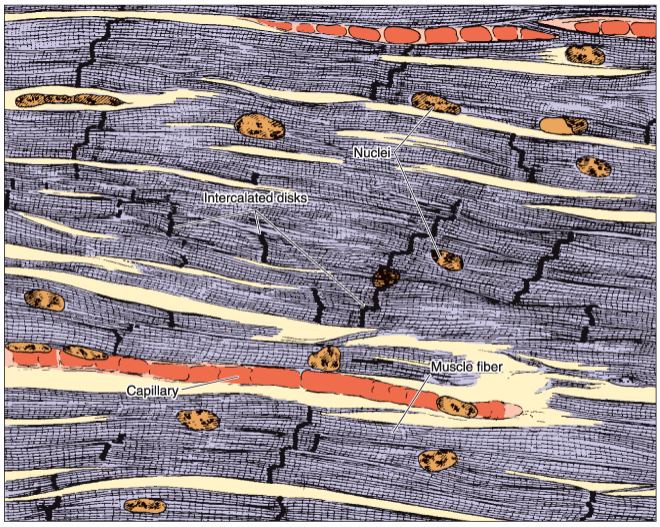

Copyright ©2006 by The McGraw-Hill Companies, Inc.
All rights reserved.

Characteristics of Smooth muscle

Smooth muscle cell are described as spindle shaped. That is they are wide in the middle and narrow to almost a point at both ends. Smooth muscle cells have a single centrally located nucleus. Smooth muscle cells do not have visible striations although they do contain the same contractile proteins as skeletal and cardiac muscle, these proteins are just laid out in a different pattern. The visceral muscle cells are not striated. The smooth muscles are connected by gap junction. Gap junctions play a central role integrating the smooth muscle cell function.

Most smooth muscle is present in the walls of hollow viscera (e.g. gut, ureter, uterine tube) where it is arranged in sheets with cells aligned circumferentially or longitudinally, with contraction resulting in reduction of the lumen diameter.

Dr.Akram Yasear

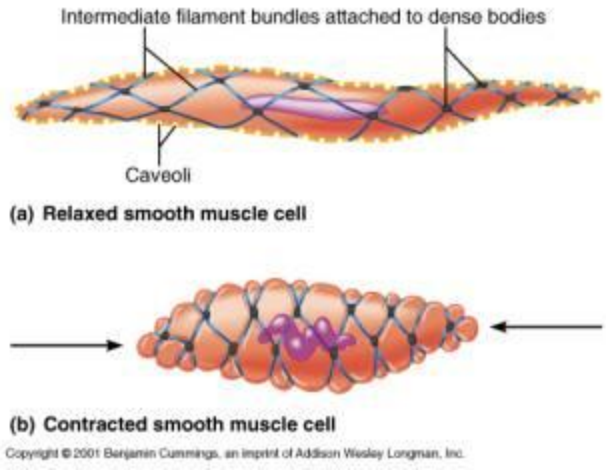

Connective tissues of the skeletal muscle:

a. Endomysium.

b. Perimysium

c. Epimysium/

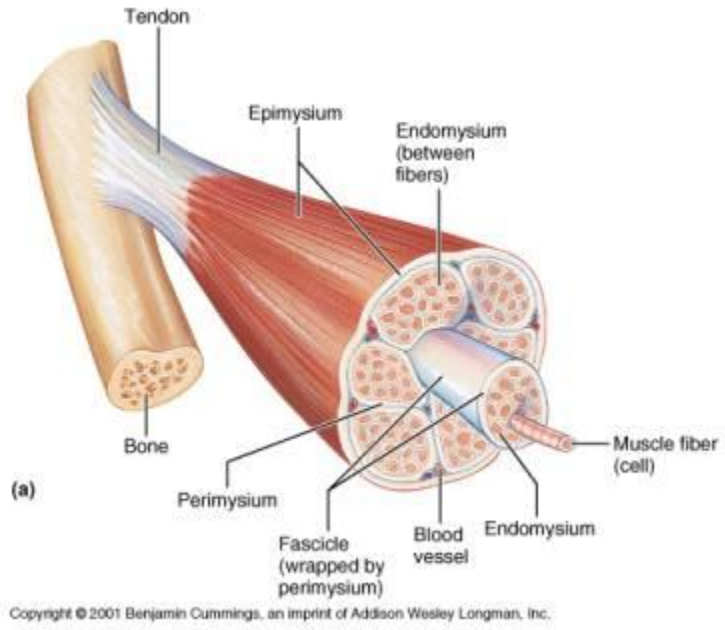

The muscle is made up of smaller bundles known as fascicles. Fascicles are actually bundles of individual muscle cells (myofibers or myocytes). These bundles are surrounded by a connective tissue sheath called **the perimysium**.

Dr. Akram Yousif Yasear

Each fascicle is made up of several muscle cells known as myocytes. They may also be called myofibers or muscle fibers. Each muscle cell is surrounded by a connective tissue sheath known as the **endomysium**. This sheath is very important in the physiology of muscle contraction because it electrically insulates the individual muscle cells from each other.

The whole muscle is surrounded by connective tissue called **epimysium**.

At the ends of the muscle all of the connective tissue sheaths (epimysium, perimysium, and endomysium) converge to form a tendon which will connect the muscle to its attachment site.

Each muscle fiber (muscle cell) contains all of the organelles that we find in other cell types.

Mitochondria are sites of energy production (ATP synthesis) in the muscle cell as in all other cells of the body, except for mature red blood cells.

Striated muscle filaments contain several proteins; the four main proteins are actin, tropomyosin, troponin, and myosin. Thin filaments are composed of the first three proteins, whereas thick filaments consist primarily of myosin. Myosin and actin together represent 55% of the total protein of striated muscle.

Muscles contract when they receive a motor impulse from a motor nerve.

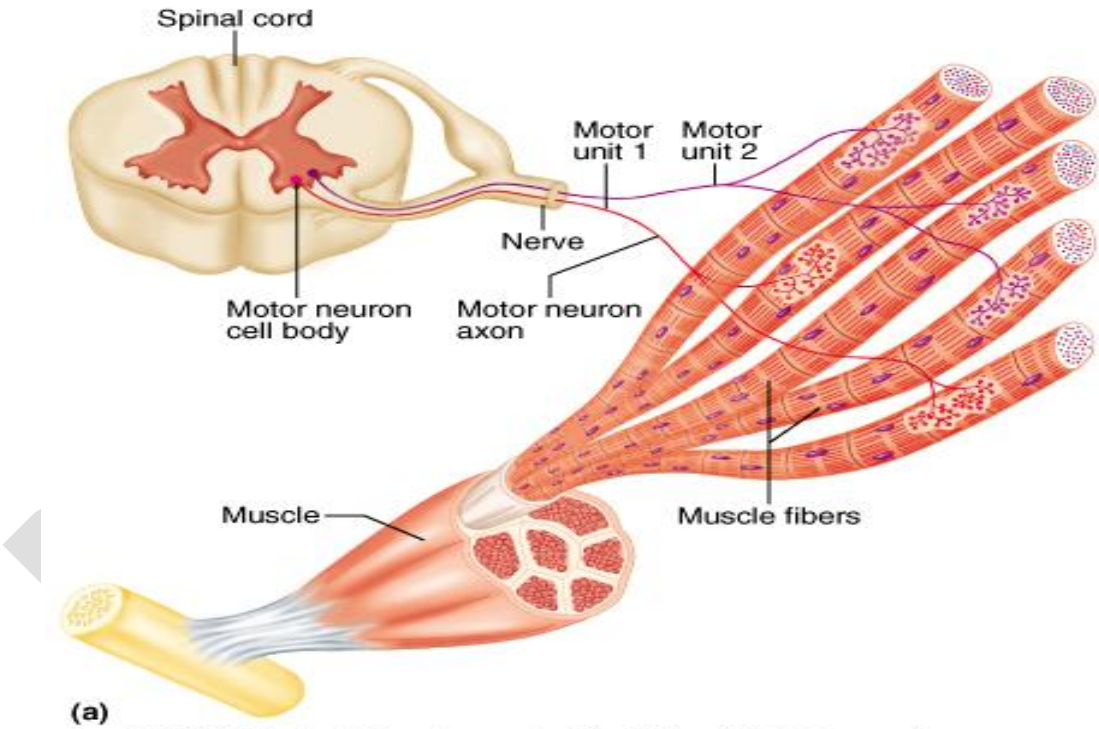

Copyright © 2001 Benjamin Cummings, an imprint of Addison Wesley Longman, Inc.

Regeneration of Muscle Tissue

The three types of adult muscle have different potentials for regeneration after injury.

Cardiac muscle has almost no regenerative capacity beyond early childhood. Defects or damage (eg, infarcts) in heart muscle are generally replaced by the proliferation of connective tissue, forming myocardial scars.

In skeletal muscle, although the nuclei are incapable of undergoing mitosis, the tissue can undergo limited regeneration. The source of regenerating cells is believed to be the **satellite cells.** The latter are a sparse population of mononucleated spindle-shaped cells that lies within the basal lamina surrounding each mature muscle fiber.

After injury or certain other stimuli, the normally quiescent satellite cells become activated, proliferating and fusing to form new skeletal muscle fibers.

Smooth muscle is capable of an active regenerative response. After injury, viable mononucleated **smooth muscle cells and pericytes from blood vessels undergo mitosis and provide for the replacement of the damaged tissue.**

Certain forms of contractile cell function as single-cell contractile units:

- **Myoepithelial cells are an important component of certain secretory** glands where they function to expel secretions from glandular acini.
- **Pericytes are smooth muscle-like cells that surround blood vessels.**
- **Myofibroblasts are cells that have a contractile role in addition to being able to secrete collagen. This type of cell is generally inconspicuous in normal tissues but comes to be a dominant cell type when tissues undergo repair after damage in the formation of a scar.**

Dr.Akram Yousif Yasear