Lecture 18 GENERAL PATHOLOGY

NEOPLASIA

DYSPLASIA, referring to disorderly proliferation Dysplastic epithelium is recognized by a loss in the uniformity of individual cells and in their architectural orientation. This change is encountered principally in epithelial membranes (e.g. the squamous epithelium of the cervix uteri, skin, and metaplastic bronchial mucosa

Characteristic changes in dysplasia

1. Pleomorphism and loss of orientation of the affected cells 2. Frequent presence of hyperchromatic and large nuclei 3. Unusually abundant mitotic figures; although these are almost of normal patterns (bipolar), frequently, however, the mitoses appear in abnormal locations within the epithelium, for e.g. in dysplastic stratified squamous epithelium; mitoses are not limited to the basal layers as is the case normally, but appear at all levels including the surface cells.

According to the severity & extent of the above changes, **dysplasias are graded** into mild, moderate and sever

Mild to moderate dysplasia :when the dysplastic changes do not involve the entire thickness of the epithelium and sometimes regress completely, particularly if inciting causes are removed. Mild to moderate dysplastic changes of the cervical squamous epithelium may be reversible, and with the removal of the inciting cause, the epithelium may revert to normal

carcinoma in situ, a preinvasive stage of cancer: When dysplastic changes are severe and involve the entire thickness of the epithelium. **Invasive carcinoma:** Once the tumor cells move beyond the normal confines through breaching the limiting basement membrane, the tumor is considered an invasive carcinoma**.**

Dysplastic changes are often found adjacent to foci of invasive carcinoma, and in some situations, such as in long-term cigarette smokers, severe epithelial dysplasia of the bronchial epithelium frequently precedes the appearance of cancer. However, dysplasia does not necessarily progress to cancer.

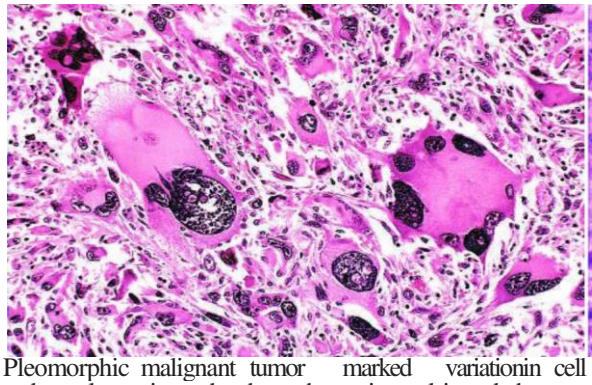
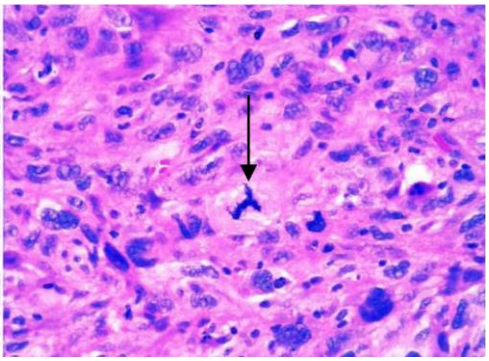

Pleomorphic malignant tumor marked variationin cell and nuclear sizes, the hyperchromatic nuclei, and the presence of tumor giant cells.

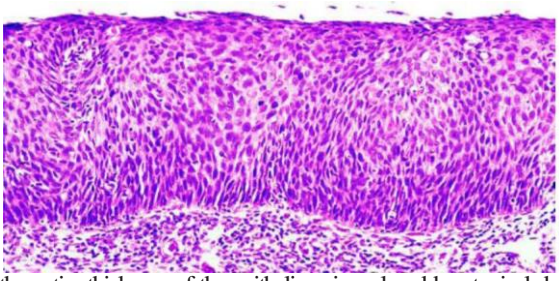
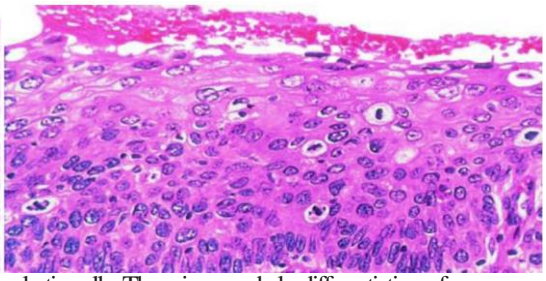

the entire thickness of the epithelium is replaced by atypical dysplastic cells. There is no orderly differentiation of squamous cells. The basement membrane is intact, and there is no tumor in the subepithelial stroma

II. Local invasion The growth of cancers is accompanied by progressive infiltration, invasion, and destruction of surrounding tissues, whereas most benign tumors grow as cohesive expansile masses that remain localized to their sites of origin.

Because benign tumors grow and expand slowly, they usually (not always) develop a rim of compressed fibrous called fibrous capsule **,** Encapsulation creates a tissue plane that makes the tumor discrete, moveable (non-fixed) readily excisable by surgical enucleation . An example is fibroadenoma of the breast. This tumor on clinical examination is well-defined and typically mobile mass. Benign tumors remain confined to the site of origin without having the ability to invade locally or metastasize to distant sites. In contrast, most malignant tumors are invasive and can be expected to penetrate and destroy the underlying tissues i.e. they are not surrounded by a capsule. Fixation of a breast mass on clinical examination makes it suspicious for malignancy. It is this invasiveness that makes surgical resection of cancers difficult. It is necessary during surgery to remove a margin of apparently normal tissues (margin of safety) adjacent to infiltrative cancer..

III. Metastasis

By definition metastases are "tumor implants discontinuous with the primary tumor". Metastasis is the only definitive criterion of malignancy because benign neoplasms do not metastasize. In general, the more anaplastic and the larger the primary neoplasm, the more likely is metastatic spread.

Almost all cancers can metastasize. The major exceptions are

1. Most malignant gliomas of CNS
2. Most Basal cell carcinomas of the skin. Rodent ulcer is a clinical descriptive term used for basal cell carcinoma because of their destructive invasiveness. Yet, they do not, metastasize.

.Pathways of Spread Dissemination of cancers may occur through one of three pathways: A-Seeding of Body Cavities and Surfaces

This may occur whenever a cancer, as a result of progressive invasion, penetrates into a natural "open field." Most often involved is the peritoneal cavity, but any other cavity—pleural, pericardial, subarachnoid, and joint space—may be affected. Peritoneal seeding is particularly characteristic of ovarian carcinomas. Lung and breast carcinomas as well as many other cancers may involve pleural cavity. Involvement of serous membranes by metastases is associated with pouring of exudates in to these cavities (malignant peritoneal, pleural or pericardial effusion).

B-Lymphatic Spread

This is the most common pathway for the initial dissemination of carcinomas, but some sarcomas may also use this route. The pattern of lymph node involvement follows the natural routes of lymphatic drainage.

Sentinel lymph node is defined as "the first node in a regional lymphatic basin that receives lymph flow from the primary tumor." This node is therefore a representative of the regional lymph nodes status. Drainage of tumor cell antigens without cancerous cells may induce reactive changes (reactive lymphoid hyperplasia) within the regional nodes causing their enlargement. **Therefore, nodal enlargement near a cancer does not necessarily mean dissemination of the primary tumor.** Differentiation between the two is only possible through microscopic examination of sections from the excised nodes.

C-Hematogenous spread is typical of sarcomas but is also seen with carcinomas. Veins, because of their thinner wall, are more readily penetrated than arteries. With venous invasion, the blood-borne cells follow the venous flow draining the site of the neoplasm**.** The liver and lungs are most frequently involved by metastases. This is because all portal area drainage flows to the liver, and all vena cava blood flows to the lungs. Cancers arising in close proximity to the vertebral column often metastasize through the paravertebral plexus of veins, and this pathway is probably the cause of frequent vertebral (bone) metastases of carcinomas of the thyroid and prostate..

Difference between Benign and malignant tumors can be distinguished from one another based

1-**Degree of differentiation**

Benign tumors resemble the tissue of origin and are well differentiated; malignant tumors are poorly or completely undifferentiated (anaplastic).

2-**Rate of growth**

Benign tumors tend to be slow growing,

Malignant tumors generally grow faster.

3-**local invasiveness**,

Benign tumors are well circumscribed and have a capsule;

Malignant tumors are poorly circumscribed and invade the surrounding normal tissues.

4-**Metastasis**

Benign tumors remain localized to the site of origin, Malignant tumors are locally invasive and metastasize to distant sites.