Clinical Techniques For Direct Class III, IV, and V restorations

Cavity preparation for composite restorations:
Three designs of tooth preparations for composite restorations, and sometimes they are used in combination. The designs include:
(1) Conventional (2) Beveled conventional (3) Modified

Class III Tooth Preparation:

- There is a choice between facial or lingual entry into the tooth

Indications for Lingual Approach

1. To conserve facial enamel for enhanced esthetics.
2. Carious lesion is positioned lingually.
3. Lesion is accessible from the lingual.
4. Color matching of the composite is not as critical.
5. Discoloration or deterioration of the restoration is less visible.

Indications for Facial Approach

1. The carious lesion is positioned facially
2. Teeth are irregularly aligned, making lingual access undesirable.
3. Extensive caries extends into the facial surface.
4. A faulty restoration was originally placed at the facial.

<u>Conventional Class III</u>
Indicated for restorations involving the root surface

1. Using a No. ½, 1, 2 round bur prepare the outline form on the root surface
2. Extend the preparation into sound walls
3. Extend pulpally 0.75mm in depth
4. The gingival/cervical and incisal wall is perpendicular to the root surface (box-like design)

5. Continuous groove retention can be prepared 0.25 mm (½ of a diameter of bur) into the dentin of the gingival and incisal walls with a ¼ round bur.
6. The groove is placed at the junction of the axial and the external walls.
7. Clean preparation and inspect the final preparation.

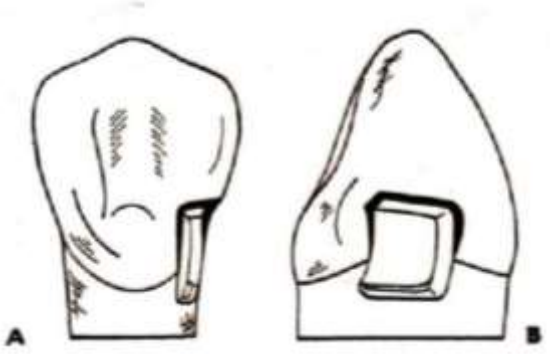

Beveled Conventional Class III

- ❖ Indicated for replacing an existing defective restoration in the crown portion of the tooth.
- ❖ When restoring a large carious lesion for which the need for increased retention and/or resistance form is anticipated.

Lingual Access

1. Use a round bur No. 1/2, 1. 2 depending on the size of caries to enlarge the opening sufficiently to allow for caries removal.
2. Extend external walls to sound tooth structure using a straight bur.
3. Extend the gingival and incisal walls up to extent of caries or location of old restoration.

Unless necessary, **DO NOT**:

- Include the proximal contact.
- Extend into the facial surface.
- Extend subgingivally

4. Create an initial axial wall depth of 0.2mm into the dentin/DEJ (approximately 0.75 – 1.25mm in depth)
5. The axial wall is convex, following the external contour of the tooth.
6. Remove all remaining infected dentin, using a round bur or small spoon excavator.

7. Remove friable enamel at the margins.
8. If necessary, prepare retention (grooves or coves). Prepare it along the gingivoxial line angle, and sometimes at the incisoaxial line angle of 0.25 mm with a ¼ round bur.
9. Place cavosurface bevel or flare at the enamel except at the gingival margin area.
10. Use a flame shape or round bur resulting in a 45 degrees angle to the external tooth surface.
11. Bevel width should be 0.25 to 0.5mm.
12. Clean the preparation of any debris and inspect the final preparation.

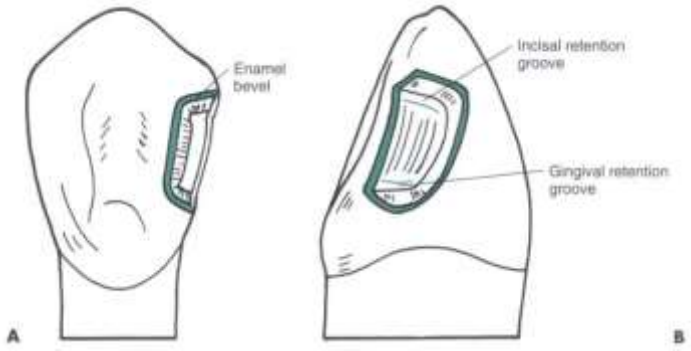

Facial Access

- ❖ The same stages and steps are followed
- ❖ The procedure is simplified because of easy access

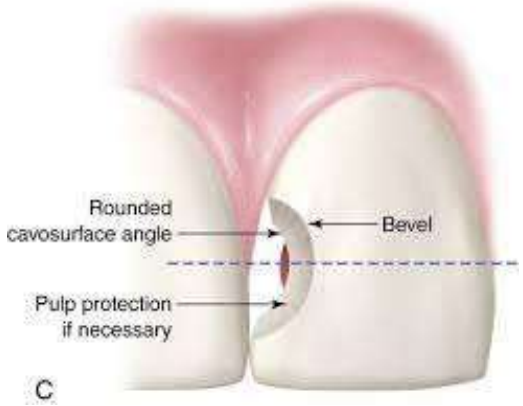

Modified Class III

- ✓ Most used type of cavity preparation.
- ✓ Indicated for small and moderate lesions or faults.
- ✓ Designed to be as conservative as possible.
- ✓ Preparation walls have no specific shapes or forms.
- ✓ The preparation design appears to be scooped or concave

1. Use a 1/2, 1, 2 round bur, point of entry is within the incisogingival dimension of the lesion, perpendicular to the enamel surface.
2. Remove all remaining caries or defects.
3. No attempt is made to create a uniform axial wall.
4. Place cavosurface bevel or flare at the enamel except at the gingival margin area.
5. Use a flame shape or round bur resulting in a 45 degrees angle to the external tooth surface.
6. The bevel width should be 0.25 to 0.5mm.
7. Clean the preparation of any debris and inspect the final preparation.

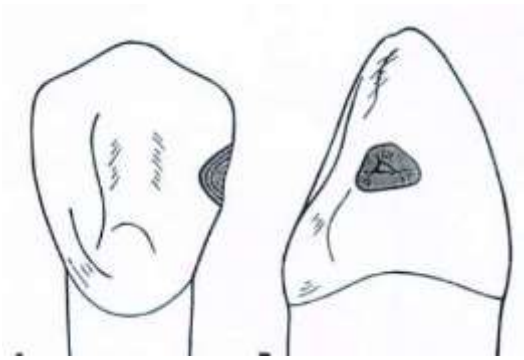

Class IV Tooth Preparation

- Preoperative assessment of occlusion is very important (placement of margin in noncontact areas)
- The shade selection is more difficult
- Preparation is similar to Class III except that the preparation for class IV is extended to the incisal angles

- For fracture: If no caries or pulpal involvement a bevel is the only preparation necessary 1.0-2 mm enamel bevel should be placed around the periphery of the cavity
- Use of Pins: Retentive pins are not needed because the adhesive technique provides sufficient retention for the restoration

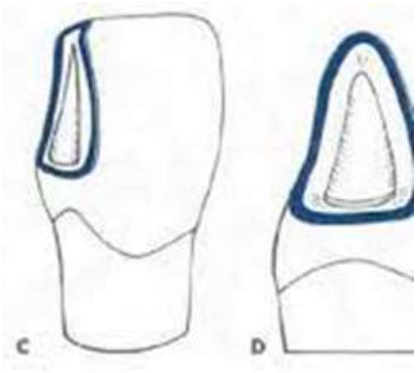

Class V Tooth Preparation

Conventional

- ❖ The feature of the preparation includes a 90-degree cavosurface angle, uniform depth of the axial line angle, and sometimes, groove retention form.
- ❖ Conventional design is indicated only for the portion of the lesion extended onto the root surface

1. Use a tapered fissure (No. 700, 701, or 271) or No.1 or 2 round bur.
2. Make entry at 45 degrees angle to the tooth surface, this should result in a 90 degree cavosurface.
3. Axial depth is 0.75 mm to the strength of the preparation wall, the strength of the composite, and placement of retention groove
4. The Axial should follow the contour of the tooth.
5. Extent of the outline form is dictated by the carious lesion extent.
6. Remove remaining carious lesion
7. Prepare retention groove (similar to Class III preparation)
8. Clean preparation

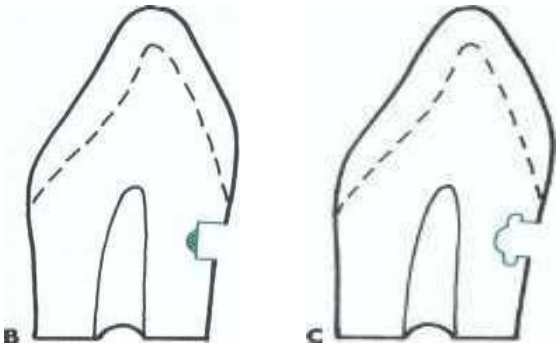

Beveled Conventional Class V

Indications

- ✓ Replacement of defective class V restorations
- ✓ large carious lesion

1. Exhibits 90 degrees of cavosurface
2. Axial wall depth is uniform (0.2mm or 0.5 when the retention groove is to place
3. Groove is not indicated when periphery of tooth preparation is located in enamel.
4. Remove all infected dentin
5. Clean preparation

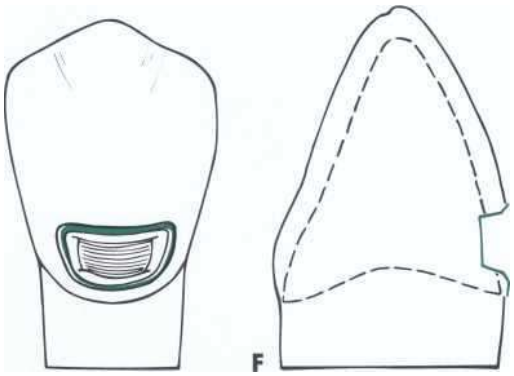

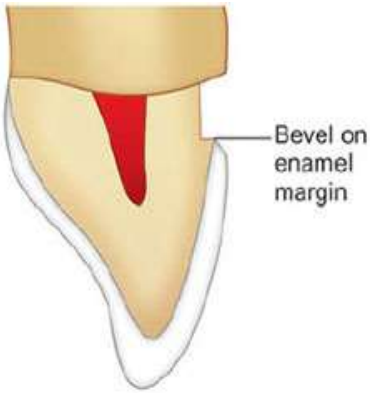

Modified Class V

1. Indicated for small and moderate lesions and lesions entirely in the enamel
2. No effort to prepare a butt-joint
3. No retention groove
4. The lesion is scooped out
5. Preparation has divergent wall
6. The axial wall does not have a uniform depth
7. Prepare the tooth with a round or elliptical instrument
8. Preparation is extended initially no deeper than 0.2 mm
9. No effort is made to prepare 90-degree cavosurface margins.
10. Infected enamel is removed with a round bur or excavator

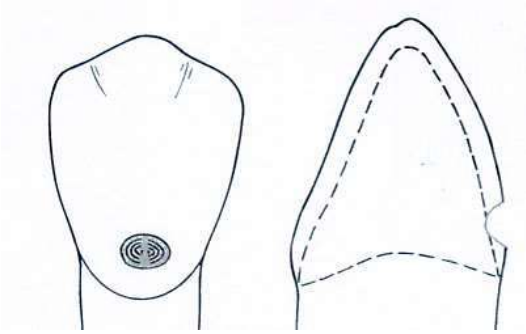

Restorative Technique

1. Determine the shade of the tooth
   - After caries removal and cavity preparation shade selection was done using a shade guide
2. Clean the tooth preparation using a slurry of pumice, polishing cup
3. Isolate the tooth, preferably with a rubber dam or cotton rolls, to keep the prepared teeth from saliva, blood, debris, and other fluids.
4. Protect the adjacent unprepared tooth from the acid etchant with a polyester strip and apply the wedge.
5. Apply the gel etchant 0.5 beyond the prepared margins onto the adjacent unprepared tooth.
6. Etchant is left undisturbed for 15 seconds.
7. The area is washed to remove the etchant.
8. Dry the tooth structure

9. A bonding system is applied on all tooth structure that has been etched with a micro brush or other suitable applicators
10. Application of Bonding Agent: Application of the bonding agent and then curing for 10 seconds.
11. Incrementally place composite material and cure.
12. Curing of the Composite**:** The material is cured using the light curing machine for 20 seconds for every increment of composite that was placed.
13. Finishing and Polishing**:** The use of polishers with enhancers and polishing paste was done after the trimming of the excess composites