Class II cavity preparation for amalgam restoration

Preparations involving the proximal surfaces of posterior teeth are termed Class II. The following surfaces are involved:

- Two surface cavities for posterior teeth
- Three surface cavities for posterior teeth
- Four surface (or more) cavities for posterior teeth



Steps in the cavity preparation

Initial Tooth Preparation Stage

Step 1: Outline form and initial depth
Step 2: Primary resistance form
Step 3: Primary retention form
Step 4: Convenience form

Final Tooth Preparation Stage

Step 5: Removal of any remaining infected dentin and or old restorative material, if indicated
Step 6: Pulp protection, if indicated
Step 7: Finishing of the Enamel Walls and Margins
Step 8: Final Cleaning and Inspection of the Preparation

Step 1: Outline Form and Initial Depth

Establishing the outline form means placing the preparation margins in the positions they will occupy in the final preparation. Outline form for occlusal portion follows the same principles as given for pit and fissure lesions, except that the external outline is extended proximally towards the defective proximal surface.

Establishing the Occlusal Step:

1. Enter the pit nearest the involved proximal surface with a punch cut using no.245 bur. the long axis of the bur & the long axis of tooth crown should remain parallel during cutting procedures, the bur should be rotating when applied to the tooth and should not stop rotating until removed
2. The proper depth of the initial entry cut is 1.5-2 mm
3. Extend the outline to include the central fissure while maintaining uniformity in depth of pulpal floor



4. Make the isthmus width as narrow as possible, not more than one-fourth of the inter-cuspal distance.
5. Give slight occlusal convergence to facial, lingual, and proximal walls to provide retention for amalgam. A dovetails provided in the opposite area to prevent displacement of the restoration

Preparation of Proximal Box

The objectives for the extension of proximal margins are to:

1. Include all caries, faults, or existing restorative material.
2. Remove unsupported enamel.
3. Establish not more than 0.5 mm clearance with the adjacent proximal surface facially, lingually & gingivally

Preparation of Proximal Box

1. Widen the preparation facio-lingually to just clear the contact areas.
2. The proximal cut is diverged gingivally. It results in greater facio-lingual dimension at the gingival surface than occlusal surface. It provides good retention and conservation of marginal ridge
3. Keep a small slice of enamel at the contact area to prevent accidental damage to the adjacent tooth. If there is any doubt that accidental damage to the adjacent tooth can occur, use a metal matrix band interdentally
4. The walls of the proximal box should converge occlusally

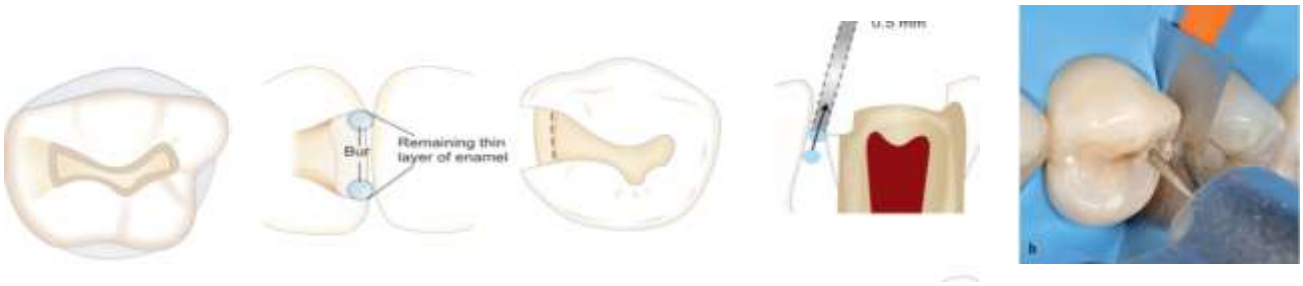

5. Flatten the gingival floor so that masticatory forces are distributed equally (Flattening of the gingival floor is done using an enamel hatchet)
6. The ideal width of the gingival seat ranges from 0.6 mm to 0.8 mm for premolars and 0.8 mm to 1.0 mm for molars (It consists of 2/3rd of dentin and 1/3rd of enamel).
7. Ideal clearance of facial and lingual margins of the proximal box should be 0.2–0.5 mm from the adjacent tooth

Step 2: Primary Resistance Form

It may be defined as the shape of the cavity that prevents fracture of the remaining tooth structure and the restoration. This includes

1. Occlusal amalgam should have a thickness of (1.5-2.0 mm) to resist fracture during function.
2. Removal of unsupported enamel by making the margin (90º-110º) because less than 90º the tooth is more subjected to fracture
3. Smooth pulpal floor & gingival seat to prevent stress concentration area.
4. Rounding the internal line and point angle
5. Cusp capping for preserving cuspal strength.

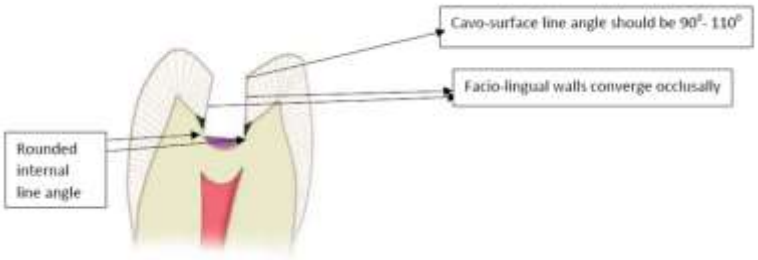

6. Maintaining minimal width of the preparation to preserve tooth structure (should not exceed ¼ intercuspal distance).
7. Mesial & distal walls of the cavity should be parallel and slightly diverge occlusally to be within the enamel rod direction and prevent any unsupported enamel at the marginal ridge
8. Rounding of axiopulpal line angle: This reduces the stress concentration and increases the bulk of amalgam at that area.
9. Rounded gingival cavo-surface line angle

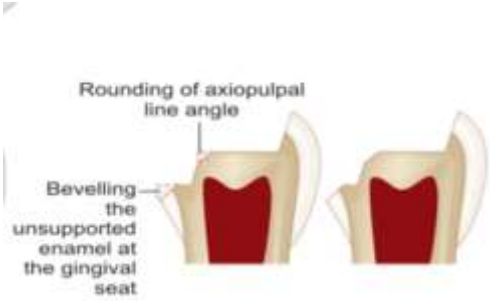

Step 3: Primary retention Form

It is the shape of the cavity that permits the restoration to resist displacement through the tipping or lifting force.
To provide retention, the cavity has the following

1. Facial & lingual walls should be parallel to each other or converge occlusally (5º)
2. Dove-tail preparation to increase retention
3. Width of the cavity
4. Occlusal convergence of the box

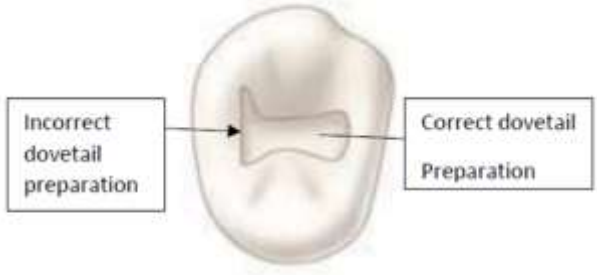

5. Retentive grooves or locks in the axiofacial and axiolingual line angle (The grooves prepared with round bur and should extend in the proximal walls just inside the DEJ and not the corners of the box
6. Pulpal floor & gingival seat of the cavity should be flat

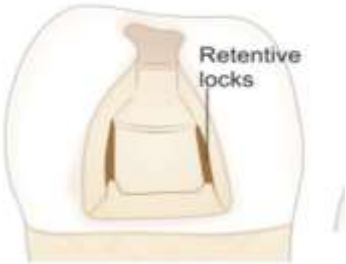

Step 4: Convenience Form

Convenience form is the shape or form of the preparation that provides for adequate observation, accessibility, and ease of operation in preparing and restoring the tooth

Step 5: Removal of remaining caries

1. Deep dentinal caries can be removed by using a spoon excavator or large round bur with slow-speed handpiece.
2. A stepped or two-level pulpal floor is made, i.e. only a portion of the tooth which is affected by caries is removed, leaving the remaining preparation dentin untouched

Step 6: Pulp protection

Use pulp protective materials on the pulpal floor and axial wall



Step 7: Finishing of the Enamel Walls and Margins

1. Finally finishing of walls and margins is done by removing all unsupported enamel. Beveling of the enamel portion of the gingival wall is done with the help of a gingival margin trimmer.
2. Gingival cavosurface bevel is not indicated if the gingival margin is placed gingival to the cementoenamel junction (CEJ)



Step 8: Final Cleaning and Inspection of the Preparation

The final stage of cavity preparation is to clean the preparation thoroughly with water and air spray. Then dry it with moist air.

Box-only preparation

Indications of simple box preparation:

1. Small proximal caries, not involving the occlusal surface
2. Proximal surface caries with narrow proximal contact
3. Proximal caries in attrited teeth.

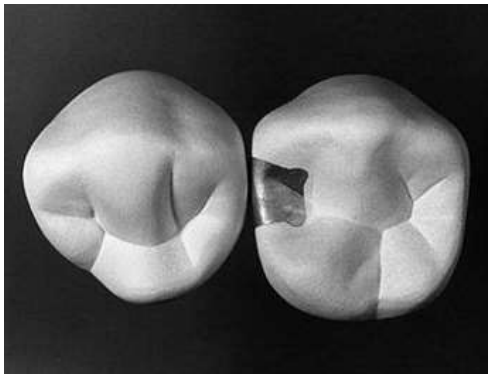

Steps for simple box preparation:

1. Prepare a proximal box with minimum facial and lingual extensions.
2. For retention, facial and lingual walls are converged, and locks of 0.5 mm depth gingivally and 0.3 mm occlusally are made in extensive proximal boxes.

