Orofacial development

The development of the primitive oral cavity (or **stomodeum**) begins as a shallow depression in the in the head of the embryo which is covered by ectoderm at the beginning of fourth week.

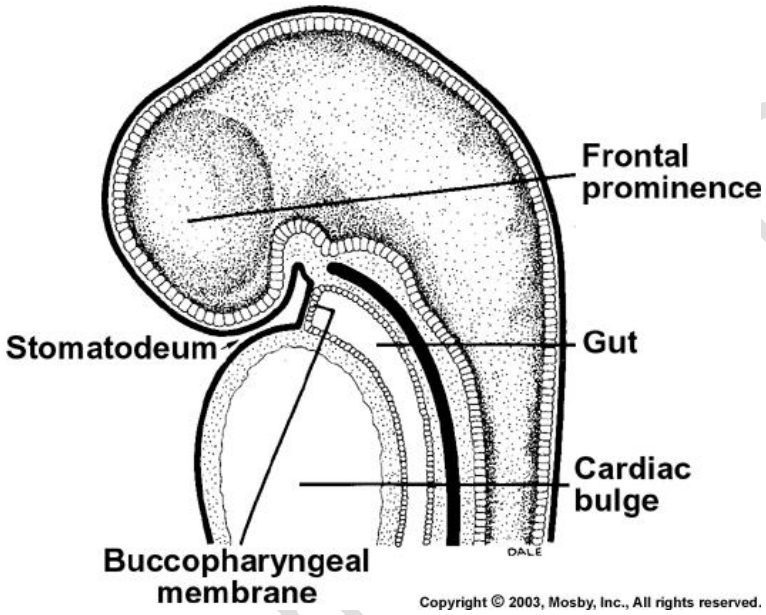

Fig. (1): Sagittal section through a 4- week embryo showing the stomodeum delimited by the frontal prominence and the cardiac bulge. The buccopharyngeal membrane separates the stomodeum from the foregut.

The **buccopharngeal membrane** also separates the stomodeum from the primitive pharynx, but soon this membrane breaks down so that the stomodeum communicates directly with the foregut which is a tube formed by the endoderm. The remnant of the buccopharyngeal membrane in our body is called glossopalatine folds With this disintegration of the buccopharyngeal membrane, the primitive mouth is increased in depth. As the stomodeum enlarges, two important endocrine glands developed in relation to it. They are the **ANTERIOR LOBE OF PRTUATRY GLAND** (the adenohypophysis) and from the floor of primitive pharynx the **THYROID** gland developed.

Dr. Akram Askar

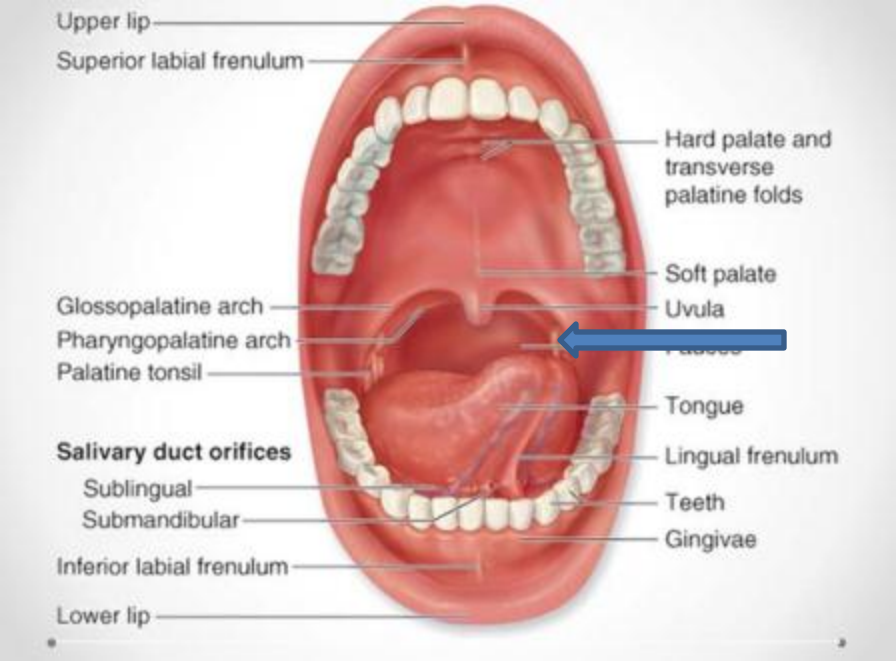

Figure (2) :Notice the glossopalatine folds (arrowed)

BRANCHIAL ARCHES:

They are bilateral swellings of tissue appear inferior to the stomodeum appear during the fourth week of prenatal development.

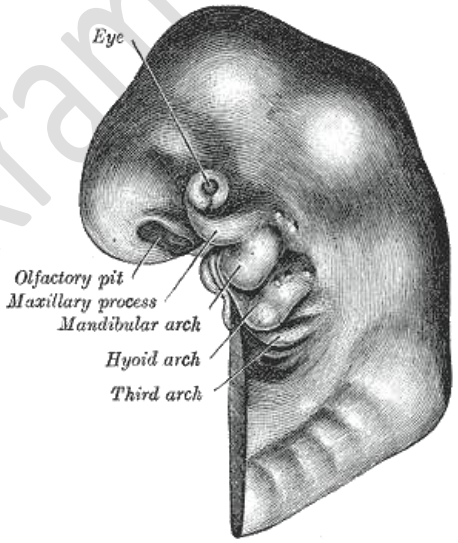

Fig. (3): A 27 old embryo viewed from the front. The beginning elements for facial development and three branchial arches are seen

Dr. Akram Yousif Alasear

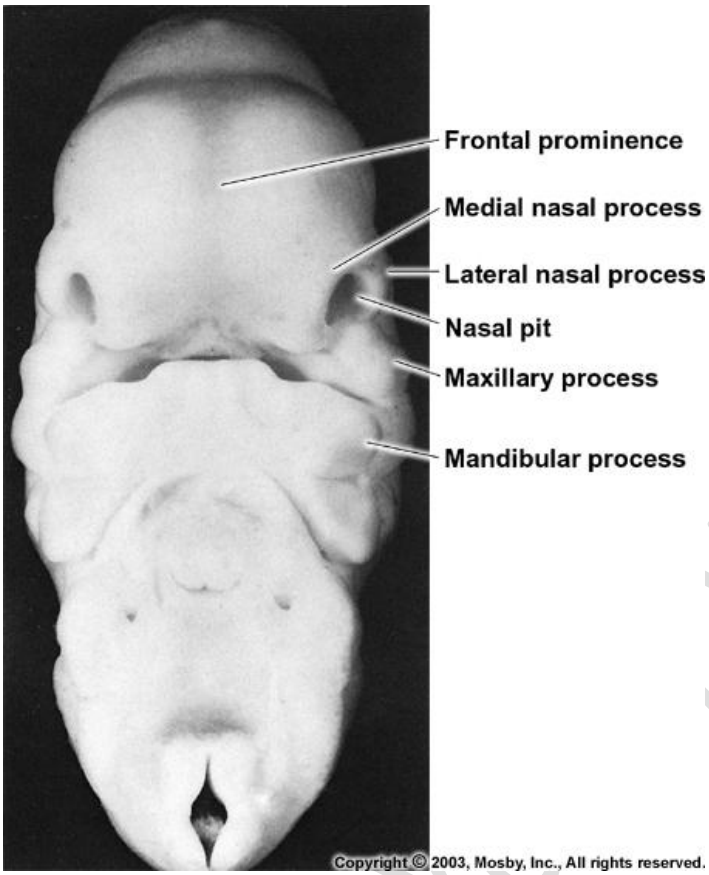

Fig. (4): A 34 days embryo viewed from the front. The nasal pits have formed, thereby marking the lateral and medial nasal processes. The first branchial arch is consisting of mandibular process and maxillary processes.

The branchial arches form the most typical feature in the development of head and neck. Each pharyngeal arch has the same basic plan.

Each arch is consisting of:

1. A core of mesodermal tissue for striated muscles development.
2. Neural crest cells (ectomesenchymal cells) surrounding a mesodermal core.
3. Cartilage derived forms the ectomesenchymal cells.
4. Specific cranial nerve .
5. An artery:

The branchial arches are numbered 5, i.e., 1st, 2nd, 3rd, 4th, and 6th. The 5th has degenerated very early due to the early degeneration of its blood supply. They appear one after another in a craniocadual direction.

First branchial arch: -

The nerve of the first arch is the trigeminal nerve. It is also called the **mandibular** arch.

Dr. Akram Yasear

It contains cartilage called Meckel's cartilage derived from the neural crest cells. It helps in the development of mandible. - The myoblasts, which originate in the mesodermal core of first arch, give rise to the muscles of mastication and also myliohyoid and anterior belly of the digastric muscles.
The nerve supply to the muscles of the first branchial arch is provided by the mandibular branch of the trigeminal nerve.
The first branchial arch is divided into two doubled processes:
a) **Maxillary processes** (left and right) which give rise to most of the upper lip and upper jaw and part of primary palate and also the secondary palate. The maxillary process is innervated by maxillary nerve.
b) Mandibular processes (left and right): form the lower lip, mandible, chin, and it is also merging with the maxillary processes to form the cheek.

The second branchial arch (hyoid arch):

The nerve supplying the second arch is the **facial nerve**.
The cartilage of hyoid arch is called **Reichert's cartilage**. Most of the cartilage disappears but part of it is responsible for the formation of stapes bone of middle ear.
The myoblasts from the mesodermal core give rise to:
a) Muscles of facial expression.
b) Stapedius.
c) Posterior belly of digastric muscle.
d) Stylohyoid muscle.

Its endodermal lining gives origin to the palatine tonsils during 5th month of intrauterine life (embryonic age).

The third branchial arch:

Has unnamed cartilage, this cartilage will be responsible for the formation of greater horn of hyoid bone and body of hyoid. The arch is innervated by the glossopharyngeal nerve. The endoderm of the third arch gives rise to inferior parathyroid glands and the fetal thymus gland.

The fourth branchial arch derivatives:

- The nerve is superior laryngeal N. of vague. The cartilaginous component of this arch contributes to thyroid cartilage of larynx.

- The muscle derived from mesoderm of the 4th arch are: -
a) Cricothyroid.
b) Pharyngeal constrictors.
c) Palatoglossus.
d) Muscles of uvula.

Dr. Akram Yousif Yasear

The sixth arch derivatives:

- The nerve of this arch is the recurrent laryngeal branch of vague. The cartilage component of this arch gives off the cricoid and arytenoids laryngeal cartilages The mesodermal cells of this arch are differentiating into the intrinsic muscles of the larynx except the cricothyroid.

The endoderm gives rises to the C-cells (parafollicular cells) which join the thyroid gland where they secrete the calcitonin hormone.

Development of the thyroid gland

The thyroid gland begins its development in the cavity of the stomodeum by day 24 at a point later indicatedin the future by the foramen caecum of the tongue .

By the 7th week the thyroid gland has reached its location anterior to larynx. The gland begins to function at end of 3rd month of fetal period.

Developmental abnormalitie:

It includes the lingual thyroid where the thyroid gland remains in its original position inside the mouth cavity at the base of the tongue.

Dorsal → superior parathyroids

Ventral → degenerates

4.5 5th pouch → ultimobranchial body → (in thyroid)

Neural crest cells → parafollicular cells

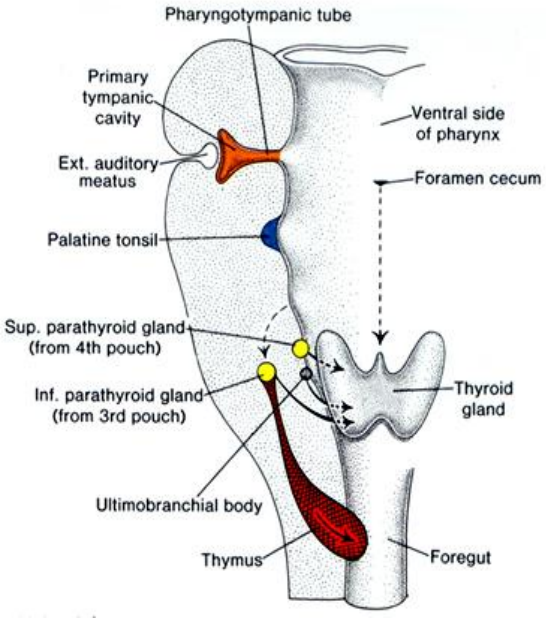

Yousif Yasear

Development of the face : -

The face developed during 5-7th wk of gestation from 5 primordia that surround the central depression of primitive oral pit. These primordia are:

1) Single frontonasal process which give rise to the upper third of the head.
2) Two maxillary processes : which give rise to the upper jaw.
3) Two mandibular processes : which give rise to the mandible.
The mandibular and the maxillary processes are all developed from first arch.

BY THE 5TH WEEK: -

It is marked by appearance of depressions in the head of the embryo , in the future position of the sense organs. They are named as:

a. The **two** nasal placodes

b. Two ear placodes.

c. Two eye placods.

During the 6th week, the underlying ectomesenchyme proliferates leading to transfer of the nasal placodes into elevations known as the medial and lateral nasal processes, which surround the newly formed depressions called the nasal pit (nostrils). These two processes appear as a horse shoe shaped elevations with open end of the slit in contact with the oral cavity.

Development of the upper lip: -

Starts at the 6th week .The two medial nasal processes merge in the midline with one another, they also merge they also merged with the two maxillary processes.

The merged medial nasal processes give rise to: -

1) The middle portion of the upper lip (philtrum).

2) The middle portion of the upper jaw.

3) The primary palate which is going to house the upper incisor teeth.

Thus the upper lip is formed by 1/3 from medial nasal processes and the other 2/3 from maxillary processes. Maxillary processes also give rise to parts of the upper jaw and the secondary hard palate. They also give rise to part of the cheek horizontally when merging with the mandibular processes.

Dr. Akram Yousif Yasear

The lower lip is formed entirely within the mandibular process.

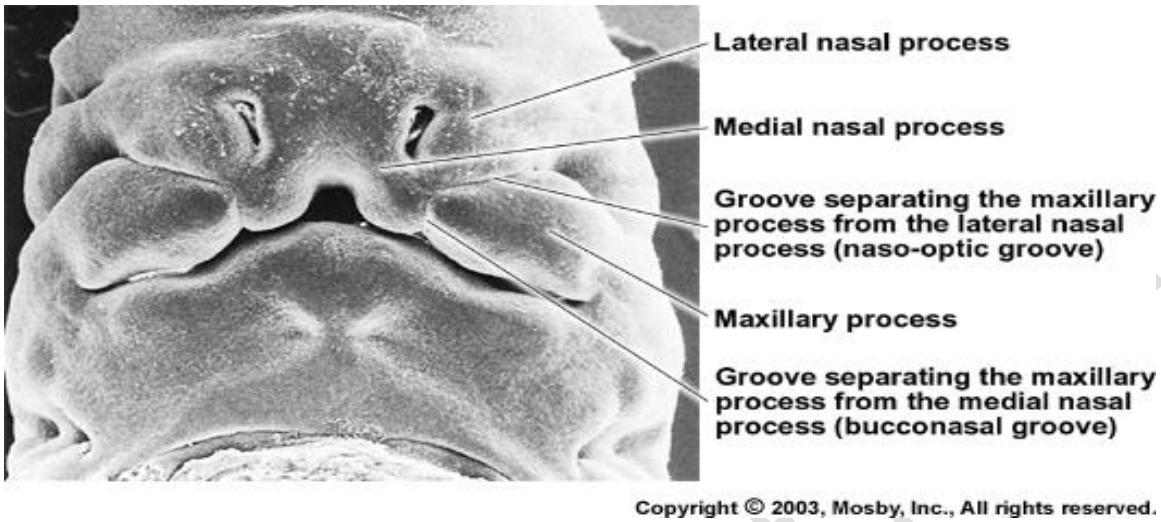

Copyright © 2003, Mosby, Inc., All rights reserved.

Fig. (6) :Sixth week human embryo ,showing the development of the face. Notice the fusion between the maxillary process and medial nasal processes to form the upper.

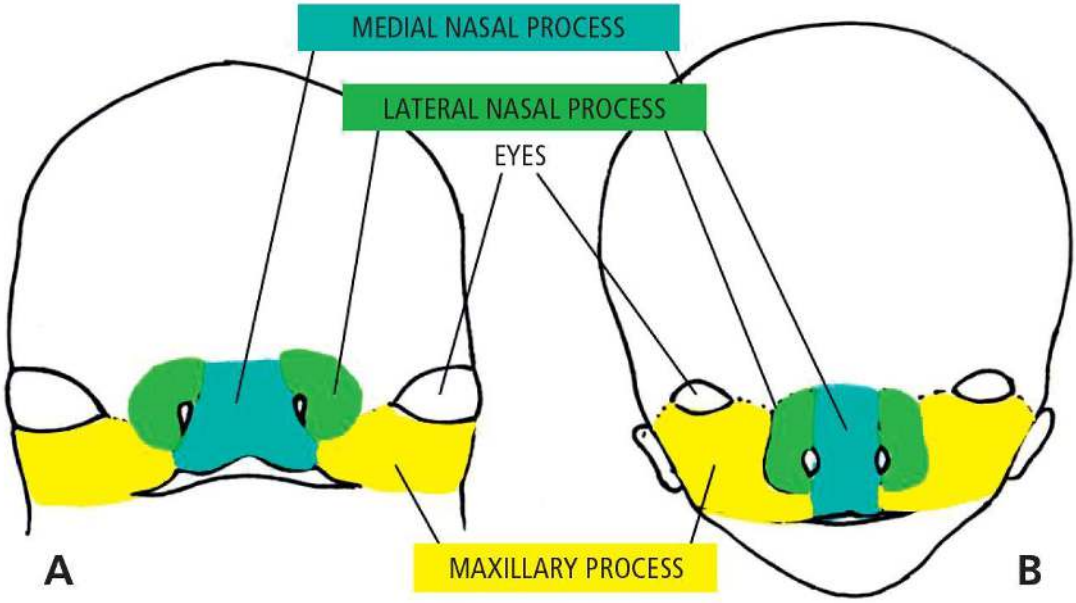

THE SIZE OF THE MOUTH: -

The size of the mouth is determined by the maxillary and mandibular processes as they merge at the lateral corners of the mouth.

EARLY DEVELOPMENT OF THE PALATE: -

The palate is the tissue between the oral cavity and nasal cavity.

The palate is formed of two tissues, the primary and secondary palates.

Primary palate:

It is so named because it appears earlier than secondary palate at beginning of 6th Week. The primary palate the from posterior part of the medial nasal processes. It gives support to the maxillary incisors, which developed inside it. The incisive foramen is the midline landmark between the primary and secondary palates.

THE SECONDARY PALATE: -

1) At the end of the 6 week two lateral palatine shelves (right and left) which form the secondary palate develop from the medial edges of the maxillary processes.

2) The palatine shelves grow first medially then downward or vertically on either side of the tongue.

At about 8th and ½ week the lateral palatine shelves roll over the body of the tongue due the growth of the jaw, leading to the descends of the tongue. This allows the vertical palatine shelves to f lip upward to become horizontal palatine shelves, which gradually grow toward each other and fuse in the midline to complete the secondary palate formation.

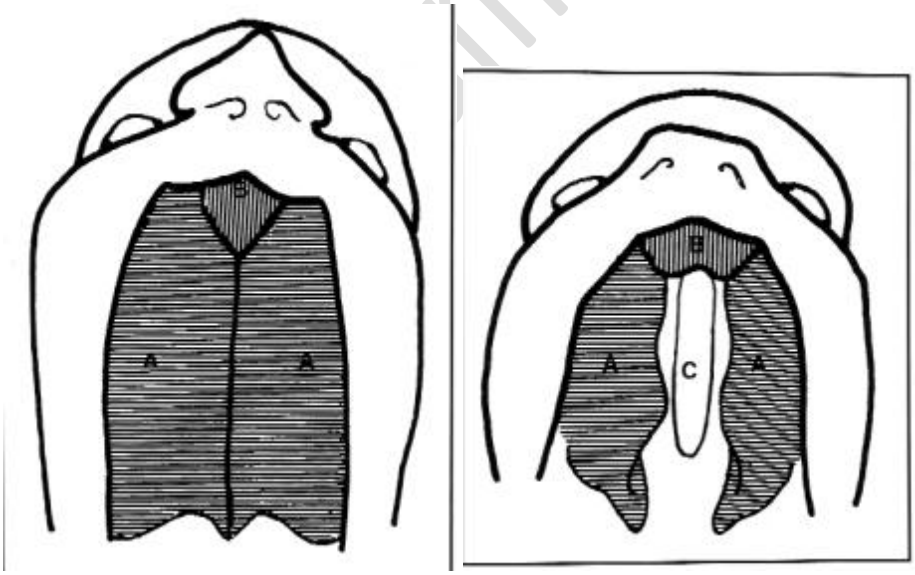

m Yousif Yasear

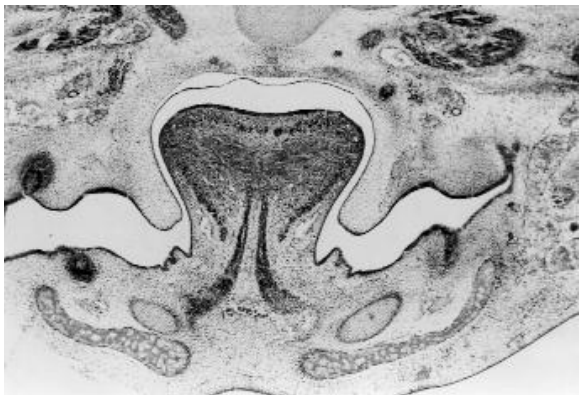

Fig.(7) : Showing steps in the development of primary and secondary . Note the vertical descend of the two palatine shelves in the lower photo.

Developmental anomalies:-

1. Cleft lip: this is a malformation of the upper lip it may be unilateral or bilateral.

a) Unilateral: failure of maxillary processes To merge with the medial nasal process on one side.

b) Bilateral: occur on same way on both sides.

2. Median cleft lip: failure of the two medial nasal processes to merge together (hare lip).

4) Cleft palate:

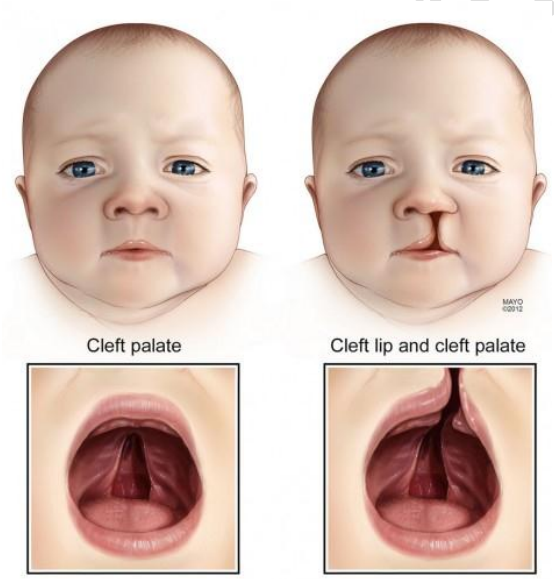

The strongest risk factor for development of a cleft is family history. Other risk factors include maternal smoking, consumption of large amounts of alcohol during the first trimester of pregnancy, certain medications taken during the first trimester, and maternal

Yousif Yasear

diabetes mellitus (but not gestational diabetes). There has been shown to be a decreased risk of cleft lip and palate with the use of prenatal vitamins and folic acid.

Development of the tongue

The tongue is composed of body (movable part) and the root (the posterior firmly attached or pharyngeal part).
The tongue begins to develop at about 4 weeks.

The **body** of the tongue develops from **3 swelling:**
a) The tuberculum impar: which arise in the midline as a single structure from the mandibular process of the first branchial arch on the floor of primitive pharynx.
b) Two lateral lingual swellings.

The two lateral lingual swellings rapidly increase in size and merge with each other and overgrow the tuberculum impar to form the anterior two thirds or body of the tongue. The **tuberculum impar** give no part in the tongue development.

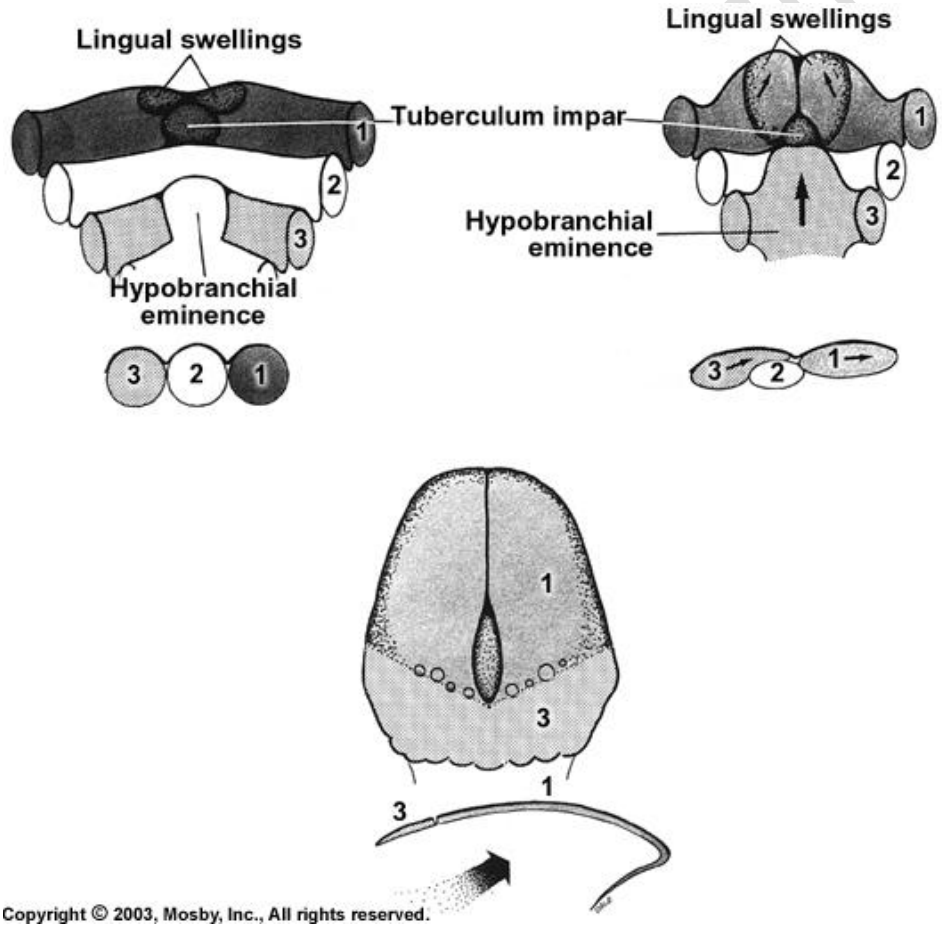

Fig. (8) : Steps in the development of the tongue;1= lingual swelling;3=root of tongue.

The formation of the **base or the posterior one-third** (root) of the tongue is from hypobranchial eminence, which is developed from the third branchial arch. The **foramen caecum** is located at the center of the v-shaped sulcus terminalis, which demarcates, between the anterior 2/3 and posterior 1/3 of tongue in the adult.

The posterior 1/3 has a lingual tonsil under the epithelium.

The muscles of the tongue have different origin; they arise from the occipital somites which have migrated into the tongue area, carrying with them their nerve supply, the hypoglossal nerve.

Tongue innervation

The unusual development of the tongue explains its multiple innervations:
1) The mucosa of anterior tow third is supplied by the nerve of 1st arch, the 5th (trigeminal) cranial N. through its lingual branch for general sensation (mandibular N.).
2) The mucosa of post-1/3 derived from 3rd arch, is supplied by the 9th cranial N. (the glossopharyngeal nerve).
3) The motor supply to the muscle of tongue is the hypoglossal N.
4) For the taste buds in the anterior 2/3 of tongue there is the chorda tympani nerve from the facial nerve.

DEVELOPMENT OF THE MANDIBLE: -

- Begins at 6th week of embryonic period.
- As a bilateral structure in the mandibular processes of the first branchial arch.
- Its development is coinciding with the development of the Meckel's cartilage of the first branchial arch.
- Meckel's cartilage is not going to change in to mandible but it is helping in the development of the mandible. The Meckel's cartilage will act as scaffolding for the developing mandible.

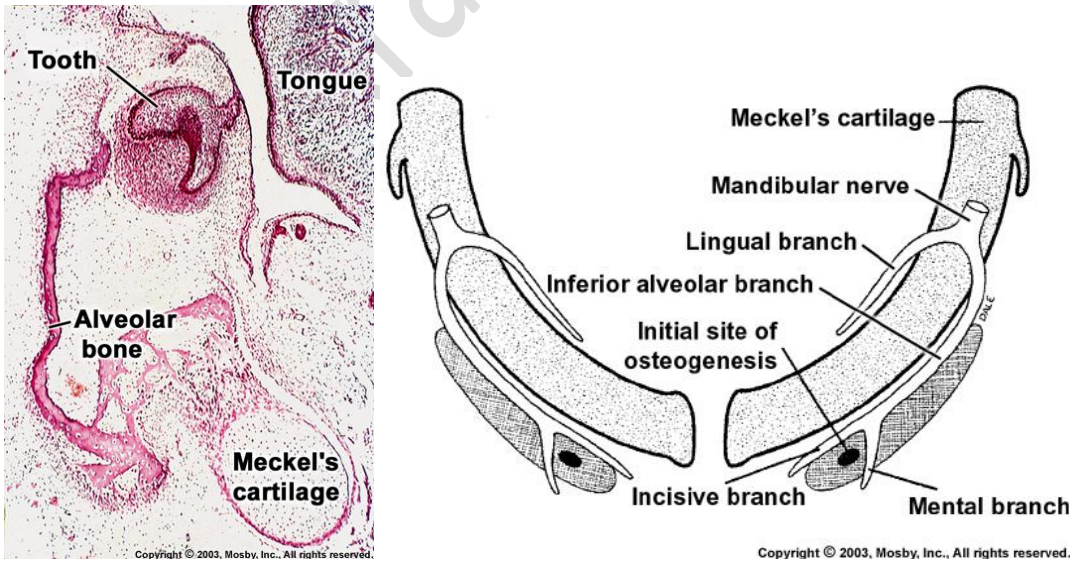

Fig.(10): Note the contribution of the Meckel's cartilage in the development of mandible

Ibrahim Yousif Yasear

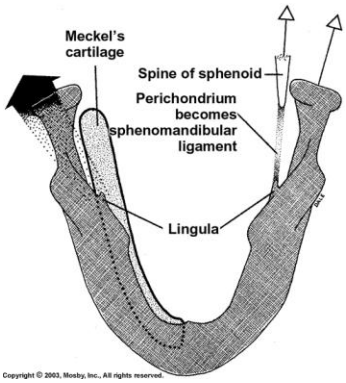

Fig.(10): The fate of Meckel's of cartilage posterior to the lingual

The Meckel's cartilage posteriorly converted into: -
a) Sphenomandibular ligament.
b) The very posterior part of the Meckel's cartilage gives rise to the malleus and incus of the middle ear.

- The formation of primitive or early mandible by the **intramembraneous** ossification is completed at 10 weeks.
- Future growth of the mandible the mandible.It includes formation of the ramus.It is helped by :-
a) Appearance of tree **secondary cartilages** named: - condylar, coronoid and symphyseal.
b) **Development of muscle of mastication.**

The secondary cartilages: -

At 20th weeks of development only a thin layer of the cartilages remain in the condylar head. This remnant of cartilages persists until the end of 20th years, giving growth for the mandible.
II) The coronoid cartilage: appears at 4th months of development and disappear before birth.
III) Symphyseal cartilage: two in number appear at the two ends of Meckel's cartilage but are independent of it. The symphyseal cartilage ossifies at the end of first year of life after birth.

Development of the maxilla

It is developed from a center of intramembraneous ossification appears in the mesenchyme of maxillary processes of the first arch around the seventh week of prenatal life.
At birth the body of maxilla is small .The maxillary sinus is still rudimentary, about the size of small pea

Dr. Akram Yousif Yasear