Orthodontics: This is a branch of dentistry concerned with facial growth; development of dentitions and occlusion; diagnosis; interception and treatment of occlusal anomalies. Orthodontics" is derived from the Greek orthos ("correct", "straight") and -odont- ("tooth").

According to the British Society of Orthodontics (1922) “Orthodontics includes the study of growth & development of the jaws & face particularly, & the body generally as influencing the position of the teeth; the study of action & reaction of internal & external influences on the development & the prevention & correction of arrested & perverted development.

According to the American Board of Orthodontics “Orthodontics is that specific area of dental practice that has as its responsibility the study and supervision of the growth and the development of the dentition and its related anatomical structures from birth to dental maturity, including all preventive and corrective procedures of dental irregularities requiring the repositioning of teeth by functional or mechanical means to establish normal occlusion and pleasing facial contours”.

In 1911 Noyes defined orthodontics as “The study of the relation of the teeth to the development of the face and correction of arrested and perverted development “.

In 1907 Angle stated that the objective of the science of orthodontics is “The correction of malocclusion of the teeth”.



Aims & objectives of orthodontic treatment: Aims & objectives of orthodontic treatment have been summarized by Jackson as the Jackson's Triad.

1. Functional Efficiency.
2. Structural Balance.
3. Esthetic Harmony.

Functional Efficiency Many malocclusions affect the normal functioning of the stomatognathic system. The orthodontic treatment should thus aim at improving the functioning of the orofacial apparatus.

Structural Balance The oro-facial region consists of the dentoalveolar system, the skeletal tissue, and the soft tissue including musculature. Stable orthodontic treatment is best achieved by balancing these three tissue systems.

Esthetic Harmony By far the most common reason for seeking orthodontic care is to improve the appearance of the teeth & face. Many malocclusions are associated with the unsightly appearance of teeth & can thus affect the individual's self-image, well-being & success in society. Thus, the orthodontic treatment should aim at improving the esthetics of the individual.

Scope of orthodontic treatment:

1. Alteration in tooth position.
2. Alteration in skeletal pattern.
3. Alteration in soft tissue pattern.

Definitions:

Occlusion: Any position or relationship in which the upper and the lower teeth come together.

Ideal Occlusion: A theoretical concept of an ideal arrangement of the teeth within the dental arches, combined with an ideal inter-arch relationship, which concentrates on optimal esthetic, function, and stability of the dentition and supporting structures. But it is rarely found in nature.

Normal occlusion: That occlusion which satisfies the requirements of function and esthetic but in which there are minor irregularities of individual teeth.



6 keys of normal occlusion:

1: Molar relation: The distal surface of the distobuccal cusps of the upper first permanent molar made contact and occluded with the mesial surface of the mesiobuccal cusps of the lower second molar, the mesiobuccal cusp of the upper first permanent molar fell within the groove between the mesial and middle cusps of the lower first permanent molar. (The canines and premolars enjoyed a cusp-embrasure relationship).

2: Crown angulation "The mesiodistal tip", The term angulation refers to angulation (or tip) of the long axis of the crown, not to angulation of the long axis of the entire tooth. The gingival portion of the long axis of each crown was distal to the incisal portion varying with the individual tooth type, the long axis of the crown for all teeth except molars is identified to be the mid-developmental ridge which is the most prominent part, and center most vertical portion of the labial or buccal surface of the crown. The long axis of the molar crown is identified by the dominant vertical groove on the buccal surface of the crown.

3: Crown inclination (Labiolingual or buccolingual inclination):

Crown inclination refers to the labiolingual or buccolingual inclination of the long axis of the crown, not to the inclination of the long axis of the entire tooth. The inclination of all the crowns has a consistent scheme:

a- Anterior teeth (Central and lateral incisors)

The labial inclination of the upper and lower anterior crown is sufficient to resist over-eruption of anterior teeth and sufficient also to allow proper distal positioning of the contact points of the upper teeth in their relationship to the lower teeth, permitting proper occlusion of the posterior teeth.

b-Upper posterior teeth (Canines through molars)

A palatal crown inclination that existed in the upper posterior crown was constant and similar to the canines through the second premolar and was slightly more pronounced in the molars.

c-Lower posterior teeth (Canines through molars)

The lingual crown inclination in the lower posterior teeth progressively increases from the canine through the second molar.

4: Rotation: There are no undesirable rotations**.** Rotated molar and bicuspid occupy more space than normal while rotated incisors occupy less space than normal

5: Spaces: There were no spaces with tight contact points.

6: Occlusal planes: The plane of occlusion varied from generally flat to

A slight curve of spee (measured from the most prominent cusp of the lower second molar to the lower central incisor), no curve deeper than 1.5 mm is accepted from a standpoint of occlusal stability.

Recently the authors believe that the correct crown diameter represents the seventh key to normal occlusion This key (the seventh key) had to be present in Andrews's non-orthodontic normal study models.

Malocclusion

'Ideal occlusion' is the term given to a dentition where the teeth are in the optimum anatomical position, both within the mandibular and maxillary arches (intramaxillary) and between the arches when the teeth are in occlusion (intermaxillary). Malocclusion is the term used to describe dental anomalies and occlusal traits that represent a deviation from the ideal occlusion. In reality, it is rare to have a truly perfect occlusion and malocclusion is a spectrum, reflecting variation around the norm.

The prevalence of malocclusion and particular occlusal anomalies depends on the population studied (e.g. age and racial characteristics), the criteria used for assessment, and the methods used by the examiners (e.g. whether radiographs were employed). In the UK, it is estimated that 9% of 12-year-olds and 18% of 15-year-olds are undergoing orthodontic treatment, with a further 37% of 12-year-olds and 20% of 15-year-olds requiring treatment). This suggests the overall prevalence of moderate-severe malocclusion is around 40–50% in adolescents

Malocclusion can be presented in several ways. Some of the common characteristics of malocclusion include:

- Overcrowded teeth
- Spacing between the teeth
- Improper "bite" between maxillary and mandibular teeth
- Disproportion in the size and the alignment between the maxillary and the mandibular jaws.

It must be appreciated that not all malocclusions need treatment. Treatment of malocclusions that are mildly unes- thetic and not detrimental to the health of the teeth and their supporting structures may not be needed and is not justified.

Unfavorable sequelae of malocclusion

Poor facial appearance
Poor oral hygiene maintenance

Risk of dental caries
Risk of periodontal diseases
Abnormalities of functions
Psychosocial problems
Risk of trauma to the teeth
TMJ problems.

Aims of Orthodontics: Improve the following:

1- Dental health:

a) Dental caries: Mal-alignment of the teeth may reduce the potential for natural teeth – cleansing and increase the risk of decay.
b) Periodontal disease: Irregular teeth reduce effective brushing, in addition to that, crowding may force one or more teeth to be squeezed buccally or lingually out of their investing bone reducing periodontal support and finally traumatic occlusion may lead to an increase in the loss of periodontal support (e.g.: anterior crossbite).
c) Trauma to anterior teeth: Research has shown that overjet of more than 3 mm had more than double the risk of traumatic injury.
d- Impacted teeth: An impacted (unerupted) tooth may affect the normal position and health of adjacent teeth in addition to the loss of function of the impacted tooth itself.

2- Function:

a- Masticatory function: Patients with open bites; markedly increased overjet (Class II) or reversed overjet (Class III) often complain of difficulties with eating, particularly incising food.

b- Speech: Crowding may have little effect on normal speech.

c- Tempro-mandibular joint: There is no clear association between malocclusion and the TMJ.

3- Psychosocial -well-being: Unattractive dentofacial appearance does have a negative effect on the expectations of teachers and employers.

Risks of orthodontic treatments:

1. Root resorption: During 2- years of fixed orthodontic treatment it is inevitable to find 1mm of root resorption, however, the use of excessive orthodontic force may lead to an unacceptable amount of root resorption and hence devitalization of affected tooth or teeth.
2. Loss of periodontal support: Caused by poor oral hygiene during orthodontic treatment.
3. Demineralization: This may occur during fixed orthodontic treatment, as a result of plaque accumulations in the case of uncooperative patients (poor oral hygiene).
4. Soft tissue damage: Traumatic ulceration may occur especially in fixed orthodontic treatment.
5. Pulpal injury: Excessive orthodontic force may lead to pulp injury and death, especially for the teeth with a history of trauma.

Orthodontic definitions:

Incisal overjet: The horizontal distance between the upper and lower incisors in occlusion, measured at the tip of the upper incisor (Fig. 1).
It is dependent on the inclination of the incisor teeth and the anteroposterior relationship of the dental arches. In most people, there is a positive overjet, i.e. the upper incisor is in front of the lower incisor in occlusion (normally 2-4 mm), but the overjet may be reversed (in the case of Class III), or edge-to-edge (Fig. 1).

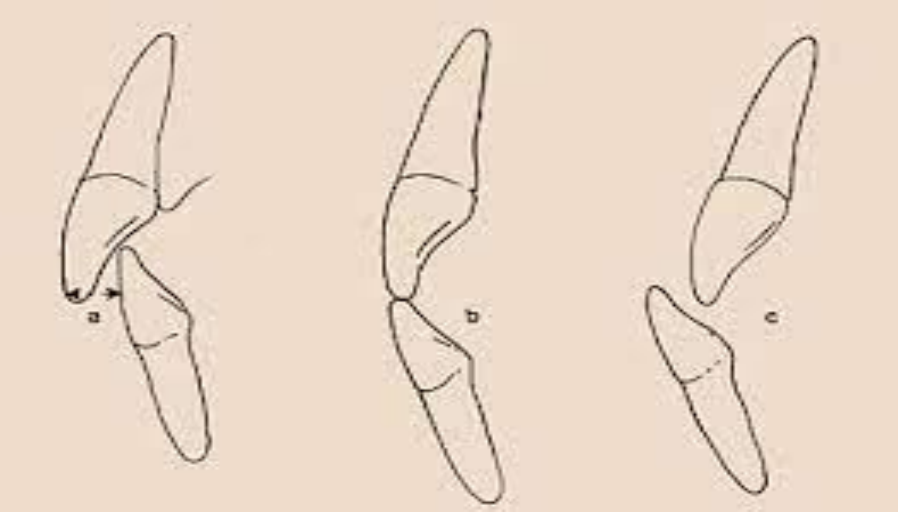

Fig. 1: Incisal overjet: (a) The ideal overjet relationship, (b) Edge-to-edge incisal position, (c) Reversed overjet.

Incisal overbite: The overbite is the vertical distance between the tips of the upper and lower incisors in occlusion (Fig.2).
It is governed by the degree of vertical development of the anterior dento-alveolar segments. Ideally, the lower incisors contact the middle third of the palatal surface of the upper incisors in occlusion (2-4 mm), but there may be an excessive overbite (deep bite), or there may be no incisal contact, in which case the overbite is described as *incomplete overbite* when the lower incisors are above the level of the upper incisal edges, or *anterior open bite* when the lower incisors are below the level of the upper incisal edges in occlusion.

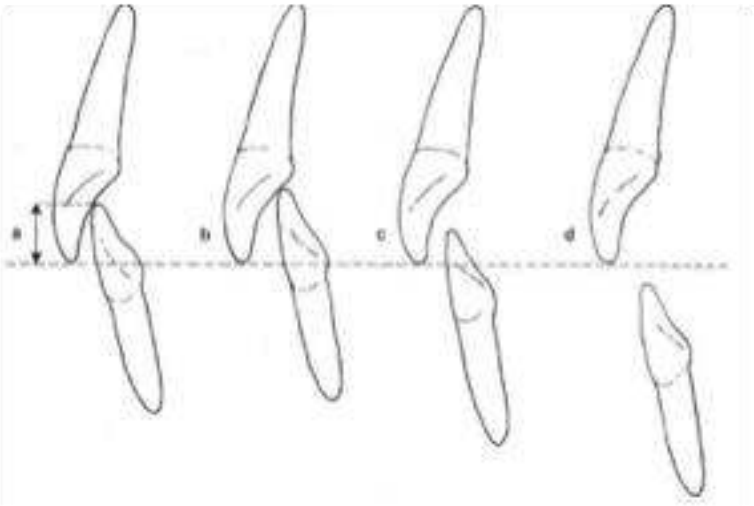

Fig.2: Incisal overbite: (a) Ideal overbite relationship, (b) Excessive incisal overbite (deepbite), (c) Incomplete overbite, (d) Anterior open bite.

Best wishes.