Lec.14

Gingival and periodontal pocket

Tooth gingival interface

The interface between a tooth and the surrounding gingival tissue is a dynamic structure. The gingival tissue forms a crevice surrounding the tooth, resembling a fluid-filled moat, wherein food debris, **endogenous and exogenous cells**, and chemicals float. The depth of this crevice, known as a sulcus, is in a constant state of flux due to microbial invasion and subsequent immune response. Located at the depth of the sulcus is the epithelial attachment, consisting of approximately **1 mm of junctional epithelium** and another **1 mm of gingival fiber attachment**, comprising the **2 mm of biological width** naturally found in the oral cavity. The sulcus is literally the area of separation between the surrounding epithelium and the surface of the encompassed tooth.

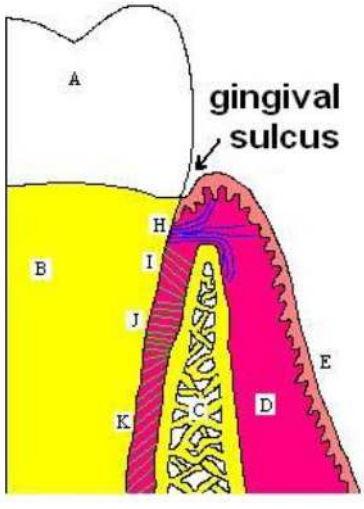

Gingival sulcus

A healthy sulcular depth is 3 millimeters or less. Through much investigation and research, it has been determined that sulcular depths of 3 millimeters or less are readily self-cleansable with a properly used toothbrush or the supplemental use of other oral hygiene aids. When the sulcular depth is chronically more than three millimeters, regular home care may be insufficient to properly cleanse the full depth of the sulcus, allowing food debris and microbes to accumulate, forming dental biofilm. This poses a danger to the periodontal ligament (PDL) fibers that attach the gingiva to the tooth. If accumulated microbes remain undisturbed in a sulcus for an extended period, they will penetrate and ultimately destroy the delicate soft tissue and periodontal attachment fibers. If left

untreated, this process may lead to a deepening of the sulcus, recession, destruction of the periodontium, including the bony tooth socket, tooth mobility, and tooth loss. Both the gingival and periodontal pocket are extensions of the gingival sulcus, which exists in health. Gingival and periodontal pockets are dental terms indicating the presence of an abnormal depth of the gingival sulcus near the point at which the gingival tissue contacts the tooth.

The pocket

✓ It's an inflammatory changes and apical migration of junctional epithelium; it is also defined as a pathological deepening of gingival sulcus, which occurs by coronal movement of gingival margin, apical displacement of gingival attachment, or both.

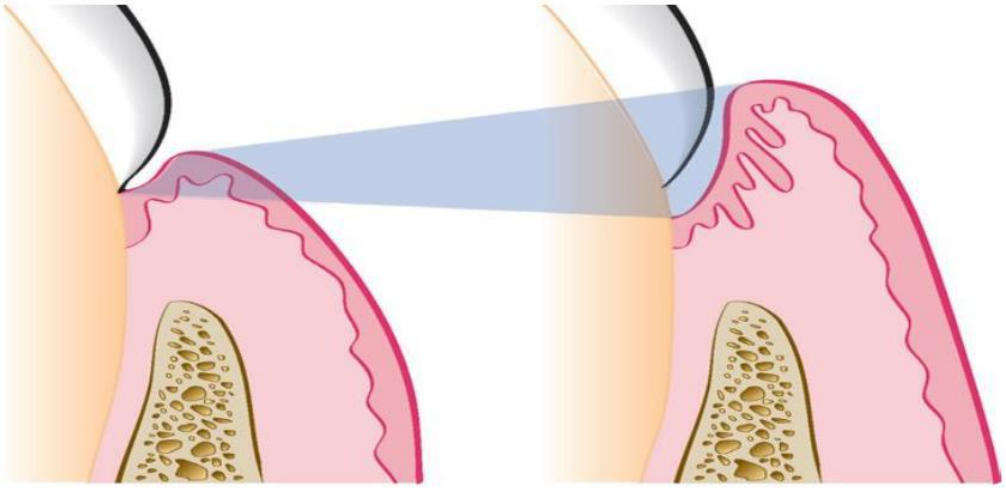

Classification:

1. According to the involved tooth surface:

a) Simple pocket: involve one surface

b) Compound pocket: involve more than one surface

c) Complex or spiral pocket: originating on one surface and twisting around the tooth to involve one or more additional surface (but it opens into the oral cavity on the surface of its origin). These types of pockets are most common in furcation areas.

2. According to its location:

A) Gingival pocket: which is formed by gingival enlargement without destruction of the underlying periodontal tissue. The sulcus is deepened because of increased bulk of the gingiva.

A gingival pocket presents when the marginal gingiva experiences an edematous reaction, whether due to localized irritation and subsequent inflammation, systemic issues, or drug-induced enlargement. Regardless of the etiology, when gingival enlargement occurs, greater than normal (the measurement in a pre-pathological state) periodontal probing measurements can be read, creating the illusion that periodontal pockets have developed. This phenomenon is also referred to as a false pocket or pseudo pocket. The epithelial attachment does not migrate, it simply remains at the same attachment level found in pre-pathological health. The only anatomical landmark experiencing migration is the gingival margin in a coronal direction.

In a gingival pocket, no destruction of the connective tissue fibers (gingival fibers) or alveolar bone occurs. This early sign of disease in the mouth is completely reversible when the etiology of the edematous reaction is eliminated and frequently occurs without dental surgical therapy. However, in certain situations, gingivectomy is necessary to reduce the gingival pocket depths to a healthy 1–3 mm.

B) Periodontal pocket: associated with the destruction of underlying supportive tissues. periodontal pocket, which is defined as a pathologically deepened gingival sulcus, is one of the most important clinical features of periodontal disease.

Pathogenesis of periodontal pocket initiated by accumulation and extension of microorganisms into gingival sulcus. All different types of periodontitis share histopathologic features, such as tissue changes in the periodontal pocket, mechanisms of tissue destruction, and healing mechanisms. However, they differ in their etiology, natural history, progression, and response to therapy.

3. According to its relation to alveolar crest:

a) Suprabony pocket: also called supra crestal or supra-alveolar. The base of the pocket is coronal to the level of underlying bone. The bone loss is horizontal

b) Infrabony pockets also known as sub crestal or intra alveolar pocket. The base of the pocket is apical to the level of adjacent bone. The bone loss is vertical.

Diagnosis/ detection of pockets

1. Careful exploration with periodontal probe. (this method is accurate).

2. Radiographic: pockets are not detected by the radiographic examination because pockets are soft tissue changes.

A calibrated silver points or gutta percha points can be used with radiography to assist in determining the level of attachment of the periodontal pocket.

Classification of periodontal probes: Periodontal probes may be divided into:

• First generation probes are conventional, and hand held probes , e.g. conventional periodontal probes.

• Second generation probes are pressure –sensitive probes. It has been shown that, with forces up to 30 gms the probe tip remains within junctional epithelium and forces up to 50gms are necessary to diagnose osseous defects. This probe did solve many problems of the conventional probes but lacked tactile sensitivity.

• Third generation probes are computerized probes. Gibbs et al designed Florida probe. E.g.-Foster Miller Probe, and Toronto Automated Probes, which can detect the cementoenamel junction

• Fourth-generation probes are the three-dimensional probes in which sequential

probe positions are measured. They are three-dimensional probes

• Fifth-generation probes are ultra-sonographic probes that provide painless probing to the patient. The guidance path is predetermined in these probes.

• Periodontal Probes have blunted, rod-shaped working ends that may be circular or rectangular in cross-sections

Pocket probing:

We have two different pocket depths:

1) Biologic or histologic depth: distance between gingival margin and base of the pocket. measured histologically (accurate measurement but not used routinely)

2) Clinical or probing depth: distance to which a probe penetrates the pocket.

The standardized force used for penetration of the probe is 25 grams (0.25 N)

Probing Pocket depth PPD: Distance between the base of the pocket measured by the periodontal probe and gingival margin.

Extent The "extent" of disease refers to the proportion of the dentition affected by the disease in terms of percentage of teeth.

Sites are defined as the positions at which probing measurements are taken around each tooth and, generally, six probing sites around each tooth are recorded, as follows:

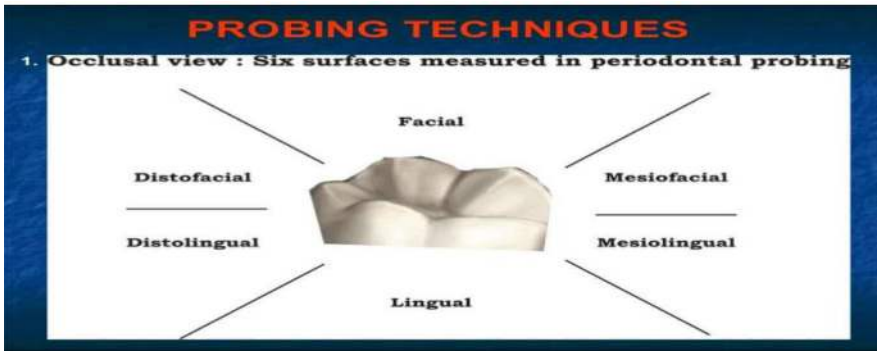

1. mesiobuccal

2. mid-buccal

3. distobuccal

4. mesiolingual

5. mid-lingual

6. distolingual

If up to 30% of teeth in the mouth are affected, the manifestation is classified as "localized"; for more than 30%, the term "generalized" is used. Probing techniques can reveal the extent of the disease

i. Occlusal view: six surfaces measured in periodontal probing

ii. In multirooted teeth, the possibility of furcation involvement should be carefully explored with specially designed probe (eg. Nabers probe).

The probe should be inserted parallel to the vertical axis of the tooth and walked circumferentially around each tooth to detect the area of deepest penetration.

iii. To detect an internal crater: the probe should be placed obliquely from both facial and lingual surfaces, so as to explore the deepest point of the pocket located beneath the contact point.

Periodontal probes are used to locate, measure, and mark pockets, as well as determine their course on individual configuration. The typical probe is a tapered, rod-like instrument calibrated in millimeters, with a blunt rounded tip The root surface wall of the pocket Root surface forms the medial wall of the pocket. As the pocket deepens, collagen fibers embedded in the cementum are destroyed, and the cementum becomes exposed to the oral environment. The root surface that gets exposed to the oral environment because of periodontal attachment loss undergoes the following changes (structural, chemical, cytological).

• Structural changes:

Exposure of cementum to the oral environment minerals present in saliva tend to get deposited on the cementum surface (Ca, F,P, Mg) area of hyper mineralization the root surface is exposed to oral fluids and bacterial plaque proteolysis of embedded remnants of Sharpey's fibers Area of demineralization root caries (yellowish or brown patch) The patient feels hypersensitivity to the thermal changes and sweets pulp exposure may occur in severe forms.(demineralization is related to dental carries)

• Chemical changes

Cementum exposed to saliva may absorb calcium, phosphorus, magnesium and fluoride. This increase in mineral content of the root surface alters the chemical composition of the cementum, making it resistant to dental caries.

• Cytotoxic changes:

Histological studies of periodontally involved cementum have shown the presence of bacteria in the cementum or endotoxins in the cementum. Collagenous remnants of Sharpey fibers in the cementum undergo degeneration, thereby creating an environment favorable to the penetration of bacteria. Bacterial penetration into the cementum can be found as deep as the cemento dentinal junction, and it may also enter the dentinal tubules.

Penetration and the growth of bacteria leads to fragmentation and breakdown of the cementum surface and results in areas of necrotic cementum that are separated from the tooth by masses of bacteria.

Content of the pocket:

1)Microorganisms.

2) Bacterial products (enzymes and endotoxins).

3)GCF.

4)Remnants of food

5)Salivary mucin.

6)Desquamated epithelial cells.

7)Leukocytes

8)Plaque covered calculus usually projects from the tooth surface

9)Purulent exudates may be present and this is a secondary feature because deep pocket may have little, or no pus and shallow pocket may have extensive pus formation so pus is not an indicator of the depth of pocket.

Surface Morphology of Tooth Wall

The following zones can be found in the bottom of a periodontal pocket

1. Cementum covered by calculus, in which all the changes can be found.

2. Attached plaque, which covers calculus, and which extends apically from it to a variable degree (typically 100 to 500 μm).

3. The zone of unattached plaque that surrounds attached plaque and extends apically to it. The zone of attachment of the junctional epithelium to the tooth.

4. A zone of semi destroyed connective tissue fibers may be apical to the junctional epithelium.

Zones 3, and 4 make up the "plaque-free zone" seen in extracted teeth.

Microtopography of the Gingival Wall

Scanning electron microscopy has permitted the description of several areas in the soft-tissue (gingival) wall of the periodontal pocket in which different types of activity take place. These areas are irregularly oval or elongated and adjacent to one another, and they measure about 50 to 200 μm. These findings suggest that the pocket wall is constantly changing because of the interaction between the host and the bacteria. The following areas have been noted:

1. Areas of relative quiescence, showing a relatively flat surface with minor depressions and mounds and occasional shedding of cells

2. Areas of bacterial accumulation, which appear as depressions on the epithelial surface, with abundant debris and bacterial clumps penetrating the enlarged intercellular spaces. These bacteria are mainly cocci, rods, and filaments, with a few spirochetes.

3. Areas of emergence of leukocytes, in which leukocytes appear in the pocket wall through holes located in the intercellular spaces.

4. Areas of leukocyte–bacteria interaction, in which numerous leukocytes are present and covered with bacteria in an apparent process of phagocytosis. Bacterial plaque associated with the epithelium is seen either as an organized matrix covered

by a fibrin like material in contact with the surface of cells or as bacteria penetrating the intercellular spaces.

5. Areas of intense epithelial desquamation, which consist of semi-attached and folded epithelial squames, which are sometimes partially covered with bacteria.

6. Areas of ulceration, with exposed connective tissue.

7. Areas of hemorrhage, with numerous erythrocytes.

The transition from one area to another could result from bacteria accumulating in previously quiescent areas and triggering the emergence of leukocytes and the leukocyte–bacteria interaction.This would lead to intense epithelial desquamation and finally to ulceration and hemorrhage.

Clinical features/histopathological features:

A.1- bluish red discoloration of the gingival wall of pocket, this caused due to circulatory stagnation.

2- flaccidity of tissue: due to destruction of gingival fibers.

3- smooth shiny surface: due to atrophy of the epithelium and edema.,

4- pitting on pressure: due to edema and degeneration.

B. Gingival wall may be pink or firm when fibrotic changes predominate over exudation and regeneration. particularly in relation to the outer surface of the pocket wall. However, despite the external appearance of health, the inner wall of the pocket invariably presents some degeneration and is often ulcerated

C. Bleeding on probing: due to

• Increased vascularity.

• Thinning and degeneration of epithelium.

• Proximity of engorged vessels to inner surface.

D. Probing is generally painful: due to ulceration of the inner aspect of the pocket wall.

E. Pus may be present: due to suppurative inflammation.

F. Other clinical features

• Thickened marginal gingiva.

• Loss of stippling.

• Tooth mobility and diastema formation

The epithelium of the lateral wall of the pocket becomes degenerated and atrophied.

The severity of the degenerative changes is not necessarily related to pocket depth

Destruction of Collagen fibers apical to the junctional epithelium and the area becomes occupied by the inflammatory cells and edema.

Mechanisms of collagen loss:

Two mechanisms involved:

➢ **First mechanism:**

Collagenases and other enzymes secreted by fibroblast, PMNs and macrophages in healthy and inflamed tissues, become extracellular and destroy collagen. These enzymes that degrade the collagen and other matrix macromolecules into small peptides are called matrix metalloproteinase.

➢ **Second mechanism**

Fibroblast phagocytize collagen fibers by extending cytoplasmic processes to the ligament-cementum interface and degrade the inserted collagen fibrils and the fibrils of cementum matrix.

Periodontal disease activity

1. Period of quiescence or inactivity this period characterized by reduced inflammatory response and little or no loss of bone and connective tissues.

2. period of exacerbation or activity bone and connective tissue attachment are lost and the pocket deepens. This period may last for days, weeks, months and eventually followed by period of remission and quiescence in which G+ve bacteria proliferate and more stable condition is established .

➢ Clinical feature shows bleeding spontaneous or on probing and a greater amount of gingival exudates

➢ Histological features, pocket appears thin and ulcerated, infiltrate composed of plasma cells and PMNs leukocytes.