Practical class on lymphatic system (1)

Side 1 :Lymph node

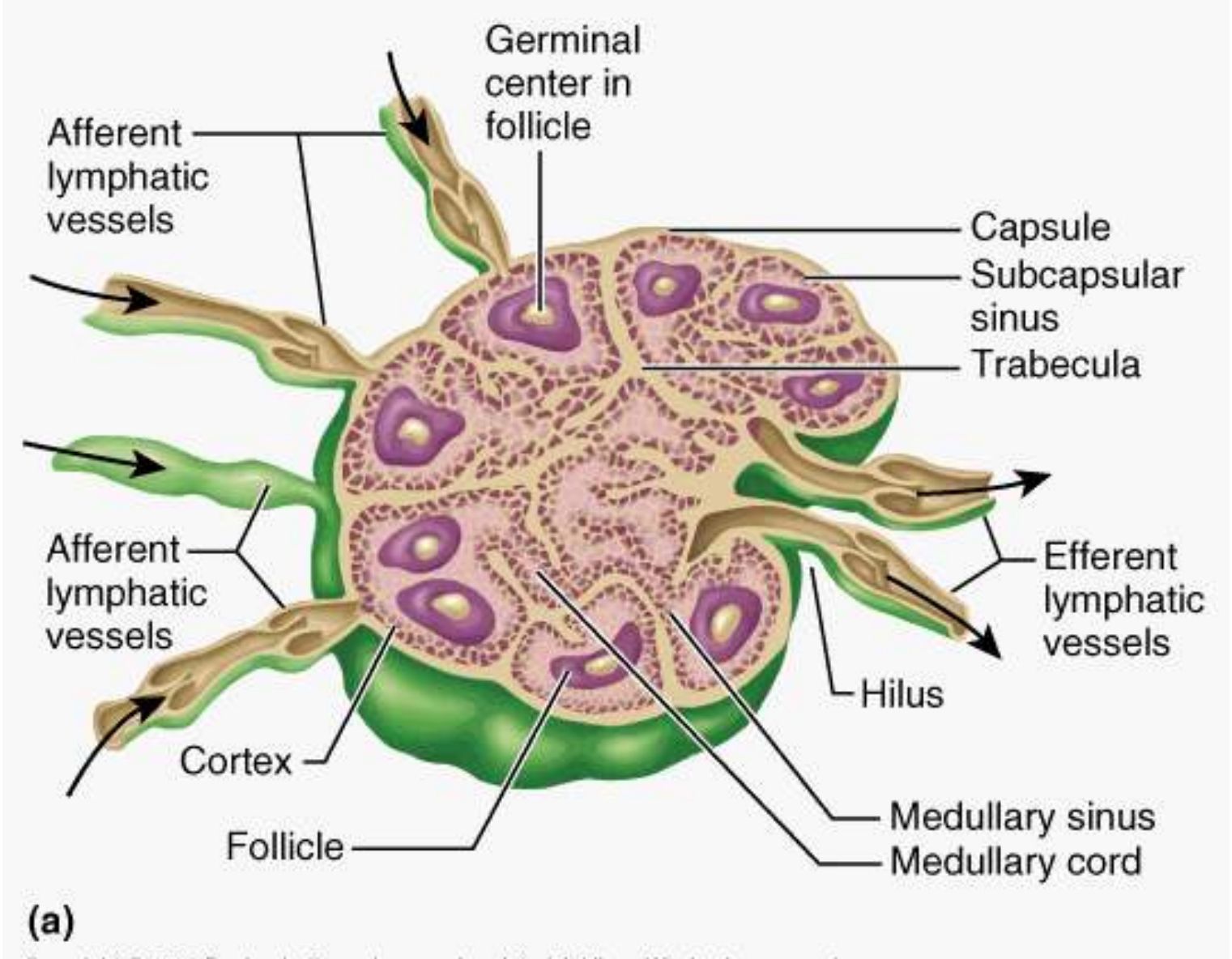

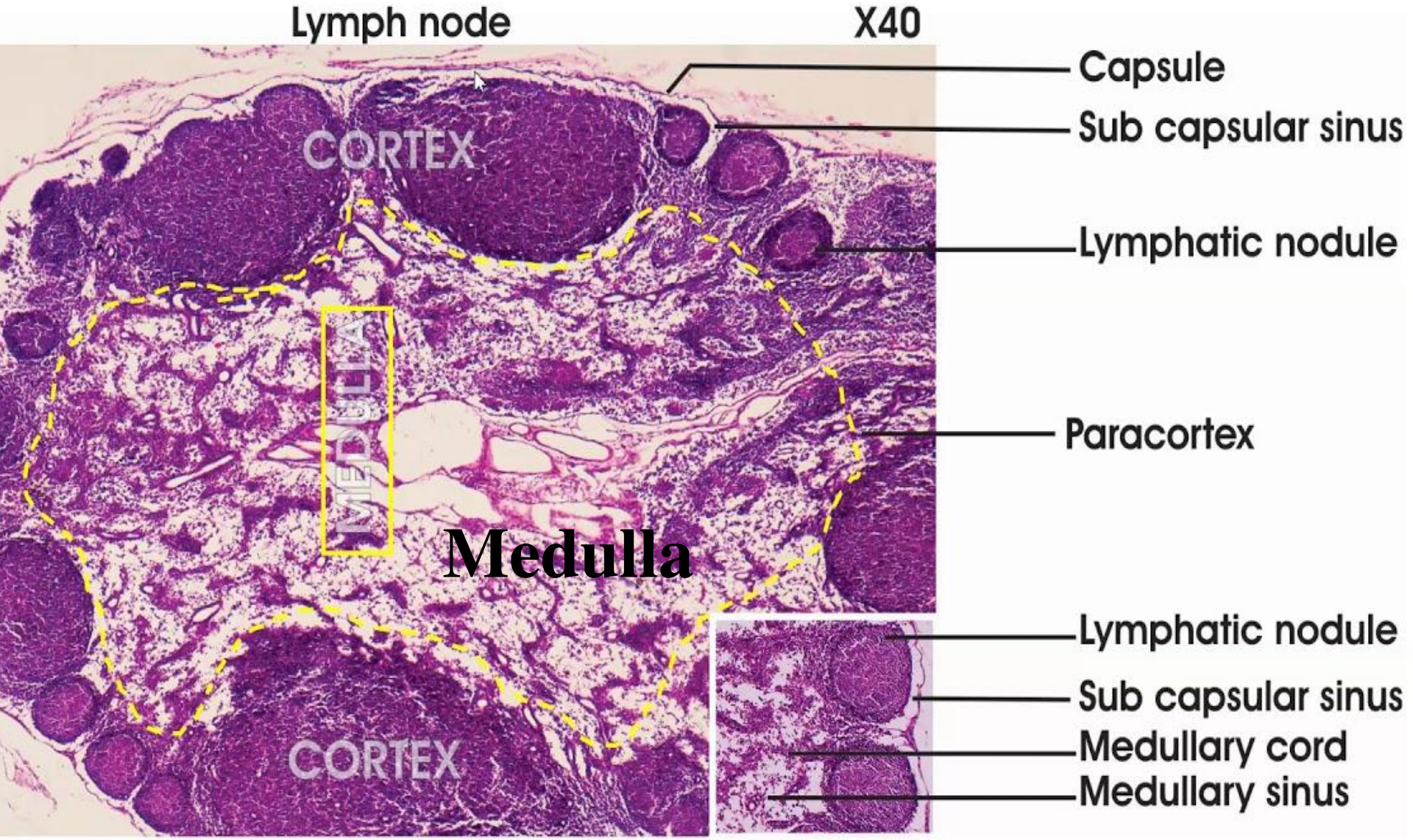
Lymph node
X40
Capsule
Sub capsular sinus
CORTEX
Lymphatic nodule
MEDULLA
Paracortex
Medulla
Lymphatic nodule
Sub capsular sinus
Medullary cord
Medullary sinus
CORTEX

Slide 2: Thymus

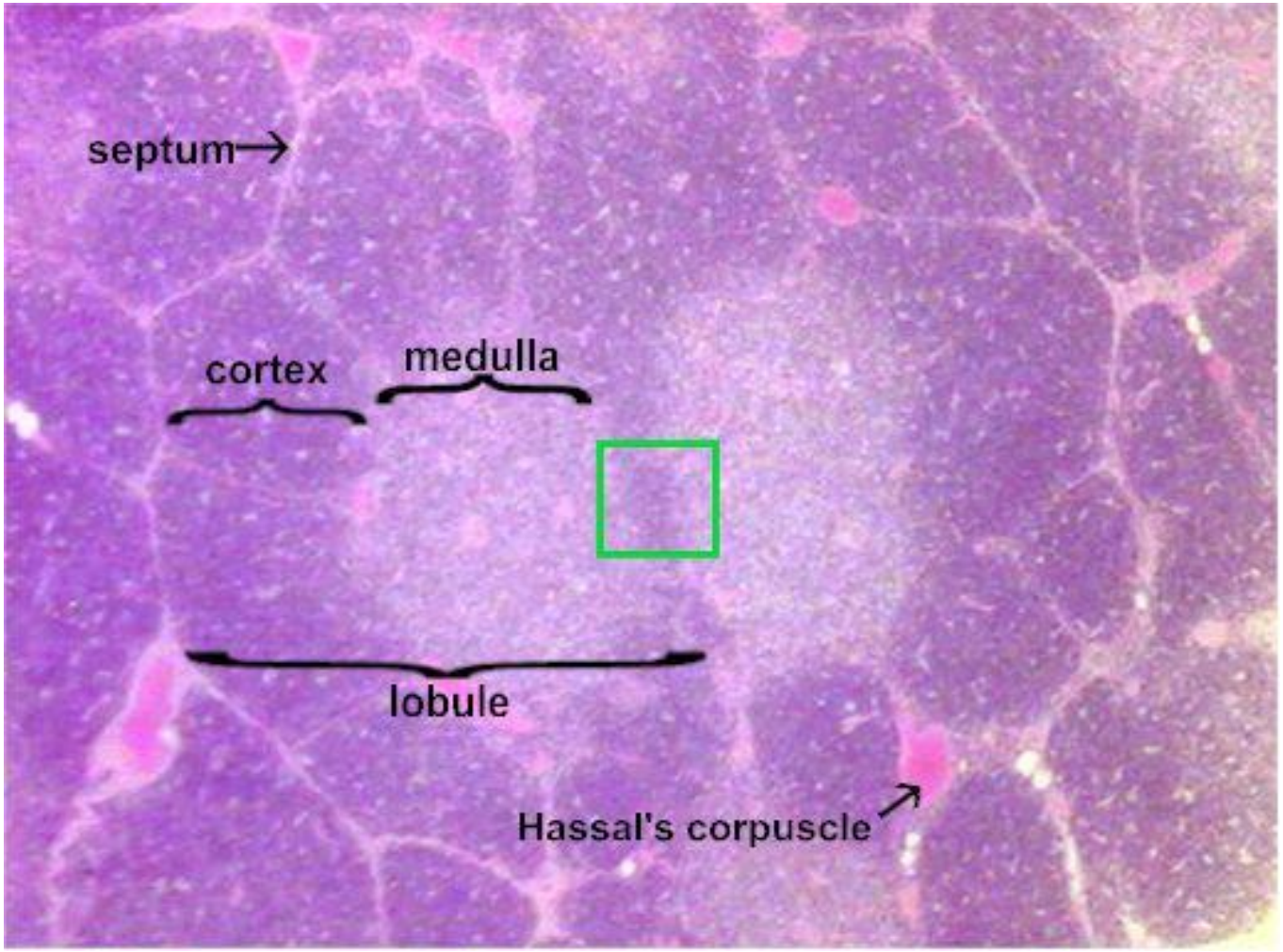

Slide 3 :Spleen

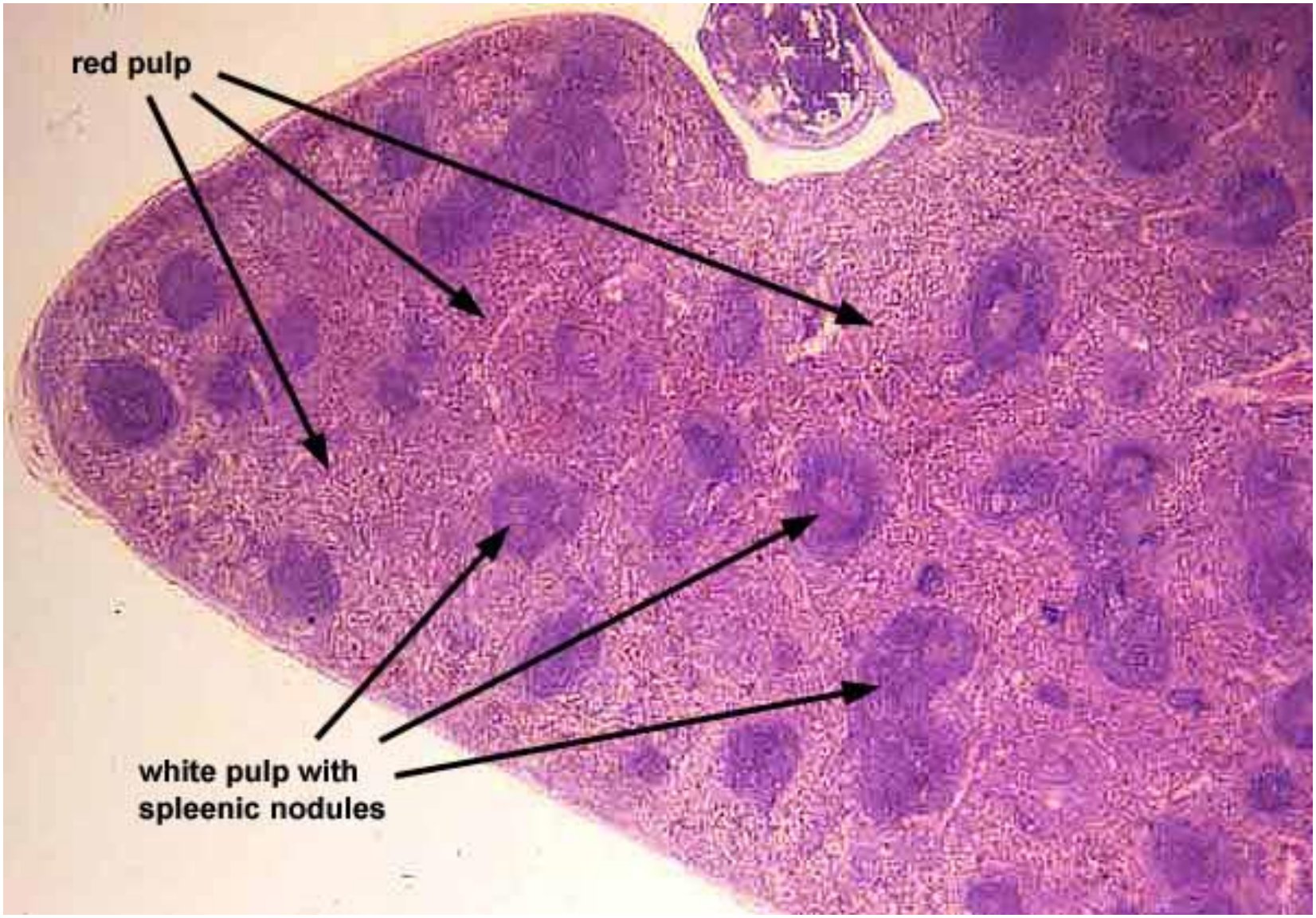

Slide 4 :Palatine tonsil

1 : Tonsilar crypt;2:stratified epithelium.; 5: Lymphatic nodule



A

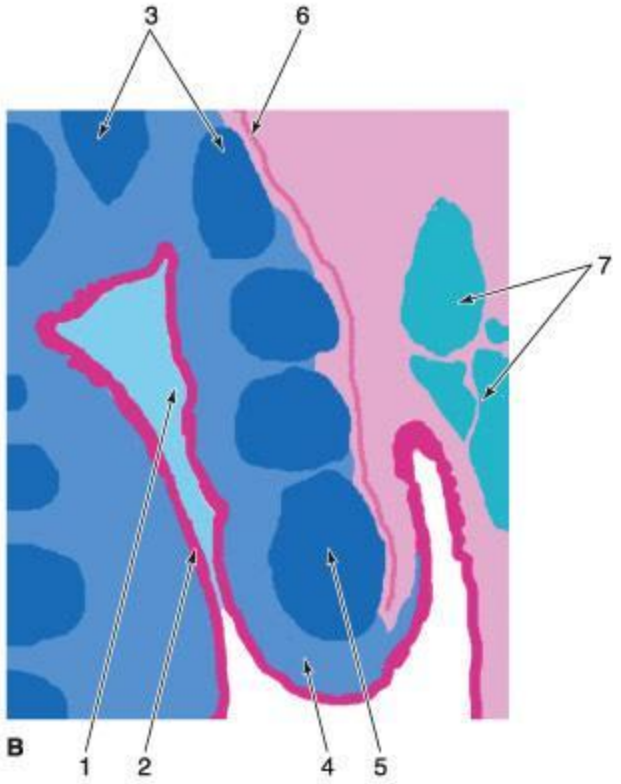

Copyright ©2006 by The McGraw-Hill Companies, Inc.
All rights reserved.