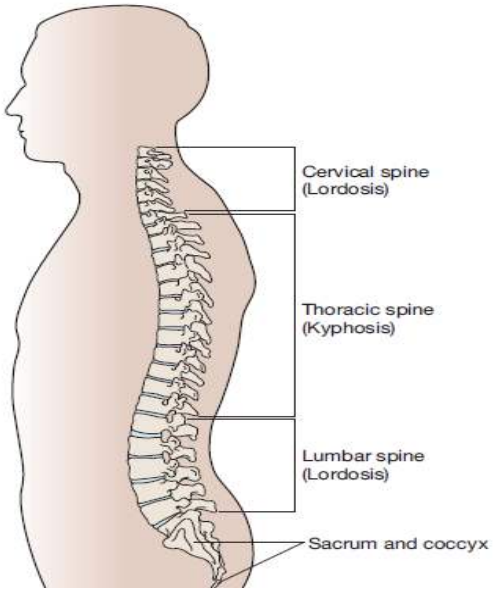
Cervical spine
(Lordosis)
Thoracic spine
(Kyphosis)
Lumbar spine
(Lordosis)
Sacrum and coccyx

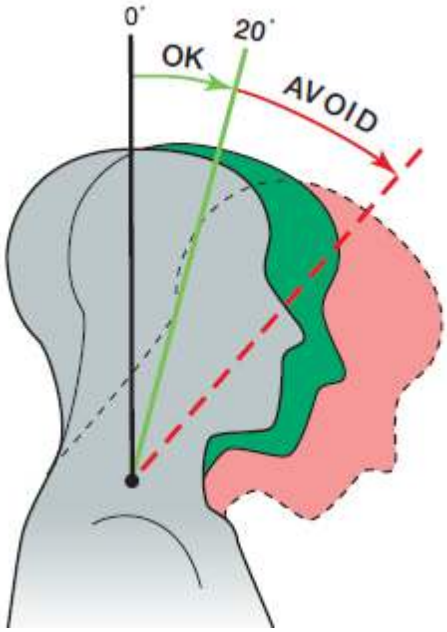
0°
20°
OK
AVOID

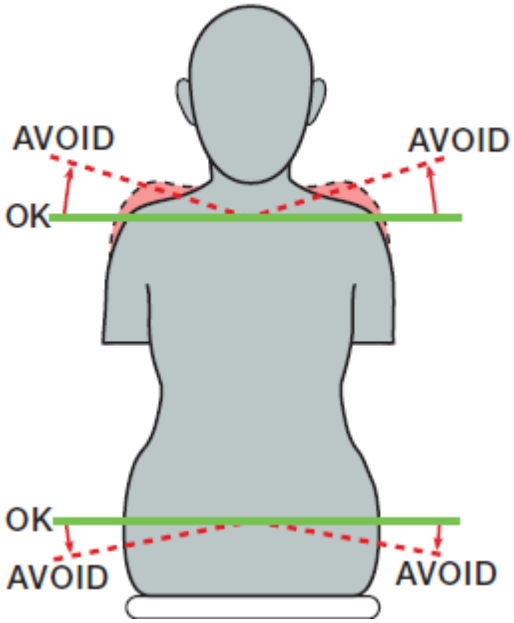
AVOID
AVOID
OK
OK
AVOID
AVOID

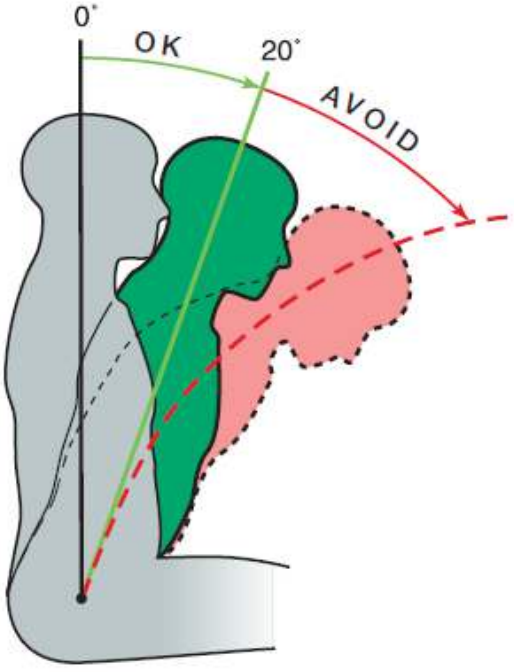
0°
OK
20°
AVOID

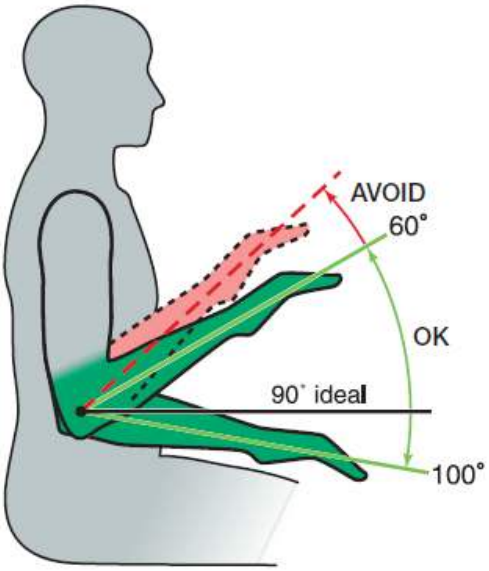
AVOID
60°
OK
90° ideal
100°

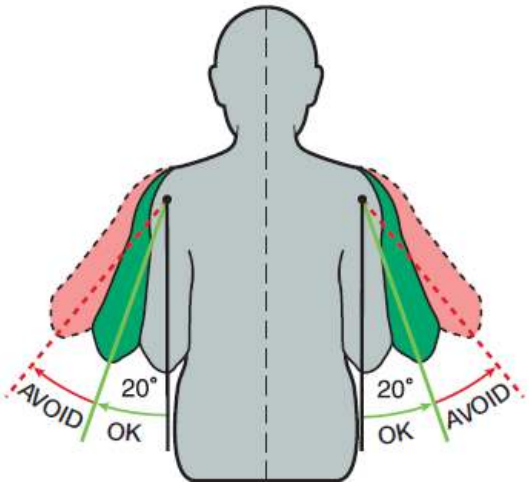
AVOID
20°
OK
20°
OK
AVOID

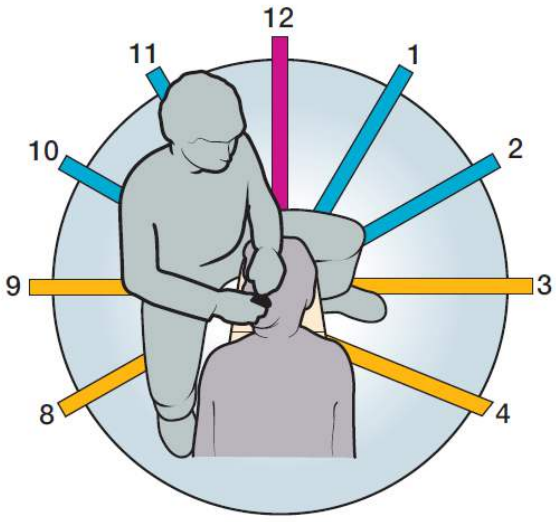
12
11
1
10
2
9
3
8
4

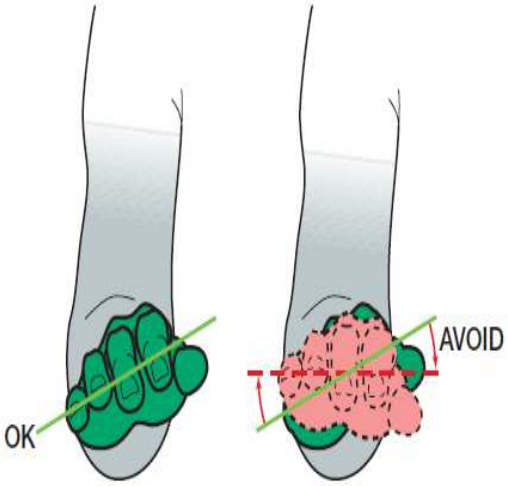
OK
AVOID

Right hand

Dentist position patient head patient teeth

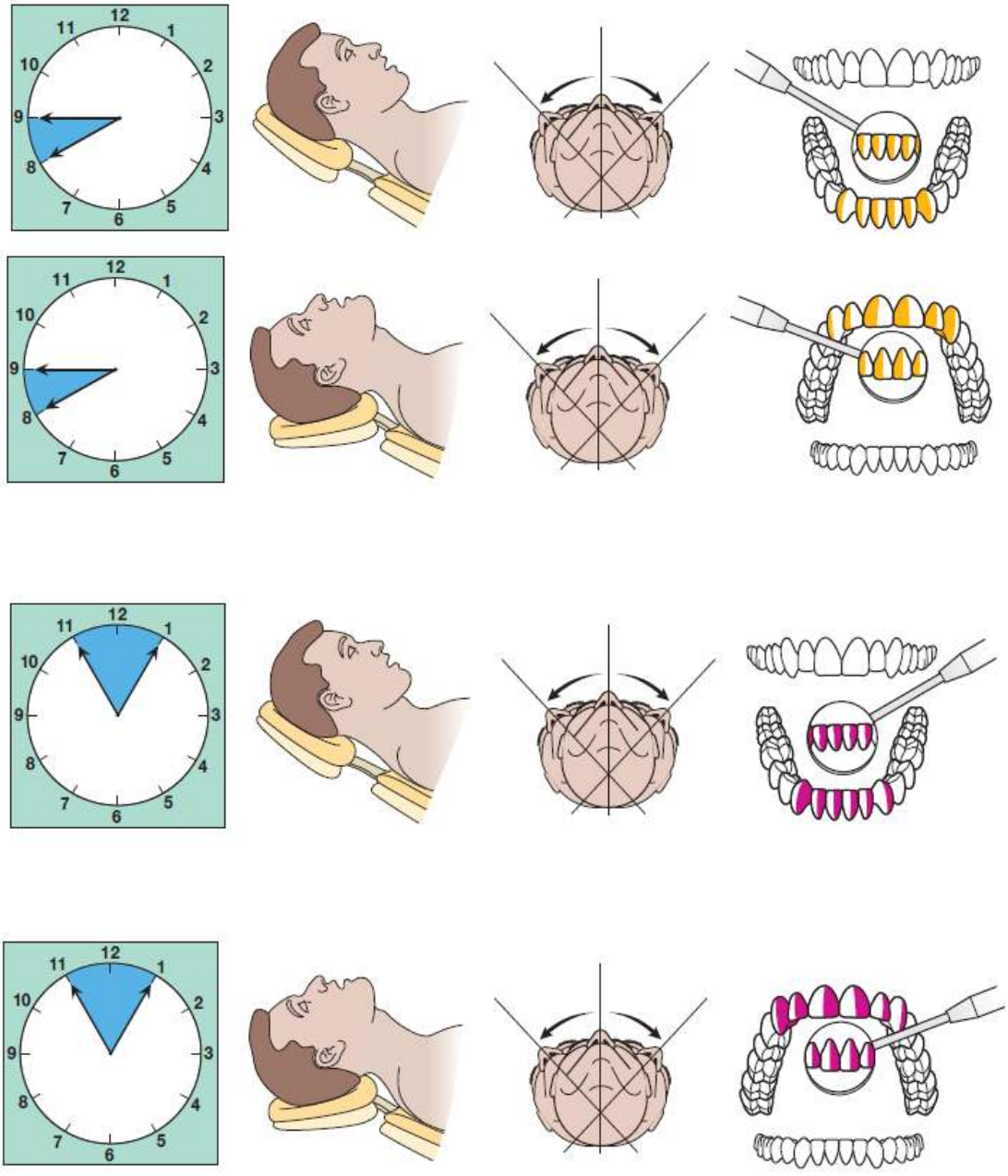

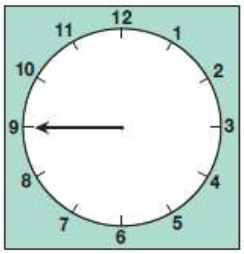
12
1
2
3
4
5
6
7
8
9
10
11
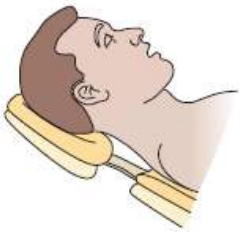
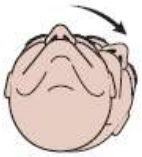
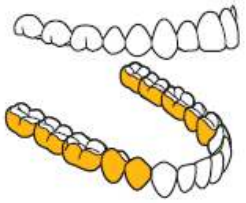
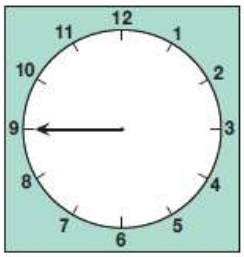
12
1
2
3
4
5
6
7
8
9
10
11
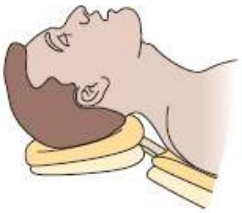

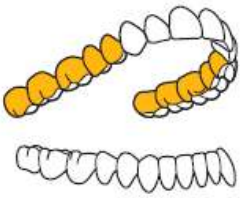
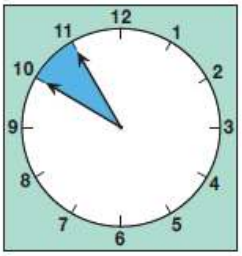
12
1
2
3
4
5
6
7
8
9
10
11


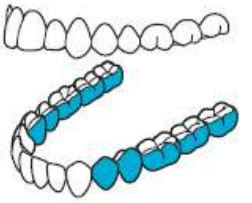

12
1
2
3
4
5
6
7
8
9
10
11
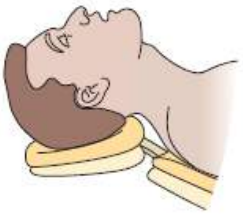

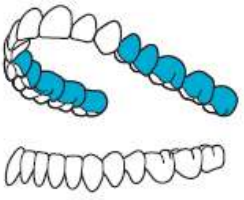

Treatment Area	Clock Position	Patient Head Position
Mandibular Arch—Anterior surfaces toward	8:00–9:00	Chin down; neutral to turned right or left
Maxillary Arch—Anterior surfaces toward	8:00–9:00	Chin up; neutral to turned right or left
Mandibular Arch—Anterior surfaces away	11:00–1:00	Chin down; neutral to turned right or left
Maxillary Arch—Anterior surfaces away	11:00–1:00	Chin up; neutral to turned right or left
Mandibular Arch—Posterior aspects toward	9:00	Chin down; neutral
Maxillary Arch—Posterior aspects toward	9:00	Chin up; neutral to turned slightly away
Mandibular Arch—Posterior aspects away	10:00–11:00	Chin down; toward
Maxillary Arch—Posterior aspects away	10:00–11:00	Chin up; toward

Left hand

Dentist position patient head patient teeth

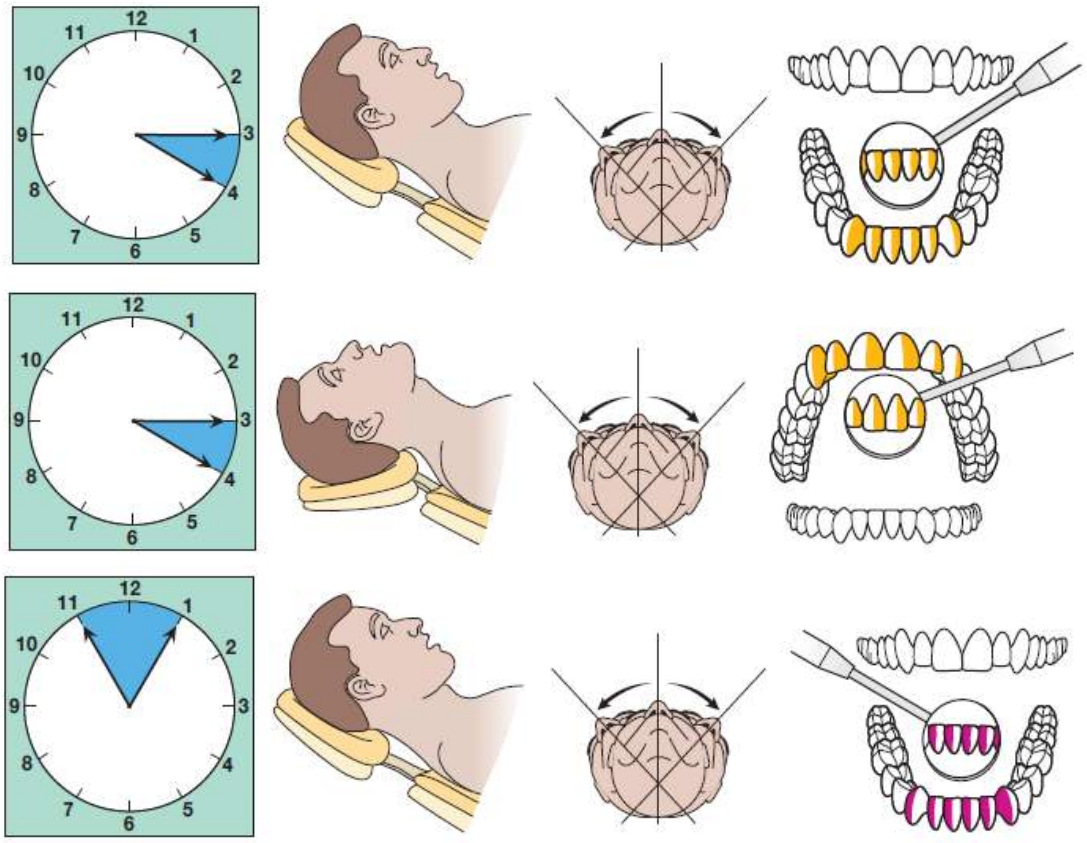

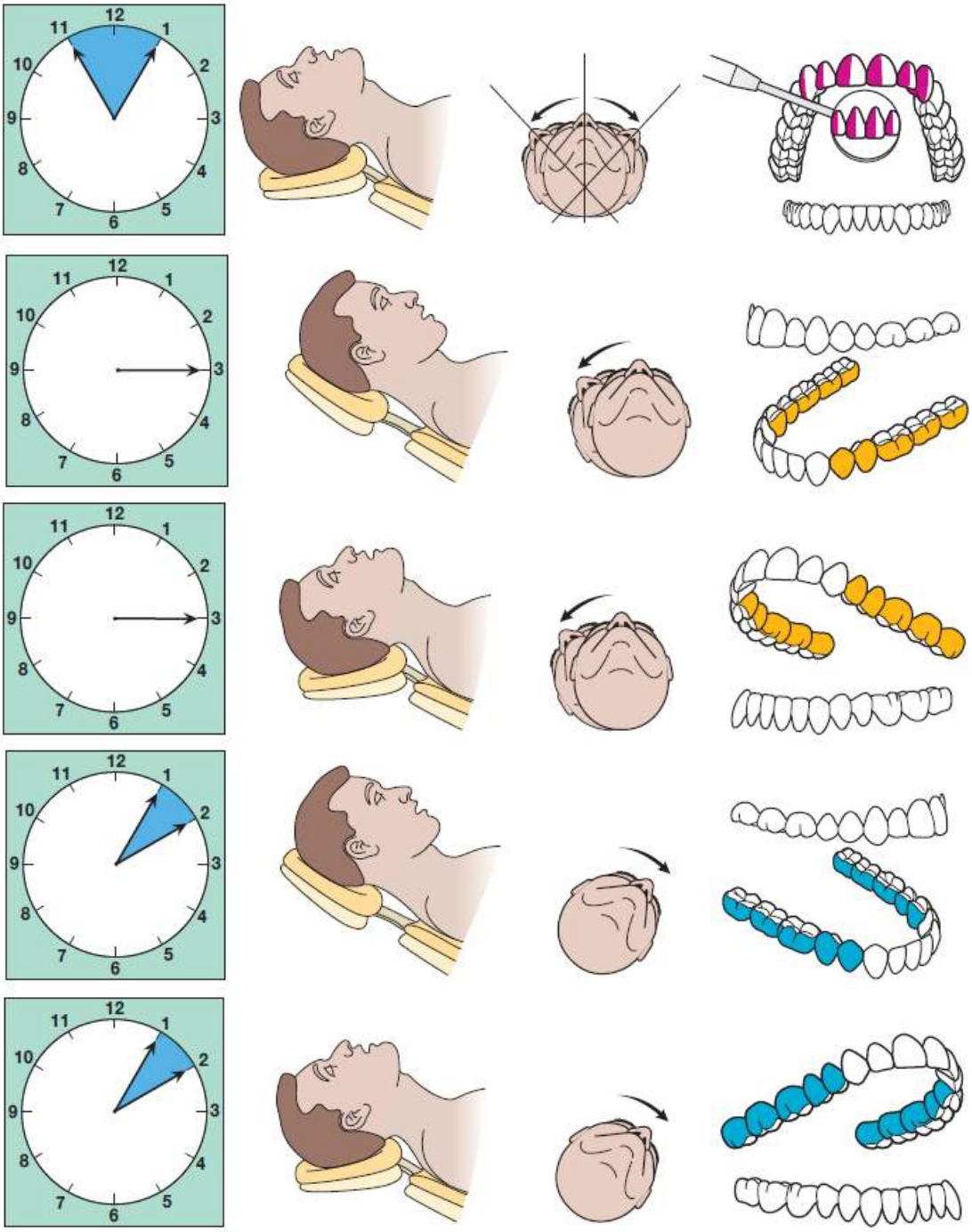
12
1
2
3
4
5
6
7
8
9
10
11

Treatment Area	Clock Position	Patient Head Position
Mandibular Arch—Anterior surfaces toward	3:00–4:00	Chin down; neutral to turned right or left
Maxillary Arch—Anterior surfaces toward	3:00–4:00	Chin up; neutral to turned right or left
Mandibular Arch—Anterior surfaces away	11:00–1:00	Chin down; neutral to turned right or left
Maxillary Arch—Anterior surfaces away	11:00–1:00	Chin up; neutral to turned right or left
Mandibular Arch—Posterior aspects toward	3:00	Chin down; neutral
Maxillary Arch—Posterior aspects toward	3:00	Chin up; neutral to turned slightly away
Mandibular Arch—Posterior aspects away	1:00–2:00	Chin down; toward
Maxillary Arch—Posterior aspects away	1:00–2:00	Chin up; toward

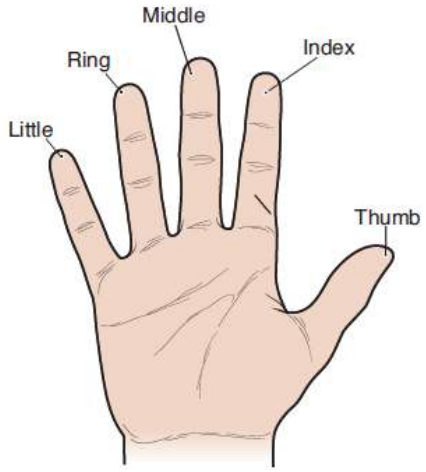

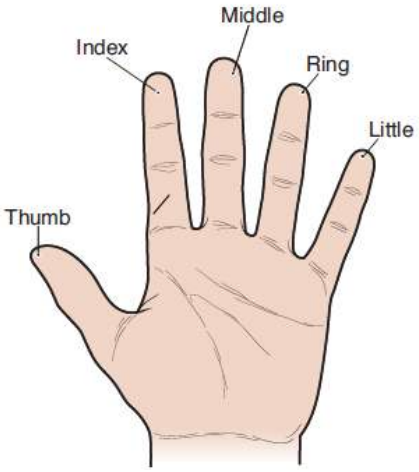

modified pen grasp

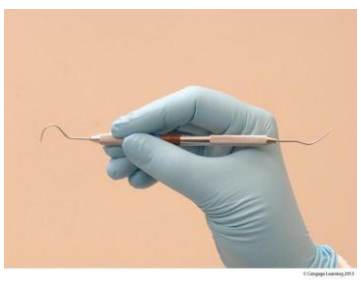

Palm grasp

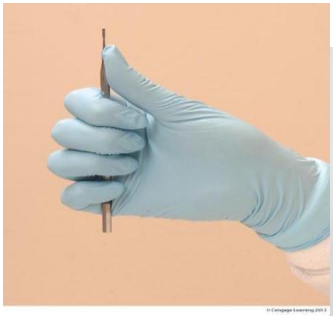

pen grasp



Digit(s)	Placement	Function
Index and Thumb	• On the instrument handle	• Hold the instrument
Middle Finger	• Rests lightly on the shank	• Helps to guide the working-end • Feels vibrations transmitted from the working-end to the shank[4]
Ring Finger	• On oral structure; often a tooth surface • Advances ahead of the other fingers in the grasp	• Stabilizes and supports the hand for control and strength
Little Finger	• Near ring finger; held in a natural, relaxed manner	• Has no function in the grasp

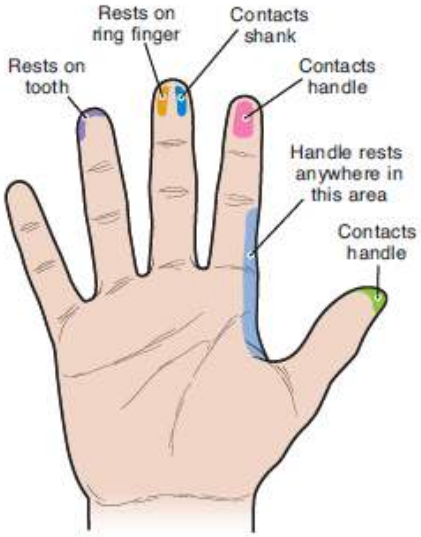

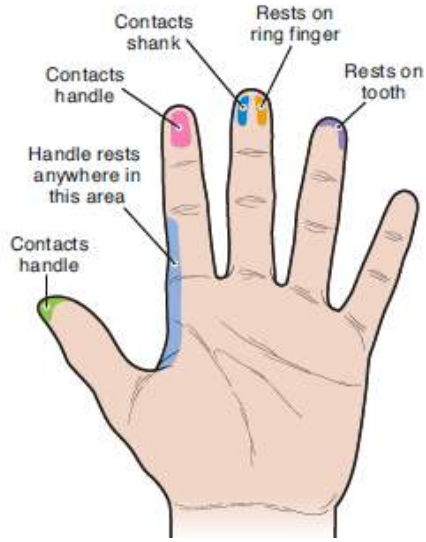



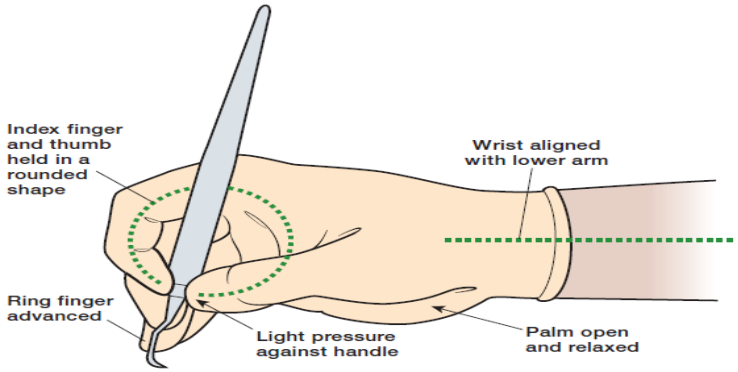

Grasp instrument of right hand



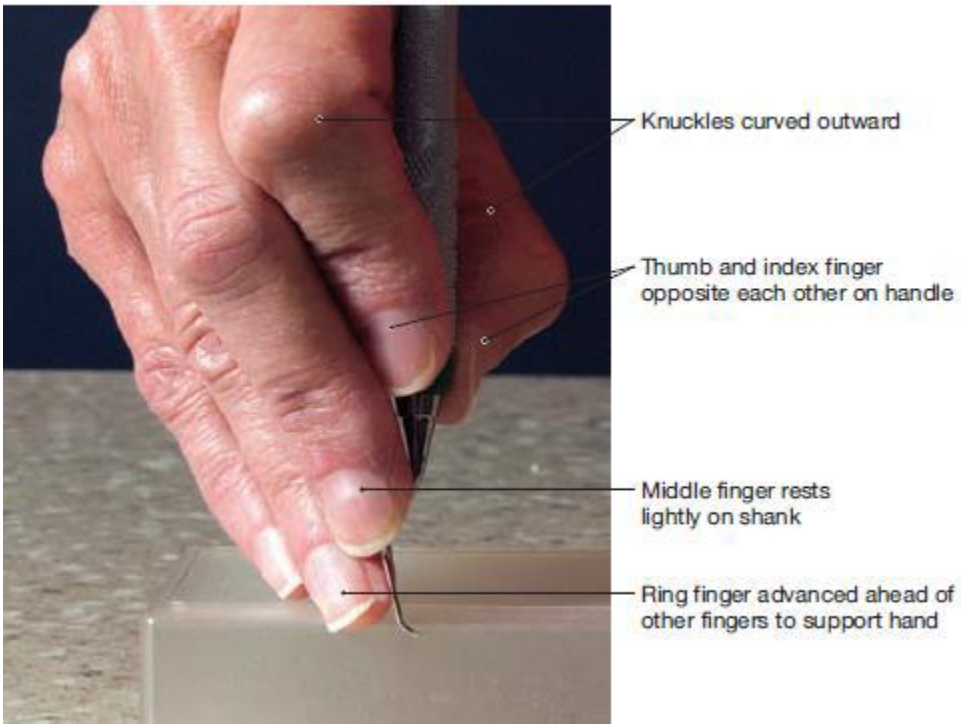

Grasp instrument of left hand





Finger rest










Types of periodontal probes

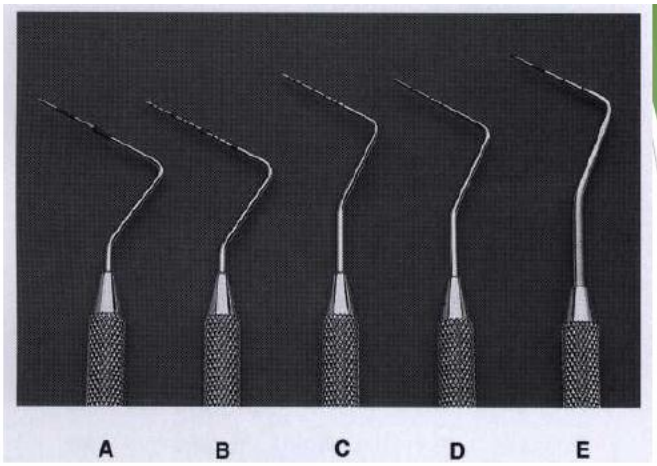

A, The Marquis color-coded probe. Calibrations are in 3-mm sections.
B, The UNC-15 probe, a 15-mm-long probe with millimeter markings at each millimeter and color coding at the 5th, 10th, and 15th mm.
C, The University of Michigan "O" probe, with Williams markings (at 1, 2, 3, 5, 7, 8, 9, and 10 mm).
D, The Michigan "O" probe with markings at 3, 6, and 8 mm.
E, The WHO (World Health Organization) probe, which has a 0.5 mm ball at the tip and millimeter markings at 3.5, 8.5, and 11.5 millimeters and color coding from 3.5 to 5.5 mm.

Checking tooth mobility checking lymph nodes

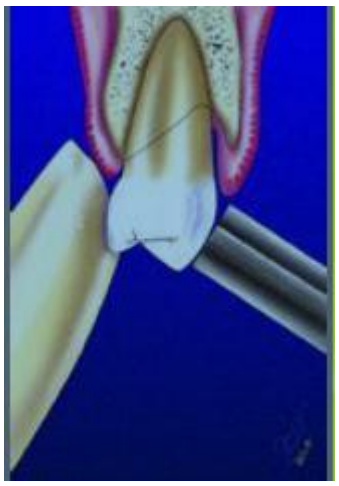





Instruction and motivation



Healthy gingiva, explain the normal, healthy features to your patient



Inflamed gingiva, show the patient the Signs of inflammation



X-ray for normal periodontium

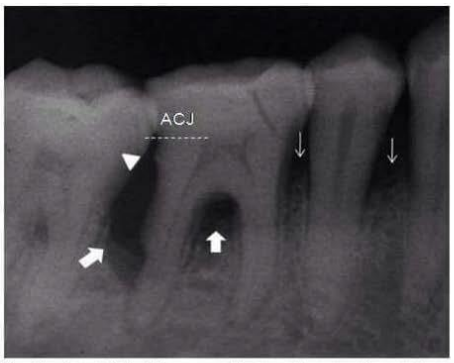

Periodontitis X-ray, show the patient the bone loss (arrows)

Show bacterial plaque







