Pulp

The dental pulp is a well vascularized specialized loose connective tissue, almost entirely enclosed by dentin. It is contained within the pulp chamber and root canals of the tooth. At the apical foramen it is continuous with the periodontal ligament. Pulp and dentin together form an embryological and functional unit called dentin –pulp complex.

Origin

The pulp is of ectomesenchymal origin, and developed from the dental papilla; when the enamel organ reaches the late bell stage and hard tissue formation begins. **At the time of root completion, the dental papilla name is changed to dental pulp**. It is only after formation of root apex, which occurs some times after tooth eruption, that the wide opening to the pulp is reduced to the dimensions of the apical foramen.

Organization

Each pulp is composed of a **coronal pulp** located centrally in the crown of the teeth and the root or **radicular pulp**.
The coronal pulp has a pulp horns which are protrusions that extend into the cusp of each tooth. Due to the continuous deposition of dentin throughout life, the size of the pulp chamber gradually decreases and obliteration of the pulp horns occurs.

The radicular pulp is that part of the pulp extending from the cervical region of the crown to the root apex. In the anterior teeth pulps are single and in the posterior ones they are multiple. The outline of the radicular pulp conforms to the dentinocemental junction. During root formation, apical root end is wide limited by the epithelial diaphragm; it resembles a wide open tube. With the complete formation of the root, the root canal becomes tapering and narrowed. Further narrowing of the apical foramen may be produced by the deposition of cementum inside the foramen.
Apical foramen: the radicular portion of the pulp is continuous with the periapical connective tissue through the apical foramen. The average size of the apical foramen of maxillary teeth in the adult is 0.4 mm, while in the mandibular teeth is 0.3 mm in diameter.

Accessory canals:
Where there is a connection between the pulp and the periodontal ligament other than the point of the apical foramen .Are commonly seen to extend from the radicular pulp laterally through the root dentin to the periodontal ligament. The mechanisms of formation of accessory canal are:

1. When blood vessels encounter a root dentin formation.
2. Premature degeneration of epithelial root sheath before the differentiation of the odontoblasts.

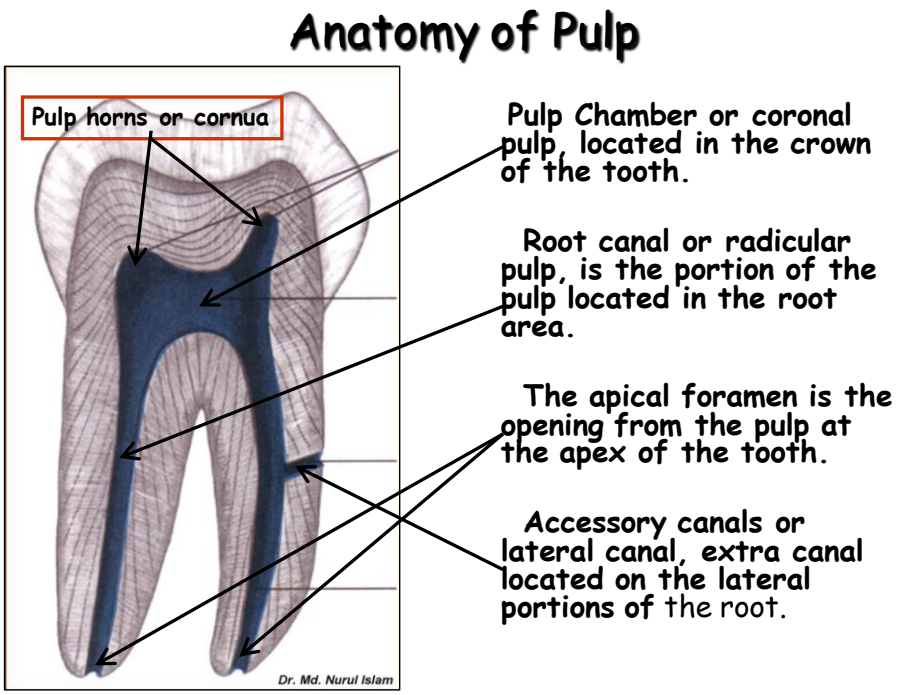

The apical constriction

It is defined as the apical part of the root canal with the narrowest diameter.

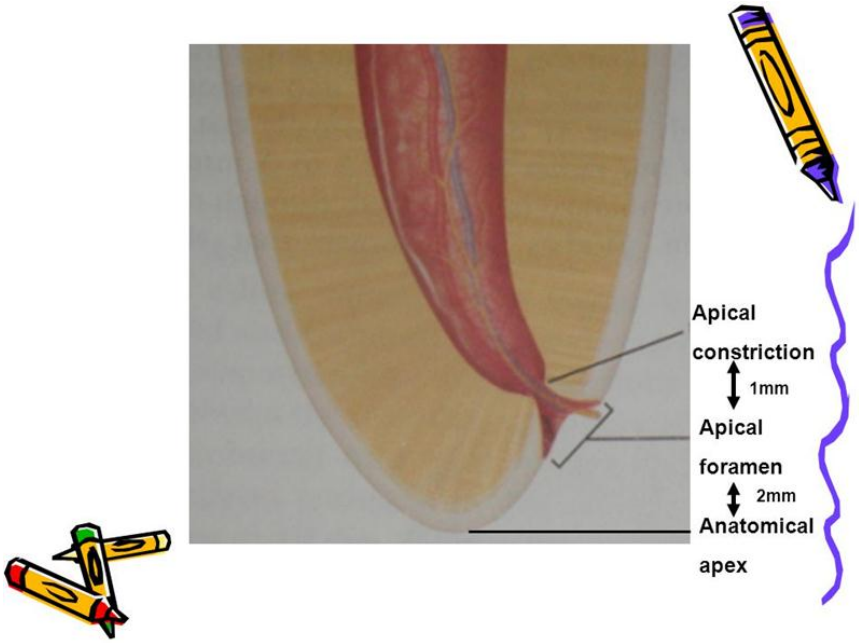

Histological Structure :

The dental pulp is formed of specialized **loose connective tissue**. It is formed of the three elements: cells, fibers, intercellular substance, and blood vessels and nerves. The intercellular substance is dense and gel –like in consistency. It is formed of hyaluronic acid which is non-sulfated glycosaminoglycan and glycoprotein. Glycosaminoglycans are important for attraction of water molecules to the pulp intercellular or ground substance.

A. Cells: The cells of the pulp may be divided into:

a. Formative cells: odontoblasts and fibroblasts.
b. Defensive cells: macrophages, lymphocytes, eosinophils, mast cells and plasma cells.
c. Progenitors: undifferentiated mesenchymal cells.

I. Formative cells:

a. Odontoblasts: The odontoblasts are found adjacent to the predentin with the cell bodies in the pulp and the cell processes in the dentinal tubules. The length of odontoblasts varies in different parts of the tooth. They are long in the crown, cuboidal in the mid root, and flattened near the root apex. During active dentinogenesis, the cell bodies contain well developed Golgi apparatus, RER, numerous mitochondria.

b. Fibroblasts: These are most numerous types of cells**.** These cells are responsible for the synthesis of fibers and ground (intercellular) substance of the pulp.

Zones of the pulp:

a. Odontoblast cell layer.

b.Immediately beneath the odontoblastic layer a **cell free zone** can often be seen. This zone is the area of mobilization and replacement of odontoblasts .

c. Beneath the **cell free zone** there is a narrow zone of pulp tissue, this is a **cell rich zone.** The cell rich zone is composed mainly of fibroblasts and undifferentiated ectomesenchymal cells.

The odontogenic zone is composed of odontoblasts, the cell free zone, and the cell rich zone.

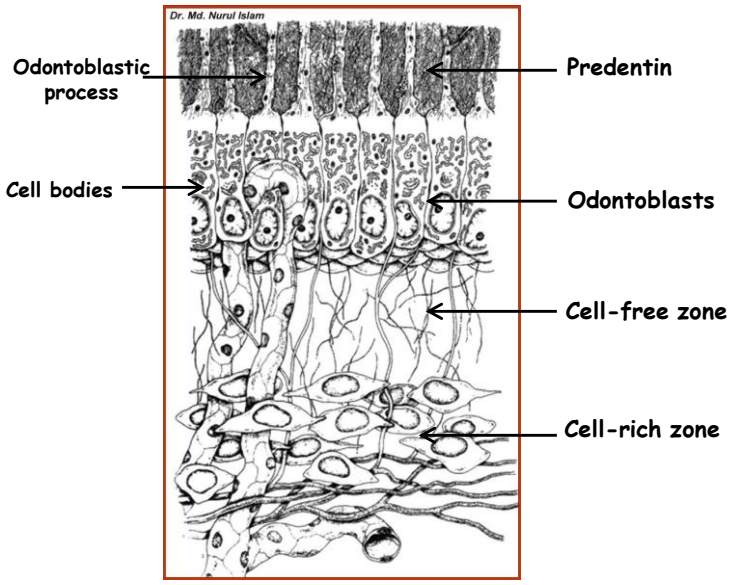

II. **Defensive cells:**

a. Macrophages: They are important during inflammation.
b. Plasma cells: These cells are seen during inflammation.The plasma cells produce antibodies.
c. Lymphocytes and eosinophils: They are found in normal pulp and they increase during inflammation.
d. Mast cellsThese cells are containing granules loaded with histamine and heparin.

III. **Progenitor (undifferentiated ectomesenchymal cells) cells**:They are usually found close to the walls of blood vessels (perivascular or **pericytes** cells). These cells have the potentiality of forming other types of formative cells of the pulp. **Depending on the stimulus, these cells may give rise to odontoblasts and fibroblasts.**

The fibers and ground substances: The collagen fibers and the extracellular ground substances surround of the pulp. Both types I and III collagen have been found in the pulp, both types are produced by fibroblasts. There are no elastic fibers in the pulp except those in the walls of blood vessels. The ground substance provides the environment that promotes life of the cells.

Blood vessels and nerves:

The pulp is highly vascularized. It is supplied by the inferior and superior alveolar arteries and drained by the same veins. The pulpal blood flow is more rapid than in most areas of the body.

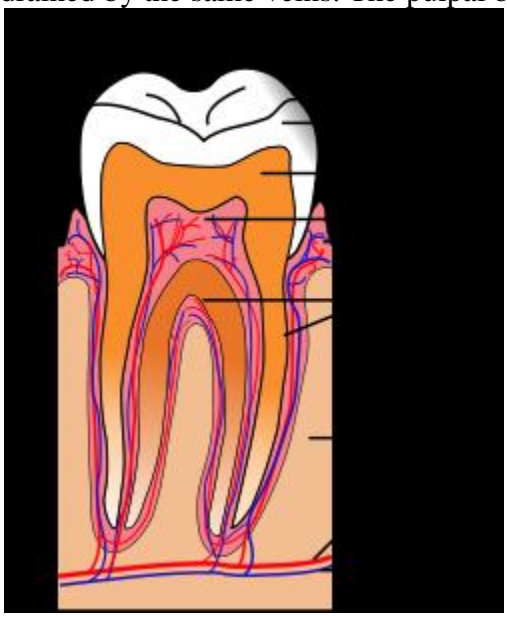

The figure is showing the straight direction of the blood vessels from the apical foramen towards the coronal pulp.

The **pericytes** surrounding the capillaries have a role in controlling the blood flow by reducing the diameter of the capillary in case of drinking cold drink to reduce the temperature in the blood. The cells also cause dilatation of the vessels in case of drinking hot drink. In both cases the pain sensation is diminished. The pericytes are differentiating into **new generation** of odontoblasts in cases of the death of the original odontoblast to produce **reparative dentin.**

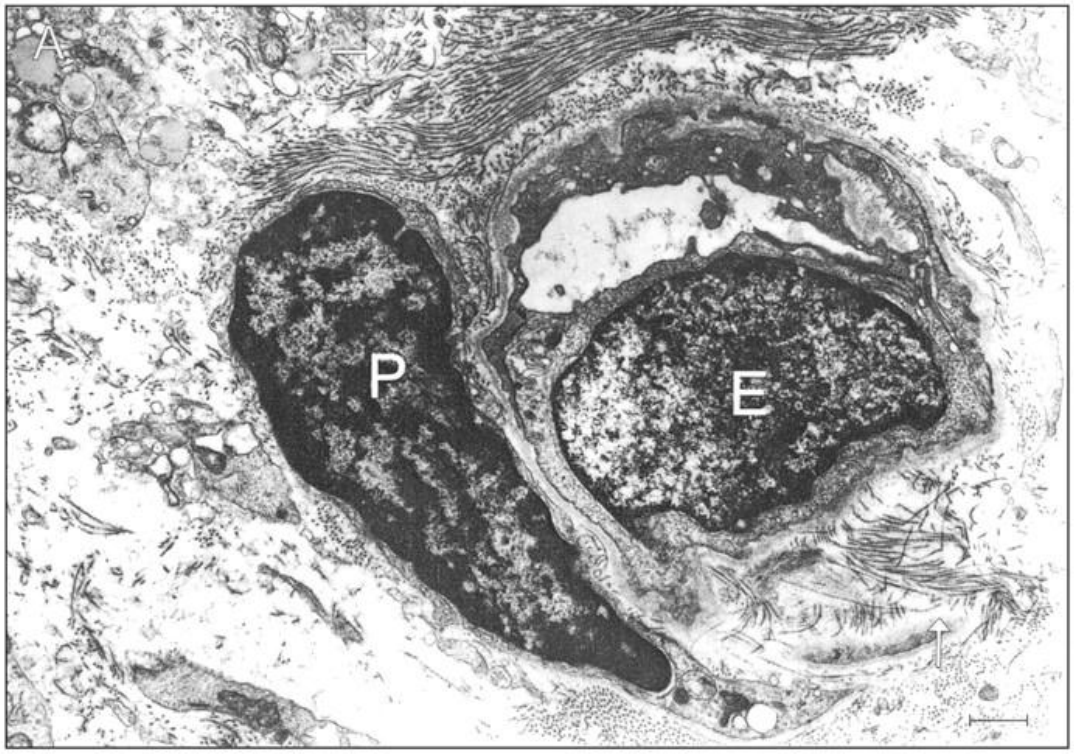

Fig.(57): Pericyte (P)around blood capillary; E: endothelial cell of blood capillary

Lymph vessels in the pulp drainage pass to submandibular and deep cervical lymph nodes.

Nerves:

The pulp has an abundant nerve supply which follows the distribution of the blood vessels. Two types of nerve fibers are present:

1. Non-myelinated fibers: found in close association with the blood vessels of the pulp and are sympathetic in nature which control the contraction of their smooth muscles.

1. Myelinated fibers: sensory nerves and they carry sensation to the brain. The nerve fibers enter the apical foramen and divides into many branches till reaching the cell rich zone where they lose their myelin sheath. The branches of these fibers form a plexus located adjacent to cell rich zone. This is termed **parietal layer** of nerves or **plexus of Raschkow**. The nerve fibers enter the dentinal tubules for short distance, not more than 0.2 mm. More nerve endings are found in pulp horns than in peripheral areas of the coronal or radicular pulp.
Sensory response in the pulp cannot differentiate between heat, touch, pressure, or chemicals. This is because the pulp organs lack those types of receptors. So the sensory nerve endings in the pulp are **pain receptors only.**

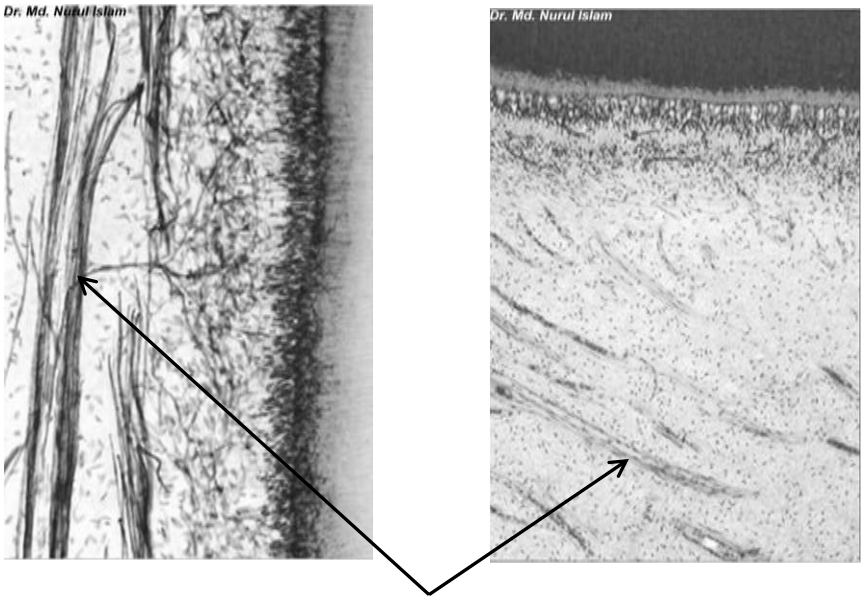

Nerves in pulp

Functions of the pulp:

1. Formative: The pulp cells (odontoblasts) produce dentin.
2. Nutritive: The pulp nourishes the dentin through the odontoblasts and their processes, and also by the means of blood vascular system of the pulp.
3. Protective: The sensory nerves in the tooth respond with pain to all kinds of stimuli such as heat, cold, pressure, chemical agents and operative cutting.
4. Reparative: By formation of reparative dentin. The pulp also has defense cells which aid in the process of repair of the pulp.

The age changes of the pulp:

1. The age changes are more accelerated in primary teeth than permanent teeth.
2. Decrease in number of cells: there are fewer cells in the aging pulp. There is also decrease in the undifferentiated ectomesenchymal cells which lead to a diminishing in the pulp ability for repair and regenerative ability.
3. Fibrosis: Increase and accumulation of both bundles and bundles of collagen fibers. The ground substance becomes less aqueous.

4. Decrease in blood supply due to progressive narrowing of the apical foramen, leading to the decrease in the vitality of the odontoblasts..
5. Atherosclerotic plaques may appear in pulpal vessels especially near the apical foramen.
6. Pulp recession: As a result of deposition of both secondary and tertiary dentin.
7. Pulp stones (denticles): Are calcified masses appearing either in coronal or radicular pulp. They are classified according to their structure into:

a. True pulp stone: either
   I. Attached when attaching to the wall of dentin.
   II. Or free in the pulp. True pulp stone is caused by inclusion of remnants of epithelial root sheath with the pulp. The remnant of epithelial root sheath induces the undifferentiated cells of the pulp to differentiate into odontoblasts, which then deposit the dentin –like material called true pulp stone. The true pulp stone exhibits dentinal tubule arrangement.
b. False pulp stone: either free in pulp ,or attaching to wall of dentin.

   False pulp stones do not exhibit dentinal tubules arrangement. They appear as concentric layer of calcified tissue within either the bundles of collagen fibers, or around blood vessels where there is a remnant of necrotic or calcified cells.
   All pulp stone begin as small nodules but increase in size by incremental growth on their surface.

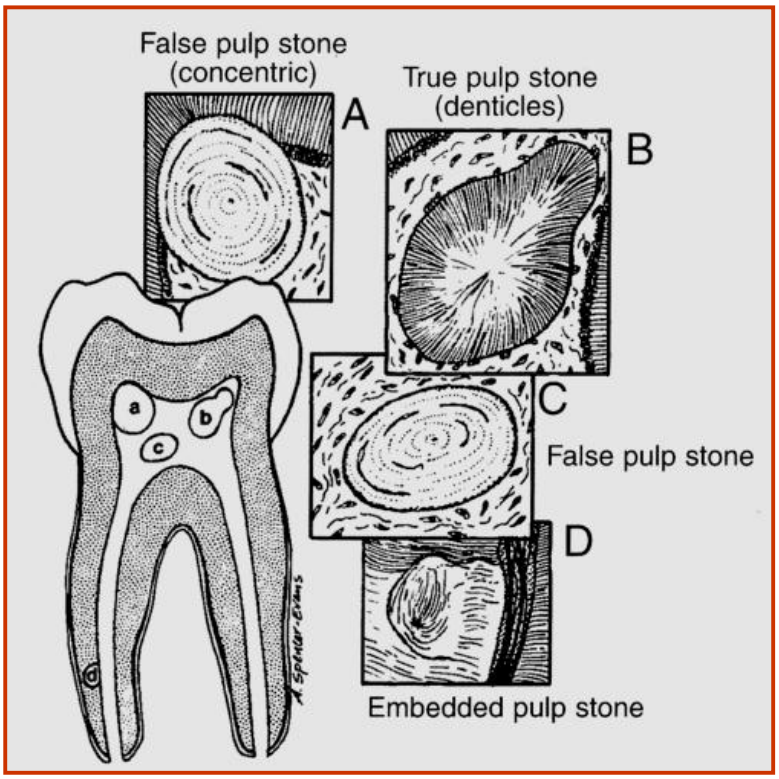

8. Diffuse calcification: Are irregular calcified deposits in pulp tissue in the path of blood vessels and collagen fibers especially in root canal and less often in coronal pulp.

Clinical consideration

1. Reaction in the pulp depends on the nature and severity of the stimuli on the pulp. Secondary dentin will be deposited in case of mild stimulation. When the reaction is severing, tertiary dentin will be deposited.
2. The preparation of non caries teeth for crowns or as a bridge, the possibility of pulp damage is even greater than in the cavity preparation(after caries), as the pulp has not previously been able to protect itself by secondary or tertiary dentin formation as would be the case where a carious cavity existed.
3. The pain experienced with pulpitis is mainly due to the effect of hyperemic and exudative changes accompanying inflammation which induce pressure on the nerve fibers of the pulp.