SKIN

The skin is an organ that forms a protective barrier against germs (and other organisms). The skin is the heaviest single organ of the body, accounting for about 16% of total body weight, and shows marked variation in structure at different sites in the body surface.

Skin is made up of two layers that cover a third fatty layer. The outer layer is called the *epidermis (ectoderm in origin)*; it is a tough protective layer that contains melanin (which protects against the rays of the sun and gives the skin its color). The second layer (located under the epidermis) is called the *dermis (mesoderm in origin)*; it contains nerve endings, sweat glands, sebaceous (oil glands), and hair follicles. Under these two skin layers is a fatty loose connective tissue layer of subcutaneous tissue: the *hypodermis* ;(the word subcutaneous means "under the skin").

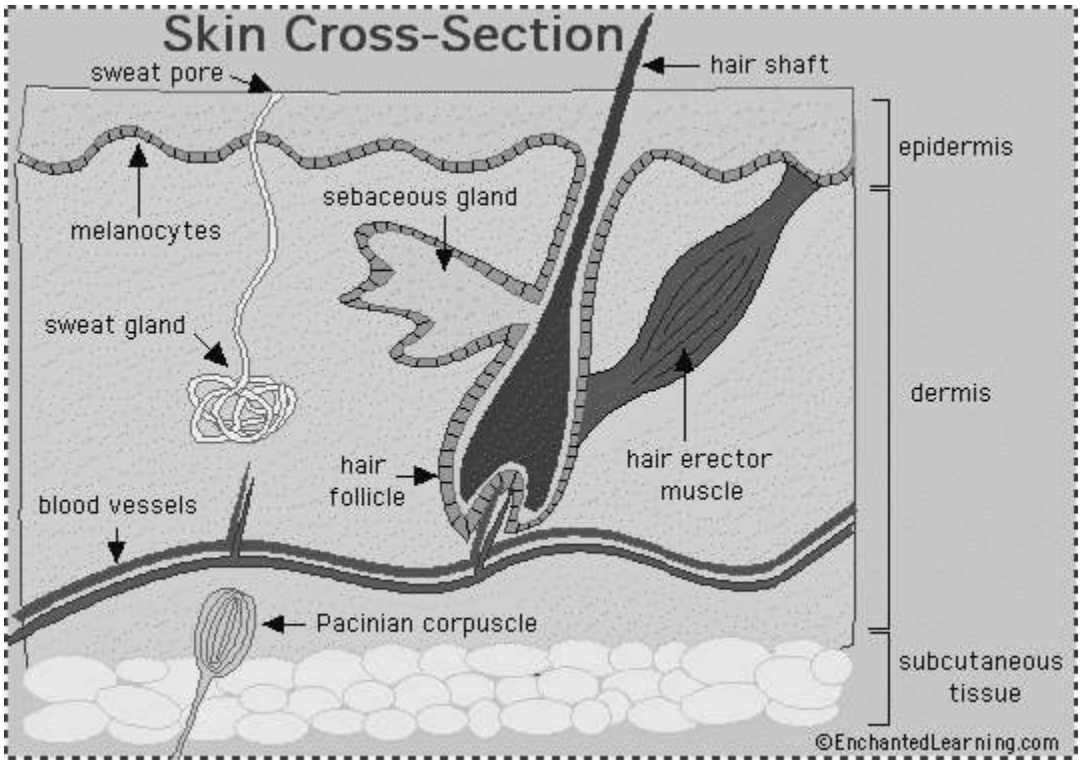

Dermo-epidermal junction is irregular. The epidermis has epidermal ridges which interdigitate with projection of dermis called dermal papillae

Epidemal derivatives include:Hairs, nails, sebaceous and sweat glands

Functions of Skin

1. **Protection against injury, bacteria ,dehydration (water proof layer of keratin), ultraviolet rays of sun (due to presence of melanin pigment).**
2. **Thermoregulation.**
3. **Reception of sensation (touch, temperature and pain).**
4. **Excretion of sweat.**
5. **Absorption of ultraviolet radiation from the sun for synthesis of vitamin D.**
6. **Diagnosis:Medical (appearance & color of skin);medico-legal (Finger prints).**

Thin and Thick skin:

Thin skin present in hairy skin in general; thick skin present in nonhairy skin (palm and sole).

Epidermis:

Consists of stratified squamous keratinized epithelium.

Cells of epidermis:

1. **Keratinocytes: constitute 90% of cell types in epidermis arranged in a form stratified layers**
2. **Non-keratinocytes (10% of cell population in epidermis):**
   Include: Melanocytes,Langerhans cells,Merckel's cells and inflammatory cells like lymphocytes.

Layers of epidermis:

1- Stratum basale : This layer is responsible, by repeated mitotic division, for the constant regeneration of the other layers of the epidermis. Epidermis renew every 15-30 days

2- Stratum spinosum

3- Stratum granulosum

4- Stratum lucidum

5- Stratum corneum. It is normally composed of flat sheets of keratin. The cytoplasm of the cells is filled with keratin with no other cytoplasmic organelles. These cells of this layer are continuously shed.

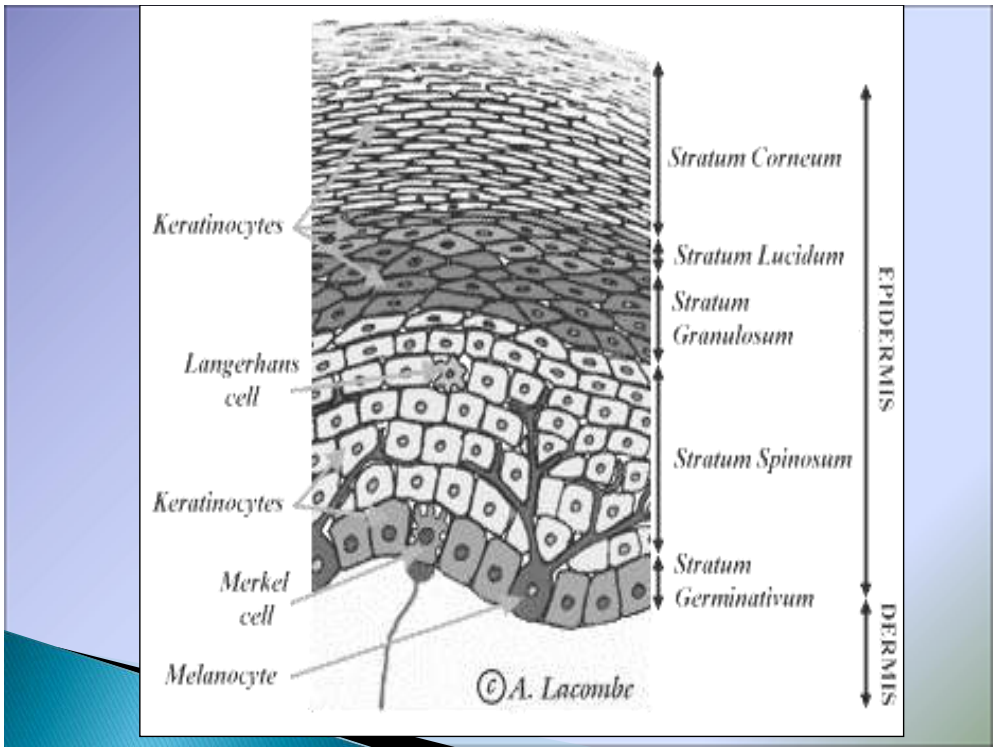

MEDICAL APPLICATION

In **psoriasis,** a common skin disease, there is an increase in the number of proliferating cells in the stratum basale and the stratum spinosum as well as a decrease in the cycle time of these cells, which shortened to about 7 days. This results in greater epidermal thickness and more rapid renewal of epidermis.

Non-keratinocytes:

1. **Melanocytes:** Melanocytes are the cells responsible for producing the pigment ***melanin from blood amino acid tyrosine.***

Melanin is responsible for skin coloration and the colour of the hair. Melanocytes are found beneath or between the cells of stratum basale and in the hair follicles.
Once inside the keratinocytes , melanin granules accumulate in the supranuclear region of the cytoplasm, thus protecting the nuclei from the deleterious effects of solar radiation.

Darkening of the skin (tanning) after exposure to solar UV radiation is the result of a two-step process. First, a physicochemical reaction darkens the preexisting melanin and releases it rapidly

into the keratinocytes. Next, the rate of melanin synthesis in the melanocytes accelerates, increasing the amount of this pigment.

Medical application:

Albinism: a hereditary inability of the melanocytes to synthesize melanin. As a result, the skin is not protected from solar radiation by melanin, and there is a greater incidence of skin cancers.

The degeneration and disappearance of entire melanocytes result in a depigmentation disorder called **vitiligo.**

'*Moles*' or *naevi* are benign accumulations of melanocytes in the dermis .

Color of skin:

The color of the skin is the result of several factors, the most important of which are

A. Its content of **melanin** and **carotene.**

B. The number of blood vessels in the dermis.

C. And the color of the blood flowing in them.

2. Langerhans Cells

Langerhans cells, star-shaped cells found mainly in the stratum spinosum of the epidermis. They are bone marrow derived. They have a significant role in immunological skin reactions.

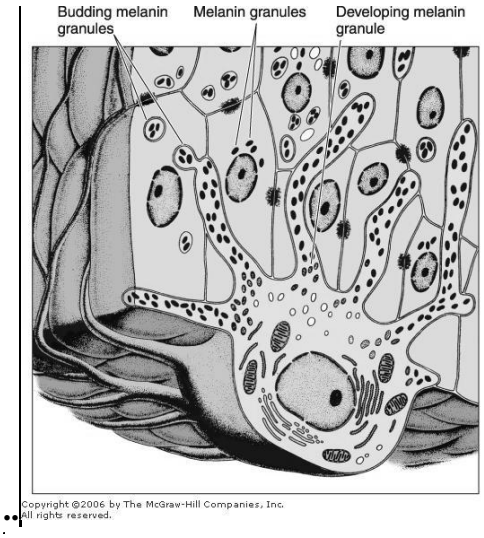

Copyright ©2006 by The McGraw-Hill Companies, Inc.
All rights reserved.

3. Merkel's Cells

Merkel's cells, generally present in the thick skin of palms and soles. These cells may serve as sensory mechanoreceptors.

Dermis

The dermis is the irregular dense connective tissue that supports the epidermis and binds it to the subcutaneous tissue (hypodermis). The dermis is composed of collagen and elastic fibers, and is responsible for the tone and texture of the skin. The dermis also contains the skin appendages, most of the vascular supply to the skin, and nerves and sensory nerve endings.

Skin appendages

Hair ,sweat glands ,sebaceous glands ,and nails

Hair

Hairs are elongated keratinized structures derived from invaginations of epidermal epithelium. Hairs grow discontinuously and have periods of growth followed by periods of rest.

- **Color of the hair**: **Black brown** due to **melanin** pigment produced by melanocytes & transported to cells of cortex & medulla.
- **Red** due to **pheomelanin.**
- **Grey color** in old people due to **inability of melanocytes to produce tyrosinase enzyme.**

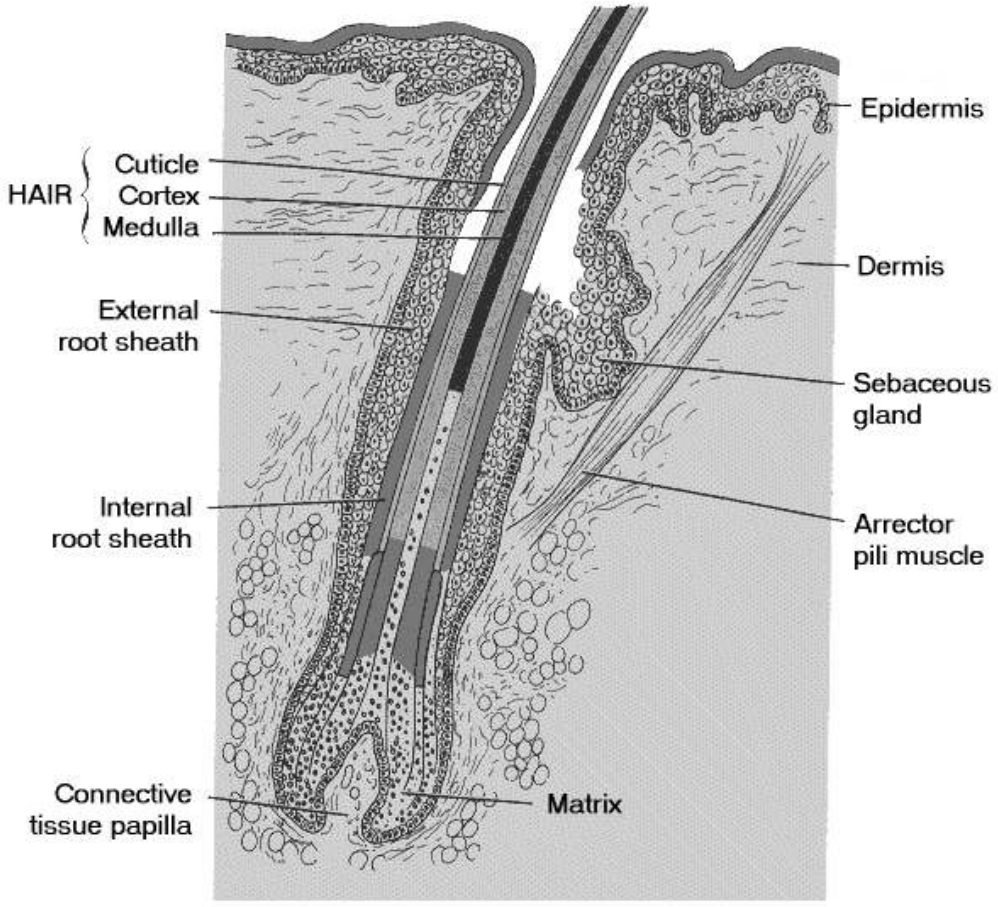

Nails

Nails are plates of keratinized epithelial cells on the dorsal surface of each distal phalanx.

Glands of the skin:

- **Sebaceous glands** are holocrine glands. The majority are associated with hair follicles, They are absent in thick skin.
- **Eccrine sweat glands** are widespread throughout the skin. They are located around the junction between dermis and subcutis and synthesise a thin watery liquid (sweat) which is passed along eccrine ducts and deposited onto the skin surface. Evaporation of this sweat reduces body temperature.
- **Apocrine glands** are confined to a few localised areas, mainly in the axillary and groin regions. Apocrine gland secretions in humans have no definite function, but in animals

they are responsible for scent production, used in territory marking .p

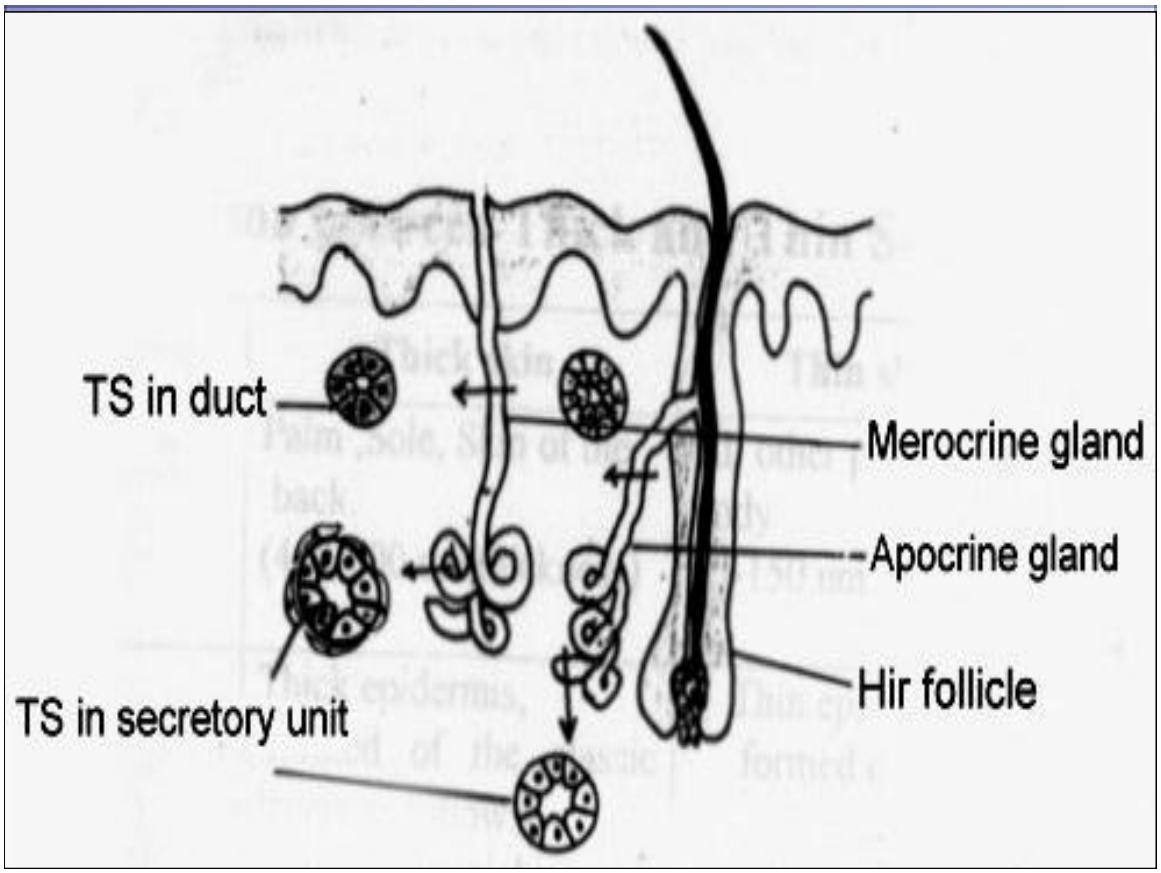

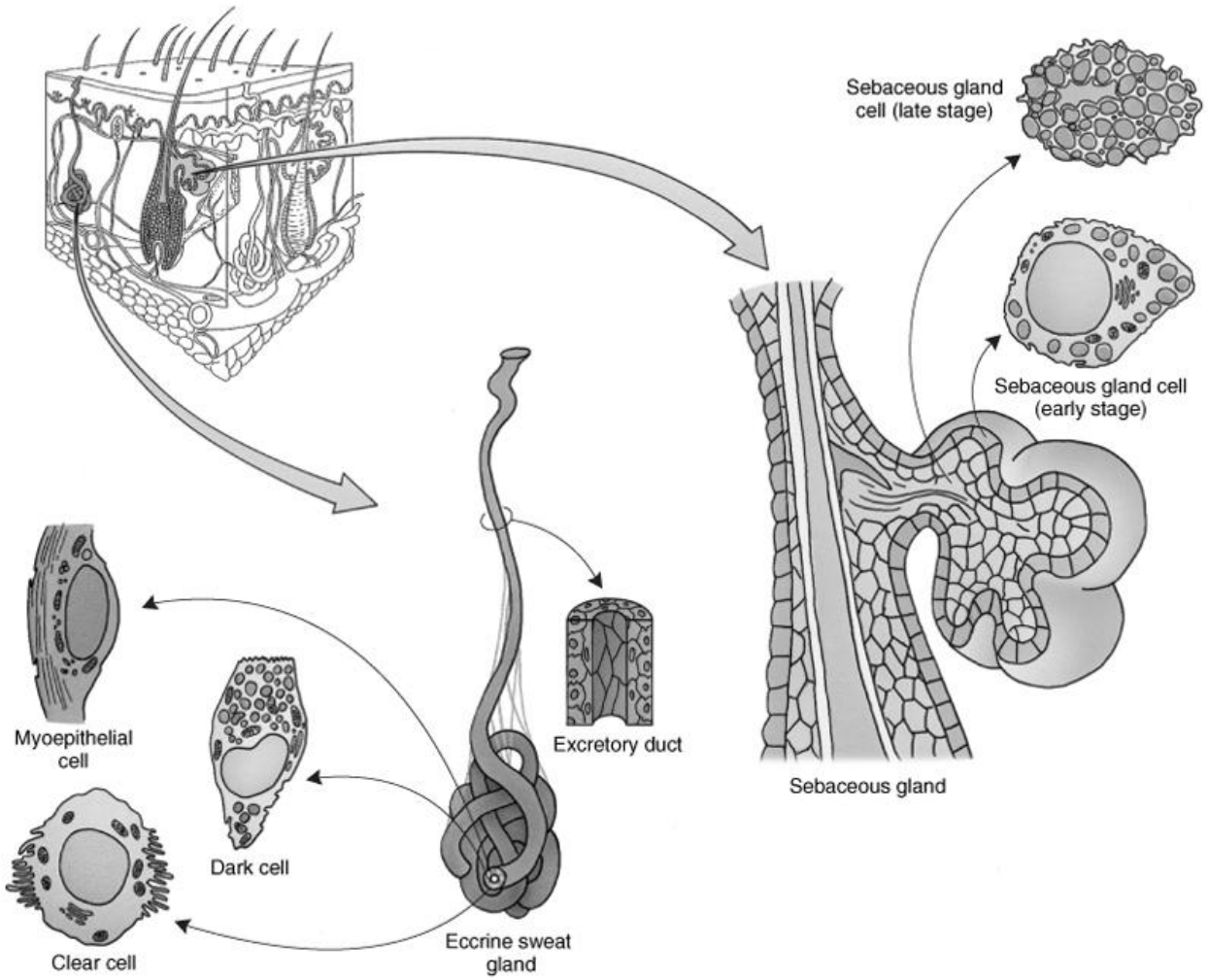

© Elsevier. Gartner & Hiatt: Color Textbook of Histology 3E - www.studentconsult.com