SKULL 2

First stage

Dr. Mustafa Fadhil

❖ Views of skull

Skull is observing by five views :

- Norma frontalis—the anterior view
- Norma lateralis—the lateral view
- Norma occipitalis—the posterior view
- Norma basalis—the inferior view
- Norma verticalis—the superior view

Norma frontalis

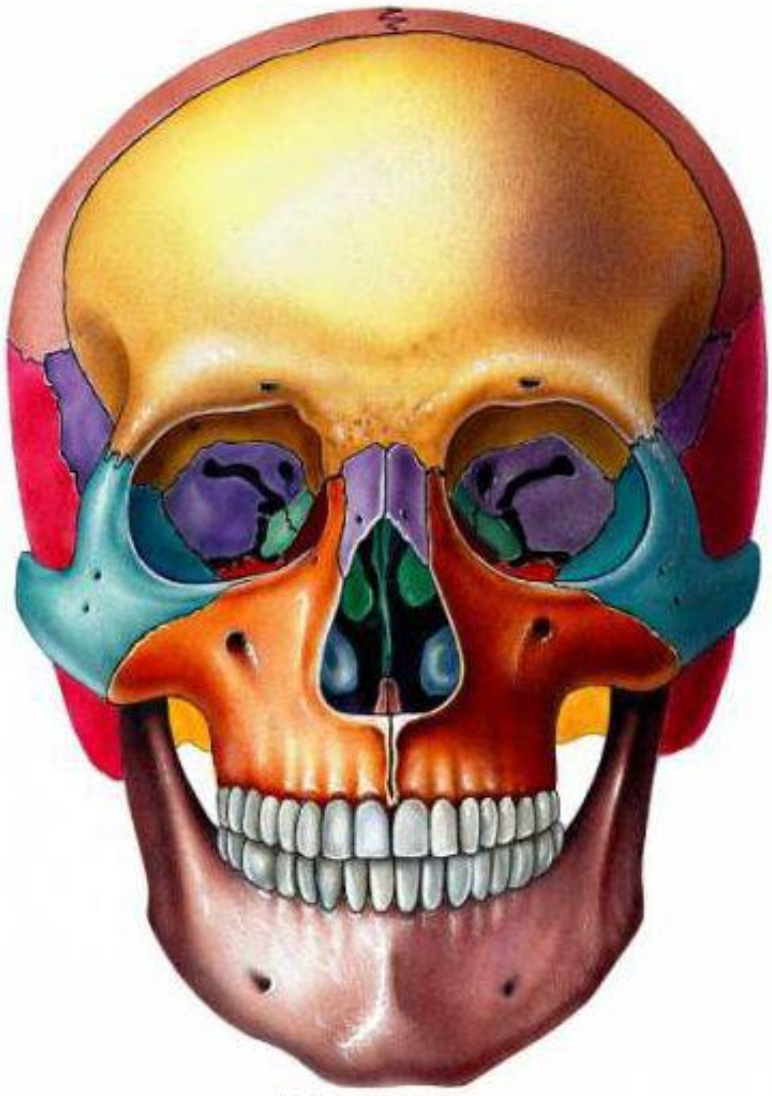

Norma lateralis

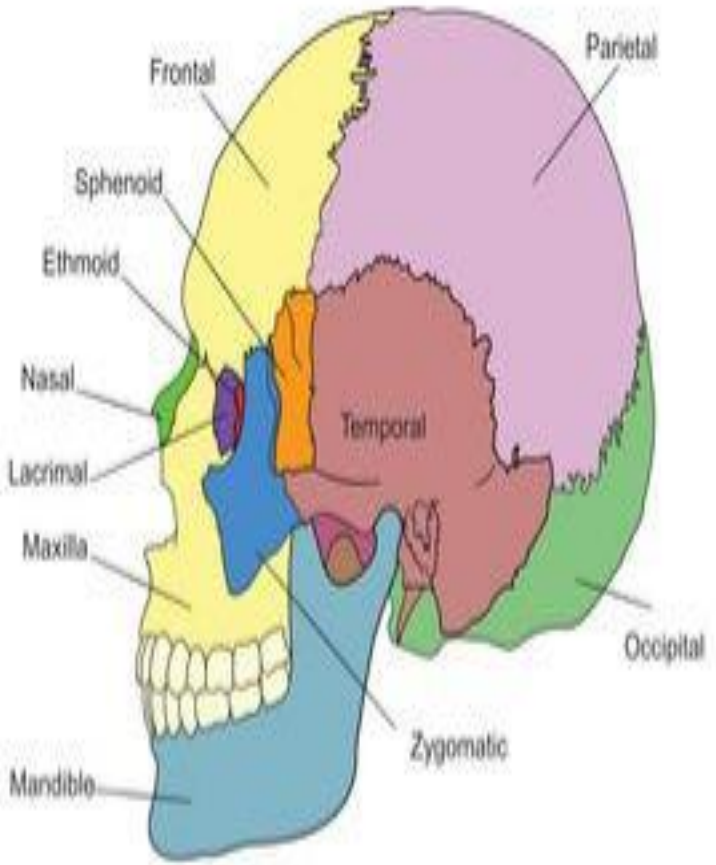

Norma verticales

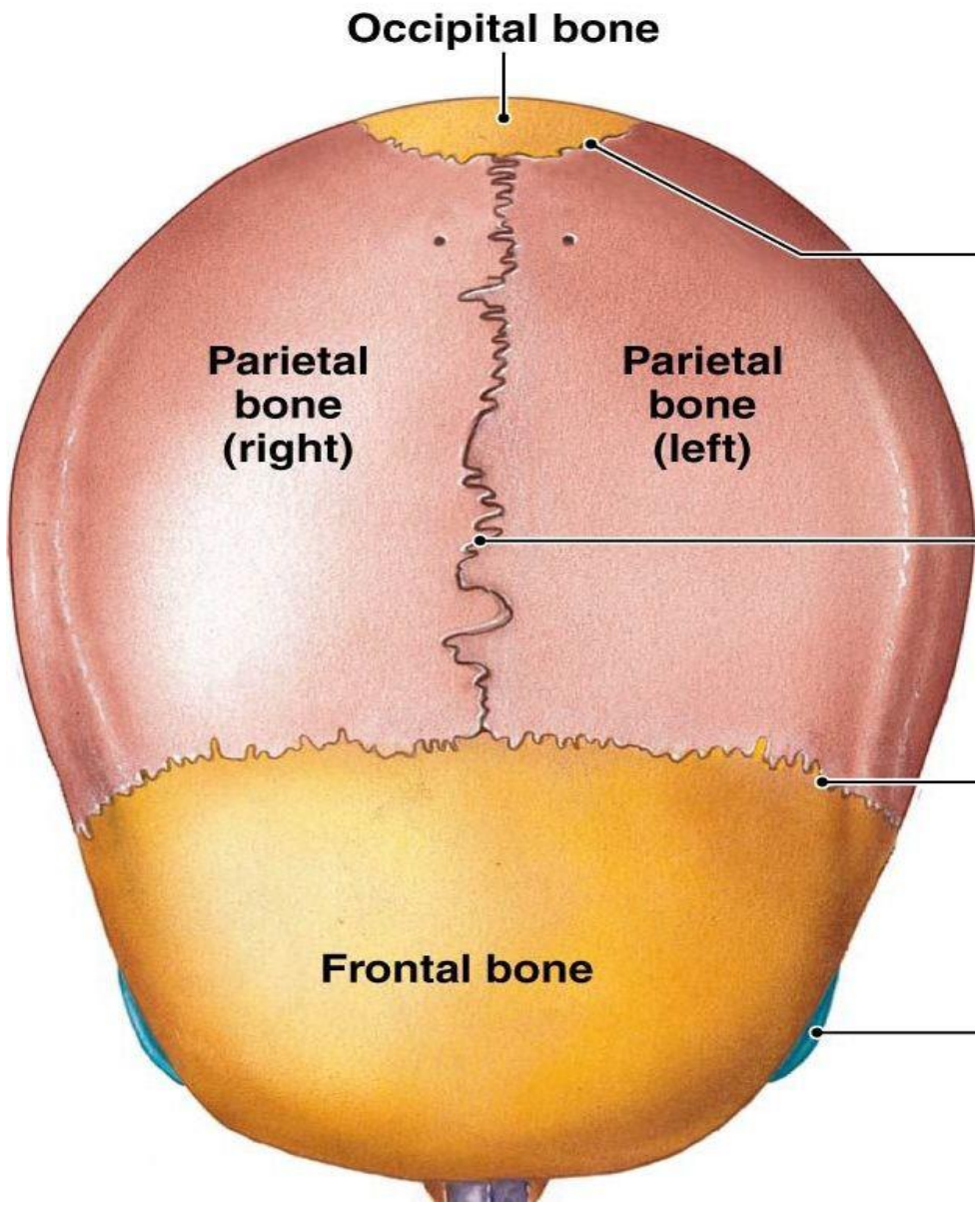

Norma basalis



Norma Occipitalis

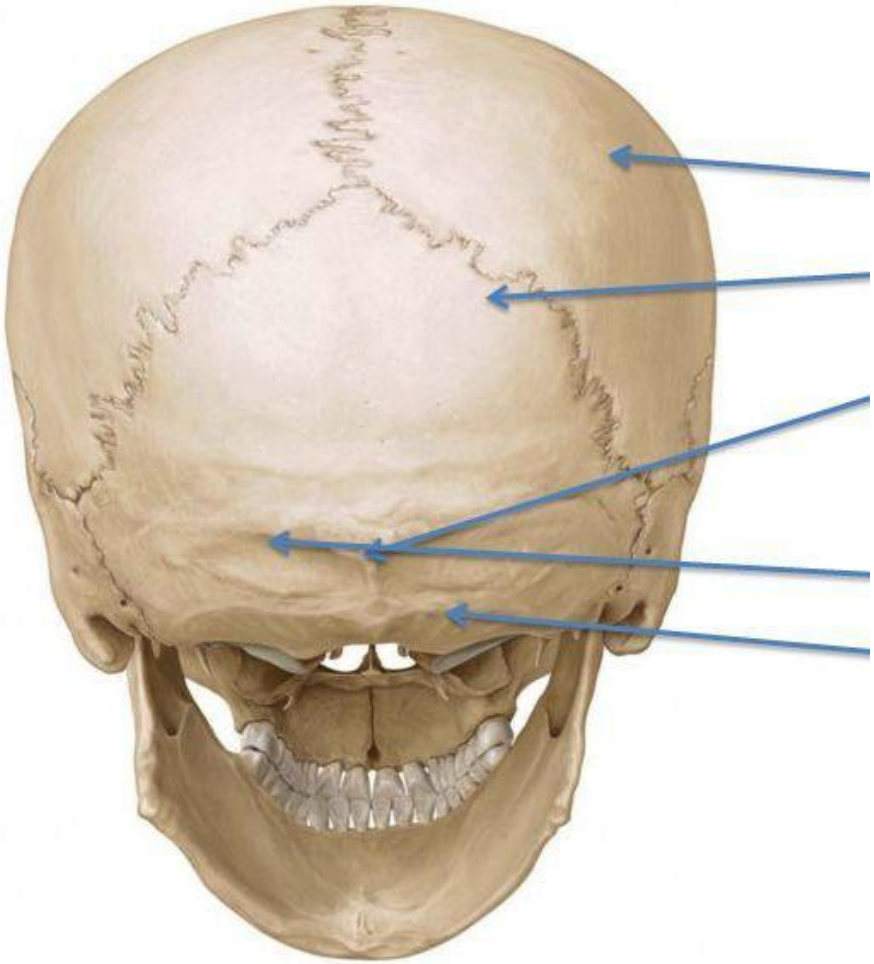

❖Regions of head

1.Frontal region
2. parietal region
3.Occipital region
4.Temporal region
5.Auricular region
6.Mastoid region
7.Orbital region
8. Infraorbital region
9.Buccal region
10.Parotid region
11.Zygomatic region
12. Nasal region
13.Oral region
14.Mantal region

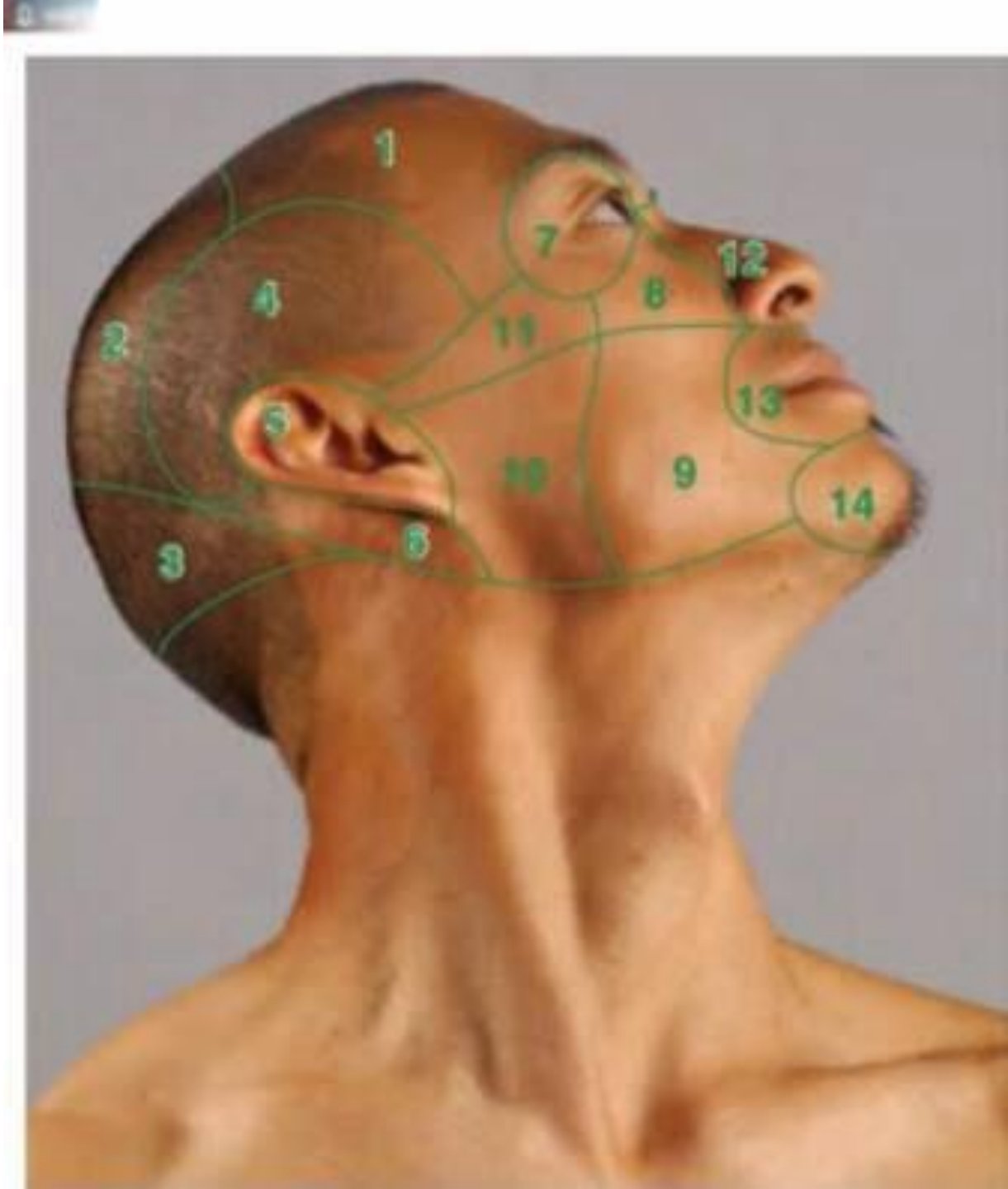

Region of head

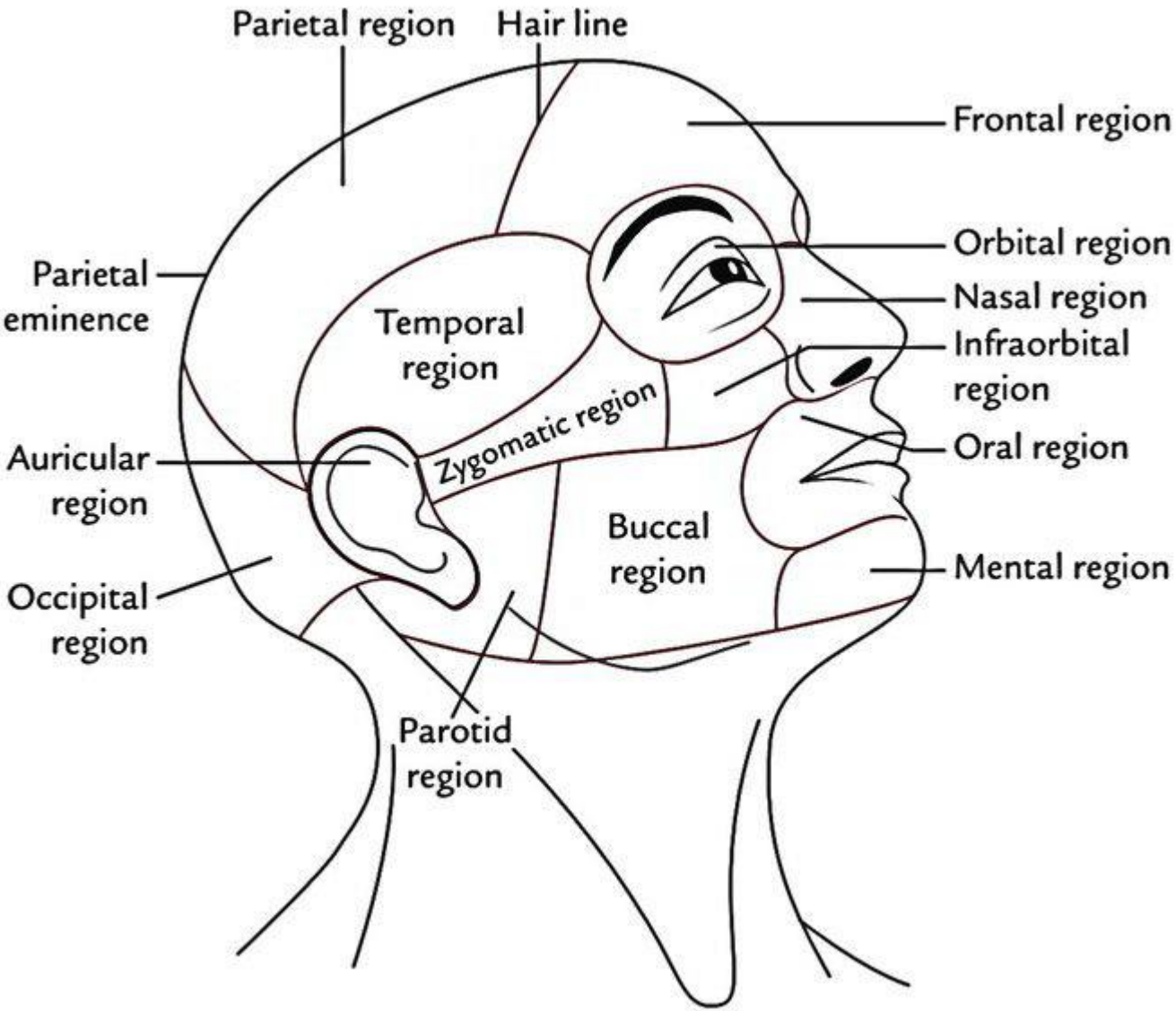

❖Attached of suture :

1.Bregma: attached coronal suture with sagittal suture (closed in 18 months).

2.Lumbda: attached sagittal suture with lumbdoid suture (closed in 6 months)

3.Pterian: H shape suture between 4 bone frontal , parietal, sphenoid and temporal (closed in 3months)

4.Asterian: attached temporal, partial and occipital bone (closed in 1months)

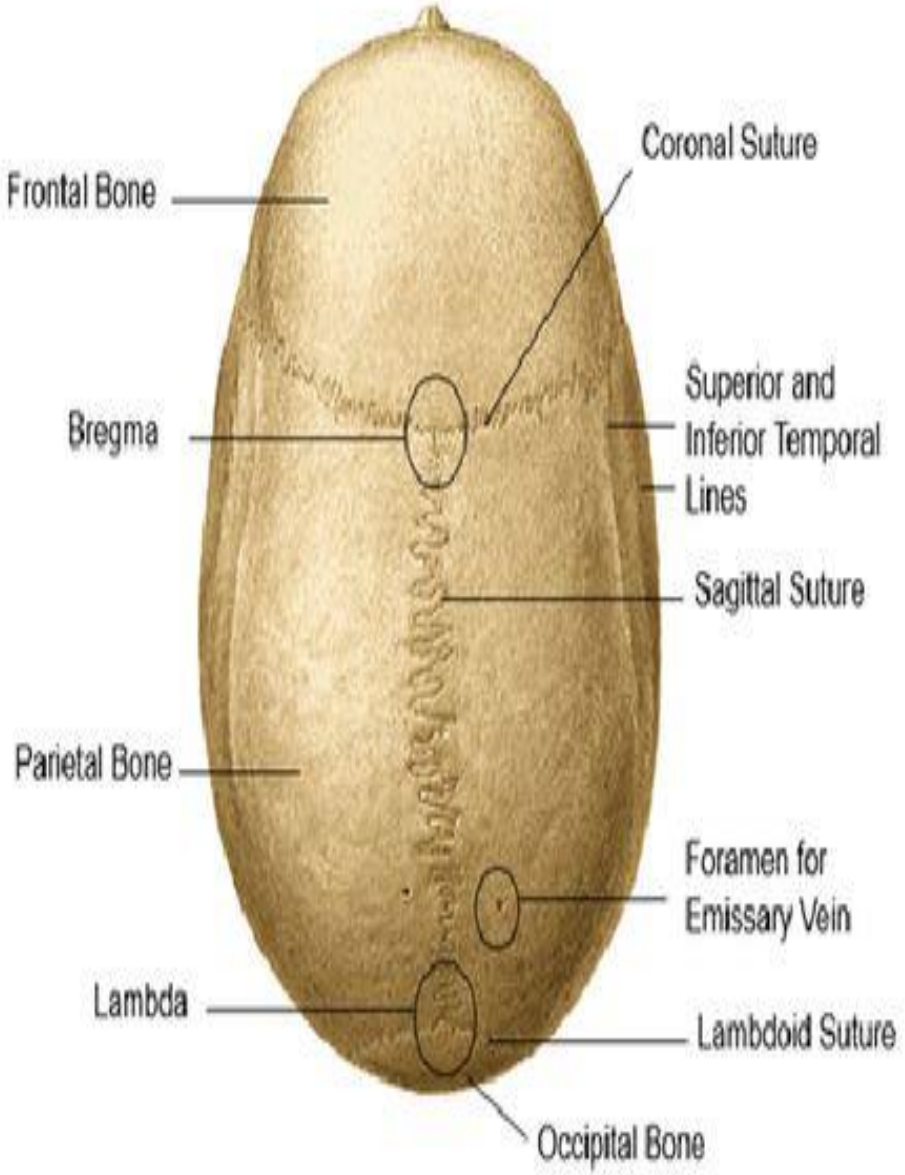
Frontal Bone
Coronal Suture
Bregma
Superior and
Inferior Temporal
Lines
Sagittal Suture
Parietal Bone
Foramen for
Emissary Vein
Lambda
Lambdoid Suture
Occipital Bone

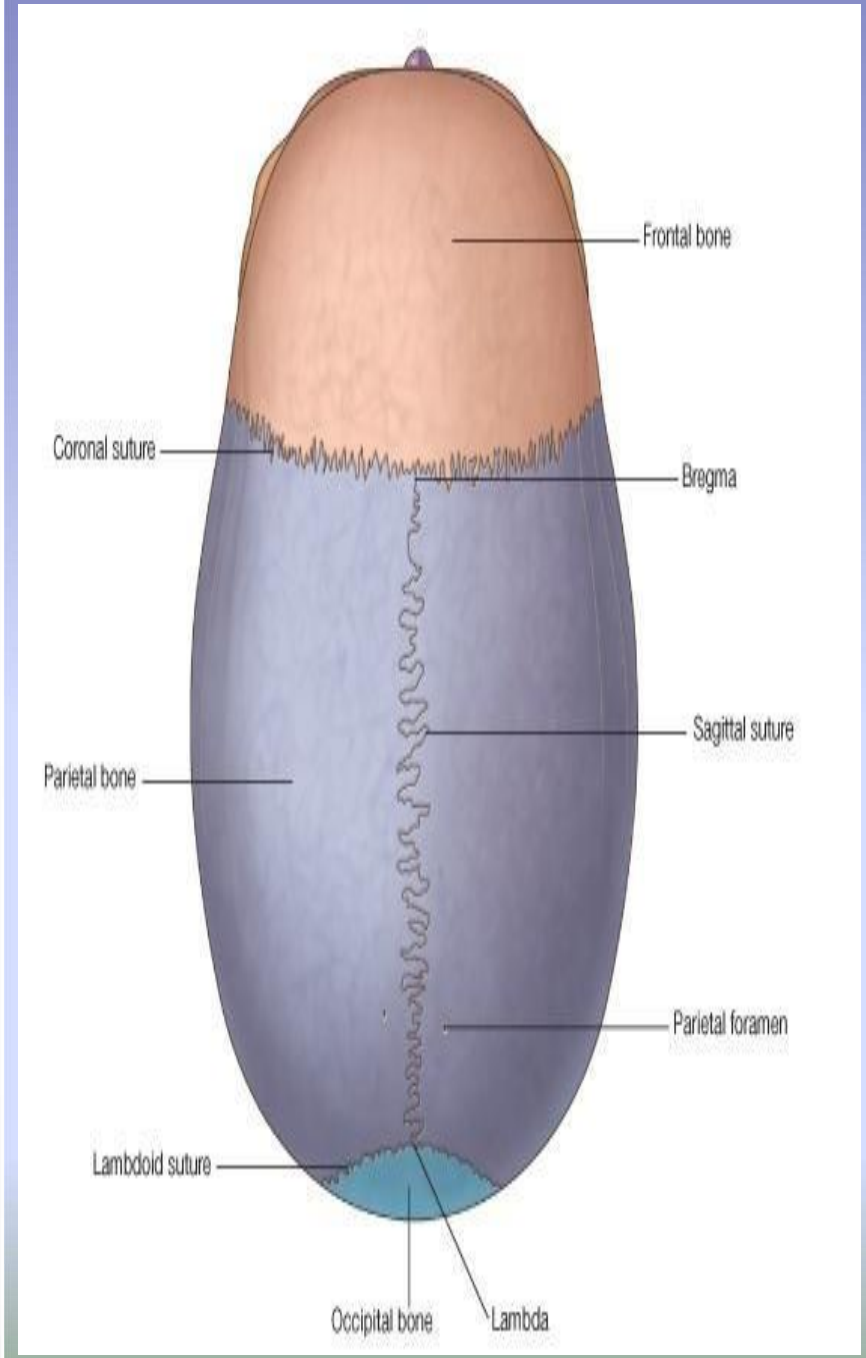
Frontal bone
Coronal suture
Bregma
Sagittal suture
Parietal bone
Parietal foramen
Lambdoid suture
Occipital bone
Lambda

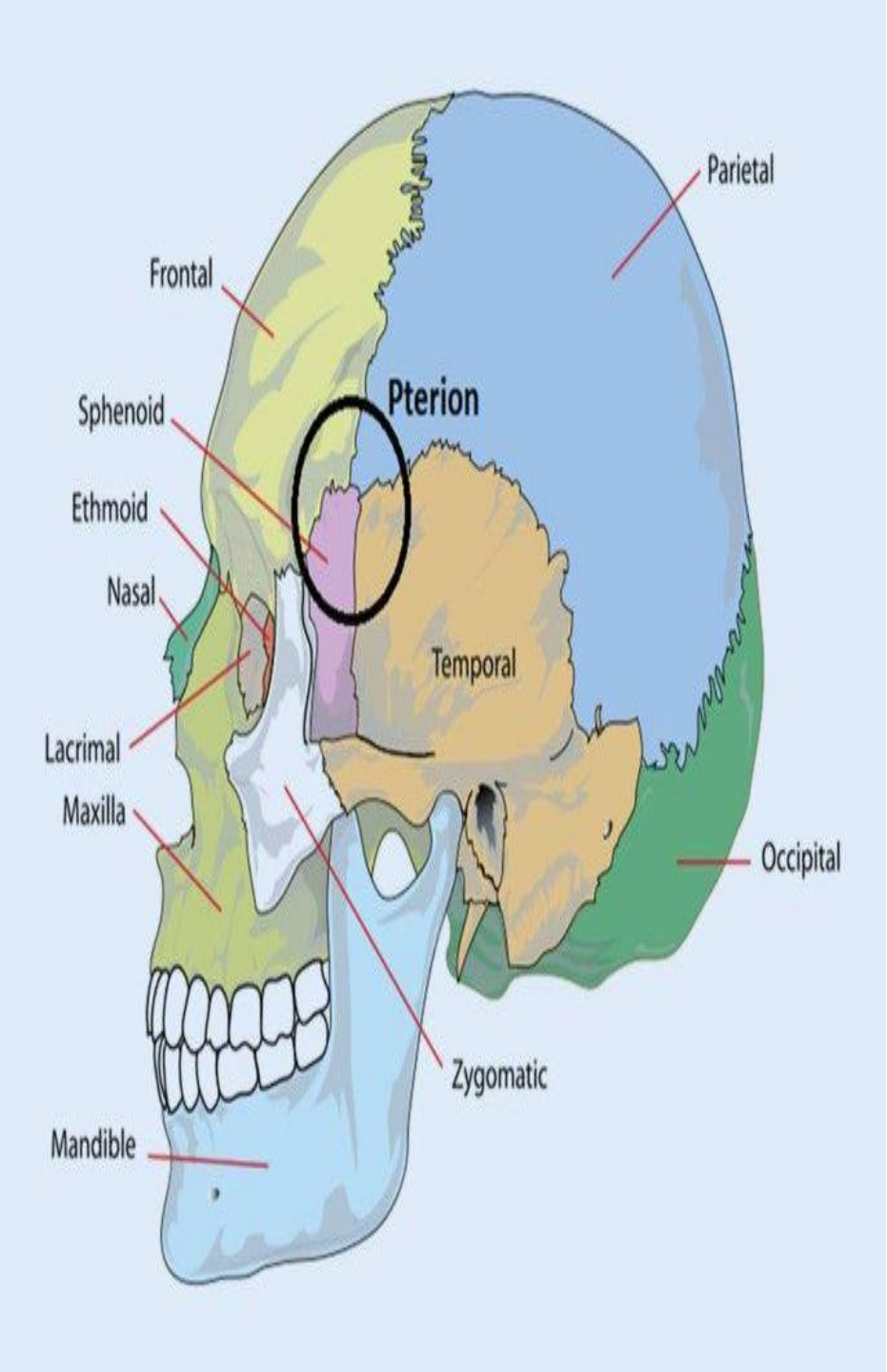
Parietal
Frontal
Pterion
Sphenoid
Ethmoid
Nasal
Temporal
Lacrimal
Maxilla
Occipital
Zygomatic
Mandible

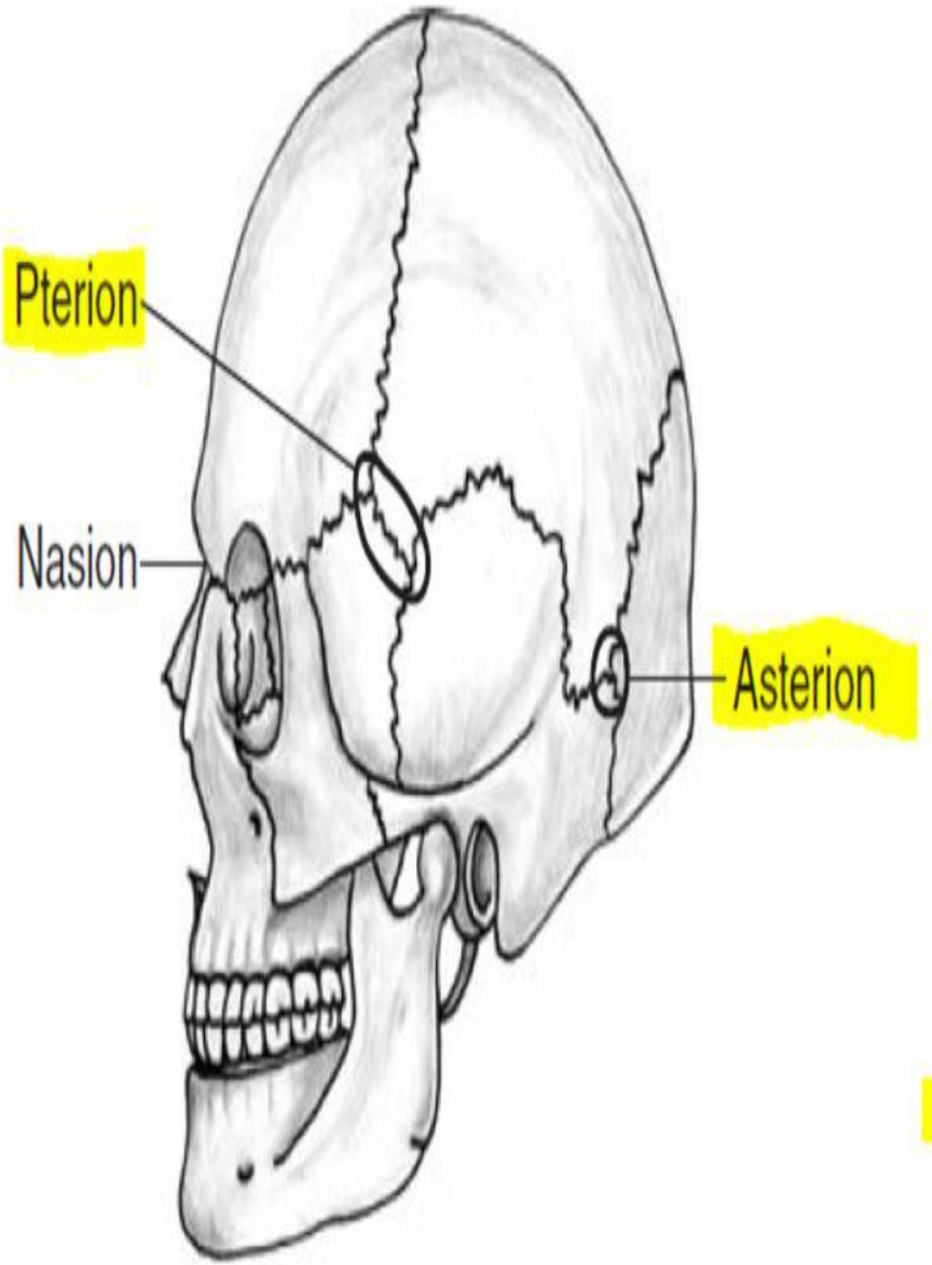
Pterion
Nasion
Asterion

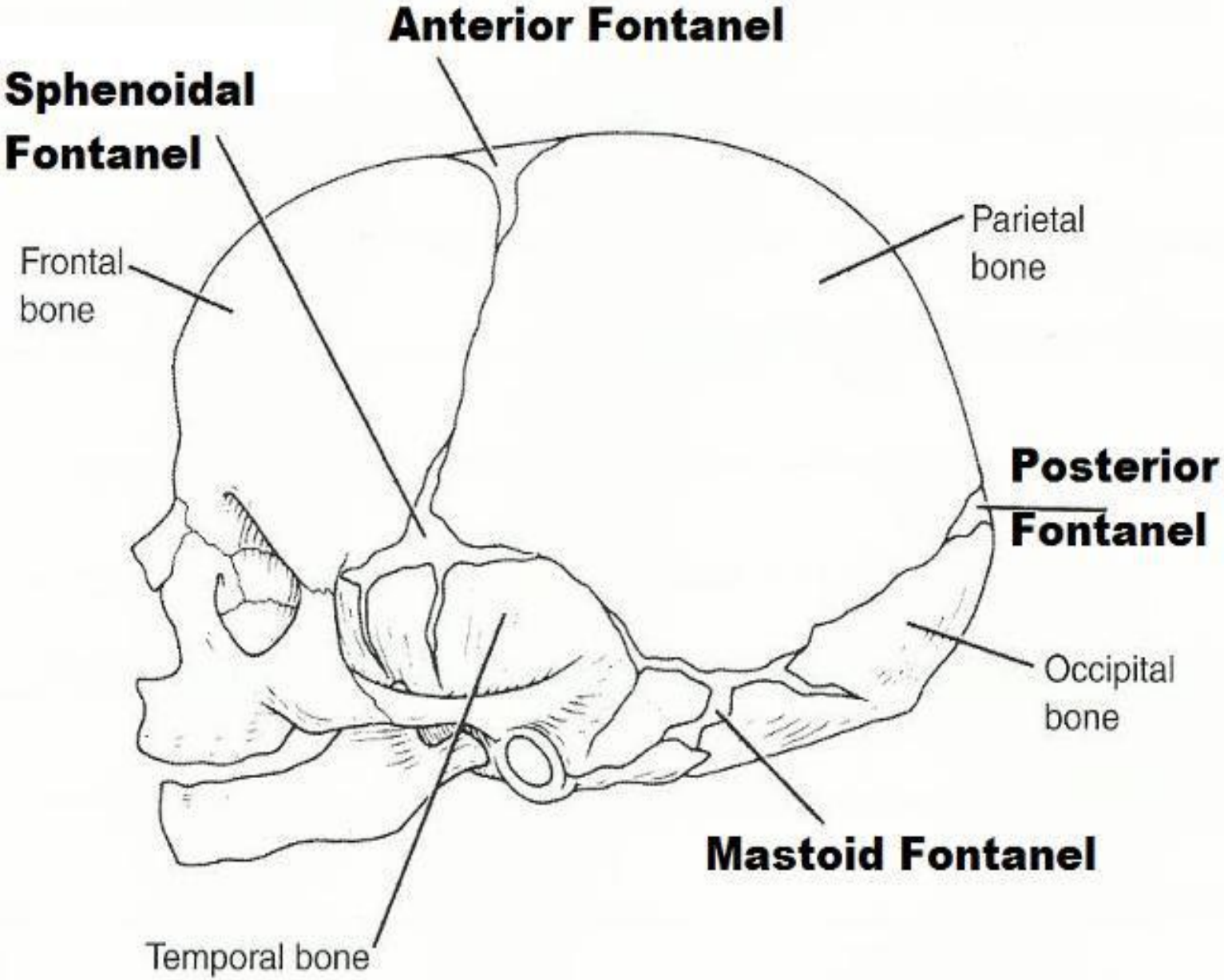
Anterior Fontanel
Sphenoidal Fontanel
Frontal bone
Parietal bone
Posterior Fontanel
Occipital bone
Mastoid Fontanel
Temporal bone

❖ **Foramen of anterior view**

- **Supraorbital foramen** in frontal bone (supraorbital nerve and vessels).
- **Optic canal** in sphenoid bone (optic nerve and ophthalmic artery).
- **Superior orbital fissure** between greater and lesser wing of sphenoid bone (ophthalmic division of trigeminal nave, coulometer n., trochlear n., abducent n., superior and inferior ophthalmic vessels).
- **Inferior orbital fissure** between greater wing of sphenoid bone and maxilla (maxillary division of trigeminal nerve, zygomatic nerve and infraorbital vessels).
- **Nasolacrimal duct** between maxillary and lacrimal bone (connect between orbit and nose).
- **Zygomaticofacial foramen** in zygomatic bone (zygomaticofacial nerve and vessels).
- **Infraorbital foramen** in maxilla bone (infraorbital nerve and vessels).
- **Mental foramen** in mandible bone (mental nerve and vessels).
- **Mandibular foramen** in mandible (inferior alveolar nerve and v.).

Anterior View

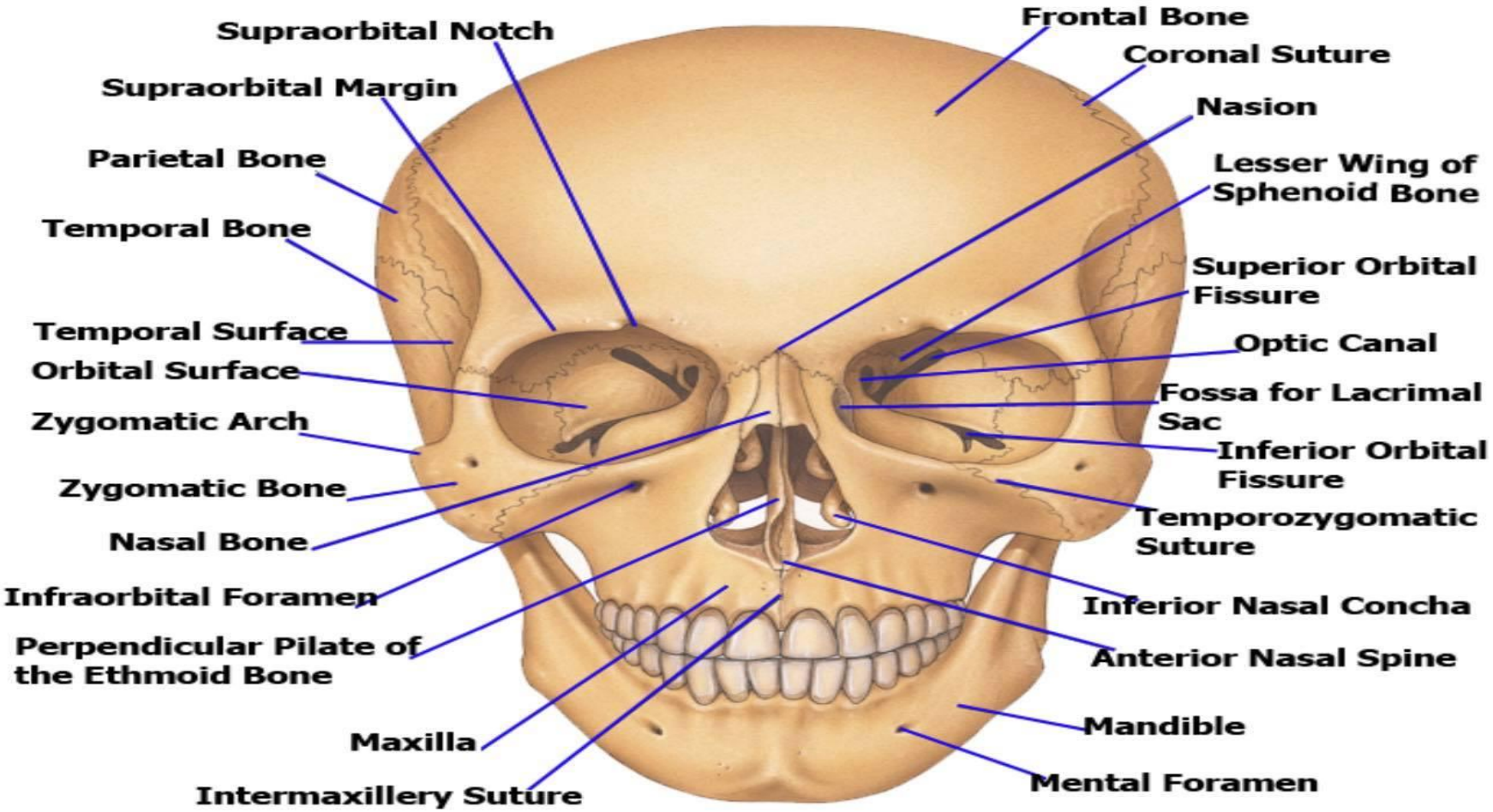

❖Inferior surface of skull (Skull base)or Norma basalis

Divided into two part :

1. Norma basalis extrna (external surface)
2. Norma basalis interna (internal surface)

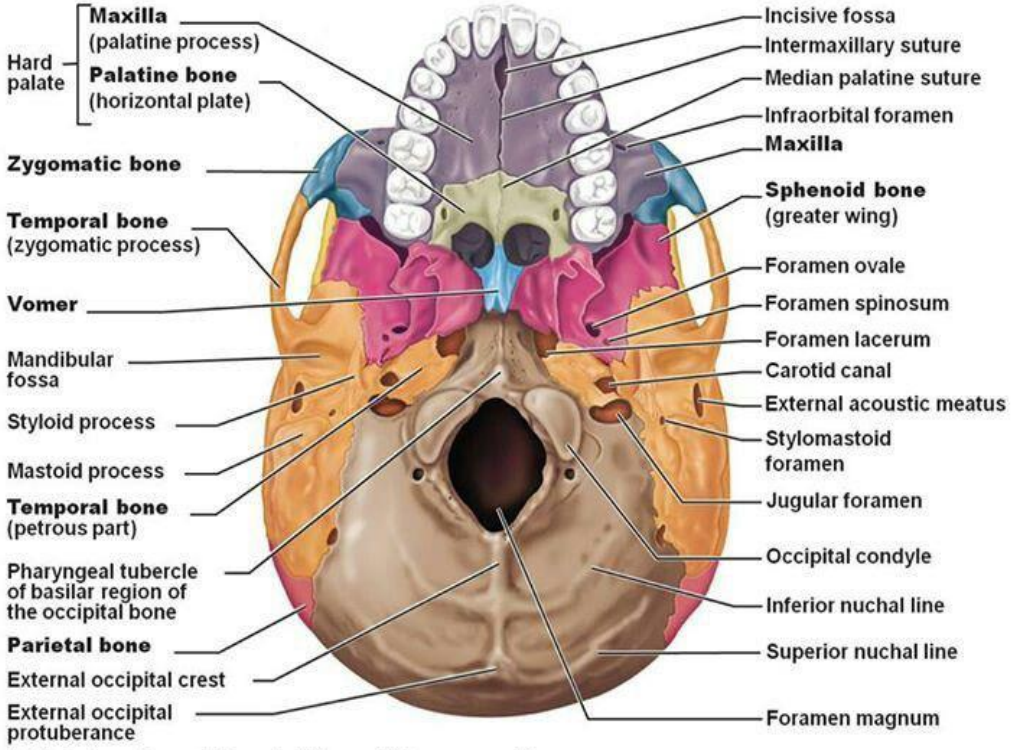

(a) Inferior view of the skull (mandible removed)

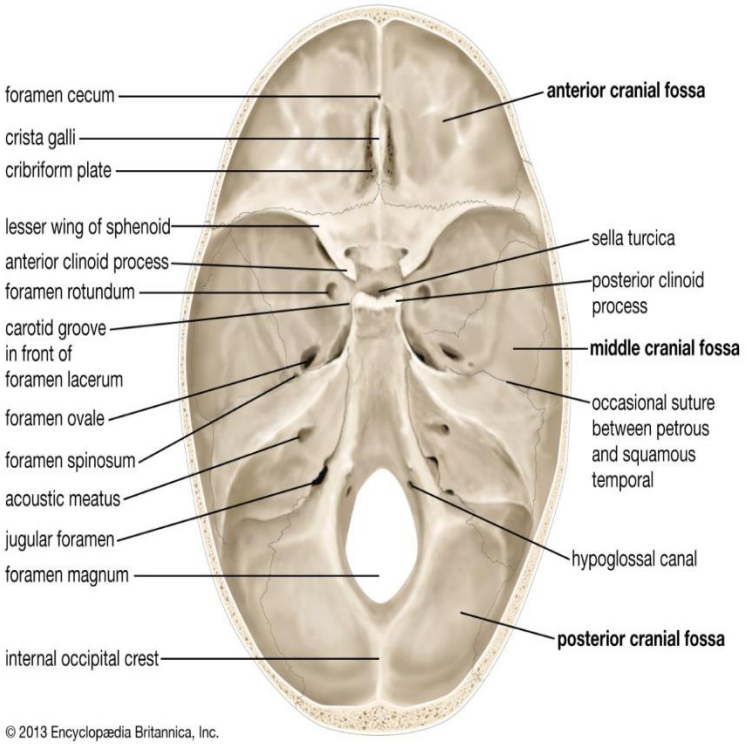

© 2013 Encyclopædia Britannica, Inc.

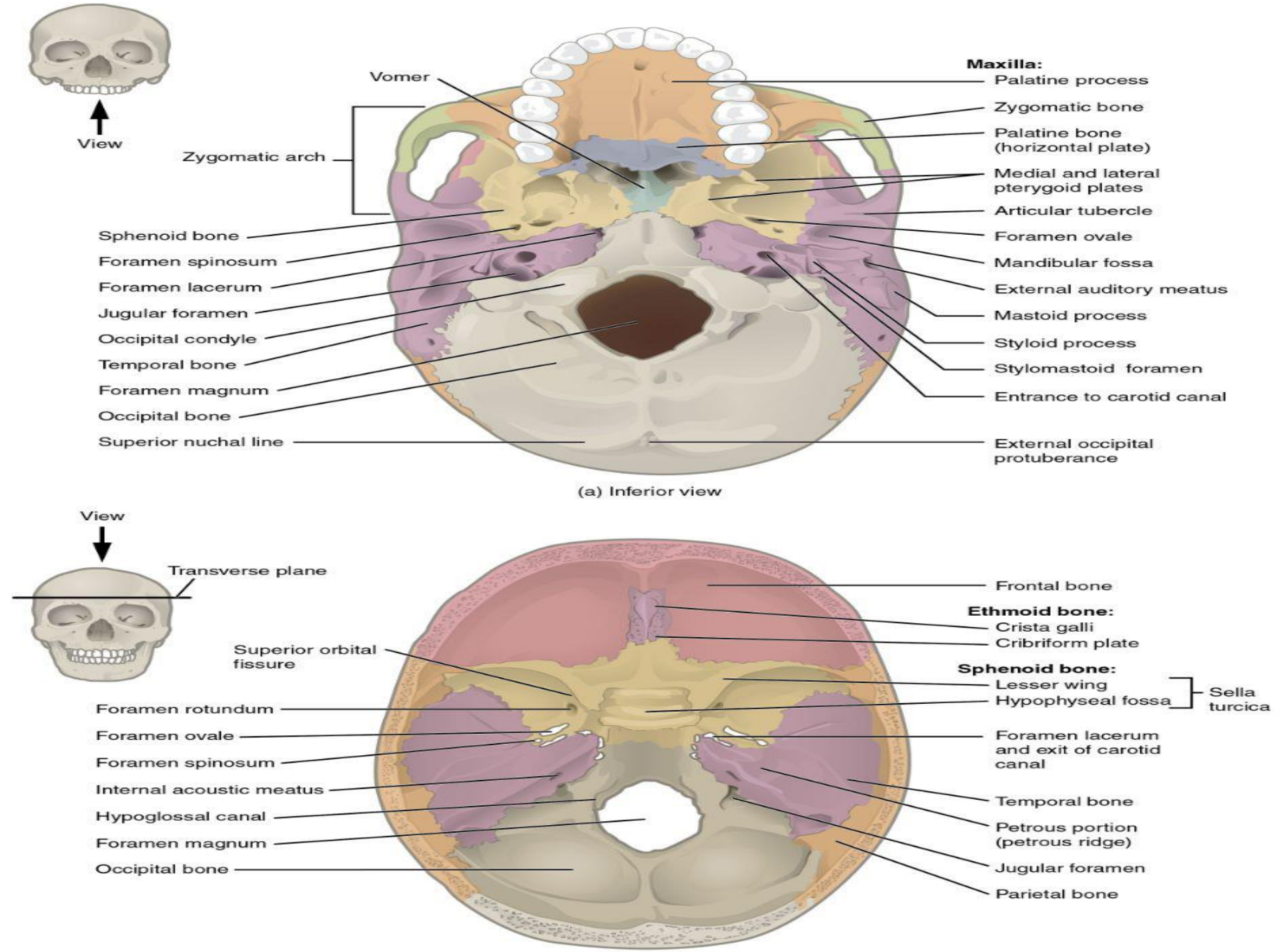
View
Vomer
Zygomatic arch
Sphenoid bone
Foramen spinosum
Foramen lacerum
Jugular foramen
Occipital condyle
Temporal bone
Foramen magnum
Occipital bone
Superior nuchal line
Maxilla:
Palatine process
Zygomatic bone
Palatine bone (horizontal plate)
Medial and lateral pterygoid plates
Articular tubercle
Foramen ovale
Mandibular fossa
External auditory meatus
Mastoid process
Styloid process
Stylomastoid foramen
Entrance to carotid canal
External occipital protuberance
(a) Inferior view
View
Transverse plane
Superior orbital fissure
Foramen rotundum
Foramen ovale
Foramen spinosum
Internal acoustic meatus
Hypoglossal canal
Foramen magnum
Occipital bone
Frontal bone
Ethmoid bone:
Crista galli
Cribriform plate
Sphenoid bone:
Lesser wing
Hypophyseal fossa
Sella turcica
Foramen lacerum and exit of carotid canal
Temporal bone
Petrous portion (petrous ridge)
Jugular foramen
Parietal bone

1.Norma basalis extrna :

(Extend from incisor teeth to external occipital protuberance), represents a central and complex bone structure of the skull that forms the floor of the cranial cavity on which the brain lies. It separates brain from facial structures and neck.

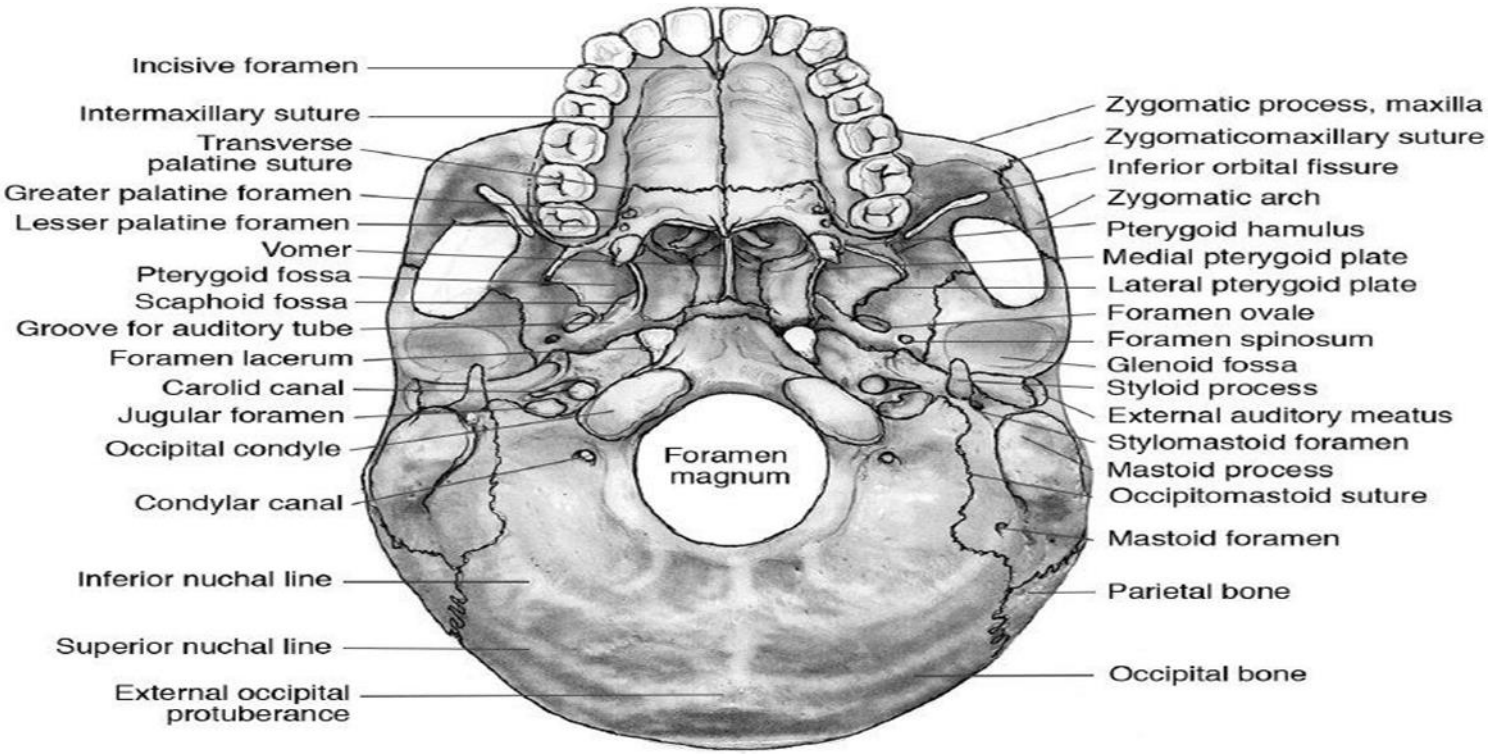

Bones :

1.Maxillary bone

2. Palatine bone

3.Zygomatic bone

4.Vomar bone

5. Sphenoid bone

6.Temporal bone

7.Parietal bone

8.Occipital bone

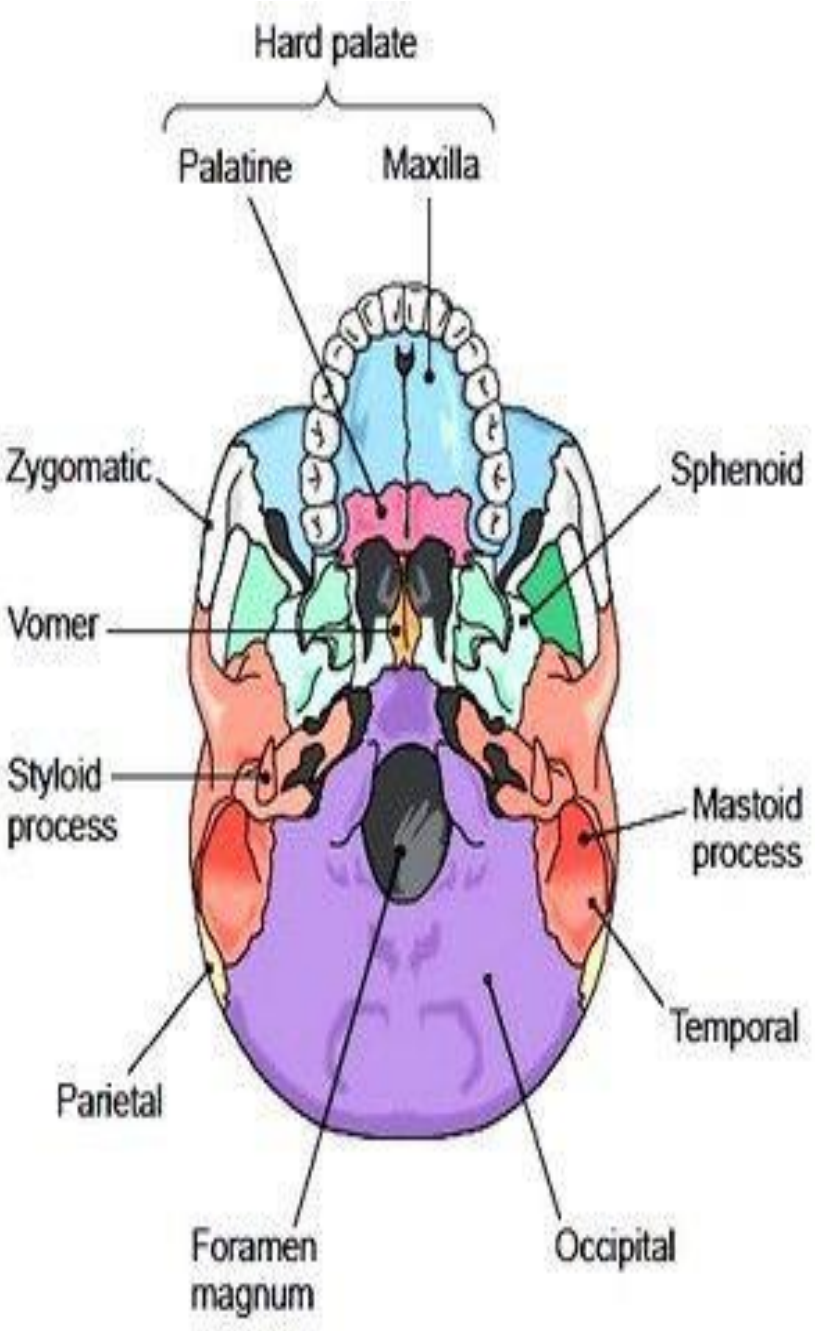

boundaries:-

Anterior ► Upper incisor teeth

Posterior ► occipital bone

Lateral ► Remaining upper teeth and the zygomatic arch



❖**Anterior part** consist from hard palate (palatine process of maxillary bone ¾ and horizontal plate of palatine bone ¼), have two suture (median palatine suture and horizontal palatine suture).

- **Incisive fossa and incisive foramen** in palatine process of maxilla bone (nesopalatine nerve and sphenopalatine artery).
- **Greater palatine foramen** in palatine bone (greater palatine nerve and vessels).
- **Lesser palatine foramen** in palatine bone (lesser palatine nerve and vessels).

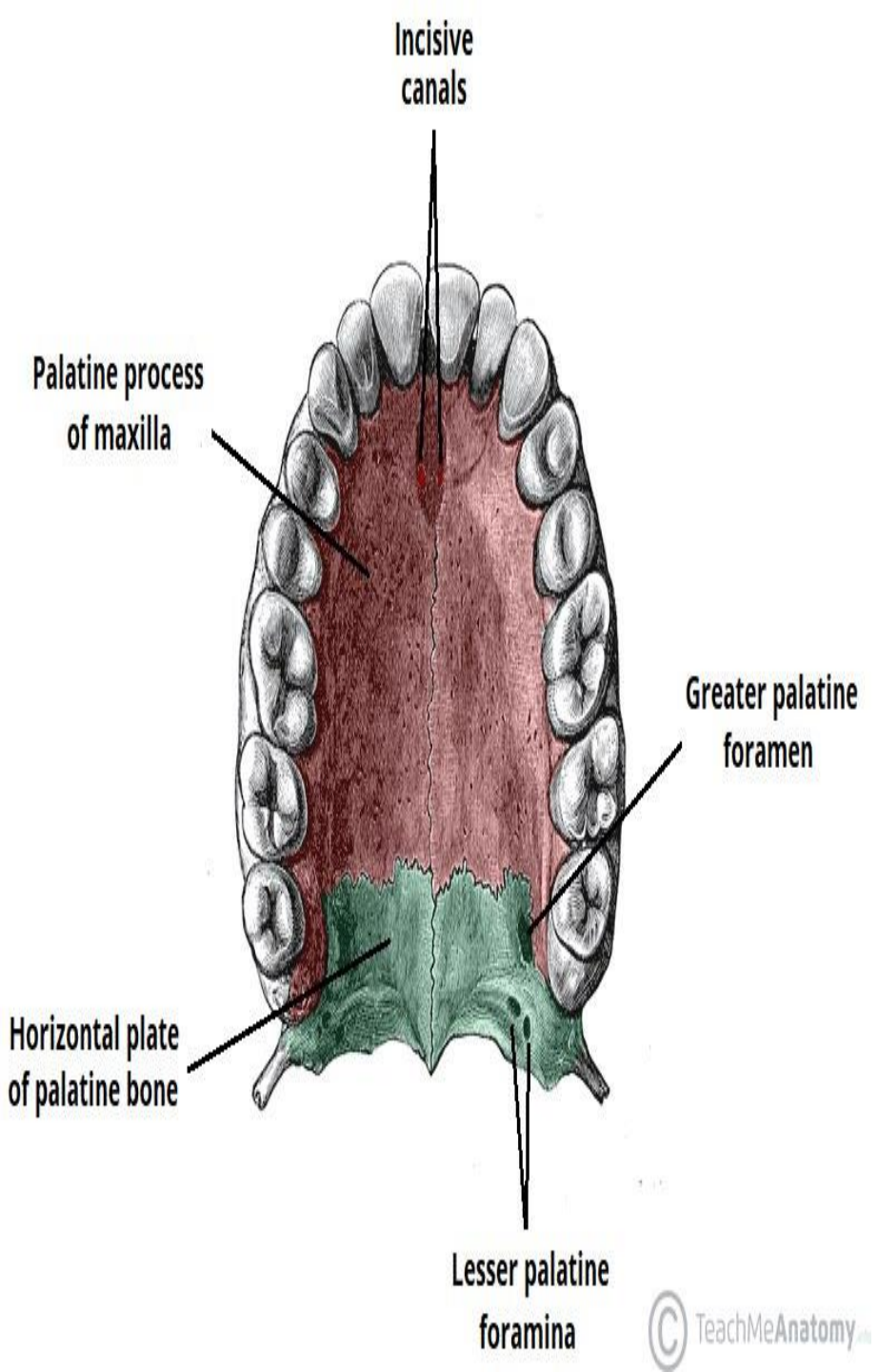
Incisive canals
Palatine process of maxilla
Greater palatine foramen
Horizontal plate of palatine bone
Lesser palatine foramina
TeachMeAnatomy

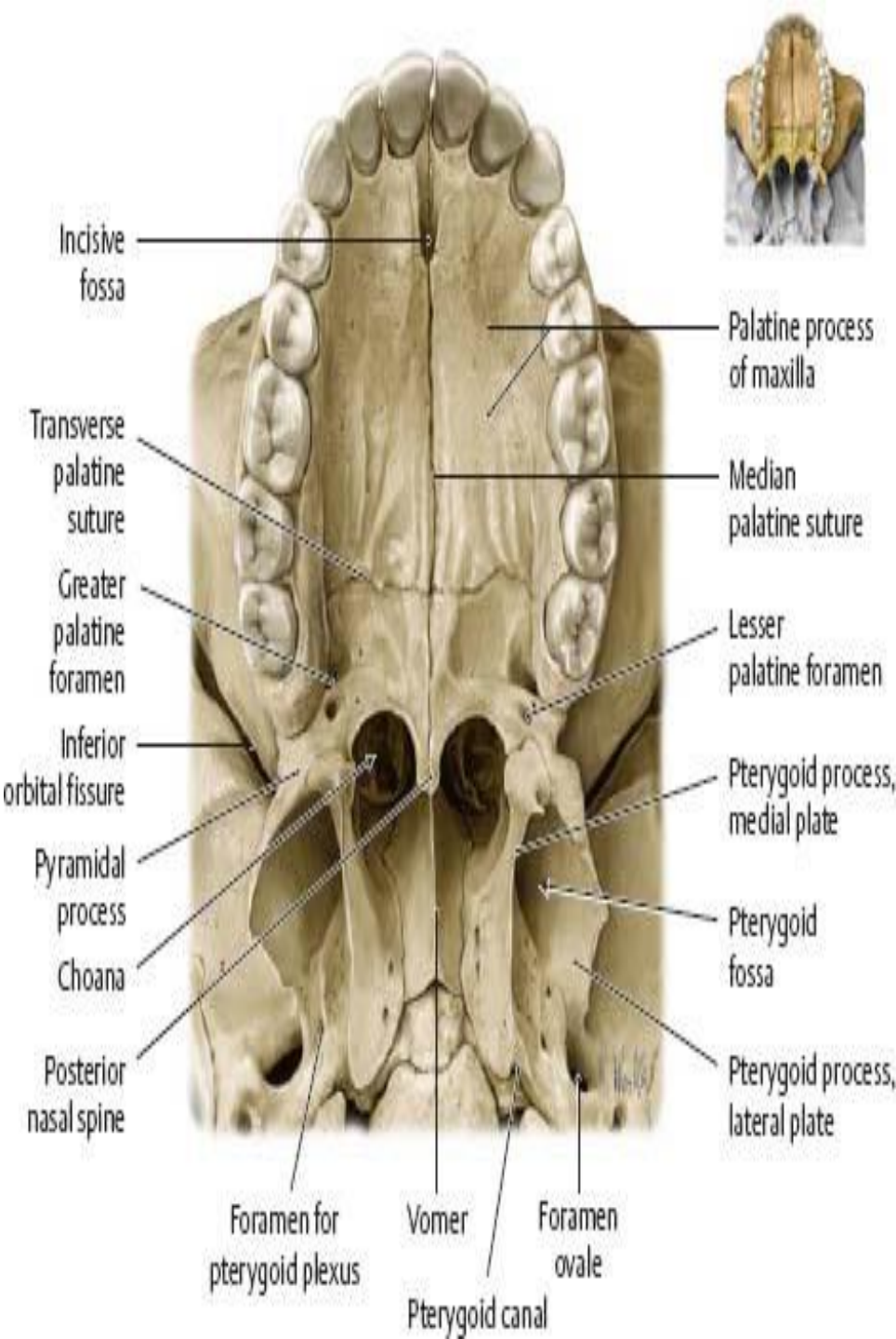
Incisive fossa
Palatine process of maxilla
Transverse palatine suture
Median palatine suture
Greater palatine foramen
Lesser palatine foramen
Inferior orbital fissure
Pterygoid process, medial plate
Pyramidal process
Pterygoid fossa
Choana
Posterior nasal spine
Pterygoid process, lateral plate
Foramen for pterygoid plexus
Vomer
Foramen ovale
Pterygoid canal

❖ **Middle part consist from (sphenoid , temporal and vomer)**

- Posterior nasal aperture or choana (palatine bone, medial pterygoid palate of sphenoid and vomer bone).
- Pterygoid hamulus prolongation of medial pterygoid palate (attached of muscle) .
- Pterygoid fossa between medial and lateral pterygoid palate .
- Infratemporal crest of greater wing of sphenoid bone .
- **Foramen ovale** on greater wing of sphenoid bone (mandibular division of trigeminal nerve, accessory meningeal artery , lesser pettrosal nerve and emissary vein).
- **Foramen spinosum** on greater wing of sphenoid bone (meningeal branch of mandibular division of trigeminal nerve and middle meningeal vessels) .
- Groove for cartilaginous part of auditory tube and canal of bony part of auditory tube .
- **Foramen lacerum** (between greater wing of sphenoid , petrous part of temporal bone and basilar part of occipital bone) (greater petrosal nerve).
- **Carotid canal** on petrous part of temporal bone (internal carotid artery and internal carotid nerve) .
- Mandibular fossa and articular tubercle in temporal bone (TMG).
- External acoustic meatus with tympanic plate .
- Petrotympanic fissure on petrous part of temporal bone contain anterior tympanic artery.
- **Stylomastoid foramen** between mastoid and styloid process (temporal bone) (facial nerve and stylomastoid artery).
- Groove for occipital artery and digastric fossa on mastoid process
- **Mastoid foramen** in mastoid part of temporal bone (emissary vein).

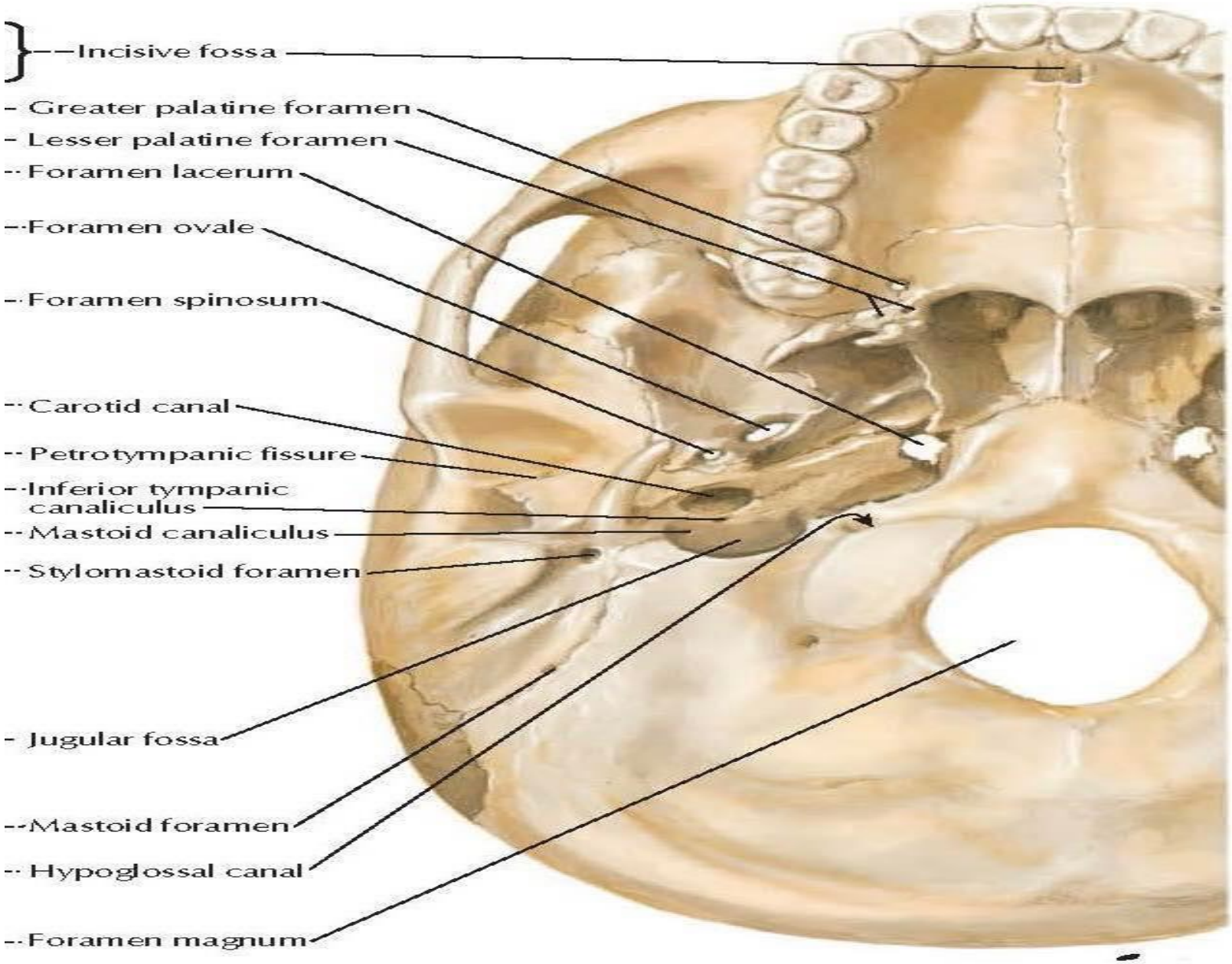
Incisive fossa
Greater palatine foramen
Lesser palatine foramen
Foramen lacerum
Foramen ovale
Foramen spinosum
Carotid canal
Petrotympanic fissure
Inferior tympanic canaliculus
Mastoid canaliculus
Stylomastoid foramen
Jugular fossa
Mastoid foramen
Hypoglossal canal
Foramen magnum

❖ **Posterior consist from (occipital bone with three parts basilar , condylar and squamous part).**

- **Jugular foramen** between temporal and occipital bone (glossopharngeal nerve (9) , vagus nerve (10) , cranial part of accessory nerve (11) and internal jugular vein).
- **Hypoglossal foramen** in occipital bone (hypoglossal(12) nerve).
- **Foramen magnum** in occipital bone (spinal cord and its meninges, vertebral artery, spinal part of accessory nerve and medulla oblongata).
- **Condylar fossa and foramen** in occipital bone (emissary vein and meningeal branches of ascending pharyngeal artery) .
- Pharyngeal tubercle , occipital condyle

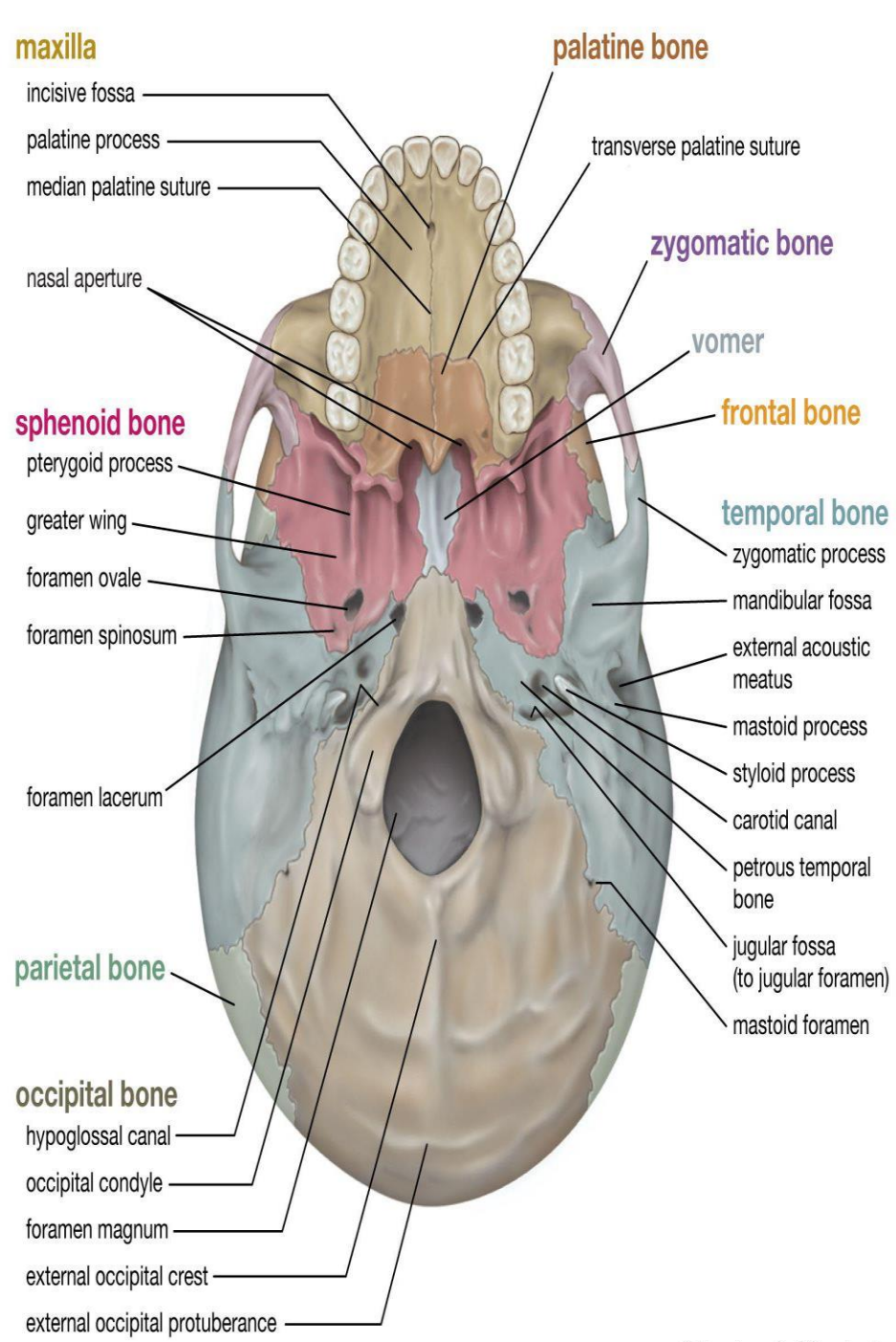

© Encyclopædia Britannica, Inc.

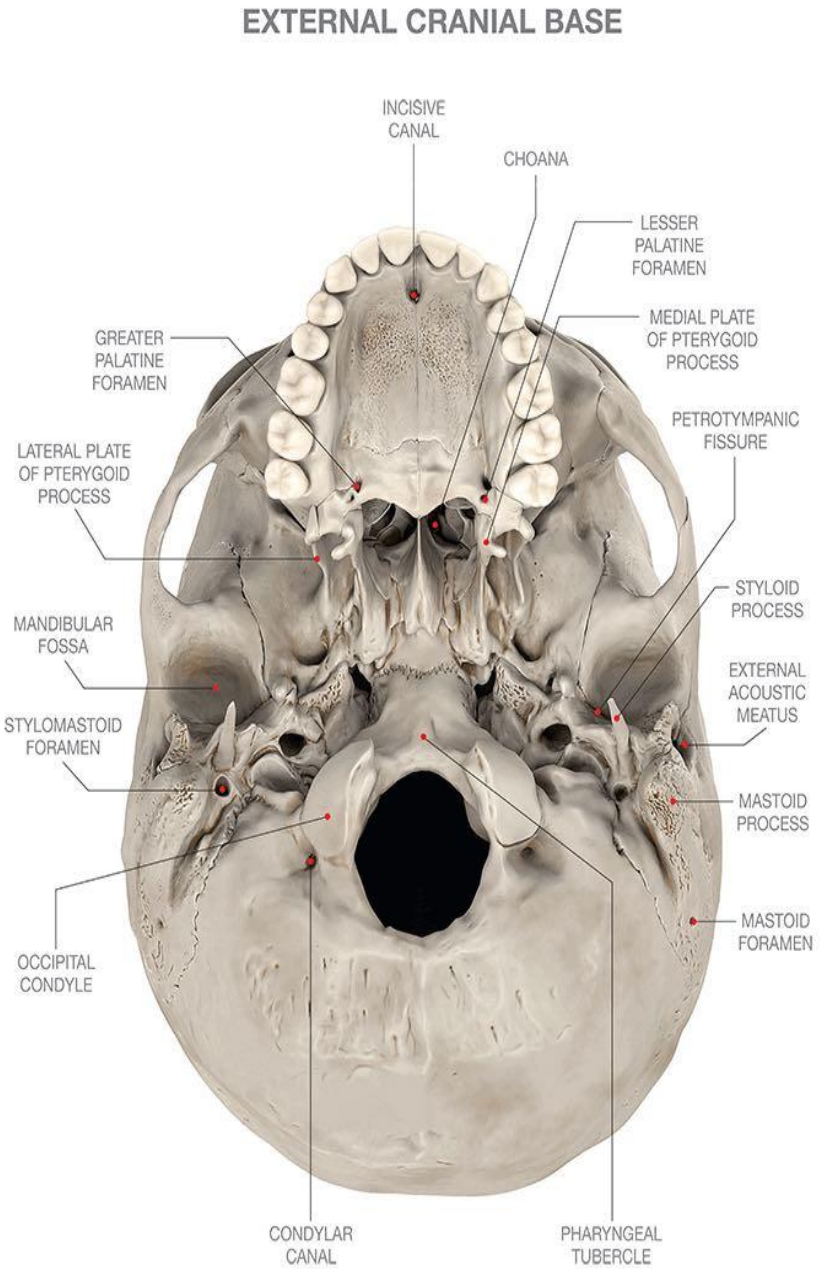

Anatomy.app

Copyrights @ 2021 Anatomy Next, inc. All rights reserved www.anatomy.app

2.Norma basalis interna also called cranial fossa :

Contain brain , meninges , cranial nerve and blood supply, divide into three part :

1.Anterior cranial fossa

2.Middle cranial fossa

3.Posterior cranial fossa



Bounders :

Anterior cranial fossa separated from middle cranial fossa by lesser wing of sphenoid bone , middle cranial fossa separated from posterior cranial fossa by petrous part of temporal bone.

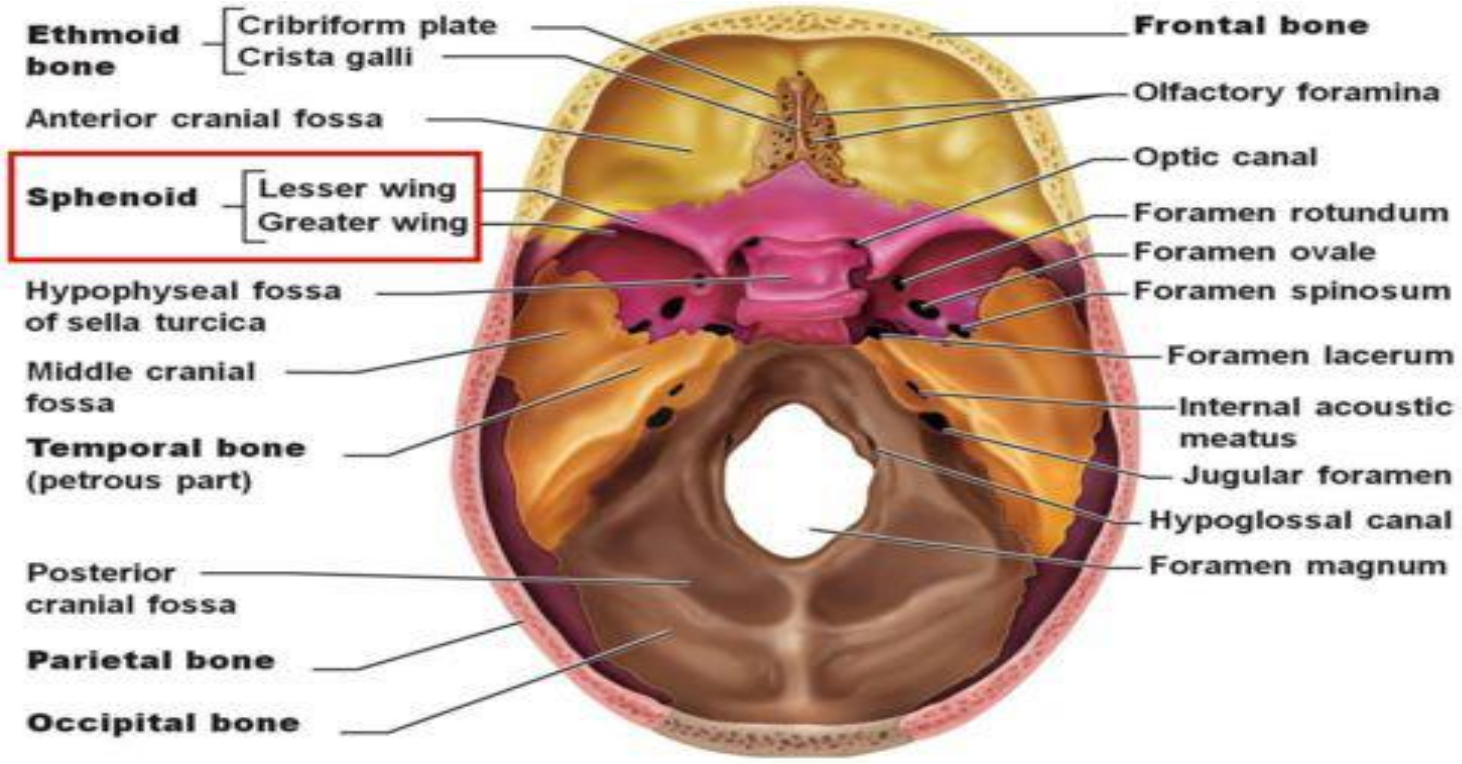

Bones :

1.Frontal bone

2.Ethmoid bone

3.Sphenoid bone

4.Temporal bone

5.Parital bone

6.Occipital bone

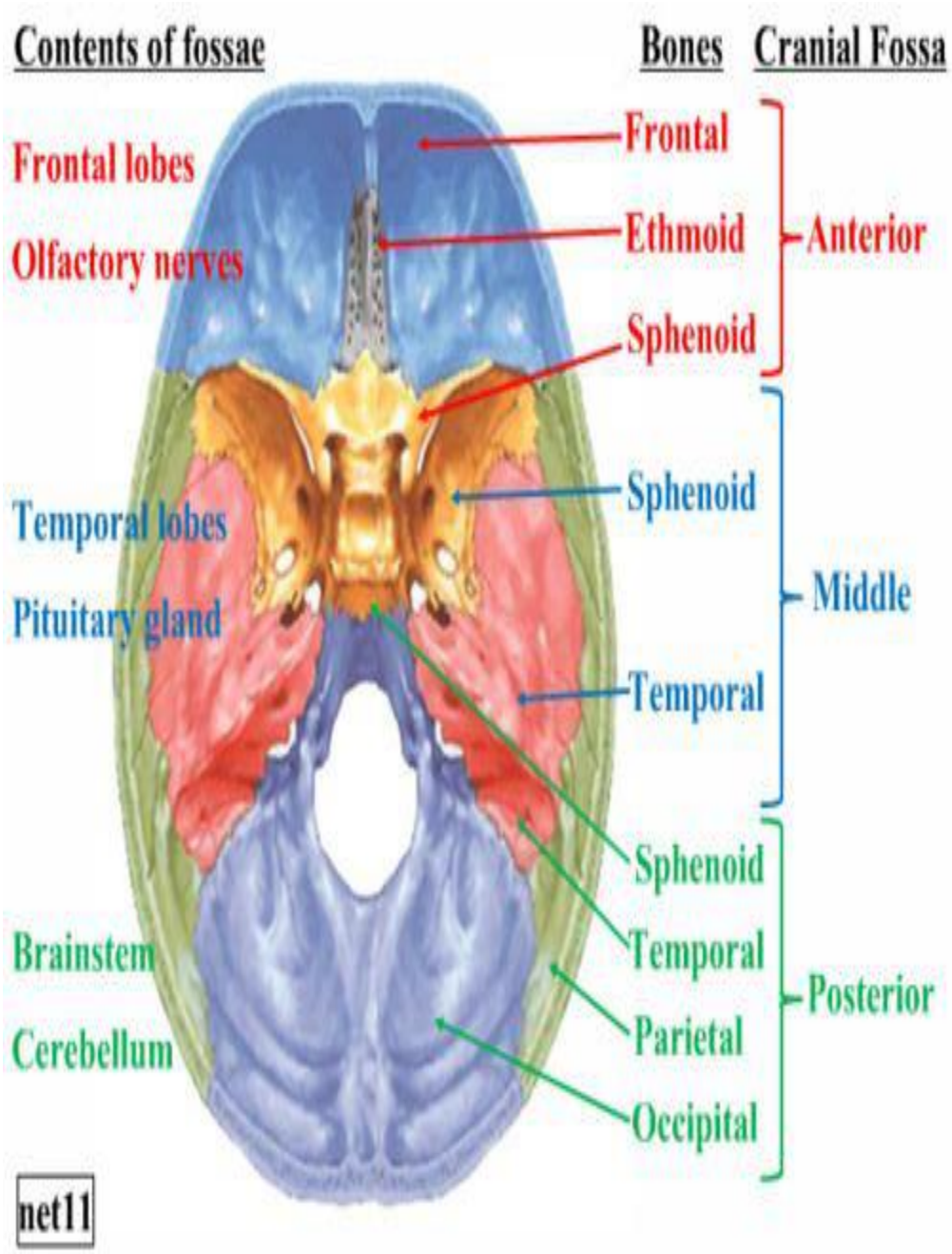

❖Anterior cranial fossa :

- **Foramen cecum** between ethmoid and frontal bone (emissary vein).
- **Anterior and posterior ethmoidal foramen** between ethmoid and frontal bone (anterior and posterior ethmoidal nerve and vessels).
- **Cribriform palate** in ethmoid bone (olfactory nerve).

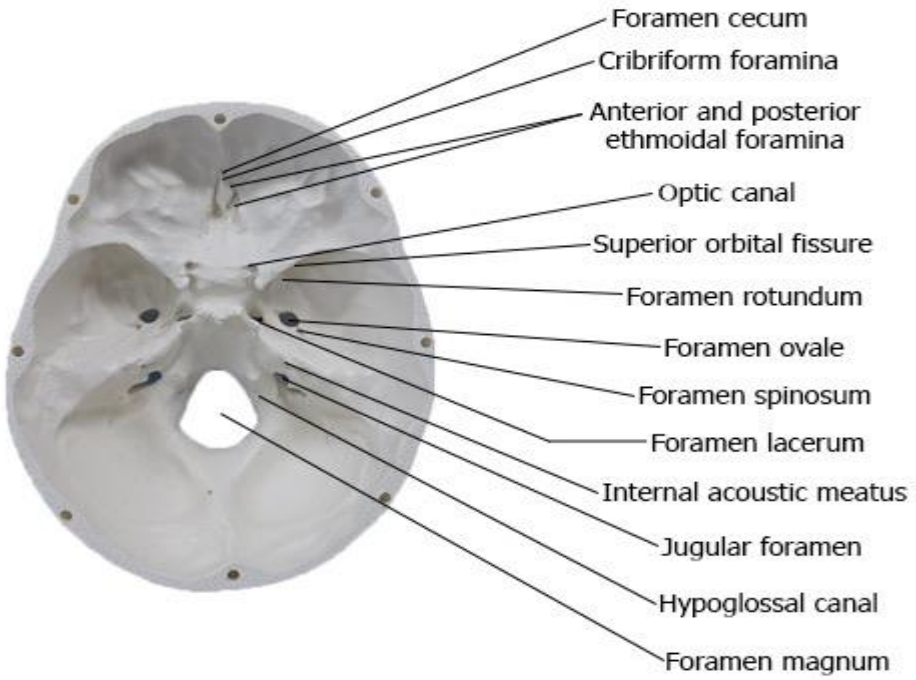

❖ **Middle cranial fossa :**

- Sellae turcica (anterior clinoid process, posterior clinoid process, tuberculum sellae, pituitary fossa and dorsum sellae)
- **Optic canal** in sphenoid bone (optic nerve and ophthalmic artery).
- **Superior orbital fissure** between greater and lesser wing of sphenoid bone (ophthalmic division of trigeminal nerve, coulometer n., trochlear n., abducent n, superior and inferior ophthalmic vessels)
- **Foramen rotundum** in greater wing of sphenoid bone (maxillary division of trigeminal nerve).
- **Foramen ovale** in greater wing of sphenoid bone (mandibular division of trigeminal nerve (v3), accessory meningeal artery , lesser petrosal nerve and emissary vein).
- **Foramen spinosum** in greater wing of sphenoid bone (meningeal branch of mandibular division of trigeminal nerve and middle meningeal vessels) .
- **Foramen lacerum** (between greater wing of sphenoid , petrous part of temporal bone and basilar part of occipital bone) (greater petrosal nerve).

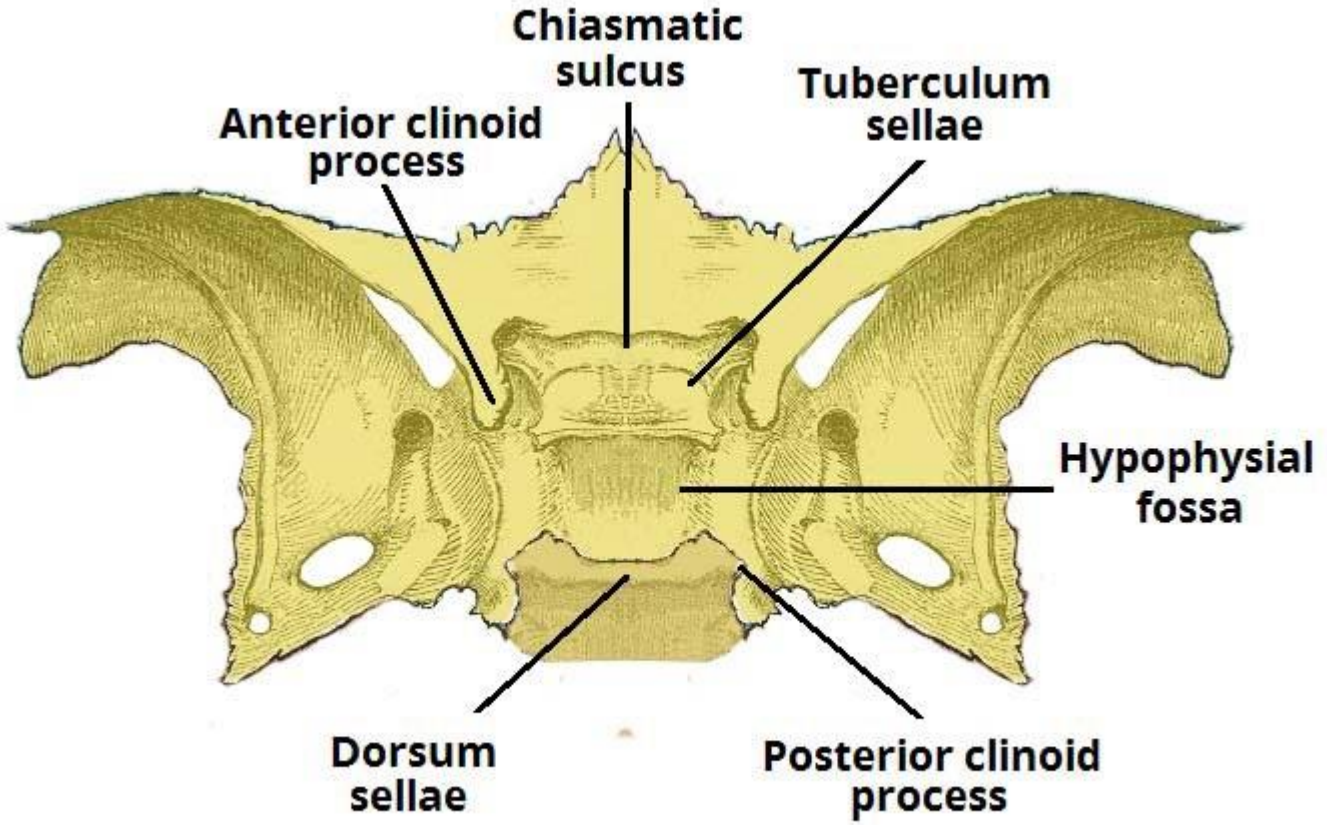
Chiasmatic sulcus
Tuberculum sellae
Anterior clinoid process
Hypophysial fossa
Dorsum sellae
Posterior clinoid process
© TeachMeAnatomy

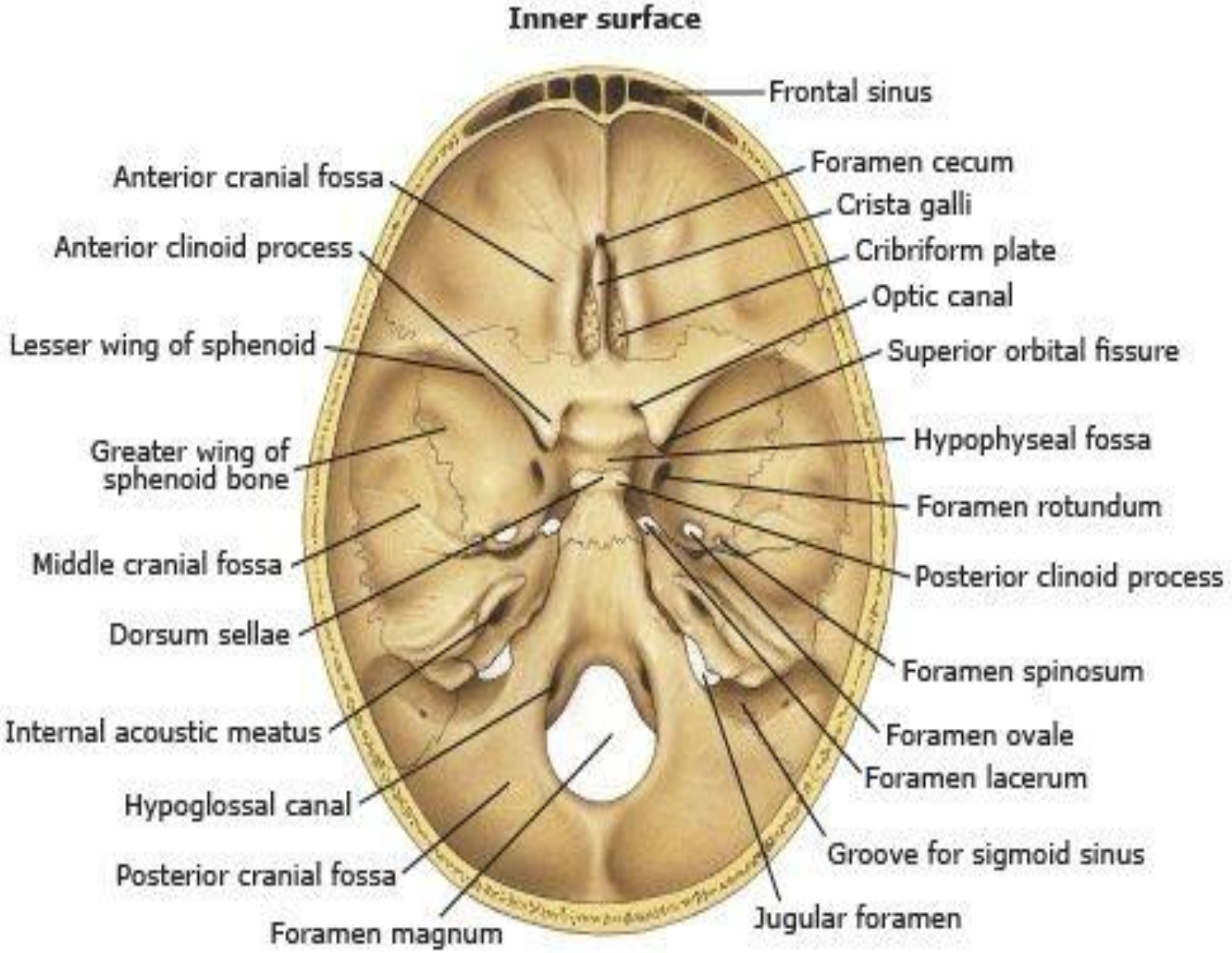
Inner surface
Frontal sinus
Anterior cranial fossa
Foramen cecum
Crista galli
Anterior clinoid process
Cribriform plate
Optic canal
Lesser wing of sphenoid
Superior orbital fissure
Greater wing of sphenoid bone
Hypophyseal fossa
Foramen rotundum
Middle cranial fossa
Posterior clinoid process
Dorsum sellae
Foramen spinosum
Internal acoustic meatus
Foramen ovale
Foramen lacerum
Hypoglossal canal
Groove for sigmoid sinus
Posterior cranial fossa
Jugular foramen
Foramen magnum

❖Posterior cranial fossa

- **Jugular foramen** between temporal and occipital bone (glossopharngeal nerve , vagus nerve , cranial part of accessory, inferior petrosal sinuses and sigmoid sinuses)
- **Internal auditory meatus** in temporal bone (facial nerve, vestibulocichler nerve)
- **Foramen magnum** in occipital bone (spinal cord and its meninges, vertebral artery, spinal part of accessory nerve and medulla oblongata).
- **Hypoglossal canal** in occipital bone (hypoglossal nerve).
- Clivus , internal occipital crest , internal occipital proterbarnce, groove for transverse sinus and groove for sigmoid siuns .

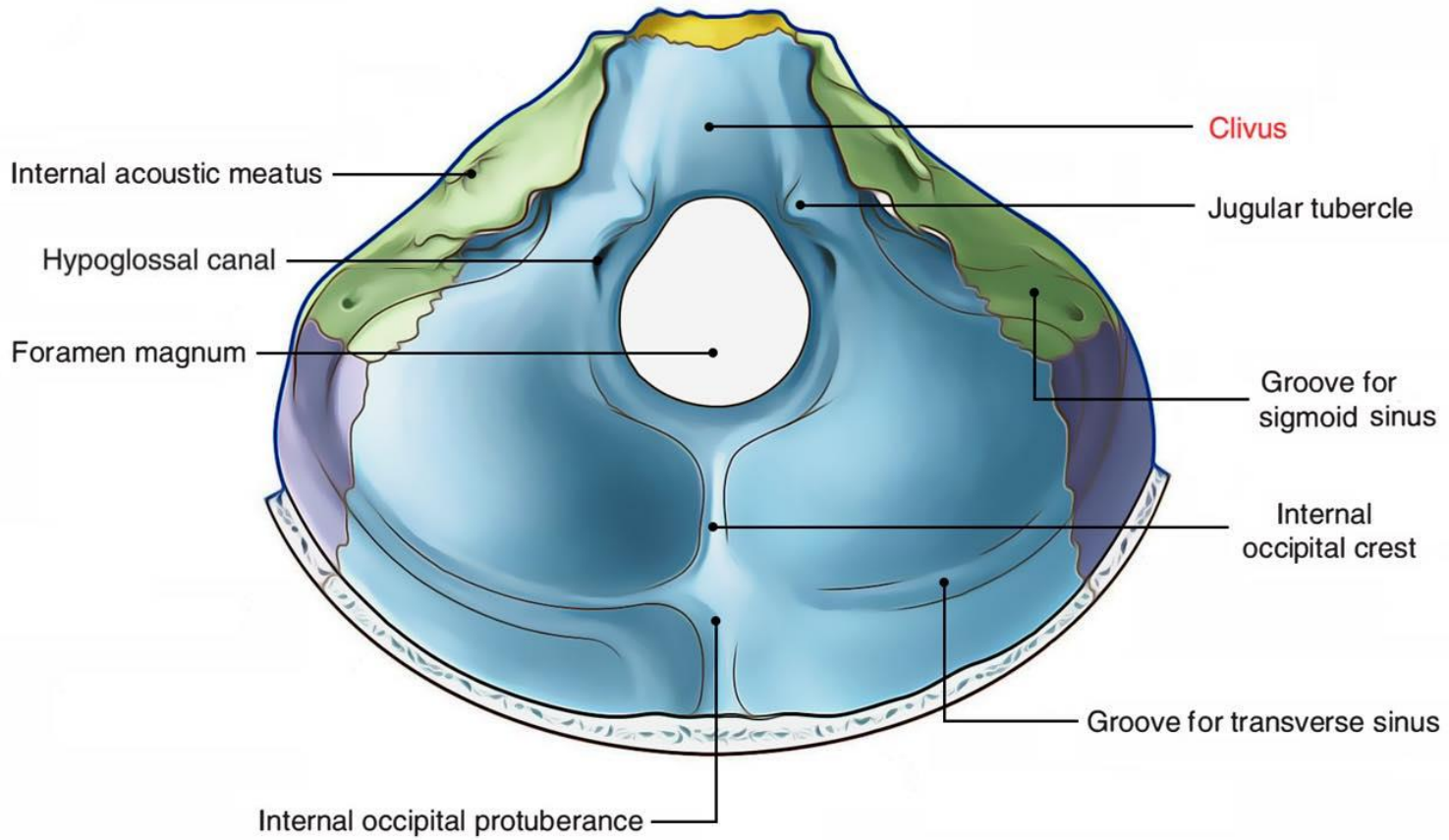
Clivus
Internal acoustic meatus
Jugular tubercle
Hypoglossal canal
Foramen magnum
Groove for sigmoid sinus
Internal occipital crest
Groove for transverse sinus
Internal occipital protuberance

Thanks