Human Anatomy

Dr.Mustafa Fadhil
PhD.Anatomy & Histology

Lec.11

Temporomandibular joint

The **temporomandibular joint** (**TMJ**) is a modified hinge type of synovial joint, permitting gliding (translation) and a small degree of rotation (pivoting) in addition to flexion (elevation) and extension (depression) movements typical for hinge joints. The bony articular surfaces involved are the **mandibular fossa** and **articular tubercle** of the temporal bone superiorly, and the **head of the mandible** (condylar process) inferiorly (**Fig. 1**). Unlike most synovial joints, its articular surfaces are covered with fibrous cartilage rather than hyaline cartilage and the joint cavity is divided by a fibrocartilaginous articular disc into upper and lower cavities (**Fig. 2A**).

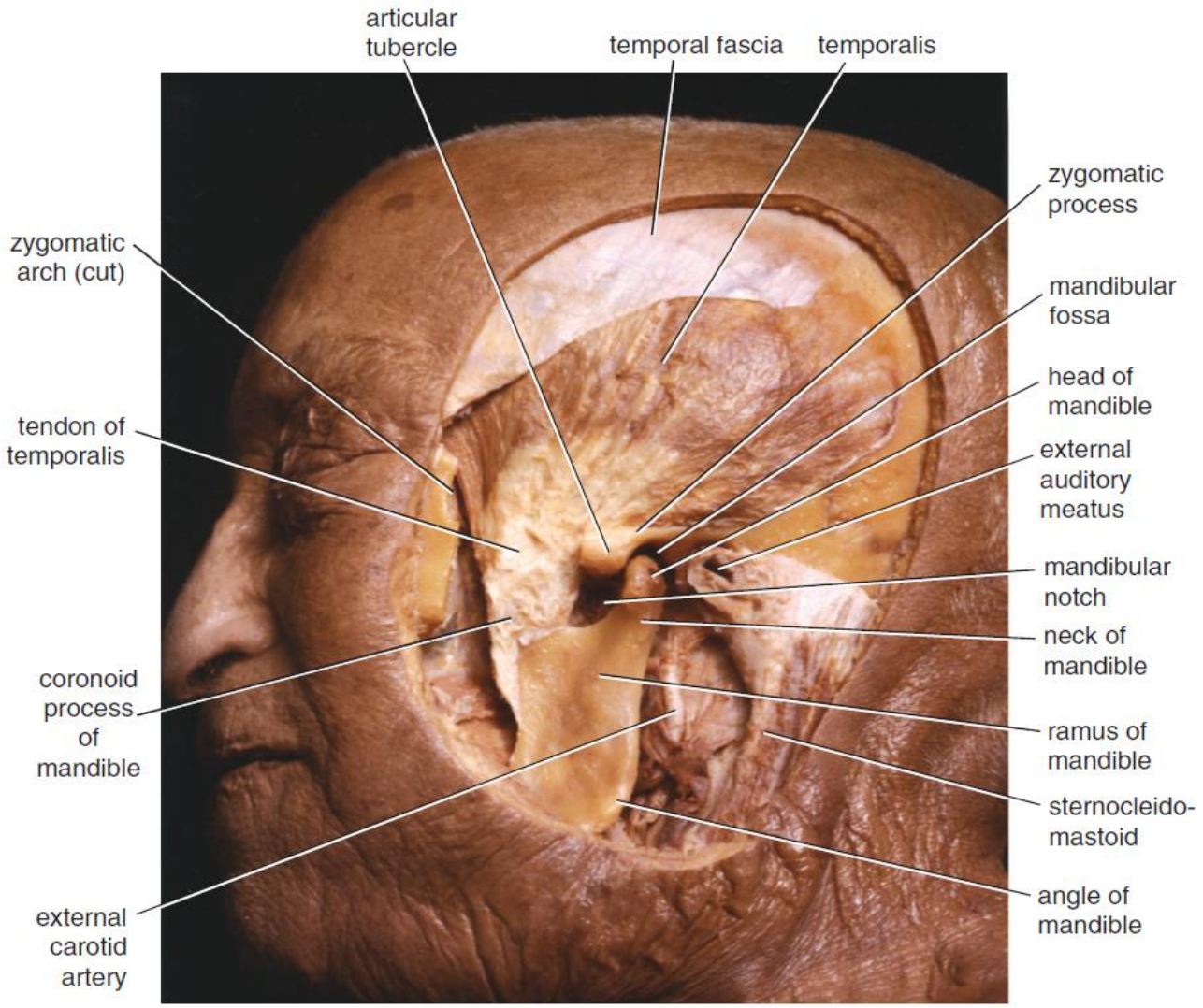

FIGURE 1: A dissection of the left temporomandibular joint.

The Articular Disk

The articular disk (**Fig. 2 A&B**) is composed of dense fibrous connective tissue and is **non-vascularized** and **non-innervated**, an adaptation that allows it to resist pressure. Anatomically the disk can be divided into three general regions: the anterior band, the central intermediate zone, and the posterior band (**Fig. 3)**. The intermediate zone is thinnest and is generally the area of function between the mandibular condyle and the temporal bone.

Retrodiscal Tissue

Posteriorly the articular disk blends with a highly vascular, highly innervated structure (the bilaminar zone), which is involved in the production of synovial fluid (**Fig. 3**). The superior aspect of the retrodiskal tissue, termed the superior retrodiskal lamina, contains **elastic fibers** attached to the tympanic plate and act as a restraint to disk movement in extreme translator movements. The inferior aspect of the retrodiskal tissue, termed the inferior retrodiskal lamina, consists of **collagen fibers** connected to the posterior margin of the condyle and thought to serve to prevent extreme rotation of the disk on the condyle in rotational movements.

Capsule

The capsule surrounds the joint and is attached above to the articular tubercle and the margins of the mandibular fossa and below to the neck of the mandible. It permits side-to-side motion, protrusion, and retrusion. The two bony articular surfaces are completely separated by intervening fibrocartilage, the **articular disc of the TMJ (Meniscus),** attached at its periphery to the internal aspect of the fibrous capsule. This creates separate **superior** and **inferior articular cavities,** or compartments, lined by separate **superior** and **inferior synovial membranes.**

Synovial Membrane

The synovial membrane is a thin, smooth, richly innervated vascular tissue (without an epithelium) that lines the capsule (**Fig. 4**). Lining the inner aspect of all synovial joints, including the TMJ, are two types of tissue: articular cartilage and synovium. The space bound by these two structures is termed the synovial cavity, which is filled with synovial fluid that contains a high concentration of hyaluronic acid that is thought to be responsible for the fluid's high viscosity. The synovium is capable of rapid and complete regeneration following injury. Functions of the synovial fluid include

lubrication of the joint, phagocytosis of particulate debris, and nourishment of the articular cartilage. The concentration of hyaluronic acid and hence the viscosity of the synovial fluid is greater at the point of load, thus protecting the articular surfaces.

Ligaments

- The **lateral temporomandibular ligament** strengthens the lateral aspect of the capsule, and its fibers run downward and backward from the tubercle (in the root of zygoma) to the lateral surface of the neck of the mandible (**Fig. 5**). This ligament limits the movement of the mandible in a posterior direction and thus protects the external auditory meatus.
- **The articular disc** divides the joint into upper and lower cavities. It is an oval plate of fibrocartilage that is attached circumferentially to the capsule. It is also attached in front to the tendon of the lateral pterygoid muscle and by fibrous bands to the head of the mandible. These bands ensure that the disc moves forward and backward with the head of the mandible during protraction and retraction of the mandible. The upper surface of the disc is concavo-convex from before backward to fit the shape of the articular tubercle and the mandibular fossa; the lower surface is concave to fit the head of the mandible (**Fig. 3**).
- The **stylomandibular ligament** lies behind and medial to the joint and extends from the apex of the styloid process to the angle of the mandible (**Fig. 5**). This ligament limits anterior protrusion of mandible.
- The **sphenomandibular ligament** lies on the medial side of the joint (**Fig. 5**). It is a thin band that is attached above to the spine of the sphenoid bone and below to the lingula of the mandible. This ligament may act as a pivot by providing tension during opening and closing.

Nerve Supply

The nerve supply to the TMJ is predominantly from branches of the **auriculotemporal** nerve with anterior contributions from the **masseteric** nerve and the **posterior deep temporal** nerve (**Fig. 2E**).

Vascular Supply

The vascular supply of the TMJ arises primarily from branches of the **superficial temporal** and **maxillary** arteries posteriorly and the **masseteric** artery anteriorly. There is a rich plexus of veins in the posterior aspect of the joint, which alternately fill

and empty with protrusive and retrusive movements respectively, and which also function in the production of synovial fluid.

Movements

TMJ movements are produced chiefly by the **muscles of mastication (Table 1;** See also **Fig. 4)**. The mandible can be depressed or elevated, protruded or retracted. Rotation can also occur, as in chewing. In the position of rest, the teeth of the upper and lower jaws are slightly apart. On closure of the jaws, the teeth come into contact. Generally, depression of the mandible is produced by gravity. The **suprahyoid** and **infrahyoid** muscles are primarily used to raise and depress the hyoid bone and larynx (**Fig. 4C**). Indirectly they can also help depress the mandible, especially when opening the mouth suddenly, against resistance, or when inverted (e.g., standing on one's head). The platysma can be similarly used.

Important Relations of the Temporomandibular Joint

Anteriorly: The mandibular notch and the masseteric nerve and artery.

Posteriorly: The tympanic plate of the external auditory meatus and the glenoid process of the parotid gland

Laterally: The parotid gland, fascia, and skin.

Medially: The maxillary artery and vein and the auriculotemporal nerve.

TABLE 1: Movements of temporomandibular joint.

Movements of Mandible	Muscle(s)
Elevation (close mouth)	Temporalis, masseter, and medial pterygoid
Depression (open mouth)	Lateral pterygoid, suprahyoid, and infrahyoid muscles[a]
Protrusion (protrude chin)	Lateral pterygoid, masseter, and medial pterygoid[b]
Retrusion (retrude chin)	Temporalis (posterior oblique and near horizontal fibers) and masseter
Lateral movements (grinding and chewing)	Temporalis of same side, pterygoids of opposite side, and masseter

[a] The prime mover is normally gravity; these muscles are mainly active against resistance.

[b] The lateral pterygoid is the prime mover here, with minor secondary roles played by the masseter and medial pterygoid.

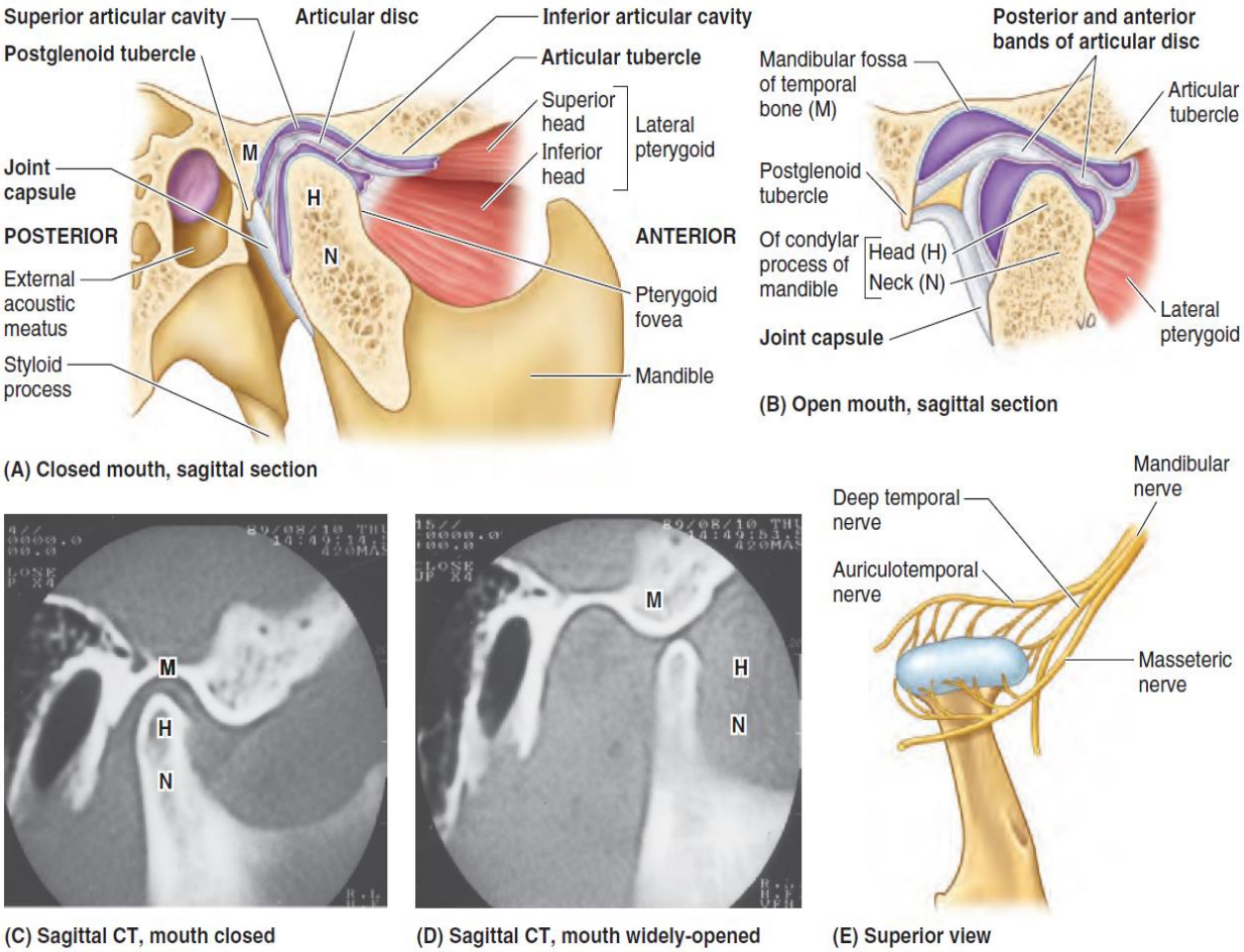

FIGURE 2: Temporomandibular joint (TMJ). **A–D**: Anatomical and CT images of the TMJ in the closed- and open-mouth positions. **E:** Innervation of TMJ.

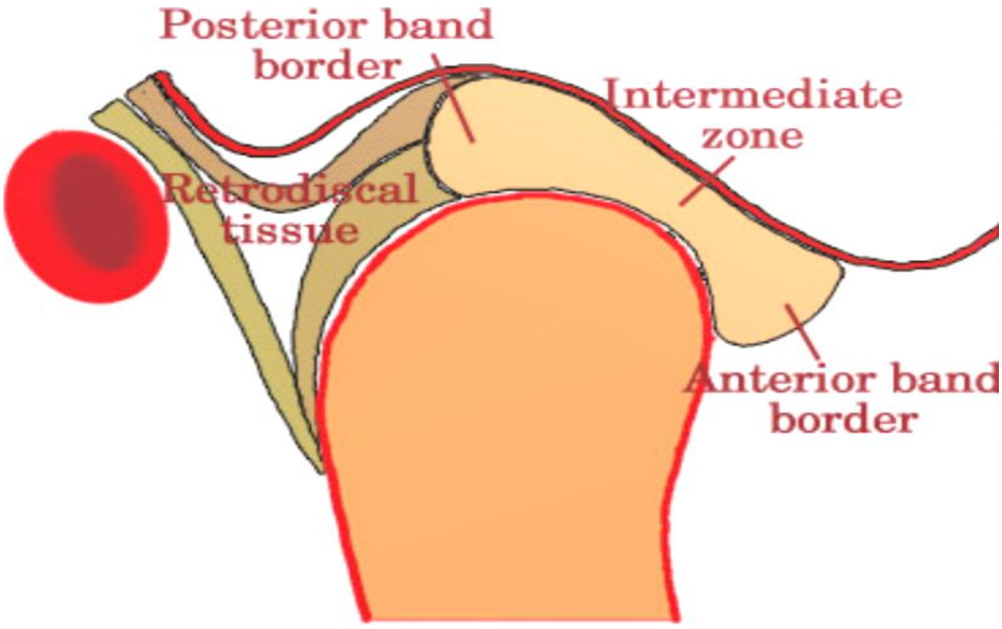

FIGURE 3: The meniscus and retrodiscal tissue.

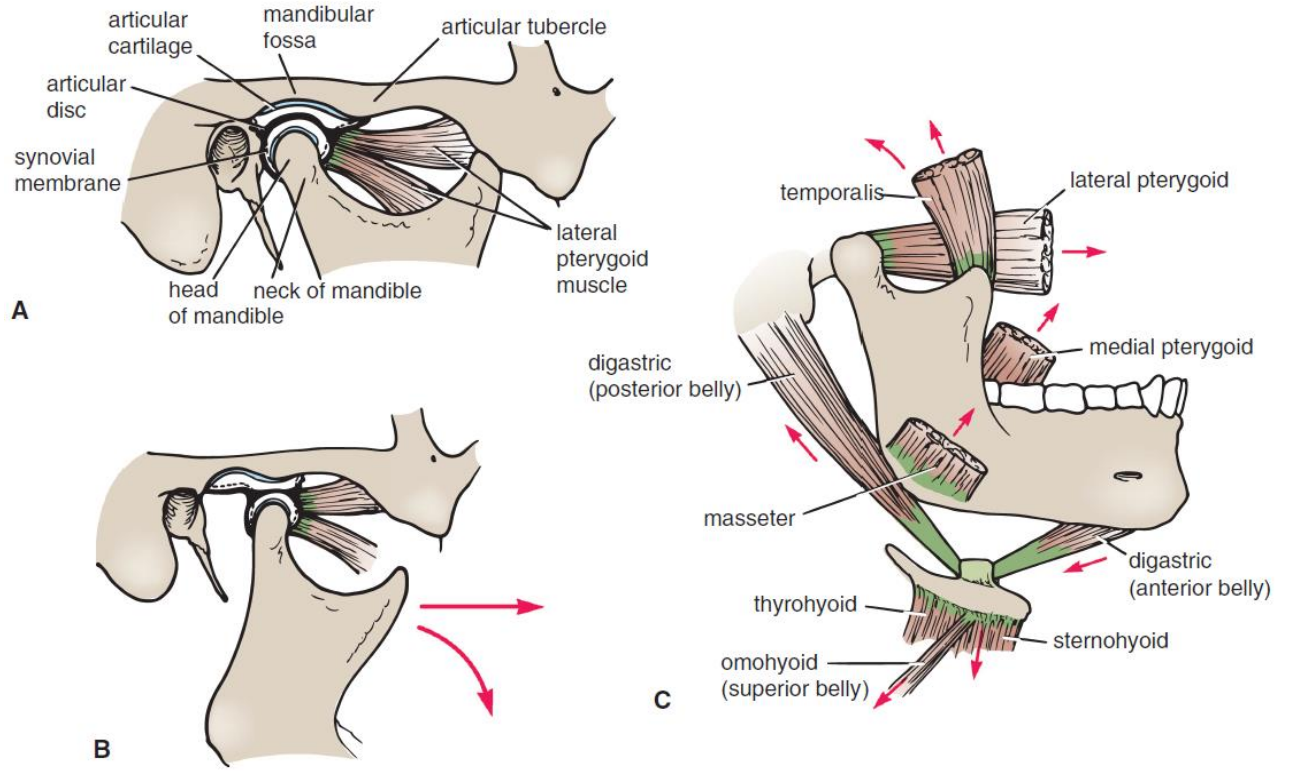

FIGURE 4: Temporomandibular joint with mouth closed **(A)** and with the mouth open **(B)**. **(C):** The attachment of the muscles of mastication to the mandible. The arrows indicate the direction of their actions.

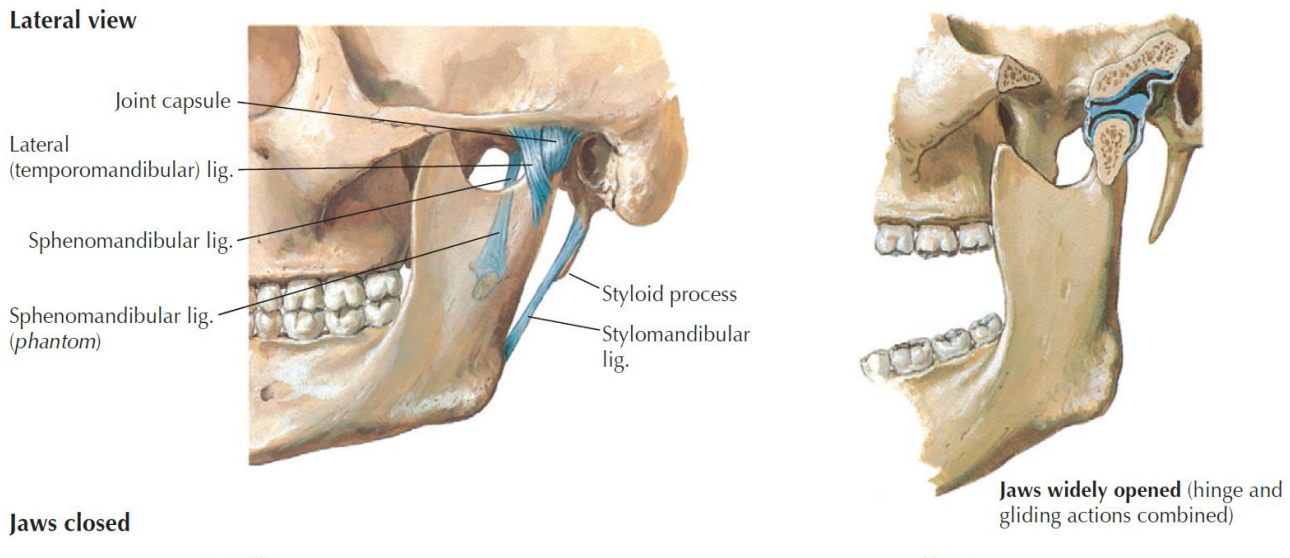

FIGURE 5: Ligaments of temporomandibular joint.

Clinical Notes

The temporomandibular joint lies immediately in front of the external auditory meatus. The great strength of the lateral temporomandibular ligament prevents the head of the mandible from passing backward and fracturing the tympanic plate when a severe blow

falls on the chin. The articular disc of the temporomandibular joint may become partially detached from the capsule, and this results in its movement becoming noisy and producing an audible click during movements at the joint.

Dislocation of TMJ

Sometimes during yawning or taking a large bite, excessive contraction of the lateral pterygoids may cause the heads of the mandible to dislocate anteriorly (pass anterior to the articular tubercles) (**Fig. 6**). In this position, the mandible remains depressed and the person is unable to close his or her mouth and the condition can be quite painful. Posterior dislocation is uncommon, being resisted by the presence of the postglenoid tubercle and the strong intrinsic lateral ligament.

Reduction of the dislocation is easily achieved by pressing the gloved thumbs downward on the lower molar teeth and pushing the jaw backward. The downward pressure overcomes the tension of the temporalis and masseter muscles, and the backward pressure overcomes the spasm of the lateral pterygoid muscles.

Surgery of TMJ

Because of the close relationship of the facial and auriculotemporal nerves to the TMJ, care must be taken during surgical procedures to preserve both of them. Injury to these nerves usually leads to laxity and instability of the TMJ.

Arthritis of TMJ

The TMJ may become inflamed from degenerative arthritis. Abnormal function of the TMJ may result in structural problems such as dental occlusion and joint clicking (**crepitus**). The clicking is thought to result from delayed anterior disc movements during mandibular depression and elevation.

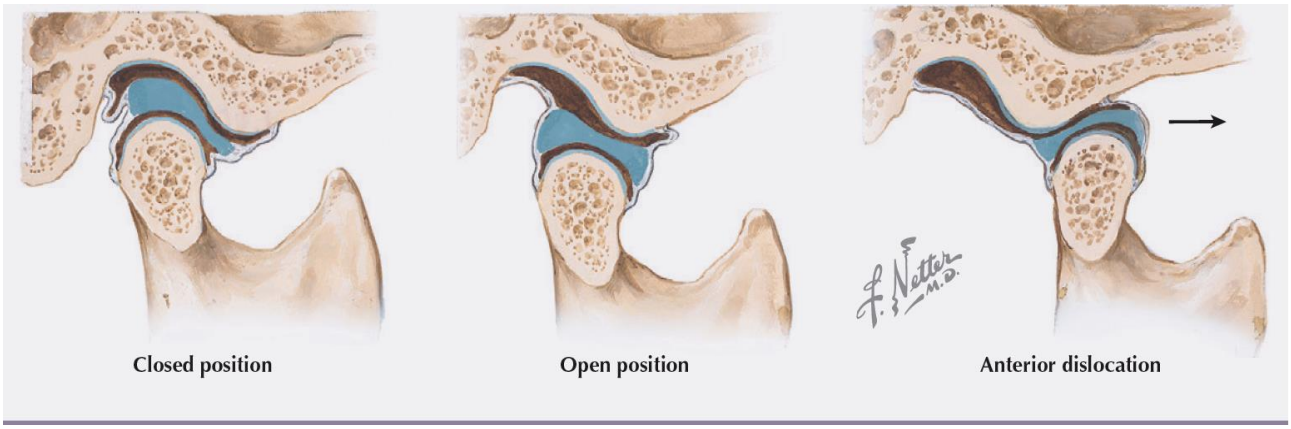

FIGURE 6: Dislocation of temporomandibular joint.

References

1. **Snell RS: Clinical anatomy by regions. Lippincott Williams & Wilkins, 2011.**
2. **Keith LM: Clinically Oriented Anatomy, 7th edition. Wolters Kluwer, 2014.**
3. **Hansen JT: Netter's Clinical Anatomy, 3rd edition. E-Book with Online Access. Elsevier Health Sciences, 2014.**