Tooth development

A process is also known as **odontogenesis**.
Tooth development is the complex process by which **teeth** form from **embryonic cells**, **grow**, and erupt into the **mouth**. It is started at **6th week** of gestation.

odontogenesis involves the development of primary (**deciduous**) and permanent (secondary) dentition, and overlapping period between the primary and secondary dentition is referred to as the **mixed dentition** period.
The process of development for both dentitions is similar, only the time of development is different.

Two embryonic tissues are responsible for the development of a tooth:

1. **Ectomesenchymal** tissues(neural crest in origin) which give rise to the dentin , pulp, periodontal ligament , cementum and part of alveolar bone
2. **Oral epithelium** (ectoderm) which gives rise to enamel of the tooth.

FORMATION OF PRIMARY DENTITION
Stages of development:

1. **INTIATION STAGE**:

The first sign of tooth development is appearance of condensation of ectomesenchymal tissue and capillary network beneath the presumptive dental epithelium. Certain areas of basal cells of oral ectodermal epithelium proliferate more rapidly than do the cells of the adjacent areas, to form the **primary epithelial band** (Figure 16).

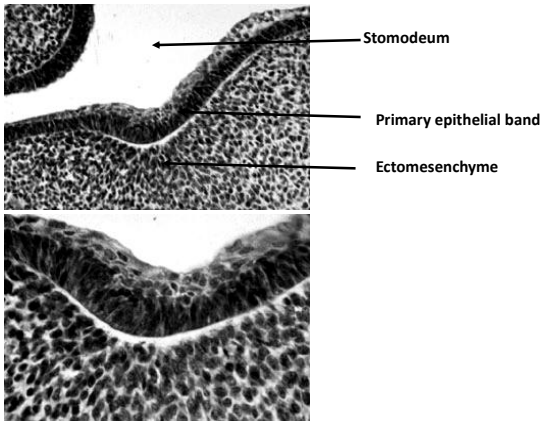

Figure (16) : showing the initiation stage of odontogenesis,notice the two types of tissue involved in tooth development i.e the oral epithelium and ectomesenchyme.

Dr. Akram Yousif yasear

The **dental lamina, which** is a band of epithelium, invades the ectomesenchymal cells along each of horse shoe-shaped future dental arch in a form of **small rounded swellings** .From its free edge to its base where the lamina is attached to the mouth epithelium. These epithelial swellings of the lamina are the **enamel organs** which represent the **tooth buds** of deciduous teeth. The developments of enamel organs of permanent molars arise directly from a distal backward extension of the dental lamina of the second molar (Figure 17) .They arise according to the following sequence:
The first permanent molar is initiated at fourth month in utero, the second permanent molar is initiated at 1st year after birth, and the third permanent molar is initiated at 4th or 5th years.

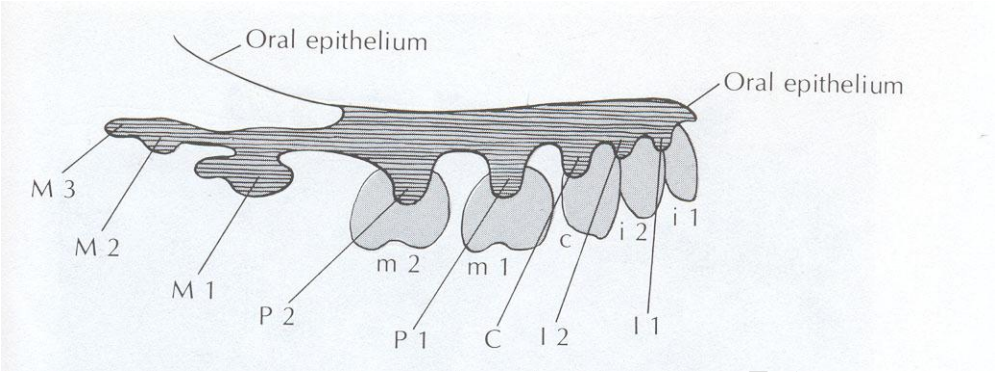

Fig. (17) Showing the development of permanent molars from an extension of dental lamina growing backward underneath the oral epithelium.

The successors of the deciduous teeth (**permanent teeth**) develop from the lingual extension of dental lamina named as the **successional lamina** and developed during the 5th month in utero (**permanent central incisor**) to 10th month of baby age (second permanent premolar).

A timetable to remember
Entire primary dentition initiated between 6 and 8 weeks of embryonic development.
Successional permanent teeth initiated between 20th week in utero and 10th month after birth
Permanent molars between 20th week in utero (first molar) and 5th year of life (third molar)

FATE OF DENTAL LAMINA: -

The activity of dental lamina extends over a period of at least 5 years. During these five years the dental lamina still active in the third molar region after it has disappeared elsewhere. As the teeth continue to develop they lose their connection with dental lamina. They later break up by mesenchymal invasion. Remnants of the dental lamina persist as ***epithelial pearls of Serres*** within the jaw and gingiva(figure 18).

Dr. Akram Yousif Yasear

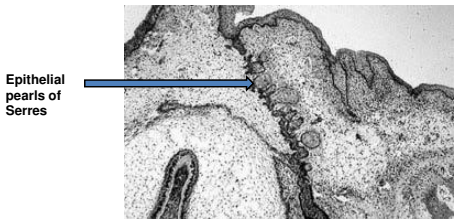

Figure (18): Epithelial pearls of Serres as one of the fate of dental lamina

2) BUD STAGE: -

It occurs at 8 week. It is named so, because there is an extensive proliferation or in growth of the dental lamina into buds or ovoid swelling (masses) penetrating into the ectomesenchymal. This penetration is occurring at 10 different locations involving the primary (deciduous) dentition of maxillary arch and 10 sites for mandibular arch. The underlying ectomesenchyme also undergo proliferation.
These buds are representing the primordial of the enamel organs of primary dentition .

3) CAP STAGE: -
By the eleventh week, the tooth bud continues to proliferate. There is unequal growth in different parts of the tooth bud leading to formation of cap shape structure attached to the dental lamina, which is characterized by a shallow invagination on the deep surface of the bud (Figure 20).The epithelial cells now become the **enamel organ** and remain attached to the dental lamina.

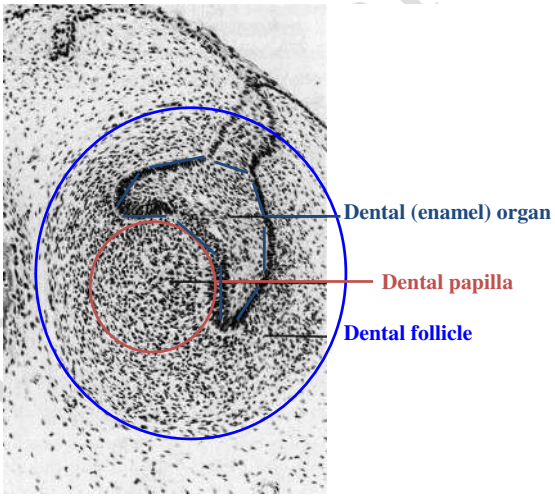

Figure 20: Is showing the cap stage of tooth development. The three parts of tooth germ is represented by enamel organ; dental papilla; and dental follicle.

Dr. Akram Yousif yasear

4) BELL STAGE: -

It has two sub stages **early bell** and **late bell stage**. During this stage there will a determination of the shape of the crown for the tooth.

Early bell stage:

It occurs between twelve to fourteenth week. Four types of epithelial layers could be seen in the enamel organ at this stage (Table 2 and figures 21 and 22):

i. Inner enamel epithelium: Consists of a single layer of cells that differentiate prior to amelogenesis into tall columnar cells called **ameloblasts.**

ii. Stratum intermedium: This layer is essential for the enamel formation because its cells contain alkaline phosphatase.

iii. **Stellate reticulum** :The cells are star-shaped with long processes
Its function includes:
Protection of stratum intermedium and inner enamel epithelium,

iv. Outer enamel epithelium:

Dental papilla: Part of its ectomesenchyme differentiate into odontoblasts.
Dental sac (follicle): Its ectomesenchyme will form the cementum, PDL and part of alveolar bone.

Yousif yasear



Figure 21: Early bell stage, which exhibits differentiation of the tooth germ. Note the enamel organ and the dental papilla. The layers of enamel organ:outer enamel epithelium(OEE);inner enamel epithethelium(IEE) both layers meet at cervical loop.The successional lamina for secondary tooth appear at this stage.

b. Late bell stage

The late bell stage is associated with the formation of first dental hard tissues of the crown which include the dentin and enamel. Usually the dentin is formed before the enamel.

The formation of dentin marks the onset of the crown stage of tooth development.

Formation of the crown is having occuluso-cervical direction of hard tissue formation

After completion of the development of the crown the remnant of the enamel organ is called reduced enamel epithelium. The function of the reduced enamel epithelium is to protect the recently formed crown.

Root of tooth development

Root development is a multistep process.

1. Root development starts after crown completion, i.e. when the enamel and dentin formation of the crown have reached the cervical area of the crown or the future cemento-enamel junction.
2. At the cervical region of the crown two layered cells sheath is extending from the crown. It is consisting of outer and inner enamel epithelium only .That sheath is called
Hertwig's epithelial root sheath. The root sheath *does not* include the stratum intermedium and stellate reticulum.
3. The epithelial root sheath grows apically. Thus the epithelial root sheath is important to molds the shape of the roots and initiates radicular dentin formation.

4. The next step is bending of the root sheath toward the median side to form the
epithelial diaphragm. There will be a space left in the middle which marks the future position of the apical foramen. The epithelial diaphragm encircles the apical opening of the dental papilla during root development.
The epithelial diaphragm position represents the apical limit of the root; any part of the root formed will move the crown in occlusal direction. In fact the beginning of root development is concomitant with a very important process called the <u>eruption</u> of the tooth towards the mouth cavity.

Dr. Akram Yousif yasear

5. Epithelial root sheath initiates the formation of dentin in the root of a tooth by causing the differentiation of odontoblasts from the ectomesenchymal cells of dental papilla.

6. As the odontoblasts differentiate along the pulpal boundary, root dentinogenesis proceeds and the root lengthen. Dentin formation continues from the crown into the root.
7. As part of root dentin is formed, there will be partial fragmentation of the epithelial root sheath. Thus there will be an exposure of the recently formed dentin to the ectomesenchymal cells of the dental follicle which induced the differentiation of the adjacent ectomesenchymal cells of dental follicle into cementoblasts, which start depositing cementum on the surface of root dentin, thus establish cemento-dental junction. On the other hand, the middle part of the ectomesenchymal cells of dental follicle will differentiate into fibroblast which will form the fibers of the PDL. At the same time the peripheral ectomesenchymal cells of the dental follicle will differentiate into osteoblasts which in turn going to form the alveolar bone.
So four tissues have been formed, viz: the root dentin, cementum, PDL, and alveolar bone, but in step wise manner. All these events are accompanied by the occlusal movement of the crown toward the mouth cavity in a process called the tooth *eruption*.
8. The remnant of the root sheath will be represented by groups of cells distributed in between the fibers of the PDL called rest cells of Malassez.

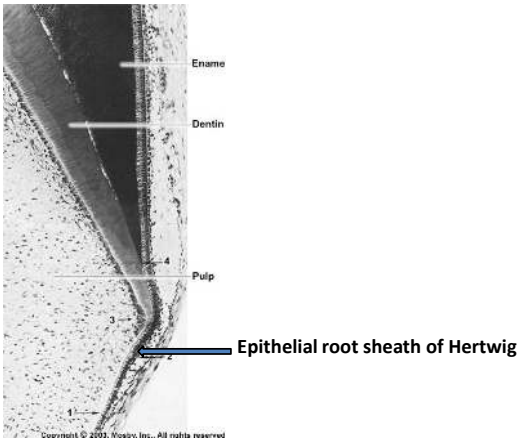

Dr. Akram Yousif Yasear

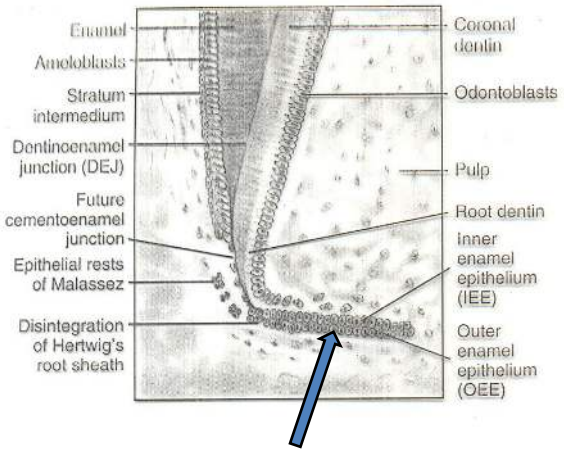

Figure 27 :Formation of epithelial diaphragm prior to the formation of the root.

DEVELOPMENT OF THE SECONDARY DENTITION: -

1- The incisors, canines, and premolars of 2nd dentition:-

These teeth are developed from tooth buds growing off the dental lamina as **successional lamina** at the level of the tooth germs of the primary dentition, which are at that time, were in the bell stage.

.

2. The molars of the secondary dentition:

They have no primary predecessors. Their enamel organs develop from a blind backward extension of the dental lamina of the primary dentition. This blind extension grows backward in the jaw, underneath the oral mucosa, from the dental lamina of the second molars of the primary dentition. This extension give rise, in succession, to the enamel organs of first, second and third molars of secondary dentition.

The development of the first permanent molar is initiated at the fourth month in utero, the second molar is initiated at about first year after birth, the third molar at the fourth or fifth years.

Both the primary and secondary teeth are in different stages of development, but they share a common bony crypt.

THE ROOT FORMATION ANOMALIES:

1- Formation of accessory root canal:
If the continuity of the root sheath were broken before dentin formation, the result could be missing or defective epithelial cells. The odontoblasts would not differentiate, and dentin would not form opposite the defect in the root sheath. The result would be a small lateral canal connecting the PDL with the main root canal. The supplemented canal called accessory root canal.

2- Exposed root dentin: -
This caused by failure of degeneration of the epithelial root sheath at the proper time, and remains adherent to the root dentin surface, so ectomesenchymal cells of the dental follicle will not come in contact with the dentin. Thus ectomesenchymal cells of the dental follicle will not differentiate into cementoblasts and no formation of cementum.
The exposed dentin areas could be found in any place of the root surface especially in cervical zone, and may be the cause of cervical sensitivity late in life when gingival recession takes place.

3-Formation of enamel pearls:
The epithelial root sheath may also remain adherent to the dentin in the cervical area near the furacation zone. In this case the inner cells of the epithelial root sheath may differentiate in functional ameloblast and produce enamel known as enamel pearls. It is found lodged between the roots of permanent molars.

Agents affecting tooth and bone development:

1- Vitamin A deficiency:
In vitamin A deficiency the ameloblast fail to differentiate properly.

2- Vitamin C deficiency:

3- Vitamin D deficiency .

4- Tetracycline and fluorides:
The first formed dentin is showing staining if tetracycline is deposited to the mother from the 5th month of pregnancy until term i.e. during the period of mineralization .The same effect is in the child up to 12 years of age because the period is marked by mineralization of crown extends from 5 months in utero (transplacental crossing) to 12 years of age and include the mineralization of both also include hypoplasia and loss of the enamel. The staining of teeth with tetracycline is permanent while with the **bon**e is **not** due to the process of remodeling of the bone which continuously throughout life.

Dr. Akram Yousif yasear

Dr. Akram Yousif yasear