Tooth mobility

Mobility

Is the loosening of a tooth in its socket& it is of two types : physiologic & pathologic mobility.

Physiological mobility

Tipping movement of the crown of a tooth surrounded by a healthy & intact periodontium& the tooth will tip within its alveolus until a closer contact has been established between root & marginal or apical bony tissue.(Fig.1).

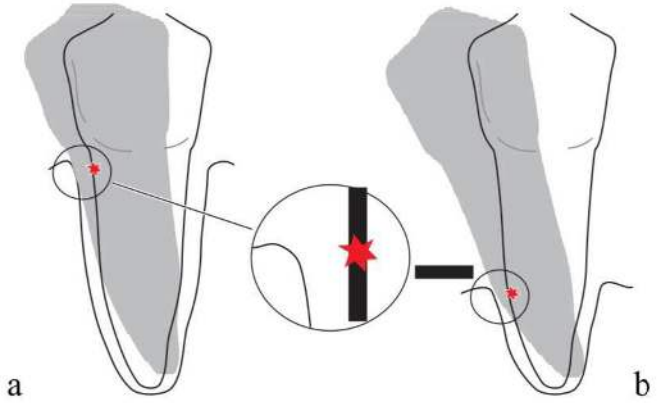

Fig .1

All teeth have a slight degree of physiologic mobility, which varies for different teeth & at different times of the day. It is greatest on arising in the morning & progressively decreases. The increased mobility in the morning is attributed to slight extrusion of the tooth because of limited occlusal contact during sleep. During the waking hours, mobility is reduced by chewing & swallowing forces which intrude the teeth in the sockets. Also this mobility is less marked in persons with healthy periodontium than in those with occlusal habits as bruxism & clenching.

If a similar force is applied to a tooth which is surrounded by a periodontal ligament with an increased width, the excursion of the crown in horizontal direction will become increased; the clinical measurement consequently demonstrates that the tooth has an increased mobility. An increase in displacement of the crown of the tooth after force application, can also be found in situations where the height of the alveolar bone has been reduced but the remaining periodontal ligament has a normal width. At sites where this type of bone loss is extensive, the degree of tooth mobility (i.e. excursion of the crown) may be pronounced.

In (Fig 1 b) a tooth which is surrounded by alveolar bone of reduced height. The width of the remaining periodontal ligament, however, is within normal limits. A horizontally directed force applied to the crown of the tooth in this case will result in a larger excursion of the crown than if a similar force is applied to a tooth with normal height of the alveolar bone and normal width of the periodontal ligament (Fig. 1 a).

Pathologic mobility

Is the progressive increasing tooth mobility, which may occur in conjunction with trauma from occlusion,is characterized by active bone resorption and which indicates the presence of inflammatory alterations within the periodontal ligament tissue. Tooth mobility could be in horizontal or vertical direction.

Horizontal tooth mobility

Is the ability to move the tooth in a facial-lingual direction in its socket. It is assessed by putting the handles of two dental instruments on either side of the tooth and applying alternating moderate pressure in the facial lingual direction against the tooth first with one, then with the other instrument handle (Fig .2)

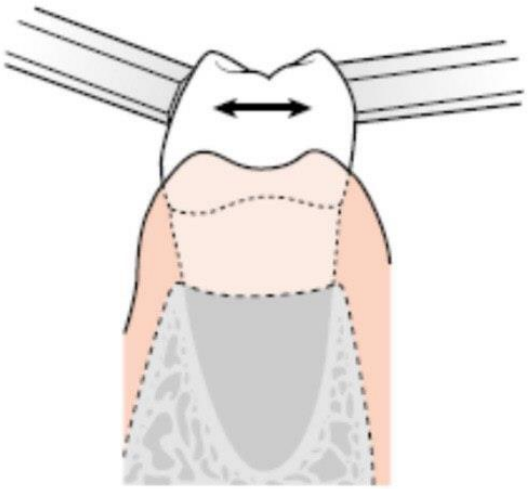

Fig (2) Assessing Horizontal Tooth Mobility. Using the ends of two handles, apply alternating pressure, first from the facial and then from the lingual aspects of the tooth.

Vertical tooth mobility

Is the ability to depress the tooth in its socket, is assessed using the end of an instrument handle to exert pressure against the occlusal or incisal surface of the tooth(Fig .3)

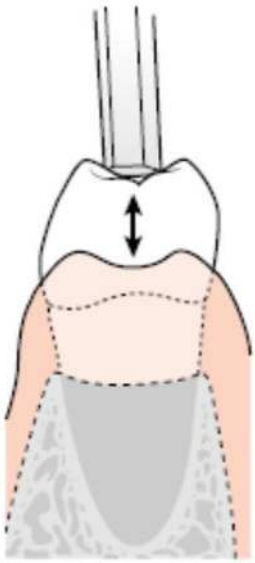

Fig(3) Assessing Vertical Tooth Mobility. Use the end of an instrument handle to exert pressure against the occlusal surface or incisal edge of the tooth.

Tooth mobility has several principal causes:

1. Advanced periodontal diseases & loss of supporting bone: Normally the crest of alveolar bone located about 1-2 mm shorter than C.E.J .The amount of mobility depends on the severity of bone destruction & there will be reduction in the height of bone.
2. Gingival & periodontal inflammation: Mobility will occur by increase the infiltration of connective tissues by fluid of inflammatory exudates.
3. Trauma from occlusion: It is injury to the tissue produced by excessive occlusal forces or occlusal habits as bruxism or clenching & it is a common cause for increased tooth mobility. The pathologic changes that occur because of trauma from occlusion are widening of periodontal ligament space &/or destruction of the bone surrounding the root.
4. Immediately following periodontal therapy: May cause transient mobility for a short period of time because of the surgical trauma (physical trauma rather than bacterial) due to the use of surgical instruments. After 2-3 weeks, the mobility will disappear if the diagnosis, treatment plan & maintenance phase of therapy were done correctly.
5. Pulpal inflammation: Spread of inflammation from periapical area to the periodontal ligament may results in changes that increase tooth mobility

Factors that govern tooth mobility in a horizontal direction:

1.The width of the periodontal ligament space (it is about 0.25mm determined by x-ray).
2. The height of alveolar bone H (is 1mm apical to the C.E.J).
3. Number of roots (multirooted teeth are less subjected to mobility than single rooted teeth).
4. The shape of the roots (short tapered shape root is more susceptible to mobility than normal size & wide roots).
5. The degree & duration of the applied force whether in normal or abnormal function.

Classification of tooth mobility:

T.M. is graded according to the following criteria:
Grade I: is the mobility of the crown 0.2-1 mm in horizontal direction.
Grade II: mobility of the crown of the tooth exceeding 1mm in horizontal direction.
Grade III: mobility of the crown of the tooth in vertical direction as well & the tooth becomes even depressed in its socket.

The displacement of the crown when a force of 500 pounds is applied varies between teeth:
Incisors 0.1-0.12 mm
Canines 0.05-0.09 mm
Premolars 0.08-0.1 mm
Molars 0.04-0.08 mm
& it is larger in children than adults & is larger in females than males & increase during pregnancy.

Signs & symptoms of T.M:

1) **Patient awareness of mobility:** Mobility is detected quite incidentally when patient's attention is brought to tooth by tenderness experienced on chewing.
2) **Functional discomfort:** Pain may be expected following sudden tooth displacement when biting on hard foods or with inadvertent trauma
3) **Aesthetic** : Anterior labial or lateral tooth displacement results in fanning & elongation of clinical crown with poor appearance.

Treatment of increased tooth mobility:

A number of situations will be described for the aim of reducing increased tooth mobility.

Situation I: (increased mobility of a tooth with increased width of the periodontal ligament but normal height of the alveolar bone).

This case is seen in teeth with improper filling or crown restoration (high spot) (fig 7) , so occlusal interferences develop & the surrounding

periodontal tissues become inflamed (trauma from occlusion). If a tooth is subjected to forces directed in buccal direction, bone resorption will develop in the buccal-marginal & lingual-apical pressure zones with a resulting increase in the width of periodontal ligament in these zones. Such traumatizing forces in teeth with normal periodontium can not result in pocket formation or loss of connective tissue attachment, the resulting mobility of the tooth is regarded as a physiological adaptation of the periodontal tissues to the altered functional demands. In such a case bone resorption is a reversible process can be treated by elimination of occlusal interferences or occlual adjustment.

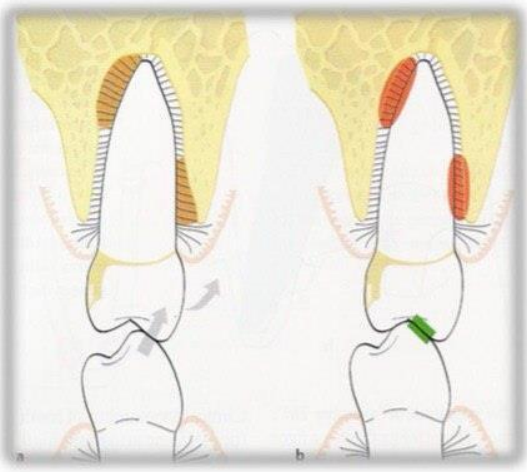

Fig.7

Situation II: (increased mobility of a tooth with increased width of P. D. ligament& reduced height of alveolar bone).

When a dentition properly treated for plaque-associated periodontal disease, gingival health is established but the teeth will be surrounded by periodontal structures of reduced height. If a tooth with reduced periodontal tissue support is exposed to excessive horizontal forces (trauma from occlusion), inflammatory reaction develops in the pressure zone of the periodontal ligament with bone resorption& result in increase width of P.D.ligament& the tooth become hypermobile. Treatment of such a case is by occlusal adjustment & elimination of the excessive force or reduce it, so bone

apposition will occur & the P.D.lig. will regain its normal width & the tooth stabilized (Fig.8).

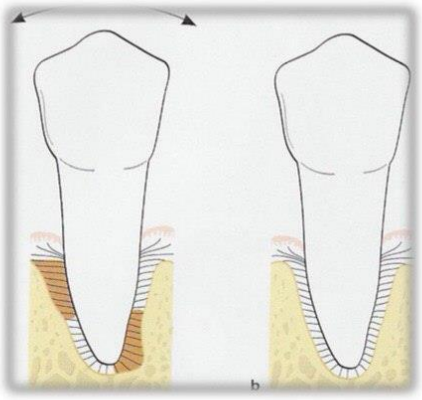

(Fig 8).

Situation III: (increased mobility of a tooth with reduced height of alveolar bone & normal width of P.D.ligament).

In teeth with normal width of P.D.lig, no further bone apposition on the walls of the alveoli can occur. If such an increased tooth mobility does not interfere with the patient chewing function or comfort, no treatment is required. If the mobility disturb the patient so it can be treated by splinting by joining the mobile tooth or teeth together with other teeth in the jaw either by using composite fillings, fixed bridges or removable partial prosthesis.

Situation IV: (progressive (increasing) mobility of a tooth (teeth) as a result of gradually increasing width of P.D.ligament in teeth with reduced height of alveolar bone).

This case seen in advanced periodontal disease, the tissue destruction may have reached a level where extraction of one or several teeth can not be avoided. Teeth that remaining in such dentition are still available for periodontal treatment may after therapy exhibit a progressively increasing mobility when force applied during function which may mechanically disrupt the remaining P.D.lig. components& cause extraction of the teeth. Treatment is only by fixed splint to stabilize the hyper mobile teeth & to replace missing teeth.

Situation V: (increased bridge mobility despite splinting)

In patient with advanced P.D. disease, the destruction of the periodontium has progressed to varying levels around different teeth & tooth surfaces in the dentition. Following proper treatment of the plaque-associated lesions, often including multiple extraction, the remaining teeth may display extreme reduction of the supporting tissues with increased tooth mobility & they may be distribued in the jaw in such away that it make it difficult or impossible to obtain proper splinting effect even by means of cross-arch bridge & the entire bridge/splint may exhibit mobility. An increased mobility of a cross-arch bridge/splint can be accepted providing that the mobility does not disturb chewing ability or comfort & the mobility of the splint is not progressively increasing.

Treatment of increased T.M can be summarized in the following table:

P.D ligament Width	Alveolar bone height	Treatment
Increased	Normal height	Occlusal adjustment
Increased	Reduced height	Occlusal adjustment
Normal width	Reduced height	Splint if mobility disturb the patient
Gradual increase in the width of P.D. lig.	Reduced height	Splint
Gradual increase in the width of P.D.lig.	Reduced height	Mobility of cross-arch splint accepted if not disturb the patient