By
Layth Kareem
Ms.c in MRI applications

Special procedures of GI tract (lec3)



Methods of imagings of GIT tract with barium water soluble contrase agents

1.Plain film
2. Barium swallow
3. Barium meal
4. Barium follow-through
5. Small bowel enema
6. Barium enema
7. Ultrasound (US):
(a) Transabdominal
(b) Endosonography
8. Computed tomography (CT)
9. Magnetic resonance imaging (MRI)
10. Angiography

Definition …

Barium swallow is the non invasive contrast procedure used in assessing the anatomy, physiology & pathology of upper GI tract including esophagus & GE junction.

Anatomy review …

The esophagus is a muscular tube that is normally 25cm long and 2-3 cm wide. The esophagus is found

anterior to the vertebral column and begin from C6 level down , following the curvature of the vertebral column.

It passes through the esophageal hiatus to end with stomach at the gastro-esophageal sphincter .

The esophagus is divided into three segments:

1. Cervical segment.
2. Thoracic segment.
3. Abdominal segment.

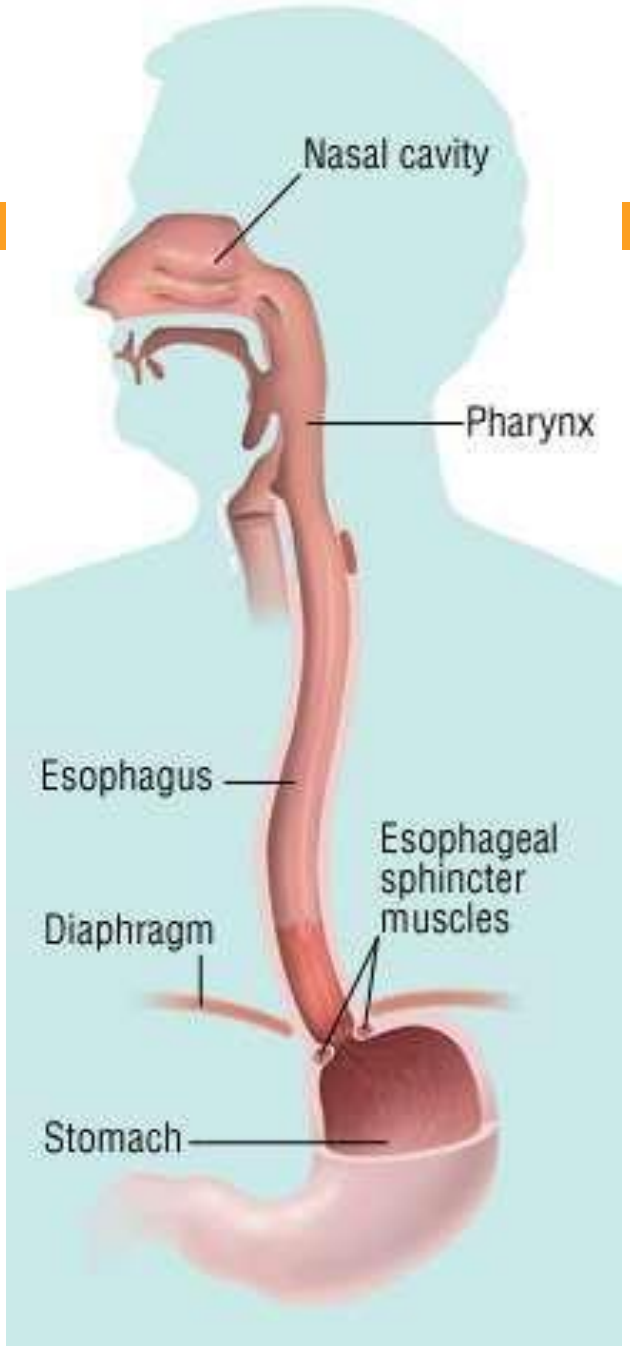
Nasal cavity
Pharynx
Esophagus
Esophageal sphincter muscles
Diaphragm
Stomach

INDICATIONS

1. Dysphagia (difficult swallowing)
2. Reflux Esophagitis
3. Stricture formation
4. Esophageal carcinoma
5. Motility disorder like Achalasia

Contraindications…

1. Suspicion of perforation
2. Suspicion of fistula (connection between esophagus and trachea) ..

In these cases we will not use barium so, LOCM contrast agents should be used instead .

Patient preparation…

- Nothing by mouth (NPO) for 6 hours prior to exam.
- Avoid smoking at the day of exam .
- Check pregnancy status for female of child bearing age.
- Procedure should be explained to the patient.

Contrast medium used …

TYPES OF STUDY :-

1. Single Contrast study (to detect any gross lesion)..

2. Double contrast study (to detect mucosal lesion)..

3. Fluoroscopic study (continuous X-ray image on a monitor, like an X-ray video recording).. for assessment of the laryngopharynx and upper esophagus during swallowing..

Technique …

- Start with the patient in the erect position,
- Ask the patient to full his mouth with contrast but not swallow it until you tell him to do so..

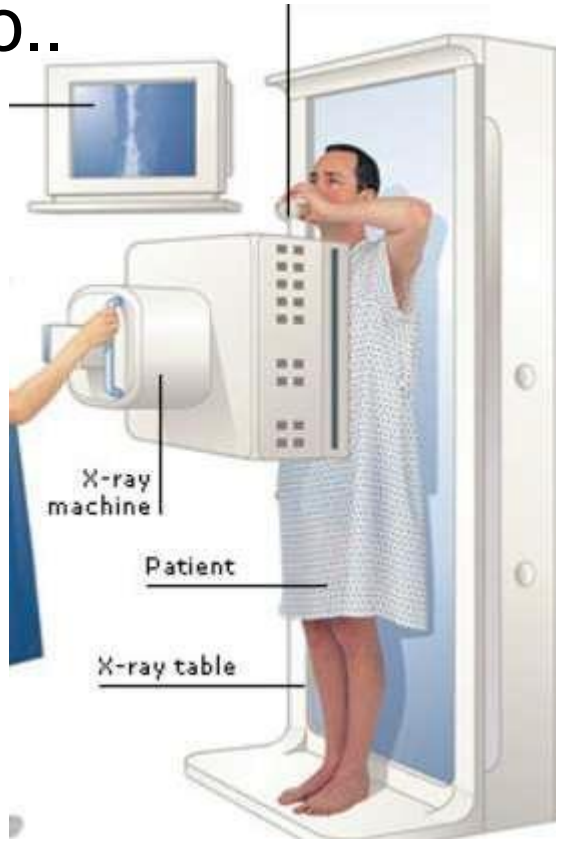

- Take frontal and lateral projections of the neck as shown ..



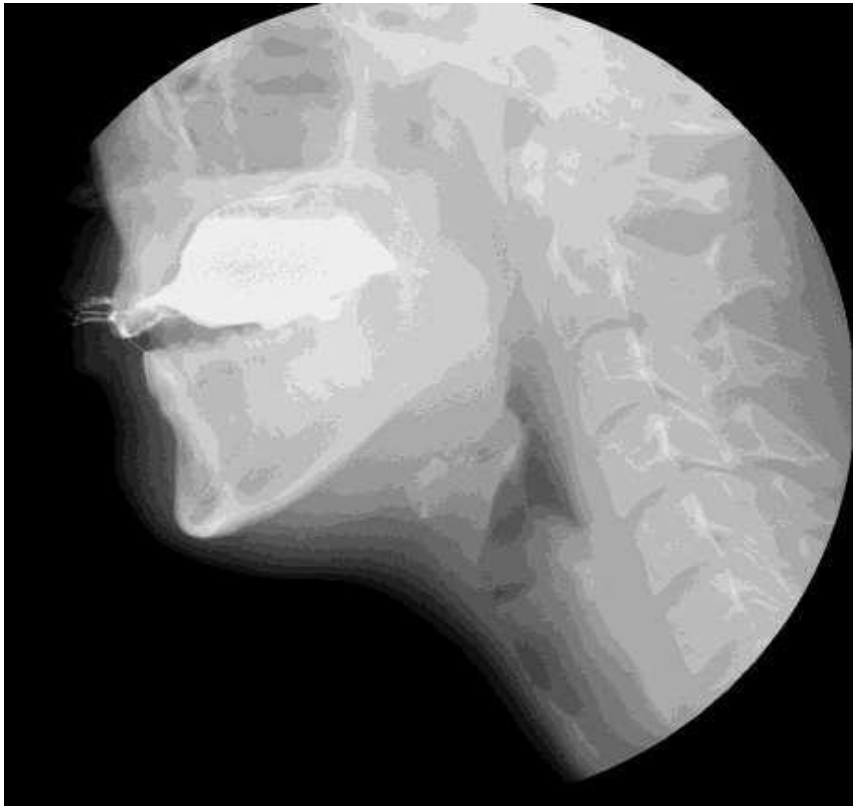

- Now position the patient in RAO , right anterior oblique, to project the esophagus clear of the spine.
- mouthful of barium is swallowed and this bolus is observed under fluoroscopy to assess the function of the esophagus. Then further mouthfuls swallowing with spot exposure(s) to include the whole esophagus distended with contrast.



RAO POSITION..

1. Aim is To throw the esophagus clear of the spine.
2. Patient should be rotated 35 – 40 degrees
3. Center of beam about 2 inches lateral to mid sagittal plane.
4. Bottom of cassette below xiphoid process ..

RAO position …

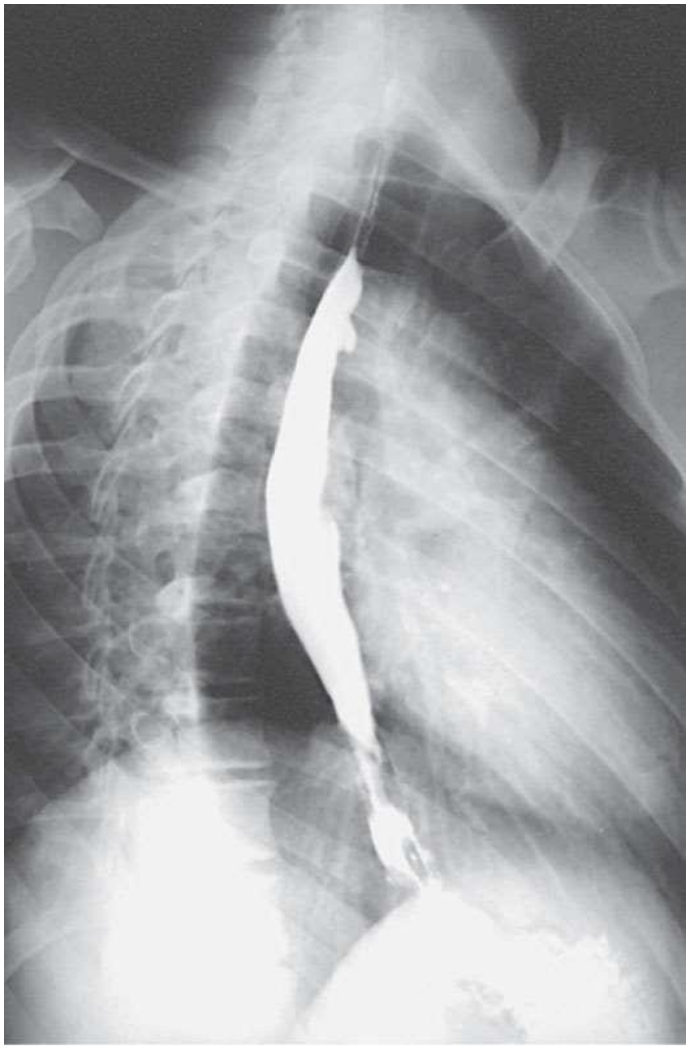

Mosby items and derived items © 2007, 2003, 1999 by Mosby, Inc., an affiliate of Elsevier Inc.

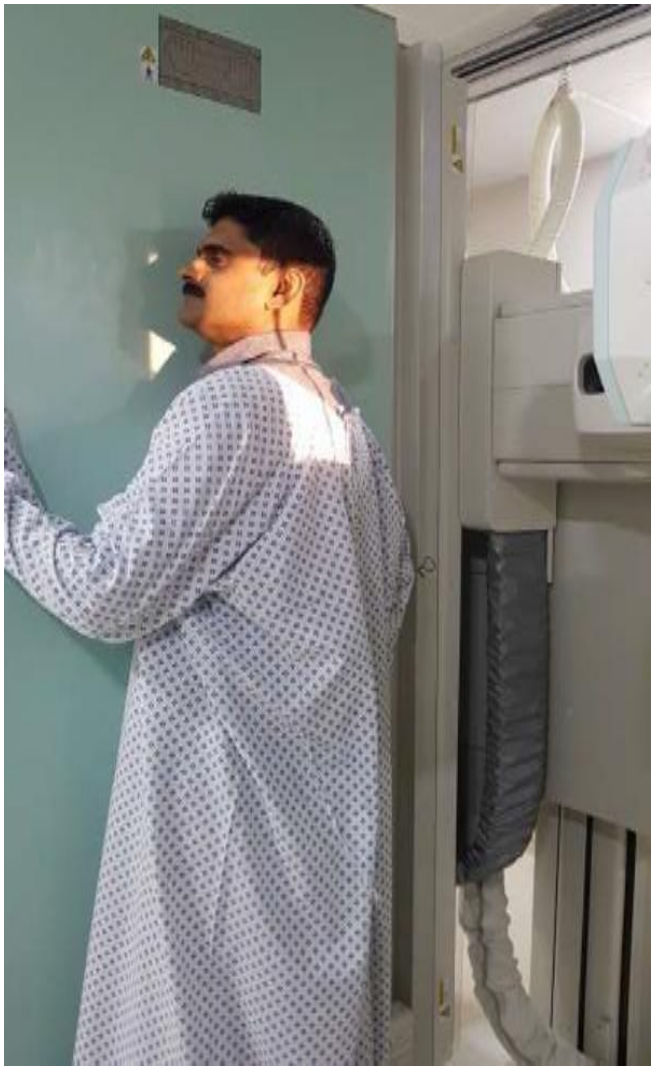

Either full length view or at least two spot films

1.Showing the upper & mid part ..

2.Showing mid & lower part ..



Barium Swallow



AP

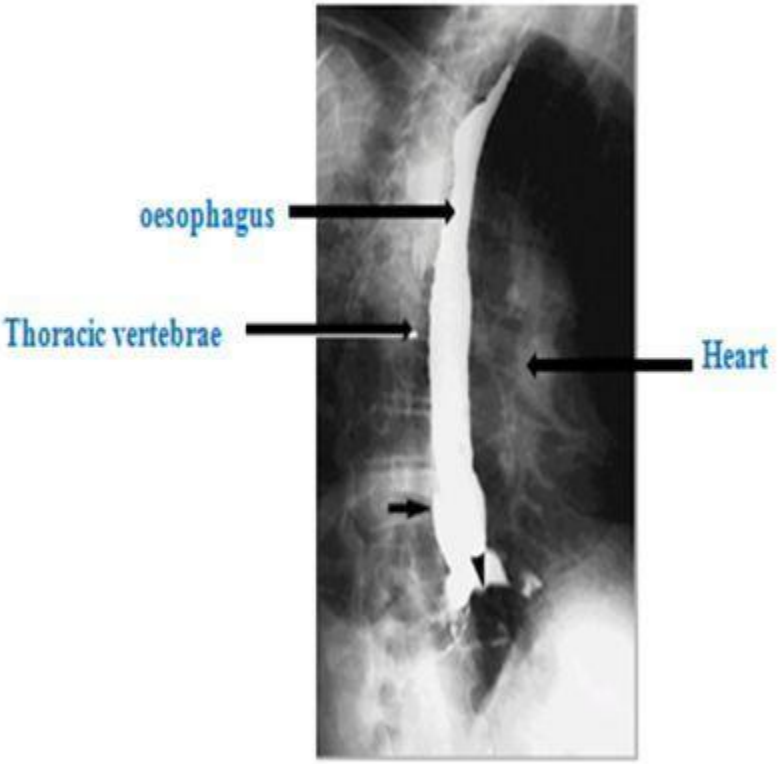

RAO

Lateral projection:-

- Place patient in lateral position.
- Center of beam midcoronal plane .
- Bottom of cassette below xiphoid process.
- Patient must drink continuously before and during exposure.

- Lateral view



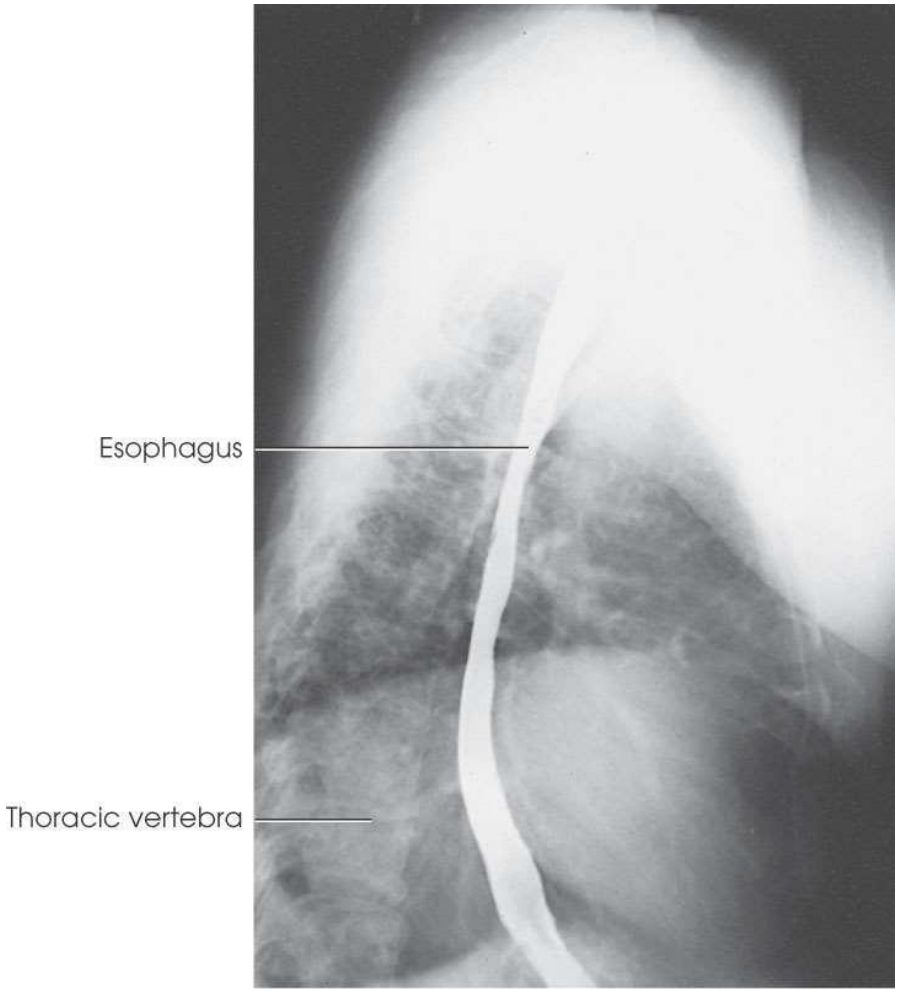

Mosby items and derived items © 2007, 2003, 1999 by Mosby, Inc., an affiliate of Elsevier Inc.

AP or PA Projection:-

- Patient supine or prone or erect .
- Center of beam midsagittal plane .
- Bottom of cassette should be placed just below tip of xiphoid..
- Patient drinks contrast before exposure and continues drinking during exposure.

- AP view



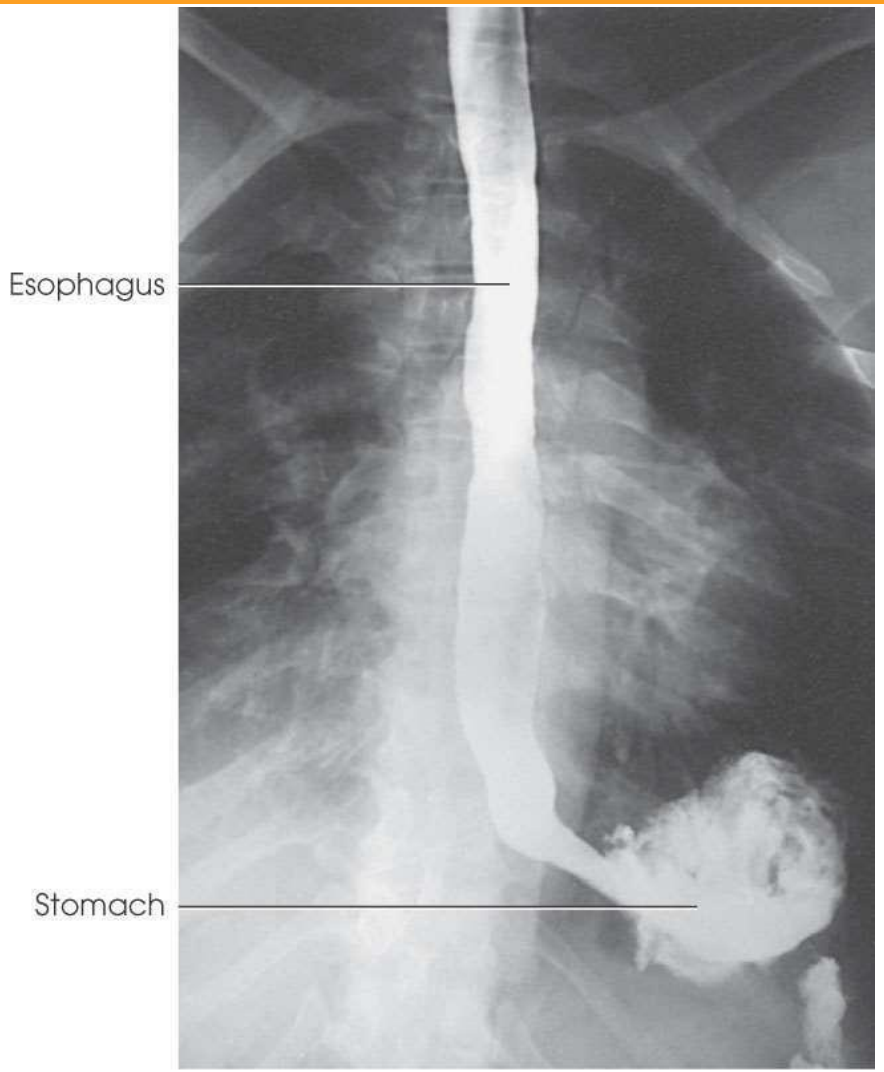

Mosby items and derived items © 2007, 2003, 1999 by Mosby, Inc., an affiliate of Elsevier Inc.

GE-sphincter assessment …

- While patient is supine turned onto the left side and then onto the back (Trendelenburg position) so that barium pools in the gastric fundus,
- GE junction is then observed fluoroscopically, looking for elicited gastro-esophageal reflux..

Trendelenburg position

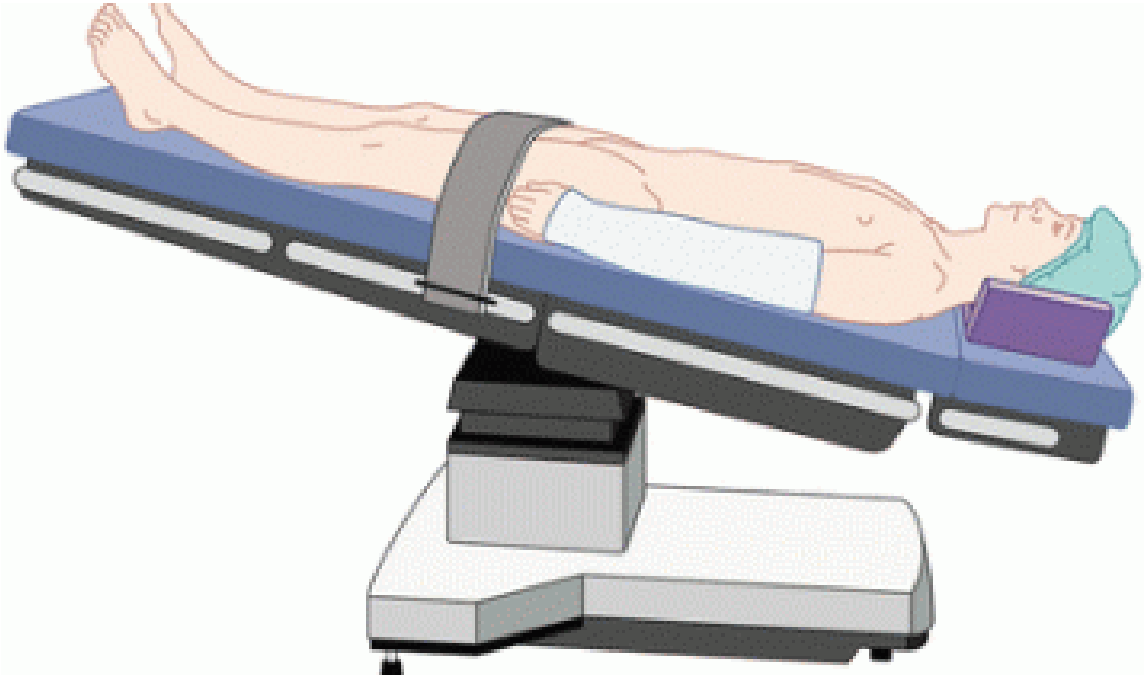

Normal vs Reflux



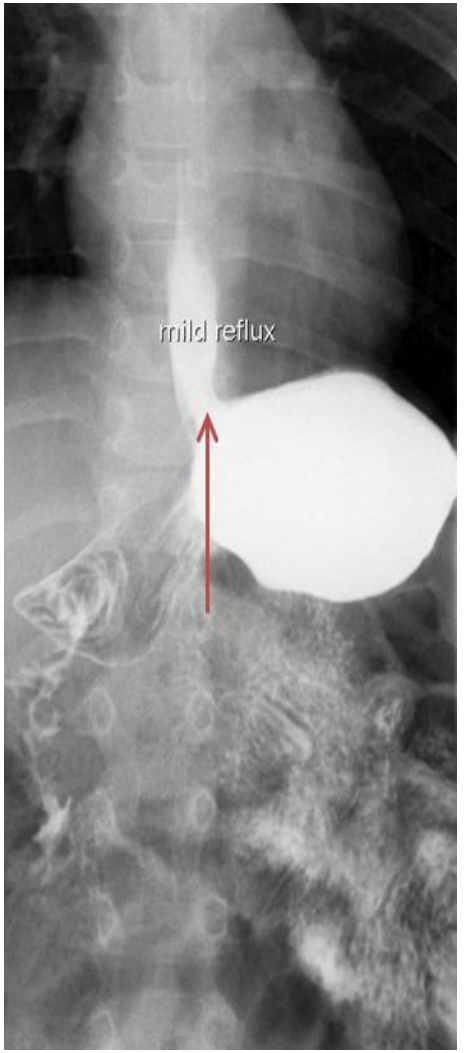

- The past procedure is single contrast study ..
- Double contrast study done by adding effervescent (air producing material) with another bolus of barium swallowed quickly ..
- So , the esophagus will be distended with

air and give better mucosal details .



Summary of views…

IMPORTANT

1) Frontal and lateral view of the neck (to assess pharynx and cervical part of esophagus).
2) Fluoroscopic video recording (to assess the motility).
3) RAO position (to get clear view of esophagus).
4) AP and lateral views .
5) Trendlenburg view (to assess GE-sphincter for reflux).
6) Single and double study done (to assess gross and mucosal lesions)…

Thank you for listening

