BARIUM MEAL …

By
Layth Kareem
Ms.c in MRI applications
Special procedures of GI tract (lec4)

Definition …

- It is a type of x-ray fluoroscopy study of gastro esophageal junction, stomach and duodenum abnormalities.

- To look for problems in the stomach and duodenum by drinking barium sulfate suspension, then X-ray series of images are taken.

Anatomy of stomach …

The stomach composed of 3 parts :-

- **Fundus** :- ballooned portion that lies lateral and superior to the cardiac orifice.
- **Body** :- which has at its lower end area of constriction -angular notch - named (incisura angularis) .
- **Pylorus** :- The smaller terminal portion of the stomach which divide into
  1. **pyloric antrum** (small dilitation distal to incisura)
  2. **pyloric canal**

Anatomy of stomach …

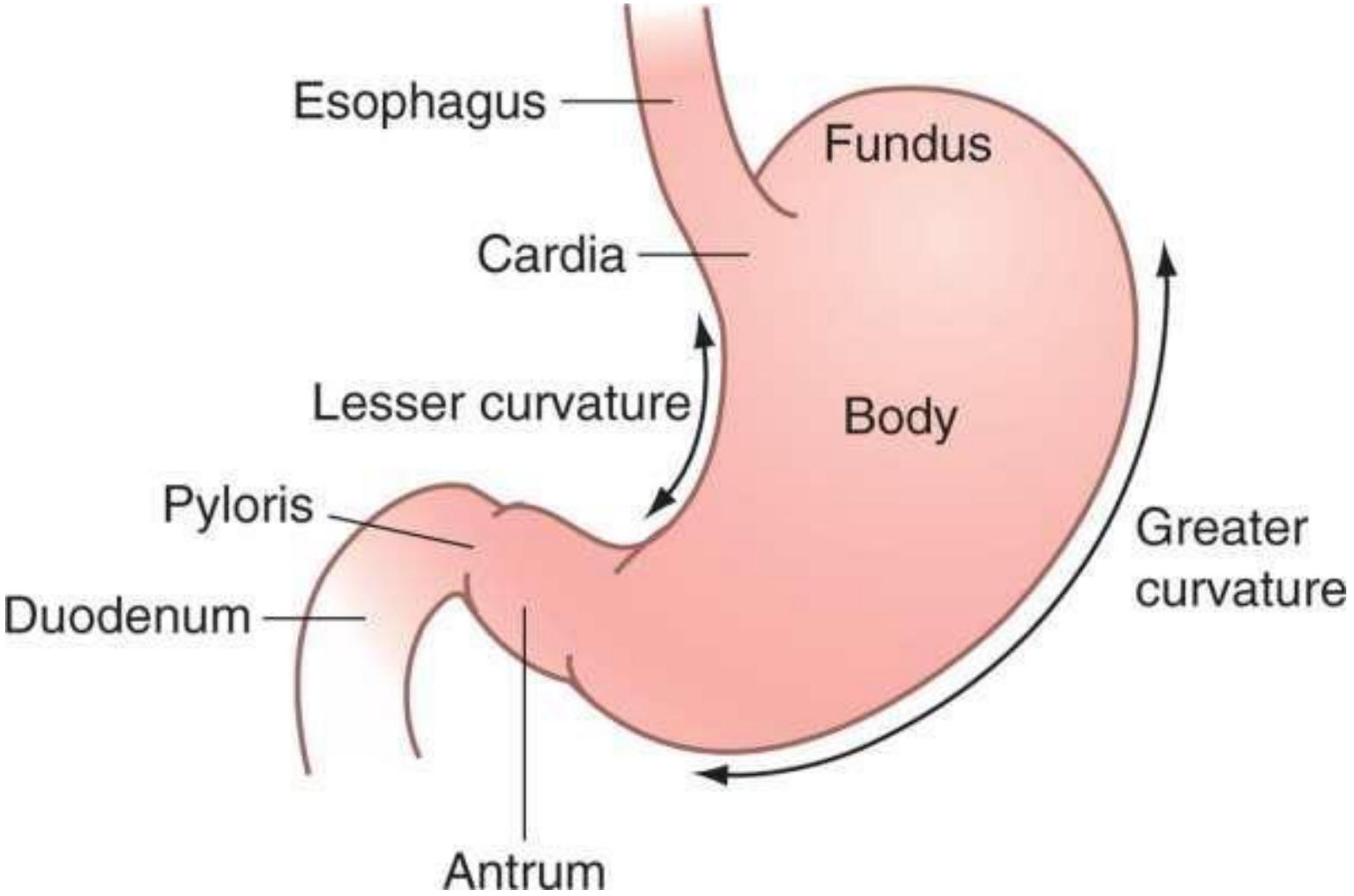

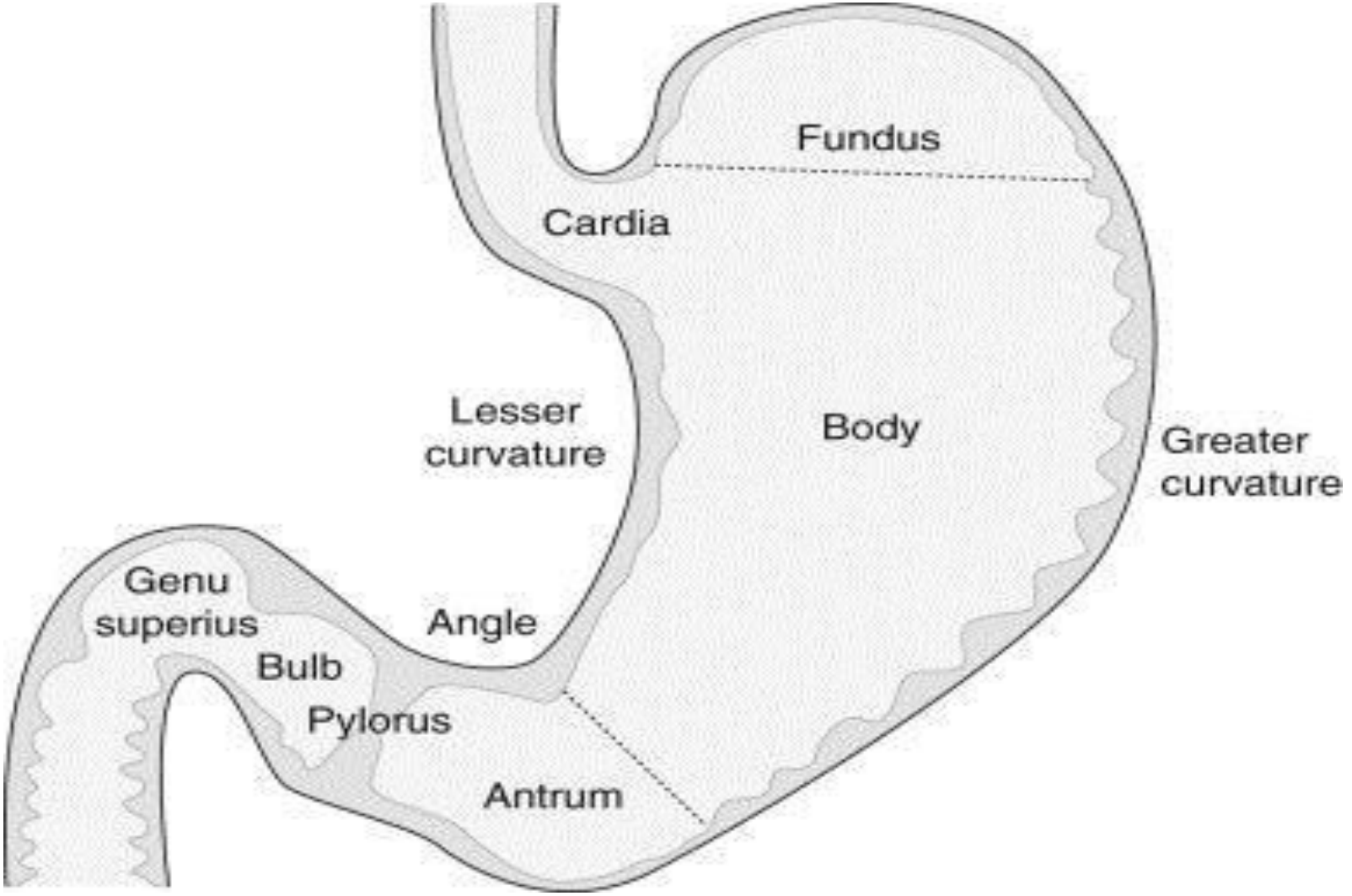
Fundus
Cardia
Lesser curvature
Body
Greater curvature
Genu superius
Angle
Bulb
Pylorus
Antrum

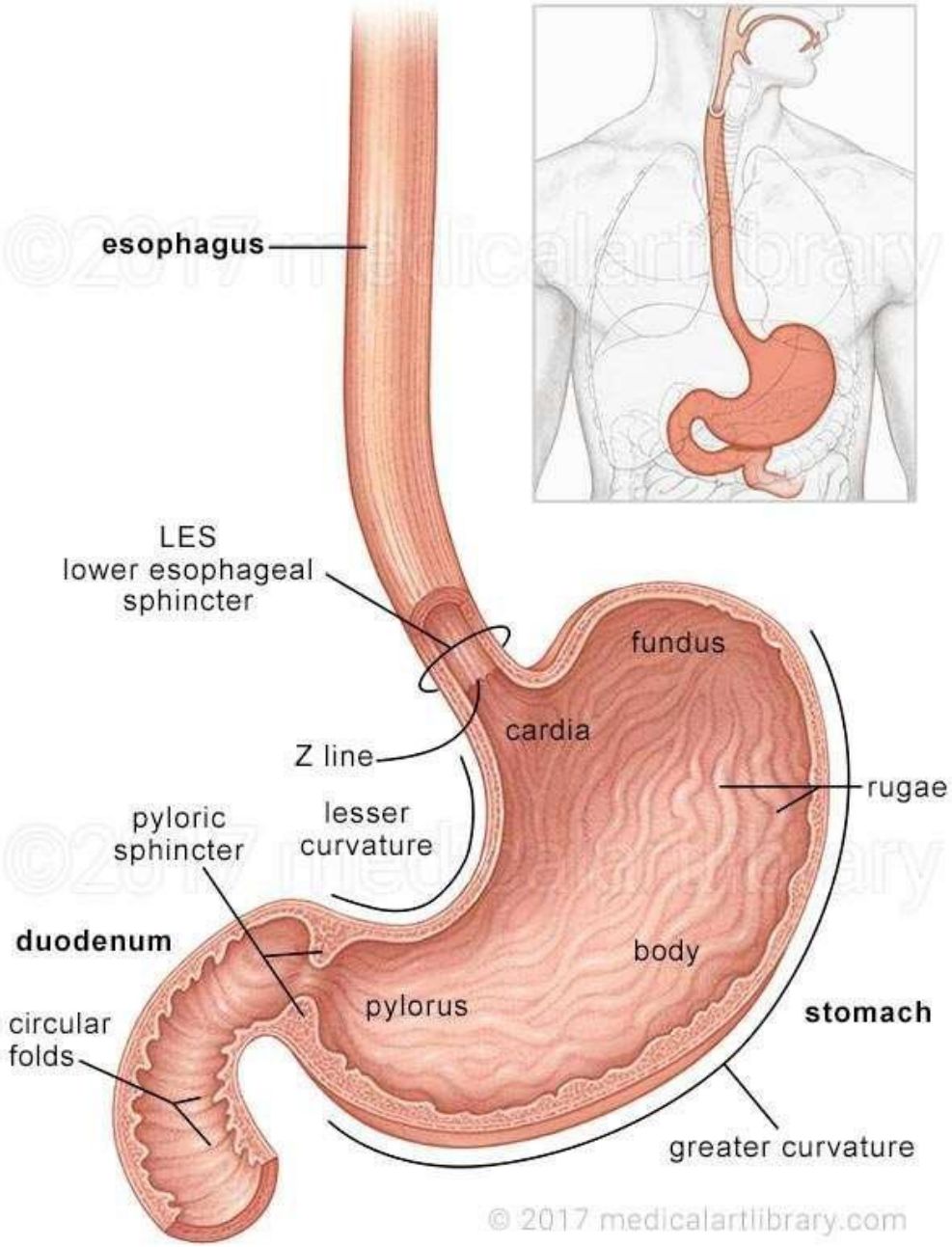
esophagus
LES
lower esophageal
sphincter
fundus
cardia
Z line
rugae
pyloric
sphincter
lesser
curvature
duodenum
body
pylorus
stomach
circular
folds
greater curvature
© 2017 medicalartlibrary.com

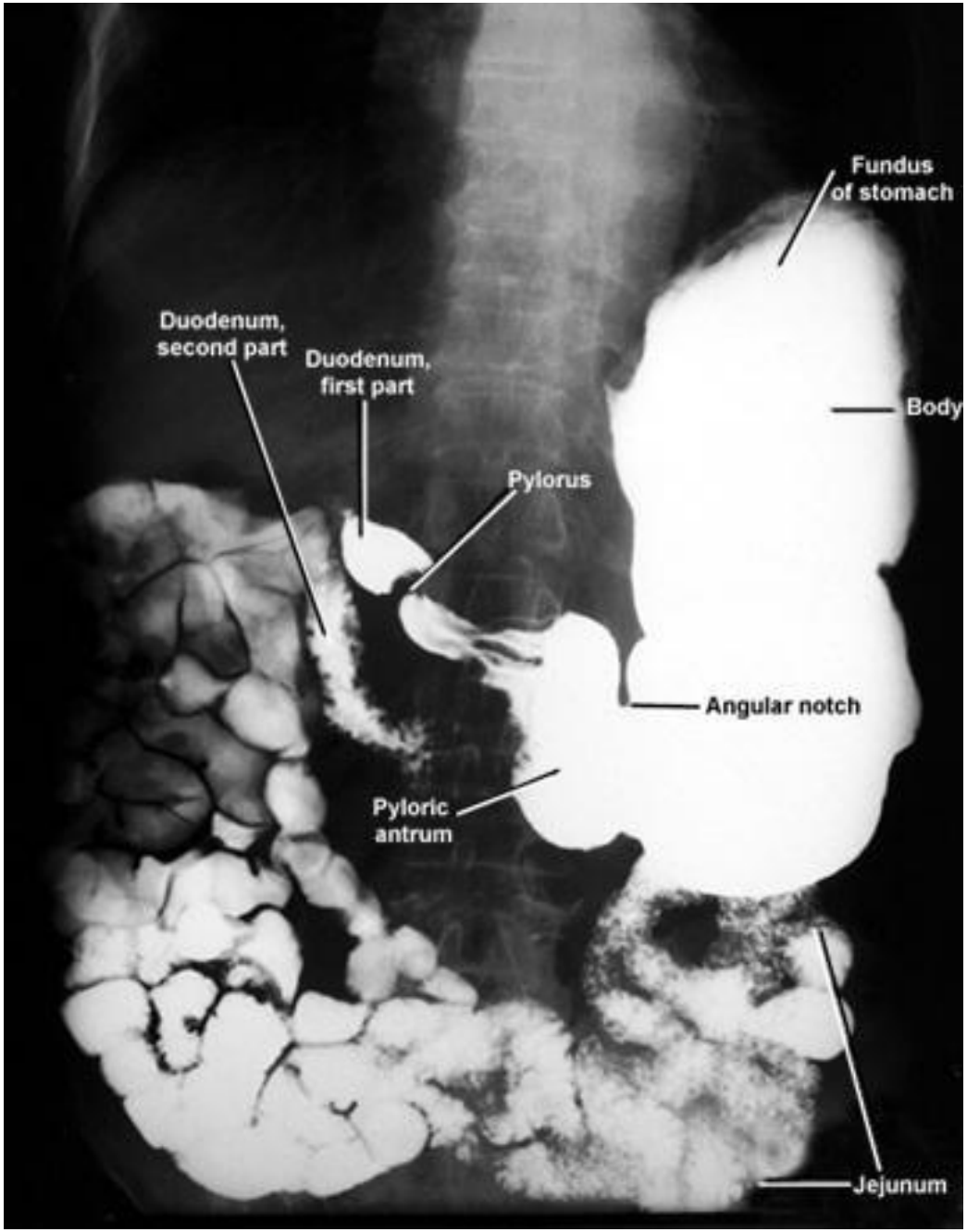
Fundus
of stomach
Duodenum,
second part
Duodenum,
first part
Body
Pylorus
Angular notch
Pyloric
antrum
Jejunum

Anatomy of duodenum …

The duodenum is shaped like the letter “C” and consists of 4 parts :-

1st part :- named duodenal bulb or cap (common site for ulcers)

2nd part :- descending part and the longest part which contain the openings of common bile duct and pancreatic duct

3rd part ;- the horizontal portion

4th part :- the ascending part that will join the jeujunum

Anatomy of duodenum …

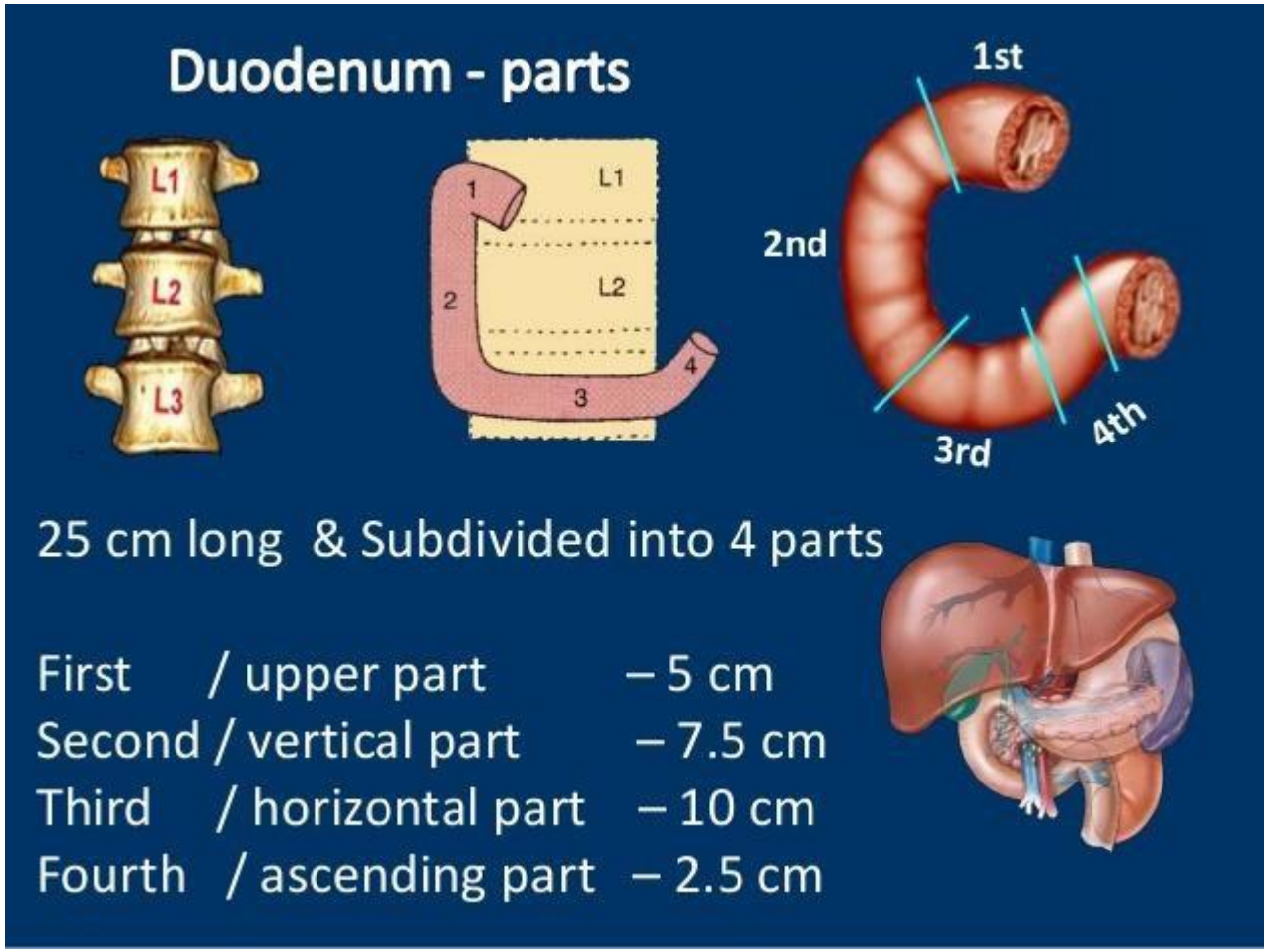

Duodenum

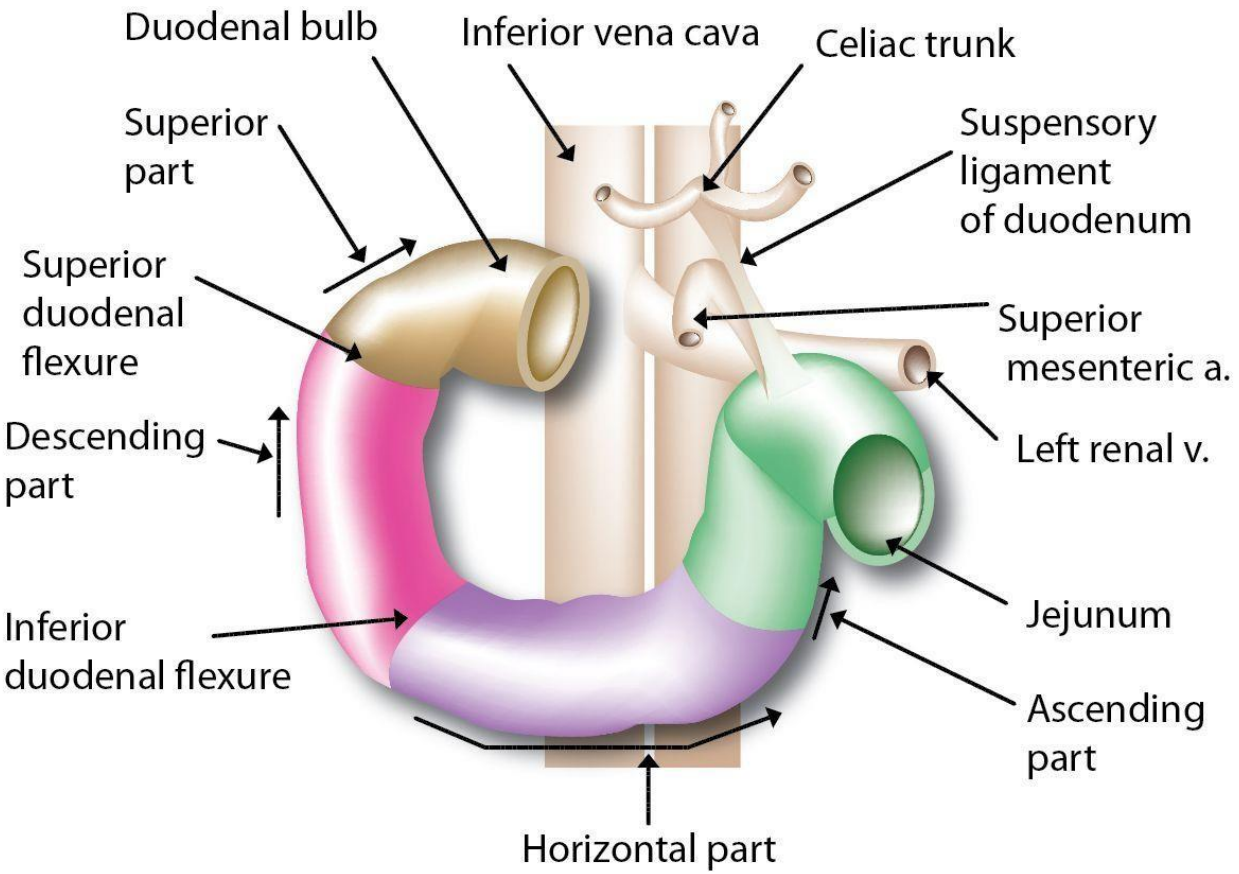

HELP
Health Education Library for People
©2013 www.healthlibrary.com

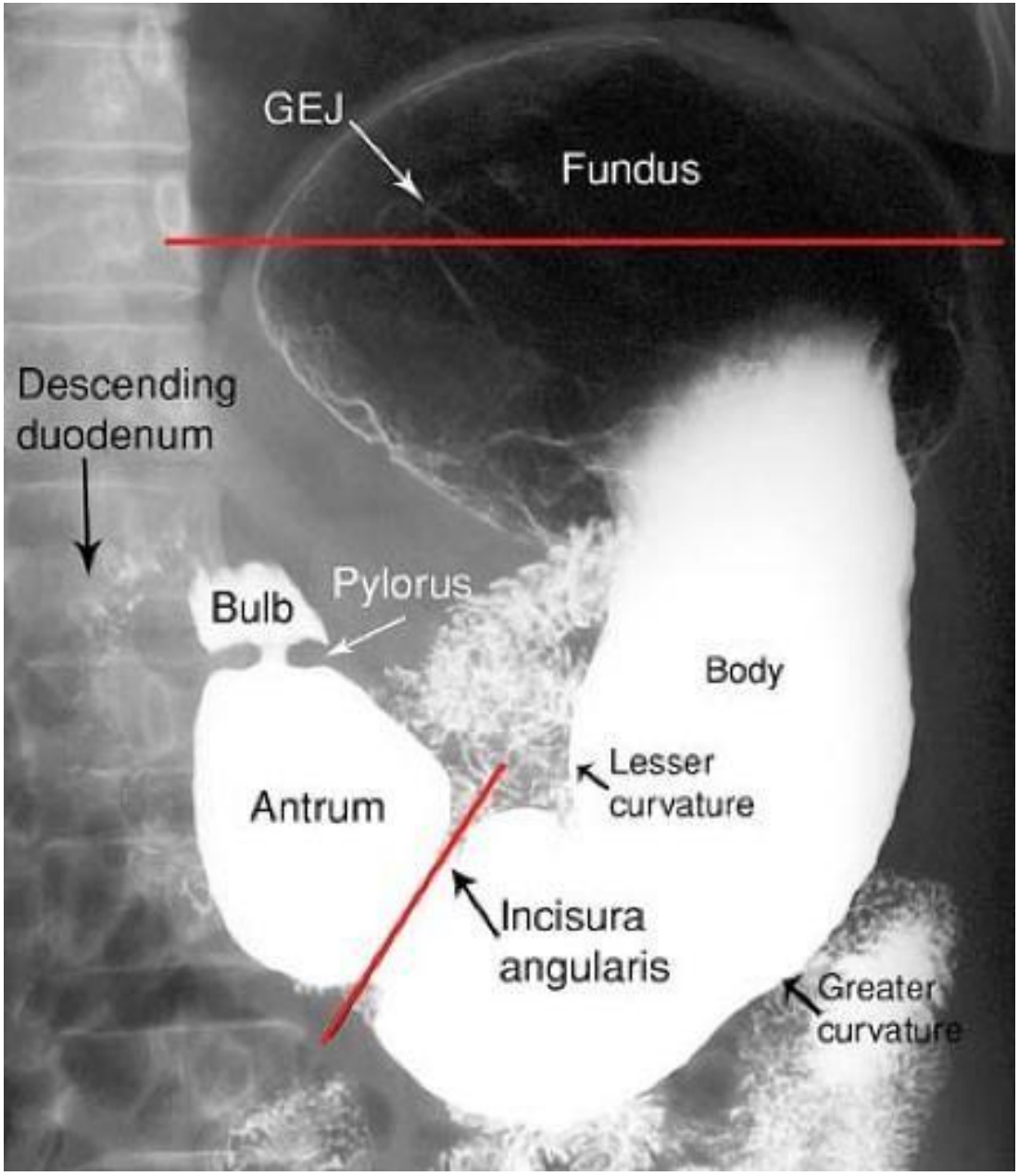
GEJ
Fundus
Descending duodenum
Bulb
Pylorus
Body
Lesser curvature
Antrum
Incisura angularis
Greater curvature

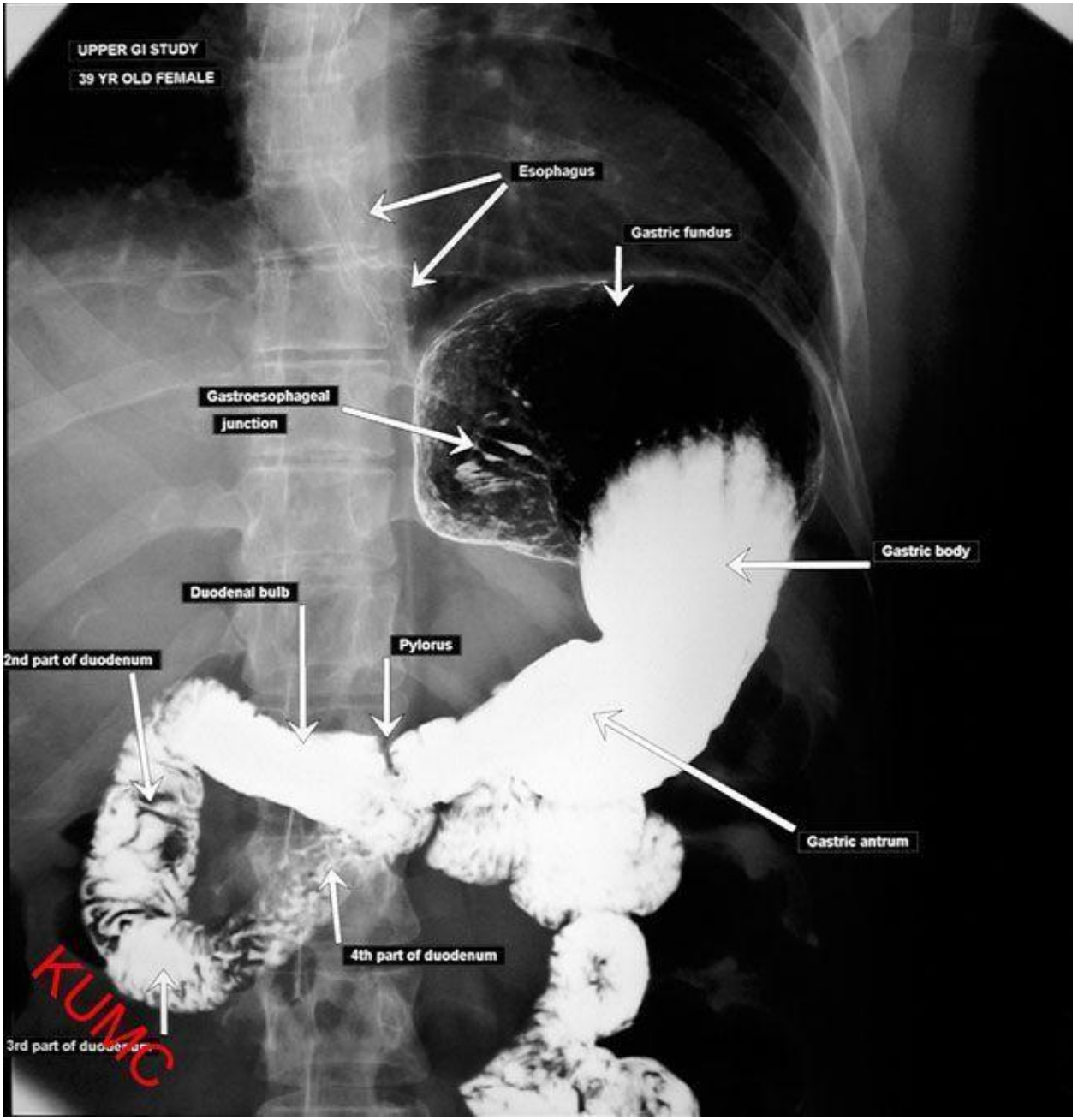
UPPER GI STUDY
39 YR OLD FEMALE
Esophagus
Gastric fundus
Gastroesophageal
junction
Gastric body
Duodenal bulb
Pylorus
2nd part of duodenum
Gastric antrum
4th part of duodenum
KUMC

Indications…

1. Epigastric pain suggestive of peptic ulceration
2. patient unwilling to undergo endoscopy
3. Dyspepsia (indigestion)
4. Unexplained Weight loss(suspicion of CA)
5. Gastrointestinal hemorrhage
6. Partial gastric or duodenal obstruction

CONTRAINDICATIONS…

1. **Complete bowel obstruction**
2. **Suspected perforation**

(it is essential that a water soluble contrast medium, e.g. **Gastrografin or LOCM**, **is used instead of barium in case of suspected bowel perforation)…**

Types of barium meal …

- **SINGLE contrast :-** Using low concentration (100 % w/v) BIG amount of BARIUM suspension **alone** to fill the stomach and duodenum

- **DOUBLE contrast :-** Using high concentration (250 % w/v) SMALL amount of BARIUM suspension **with AIR** to coat the wall of stomach and duodenum

NORMAL BARIUM MEAL

Single contrast



Double contrast

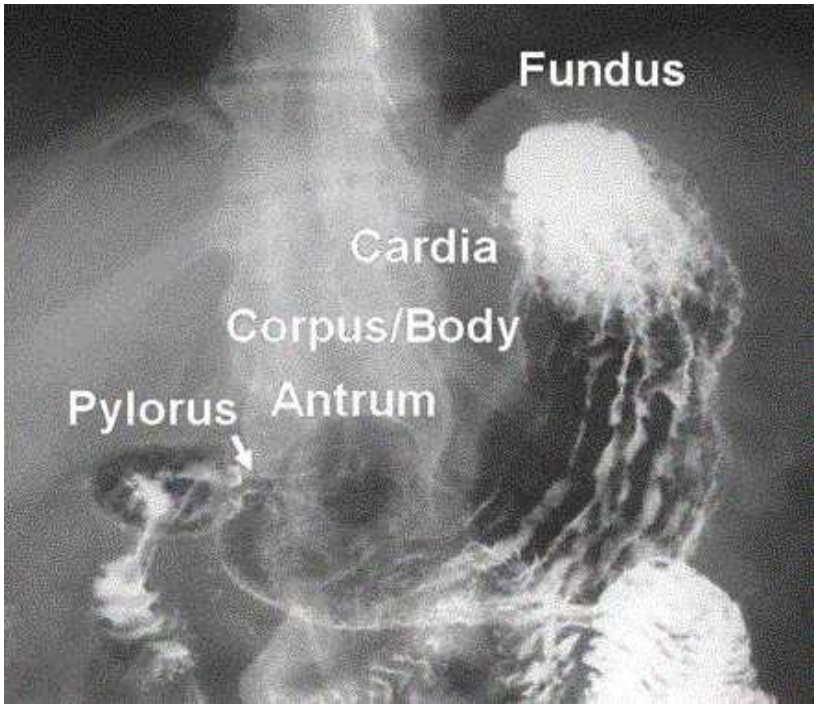

Patient preparation …

1. Patient should not eat or drink for at least 6 hours before examination.

2. As cigarette smoking may interfere with optimum coating of the mucosa, patients should restrain from smoking.

	1	2	3	4
Film	RAO	Supine	LAO	Left lateral tilted head up
Position				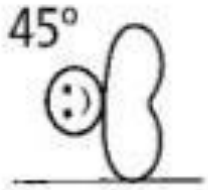
Image				
Demonstrates	Antrum + greater curve	Antrum + body	Lesser curve en face	Fundus

1. Spot exposures of the stomach (lying):

(a) RAO – to demonstrate the antrum and greater curve

(b) Supine – to demonstrate the antrum and body.

(c) LAO – to demonstrate the lesser curve.

(d) Left lateral tilted, – to demonstrate the fundus.

From the left lateral position the patient returns to a supine position and then rolls onto the left side and over into **a prone position**.

This sequence of movements is required to avoid barium flooding into the duodenal loop,

which would occur if the patient were to roll onto the right side to achieve a prone position.

- **The duodenal cap or duodenal ampulla**

is the very first part of the duodenum which is slightly dilated.

is about 2 cm long.



Prone position

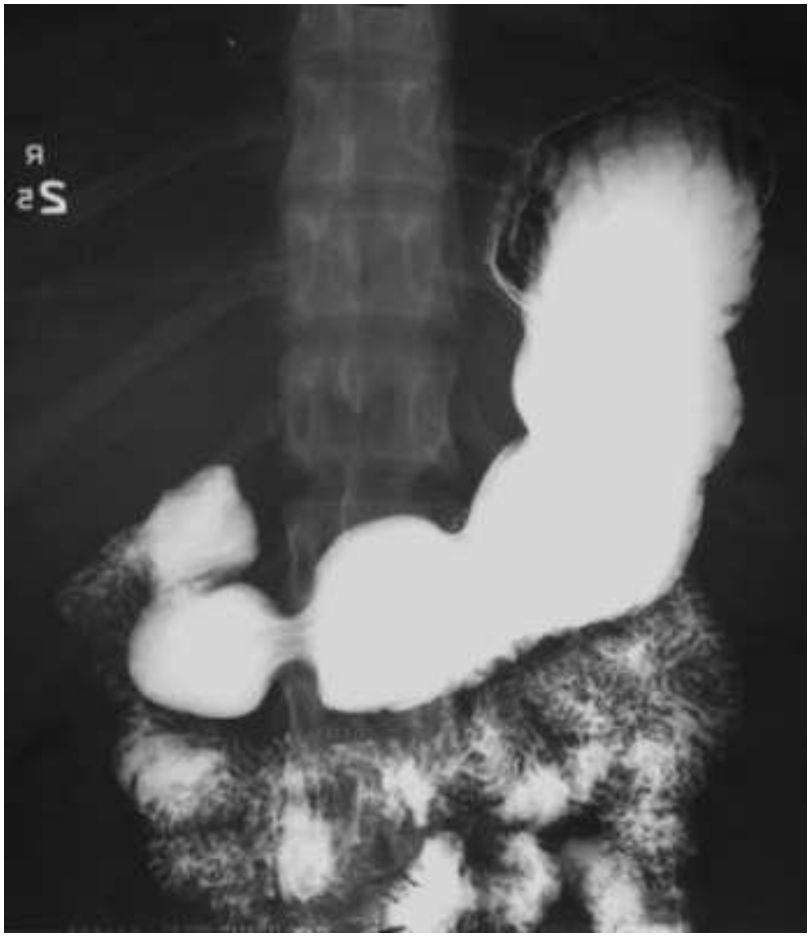

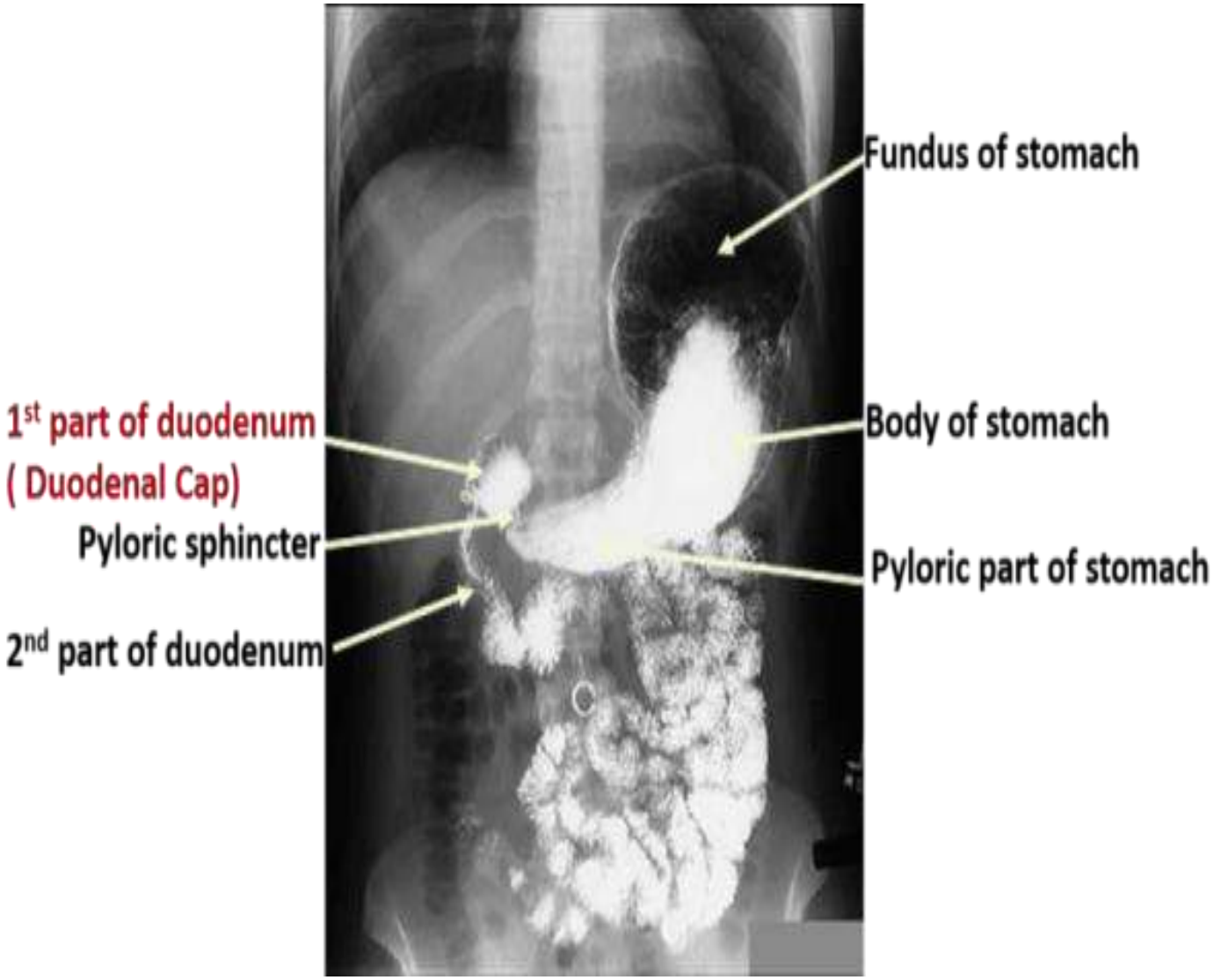
Fundus of stomach
1st part of duodenum
(Duodenal Cap)
Body of stomach
Pyloric sphincter
Pyloric part of stomach
2nd part of duodenum

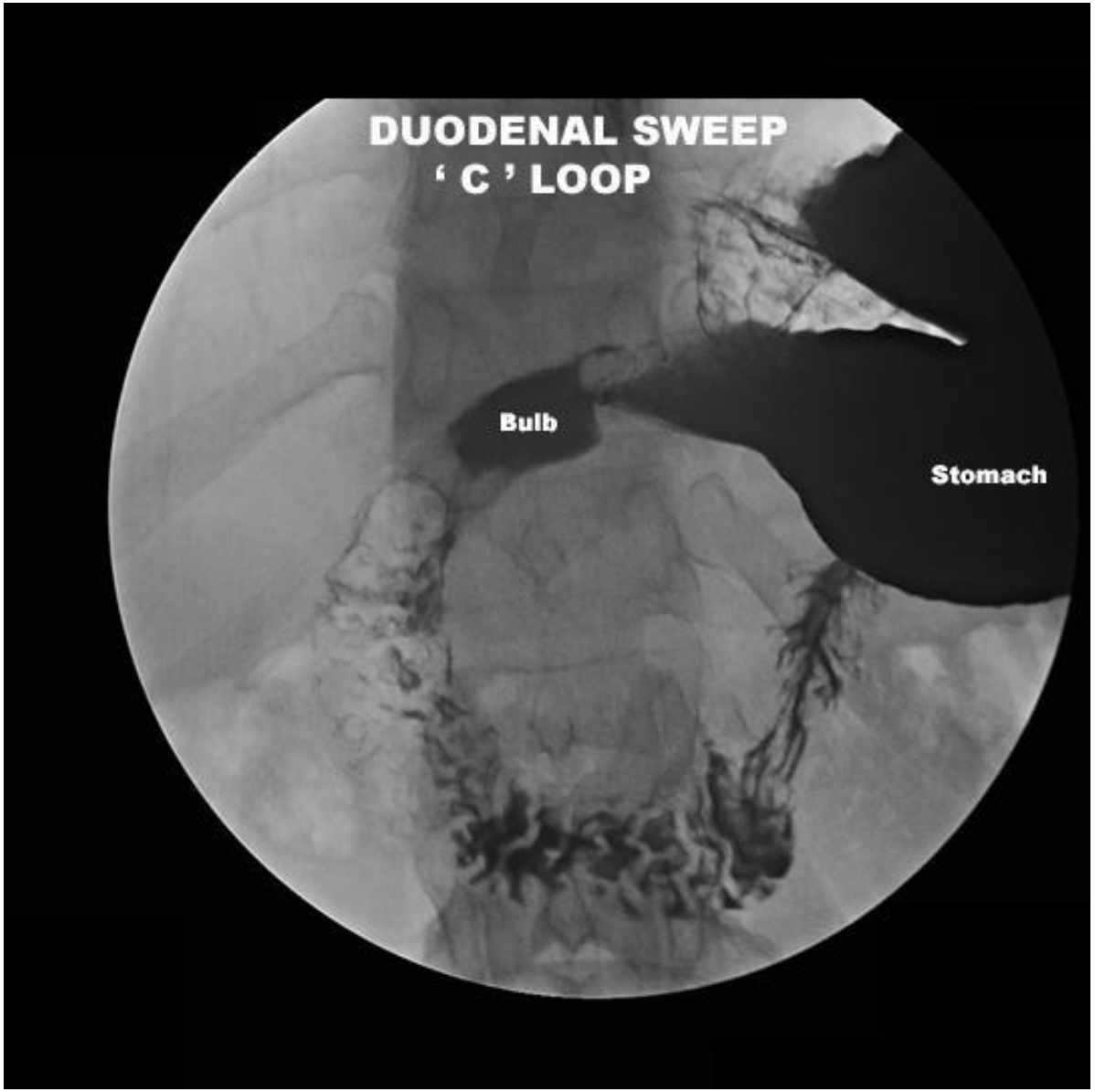
DUODENAL SWEEP
' C ' LOOP
Bulb
Stomach

Duodenal C loop

- **Because it likes the letter C**
- **Mainly formed by second part of duodenum**

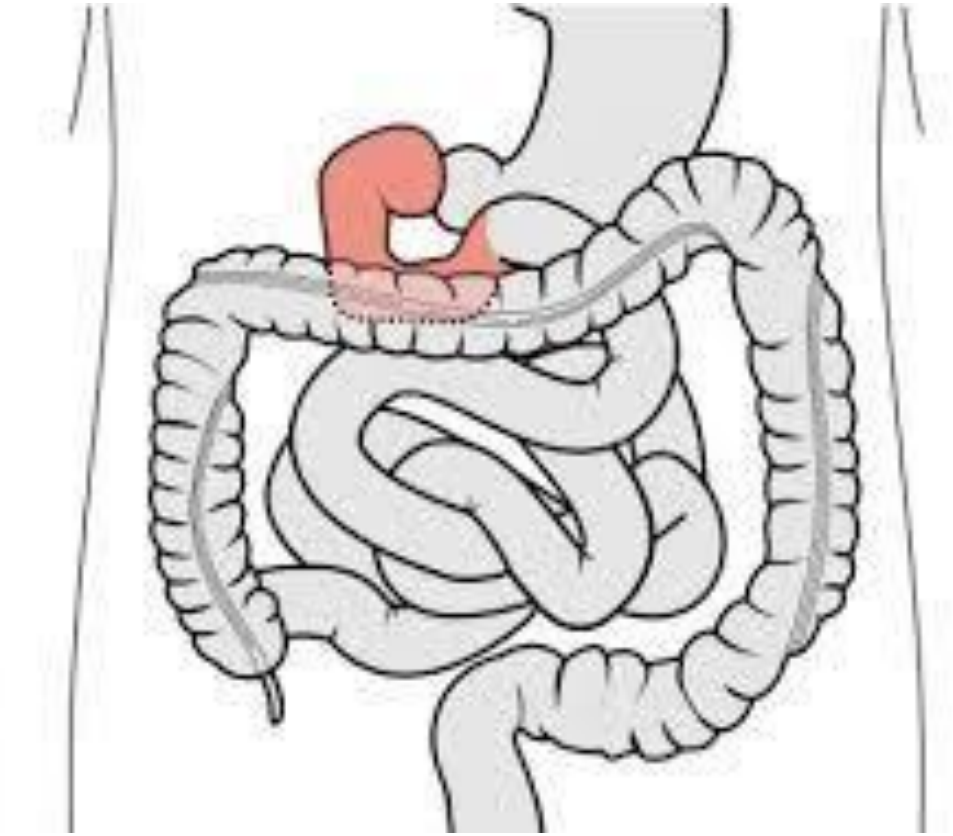

SINGLE CONTRAST STUDY

- In erect position
- 10-15 ml of 100% w/v barium suspension is given and patient is made to swallow while esophagus is seen under fluoroscopy.
- table is made horizontal, and the patient lying supine is rotated with the right side going up (RAO)
- Spot films of the filled fundus

Disadvantages of single contrast study

- Lack of sensitivity in detecting small erosion/linear ulceration, superficial gastric carcinomas and subtle mucosal abnormalities

Complications

1. **Leakage of barium from an unsuspected perforation**
2. **Aspiration**
3. **Conversion of a partial large bowel obstruction into a complete obstruction by the impaction of barium**
4. **Barium appendicitis, if barium impacts in the appendix (exceedingly rare)**
5. **Side effects of the pharmacological agents used.**

After care …

1. Patient should be told that the bowel motion will be white for few days
2. Patient should be advised to drink adequate water
3. Patient should not leave the department until blurring of vision has resolved (if Buscopan was given)

Pathological examples

Gastric ulcer

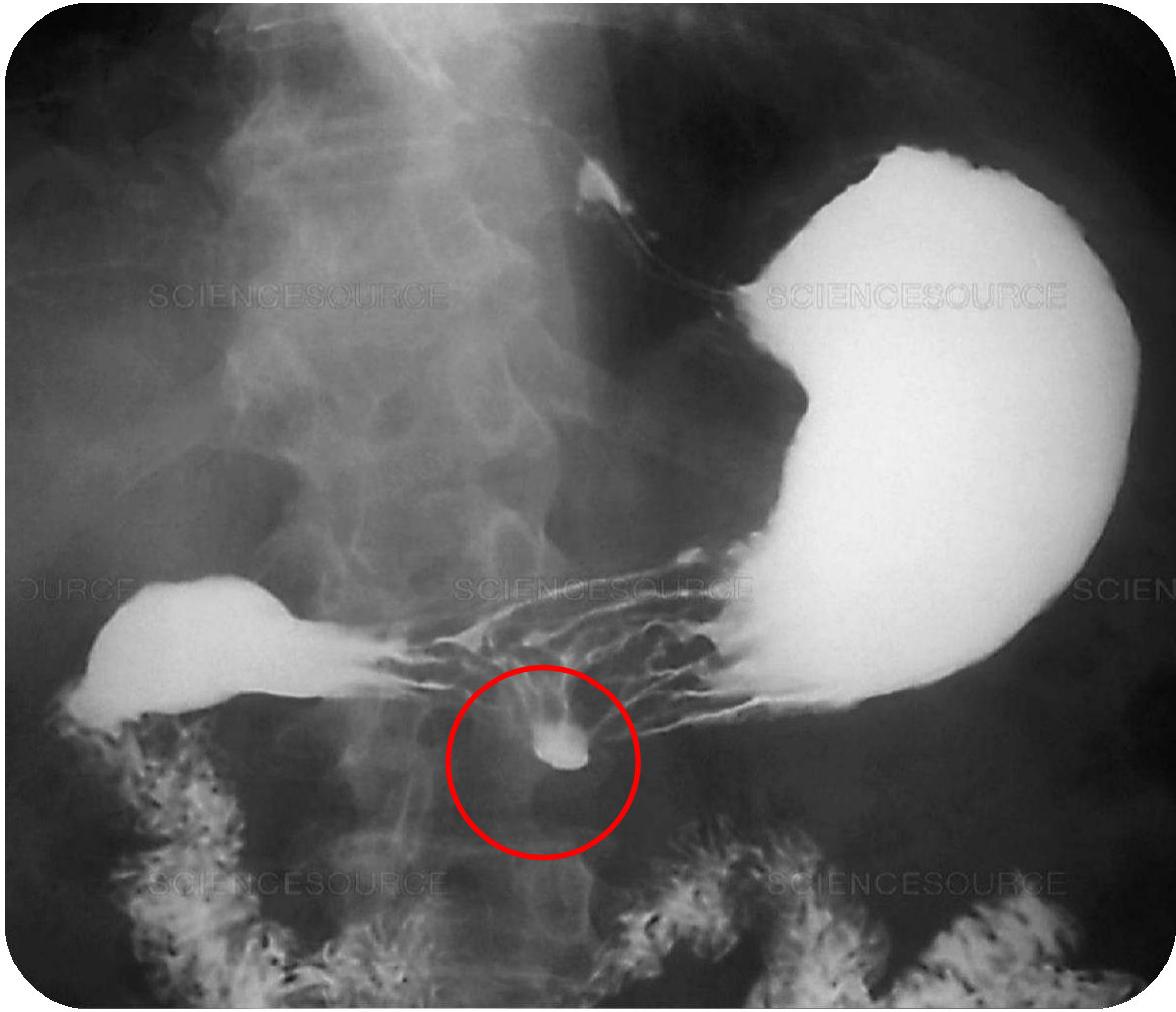

Pyloric stenosis

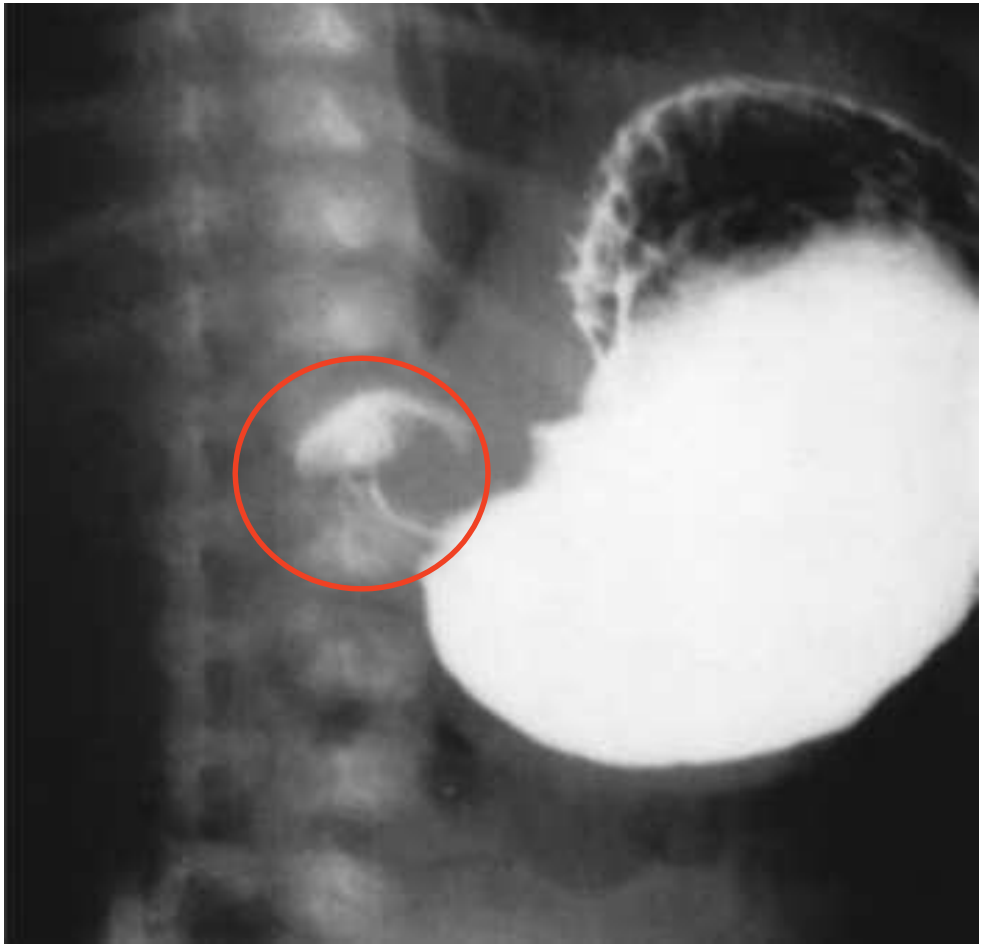

DR. TAMARA MUAYAD ABDULLAH

Thank you