BARIUM FOLLOW THROUGH

By Layth Kareem
Ms.c in MRI applications
Special procedures of GI tract (6)

Definition of ...

Follow through means **continuity** so, it is a continuation of Barium meal examination ..

Defined as that technique that uses a form of real-time x-ray called **fluoroscopy** and a barium-based contrast material to produce images of the small intestine. It is safe, noninvasive and used to help accurately diagnose bowel disease.

Indications …

1. Pain
2. Diarrhea
3. GIT bleeding
4. Partial obstruction
5. Malabsorption

Contraindications …

- Complete bowel obstruction

(better to use CT-Scan of the abdomen for evaluation)…

- Suspicion of bowel perforation

(better to use water soluble contrast media instead of barium)…

Rapid anatomical review …

The small intestine (small bowel) lies between the stomach and the large intestine (large bowel) 4-6 meters long at center of abdomen and includes three parts :-

1. Duodenum
2. Jejunum
3. Ileum

The small intestine is so called because its lumen diameter is smaller than that of the large intestine, although it is longer in length than the large intestine.

- **Duodenum** : has 4 parts: superior, descending, horizontal, and ascending.

- **Jejunum** about two fifths of the proximal small intestine with No clear demarcation is noted between the jejunum and ileum; however, there are some features which distinguish the jejunum from the ileum. The jejunum has a thicker wall and a wider lumen than the ileum and mainly occupies the left upper and central abdomen

Ileum

The ileum constitutes about three fifths of the distal small intestine

The ileum has a thinner wall and a smaller lumen than the jejunum and mainly occupies the central and right lower abdomen and pelvis

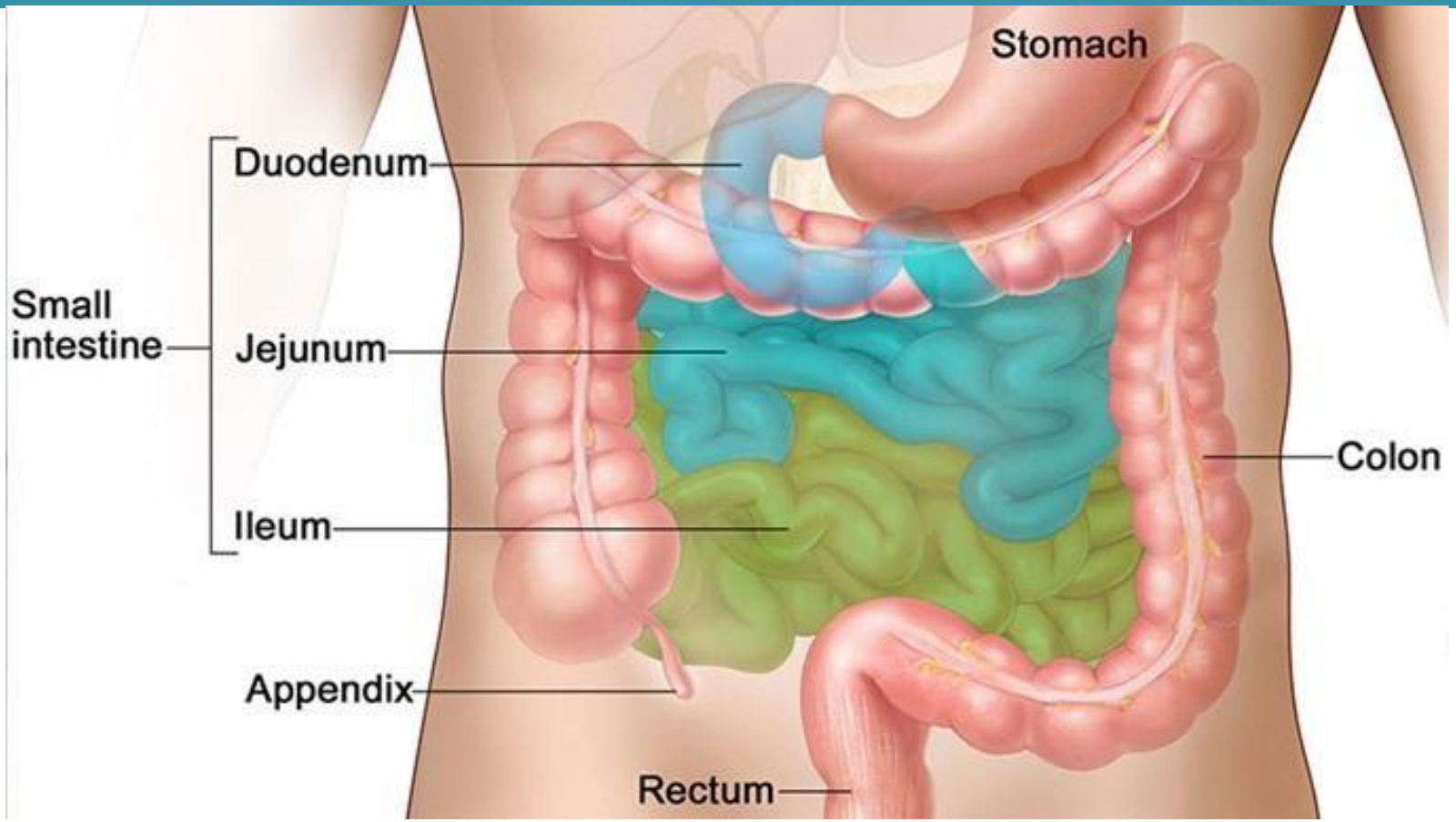
Stomach
Duodenum
Small intestine
Jejunum
Ileum
Colon
Appendix
Rectum

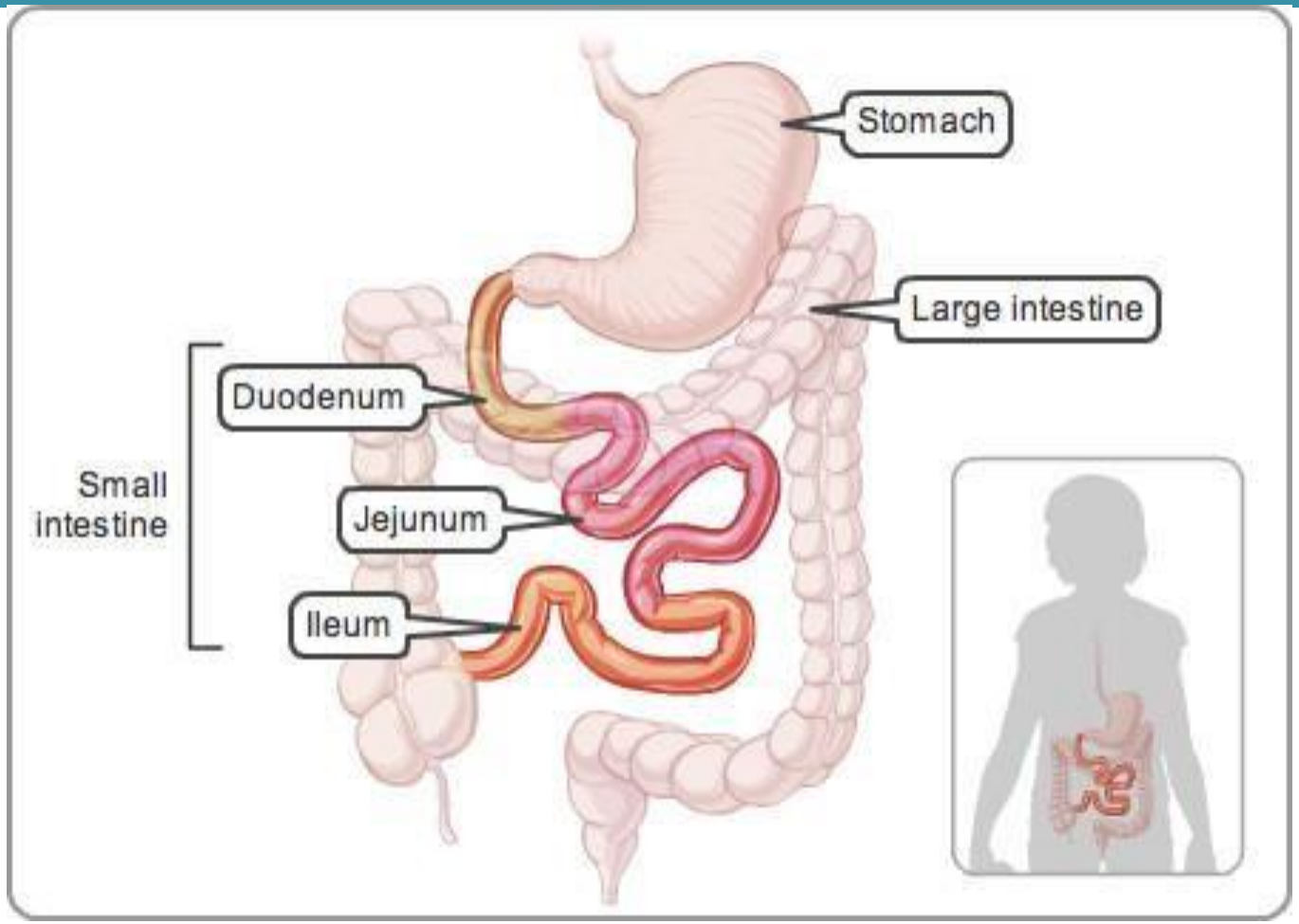
Stomach
Large intestine
Duodenum
Small intestine
Jejunum
Ileum

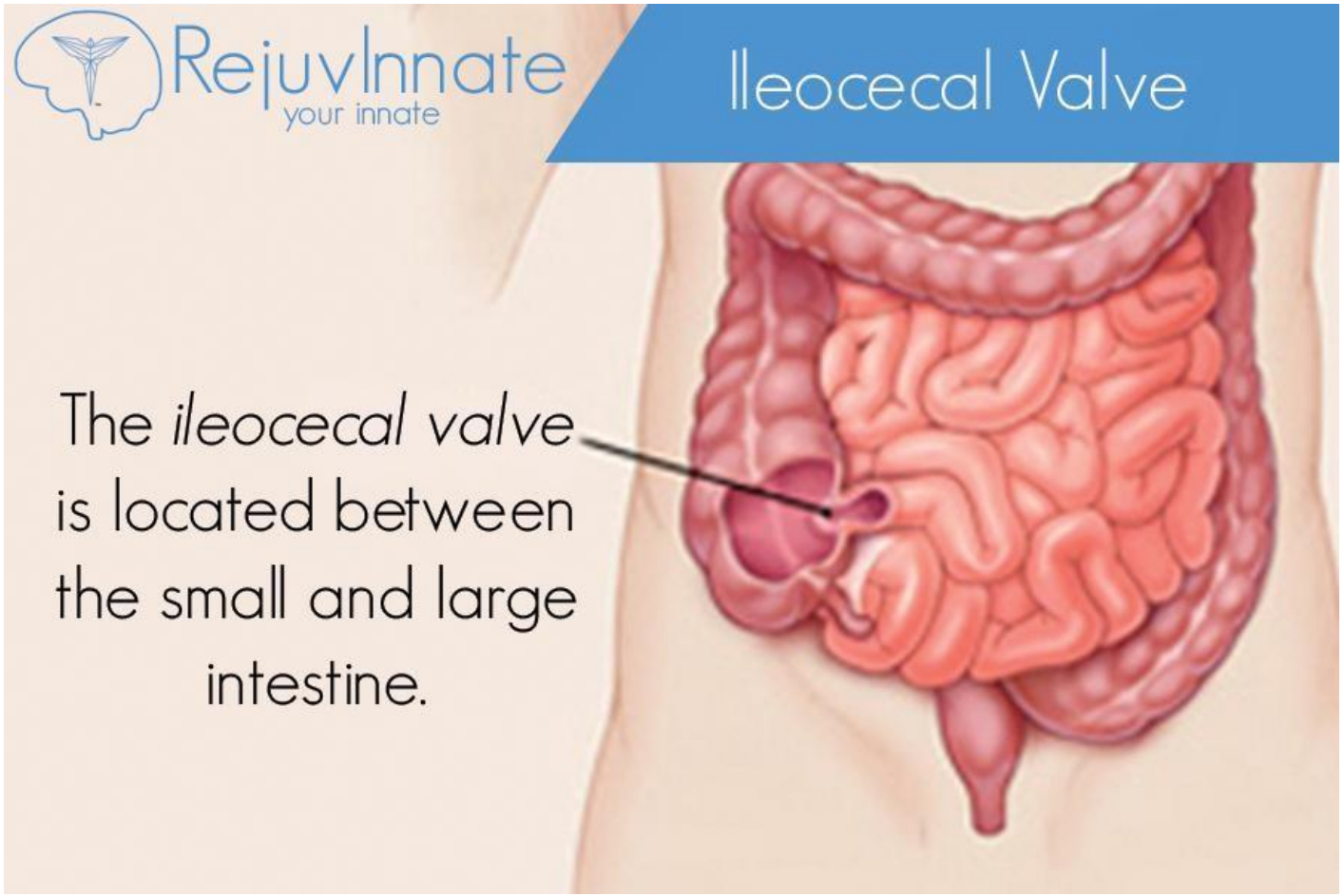
RejuvInnate
your innate
Ileocecal Valve
The *ileocecal valve* is located between the small and large intestine.

Patient preparation …

1. The colon should be cleaned by the administration of a suitable purgative. (Purgative should be avoided in patients with suspected obstruction).

2. A roughage diet and a high fluid intake is also maintained for 48 hours prior to the investigation

3. No food or fluid should be taken for 12 hours before the investigation.

Technique …

- **If the procedure is a continuation of barium meal** (the patient already have Barium) so, 300 ml of high density 1

- **If the procedure is dedicated Small Bowel Follow Through** .(the patient didn't have Barium yet) so, 600-900 ml of medium density 60 % w/v given
- The aim is to deliver a single continuous column of barium into the small bowel.

- Patient is asked to drink this as rapidly as possible. then put the patient in the right side dependent position (to aid rapid gastric emptying from stomach to duodenum and so on).

- After 15 to 20 minutes, a **PA film** is taken with the patient prone (to separate the bowel loops due to compression on abdomen during prone position).
- With high centering including the diaphragm and proximal small bowel ..

- Then every 30 minutes (for the first 2 hours) films taken until the barium sulfate column passes through the ileocecal junction and progresses into the ascending colon

- If 2 hours passed and barium not reached the ascending colon so images taken every 1 hour interval .

- To demonstrate ileocaecal junction, supine right side up is the best position since ileum enters caecum in the posteromedial part

Summary …

	Positioning	Purpse
First	Right side dependant	To Increase gastric emptying
Second	Prone	To Separate bowel loops
Third	Supine right side up	To visualize IC junction

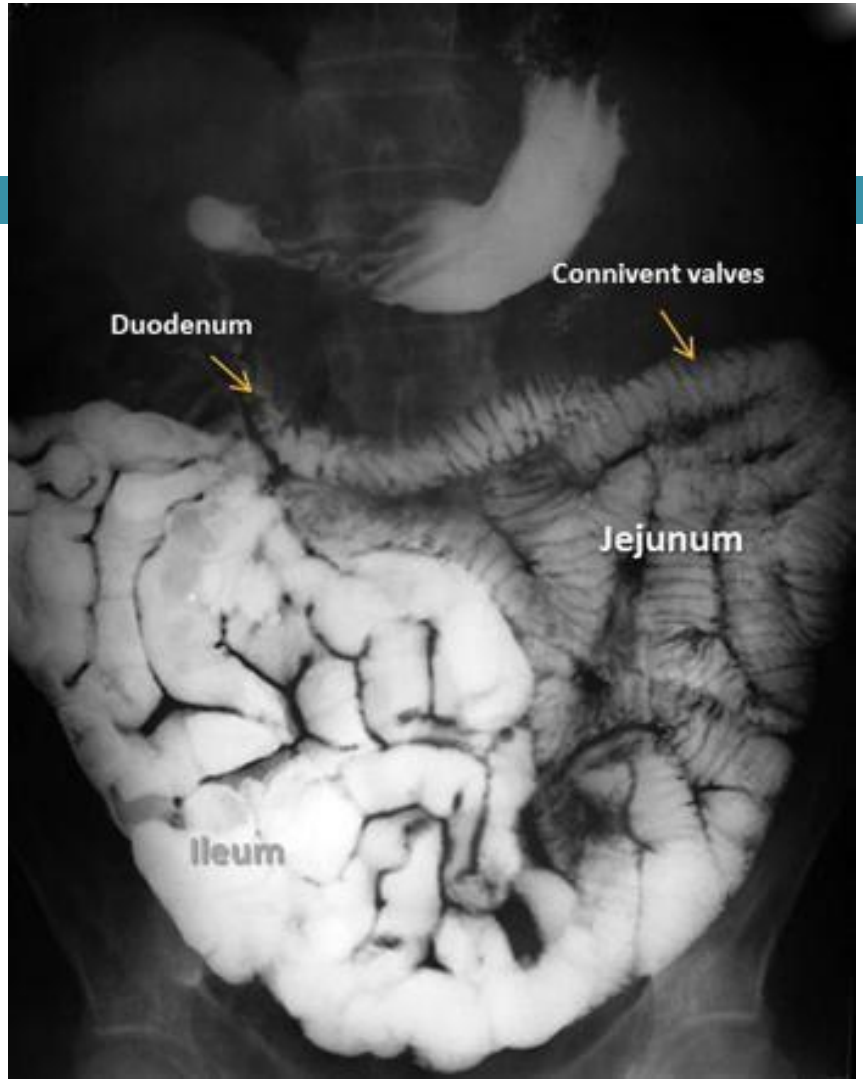
Connivent valves
Duodenum
Jejunum
Ileum

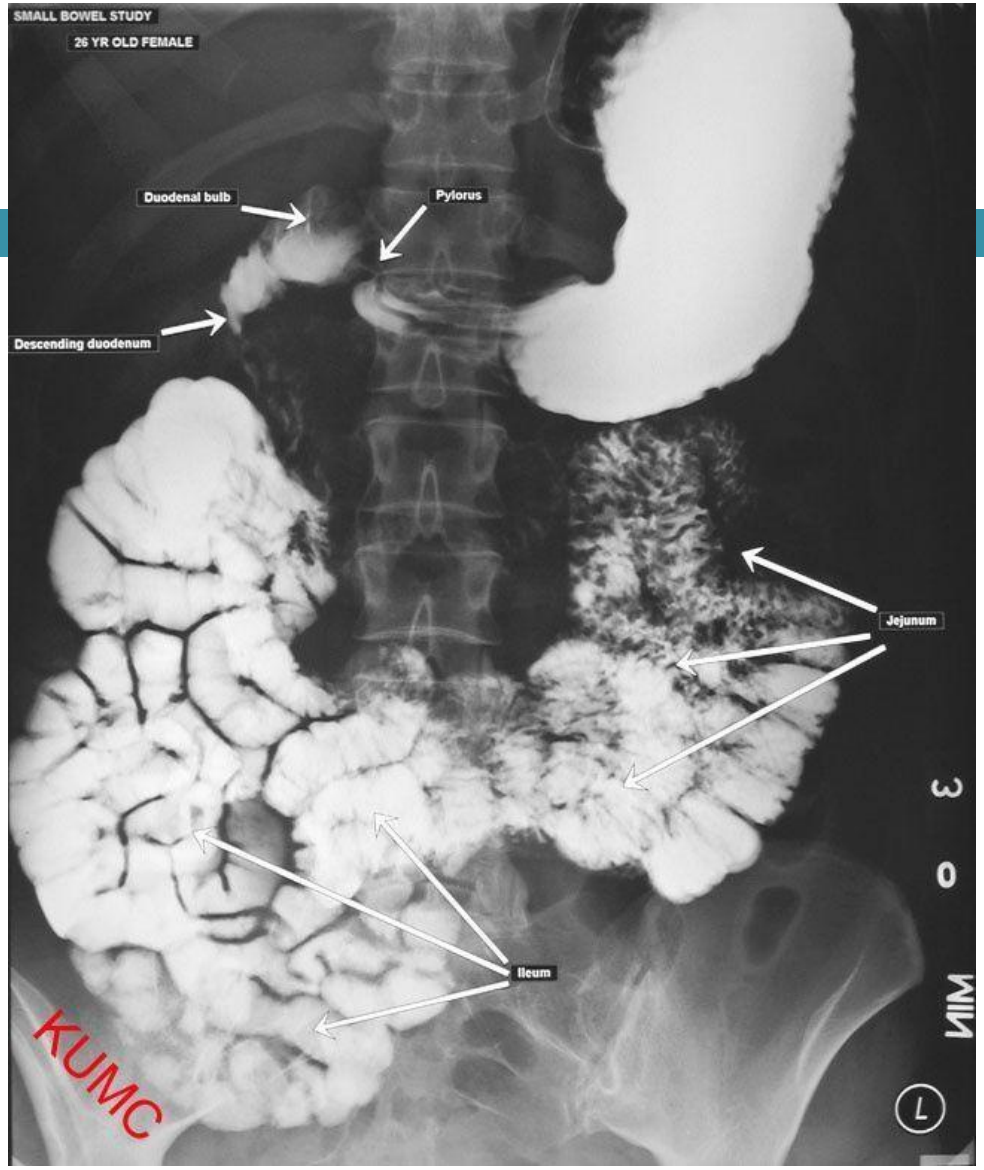
SMALL BOWEL STUDY
26 YR OLD FEMALE
Duodenal bulb
Pylorus
Descending duodenum
Jejunum
Ileum
KUMC
MIN 30
L

- **If bowel loops are overlapped and not separated what to do ? (common problem)**

1. Do more compression
2. Tilt patient head down (table head down)
3. 30° caudal angled view of pelvis.

Water soluble may be used …

- **Gastrografin**

If the transit time through the small bowel is found to be slow may help to speed it up.

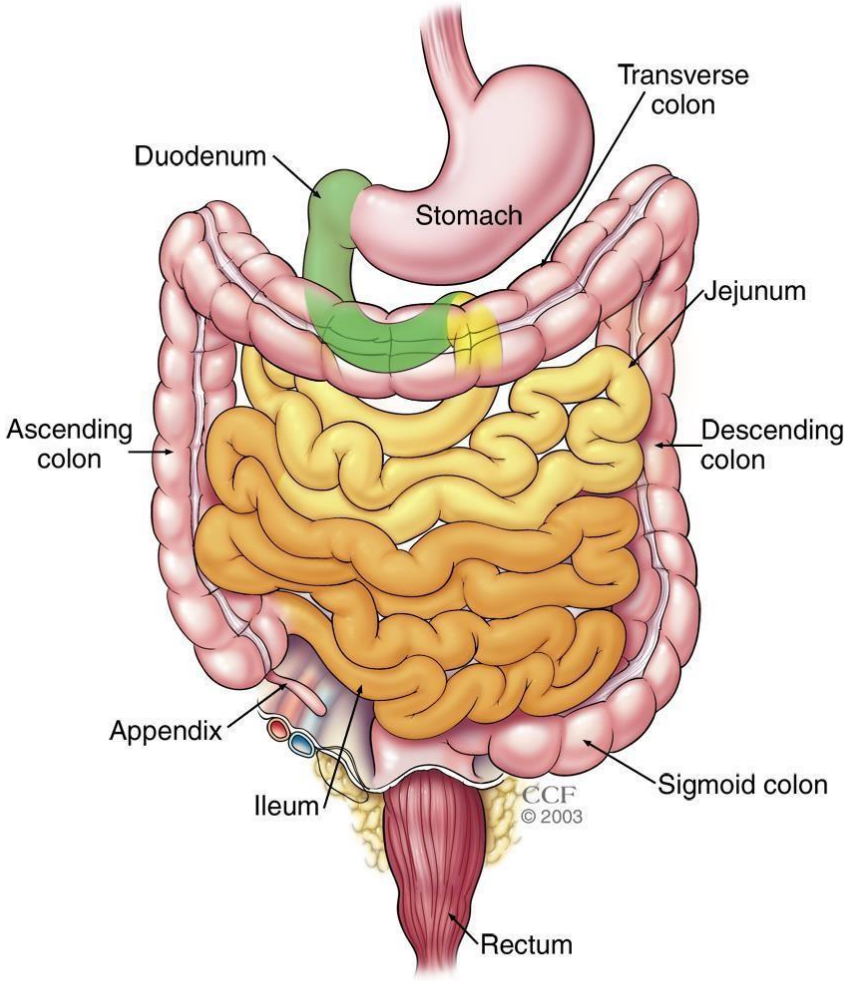
Transverse colon
Duodenum
Stomach
Jejunum
Ascending colon
Descending colon
Appendix
Ileum
Sigmoid colon
CCF
© 2003
Rectum

RejuvInnate
your innate

Ileocecal Valve

The *ileocecal valve* is located between the small and large intestine.

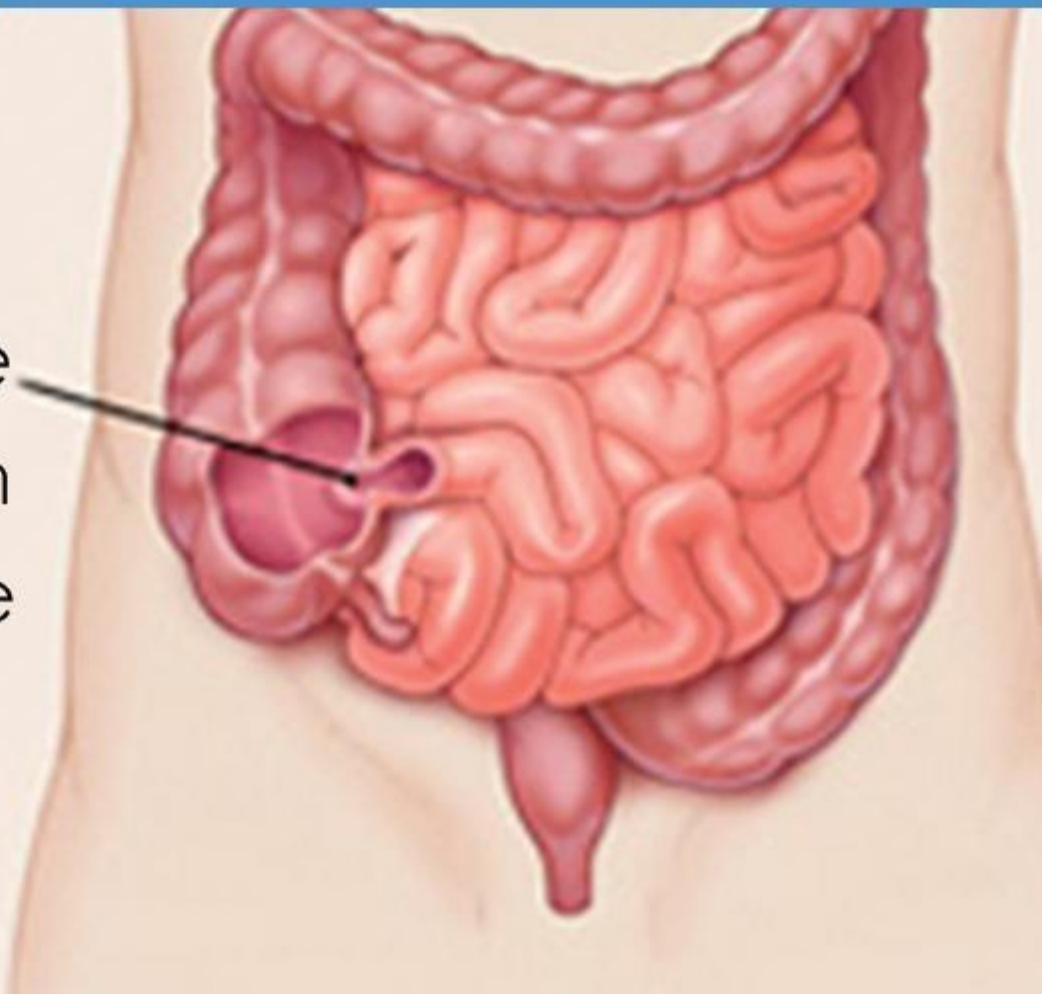

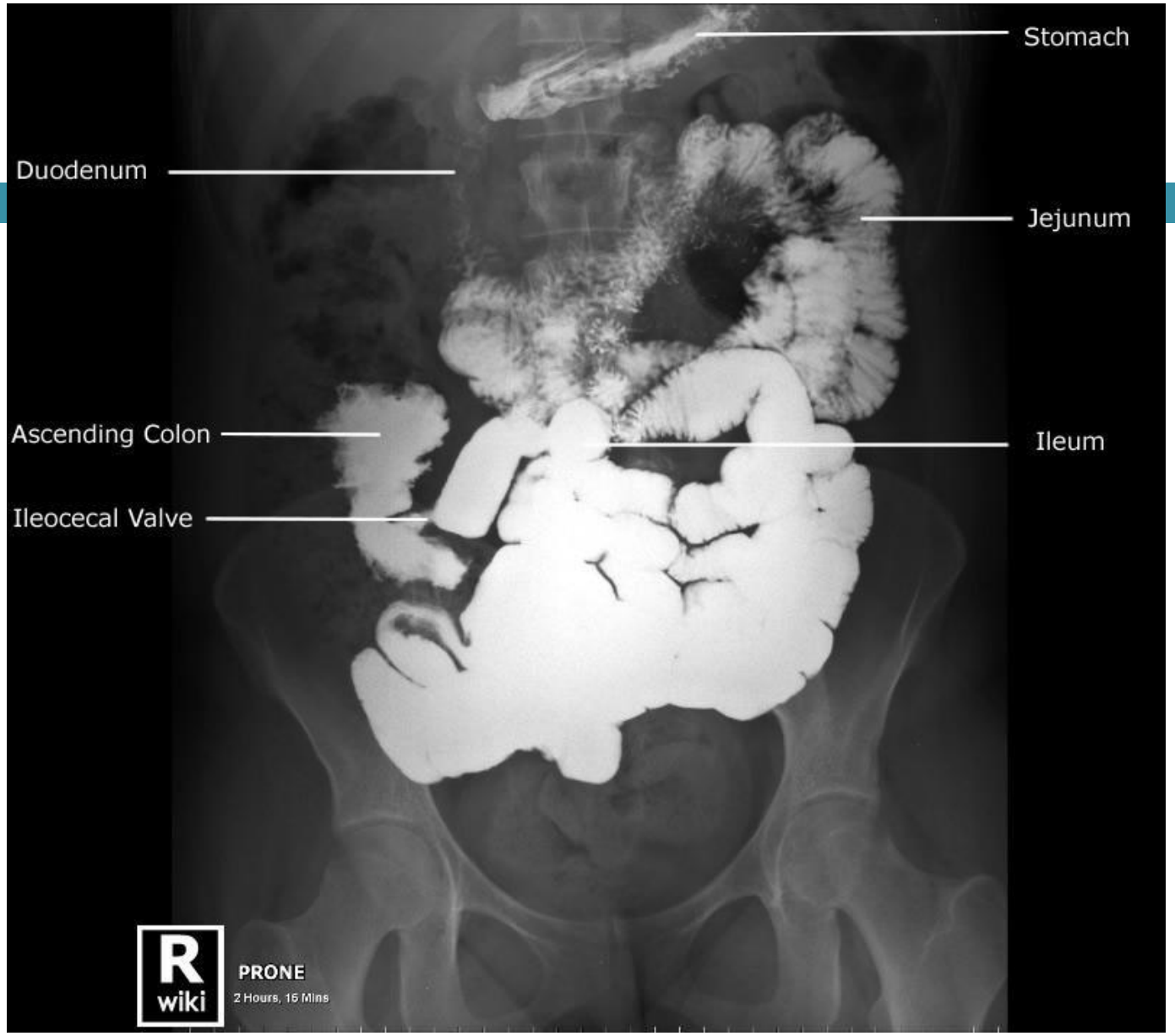
Stomach
Duodenum
Jejunum
Ascending Colon
Ileum
Ileocecal Valve
R
wiki
PRONE
2 Hours, 15 Mins

Small bowel enema

- Other name is (**Enteroclysis)**

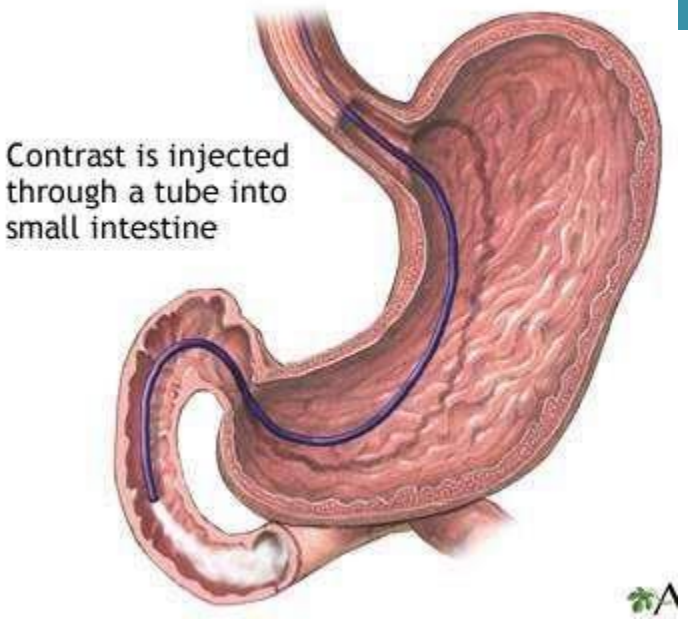

- **Defintion :**

is the radiological study of small bowel from jejunum to the ileocaecal junction **by intubation** of the jejunum and instillation of contrast through the tube.

Advantage..

- This procedure gives better distension and visualization of the proximal small bowel than that achieved by a barium follow through because rapid infusion of a large continuous column of contrast medium directly into the jejunum by tube introduced through mouth to esophagus to stomach then duodenum till reach jejunum

Disadvantages…

1. Unpleasant to the patient
2. Time consuming
3. Higher radiation dose (repeated images taken to ensure the tube in the right place)..

Indication …

- Same as small bowel follow through but more dedicated for proximal part diseases of small intestine ..

Patient preparation…

1. The patient is subjected to liquid diet (2-3 litres) for a full day before the examination and is called after overnight fasting for the procedure.
2. preceding the enteroclysis are given.

- **The above said preparation is very important because a full caecum or a food filled ileum seriously retards intestinal flow and produces artifacts and more fluid is needed to reach the caecum quickly**

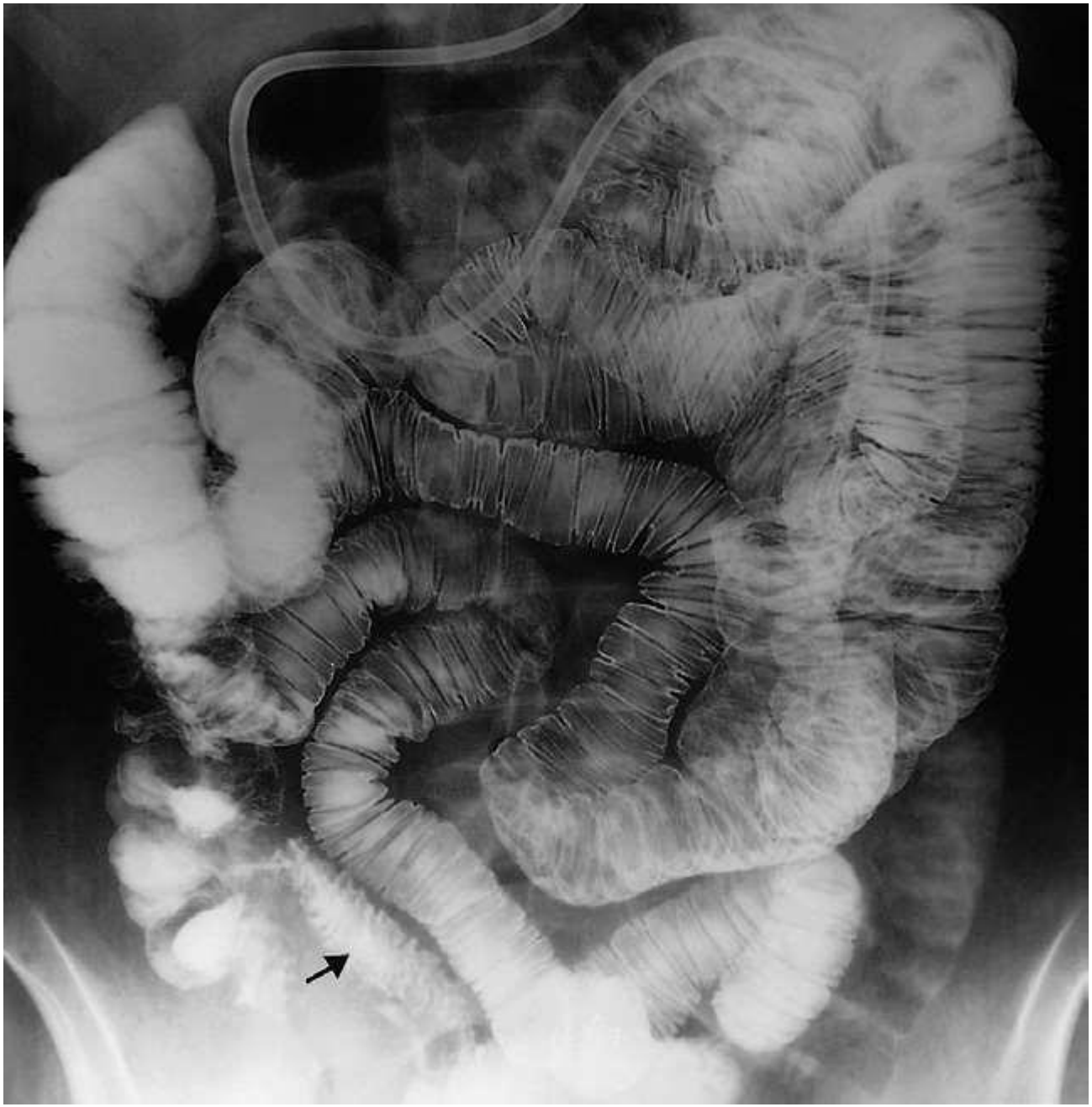

- All the filming is done with high kV technique (120- 140 kV).

After care …

- Warn patients about diarrhoea due to large volume of fluid infused.

Examples of some diseases …

- **Jejunal diverticula**

Small loops extending from the mesentric border of jejunal loop



- **Gastrointestinal tumor** arising from muscular layer of intestinal wall as **filling defect** in the jejunum.

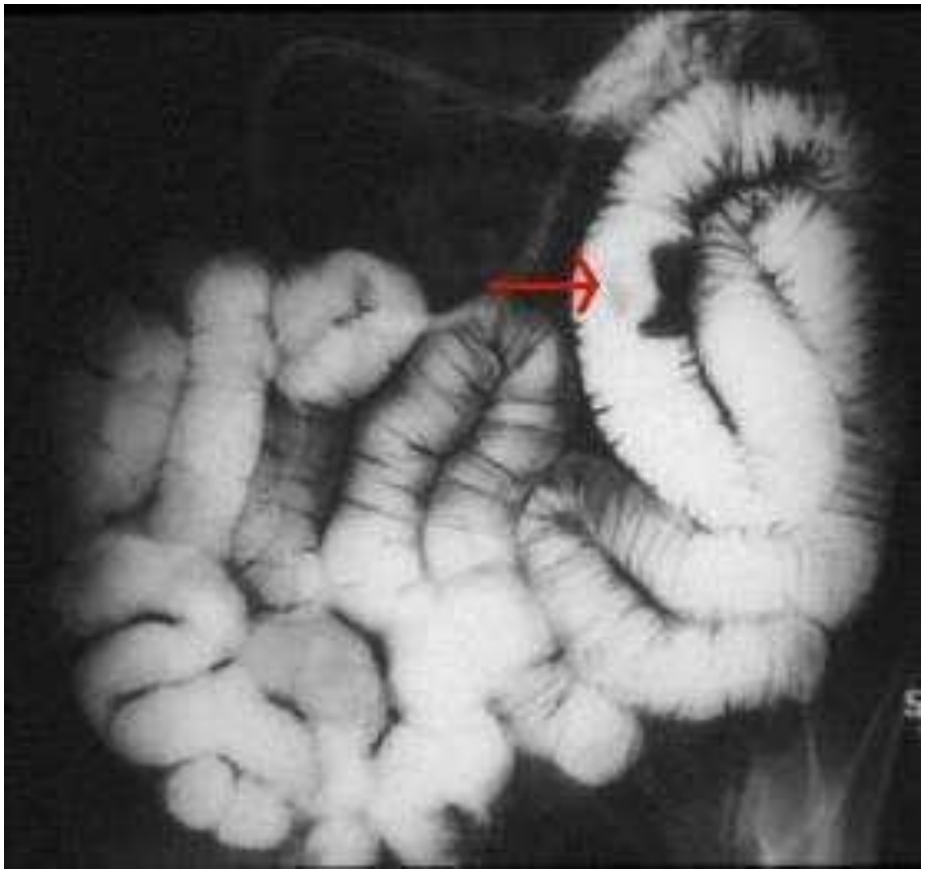

Thank you

