By

Layth Kareem

Ms.c in MRI applications

radiographic techniques for upper limbs



Basic Principles of Radiography and Digital Technology

At the end of this lecture the student should learn

- Anatomical position
- Patient aspect
- Planes of the body
- Positioning terminology

TERMINOLOGY

The human body is a complicated structure, and errors in radiographic positioning or diagnosis can easily occur unless practitioners have a common set of rules that are used to describe the body and its movement.

TERMINOLOGY

- Anatomical terminology
- Positioning terminology
- Projection terminology

Anatomical terminology

Patient aspect

Anterior aspect: that seen when viewing the patient from the front.

• **Posterior (dorsal) aspect:** that seen when viewing the patient from the back.

• **Lateral aspect:** refers to any view of the patient from the side. The side of the head would therefore be the lateral aspect of the cranium.

• **Medial aspect:** refers to the side of a body part closest to the midline, e.g. the inner side of a limb is the medial aspect of that limb.

Anterior and posterior aspect of the body



Lateral aspect of body and medial

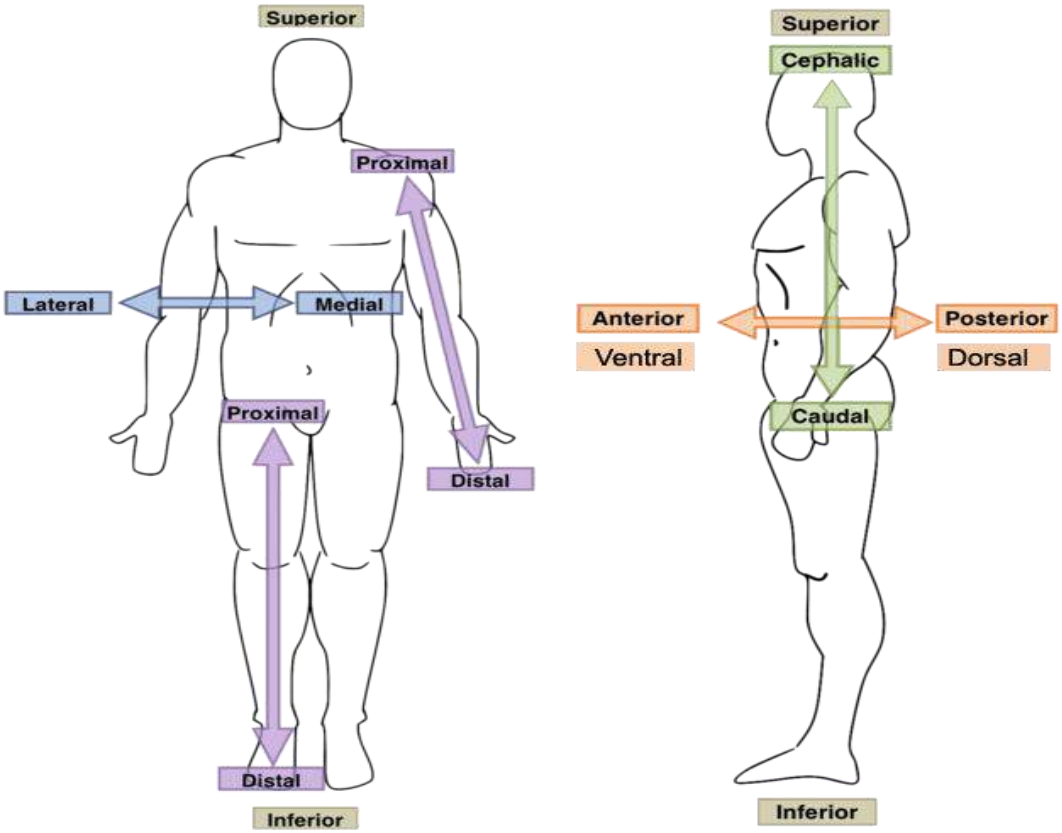

Planes of the body

Median sagittal plane: divides the body into right and left

halves. Any plane that is parallel to this but divides the body

into unequal right and left portions is known simply as a

sagittal plane or parasagittal plane.

- **Coronal plane:** divides the body into an anterior part and a posterior part.
- **Transverse or axial plane:** divides the body into a superior part and an inferior part.

Planes of the body

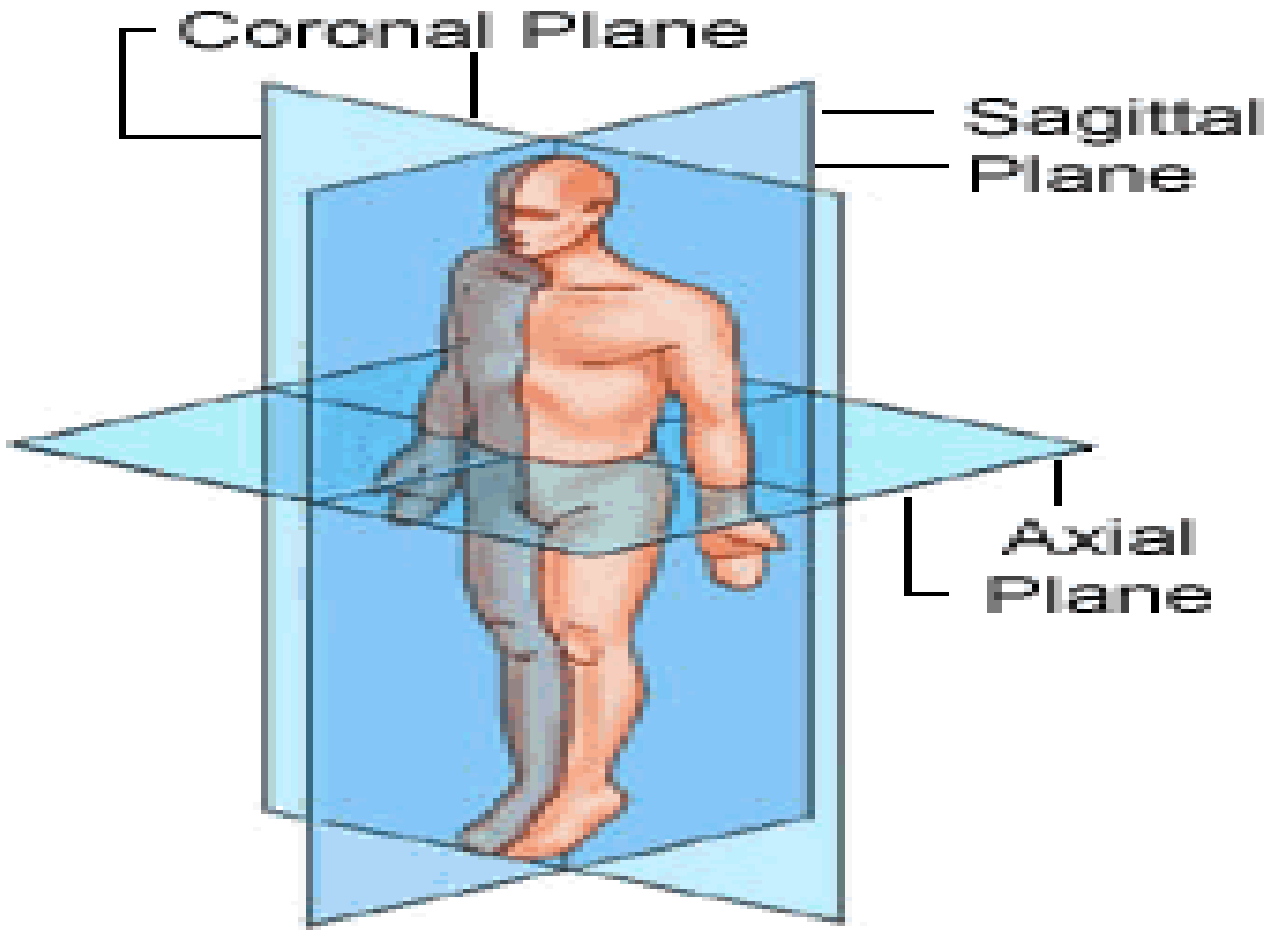

Positioning terminology

Supine (dorsal decubitus): lying on the back.

• **Prone (ventral decubitus):** lying face-down.

• **Lateral decubitus:** lying on the side. Right lateral decubitus –

lying on the right side. Left lateral decubitus – lying on the

left side.

• **Semi-recumbent:** reclining, part way between supine and sitting

erect, with the posterior aspect of the trunk against the

cassette.

Positioning terminology



(a) Supine



(b) Prone



(c) Right lateral decubitus



(d) Left lateral decubitus

Positioning terminology (*contd*)
Terminology used to describe the limb position

Extension: when the angle of the joint increases.

- **Flexion:** when the angle of the joint decreases.
- **Abduction:** refers to a movement away from the midline.
- **Adduction:** refers to a movement towards the midline.
- **Rotation:** movement of the body part around its own axis, e.g. medial (internal) rotation towards the midline, or lateral (external) rotation away from the midline.
- **Pronation:** movement of the hand and forearm in which the palm is moved from facing anteriorly (as per anatomical position) to posteriorly. **Supination** is the reverse of this. Other movement terms applied to specific body parts are described in the diagrams.

Positioning terminology

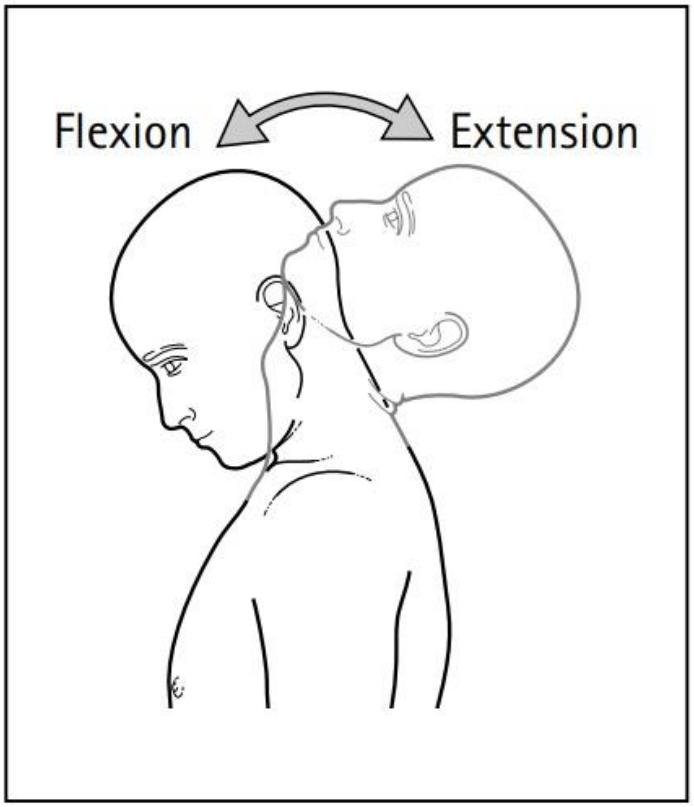

Flexion and extension of neck

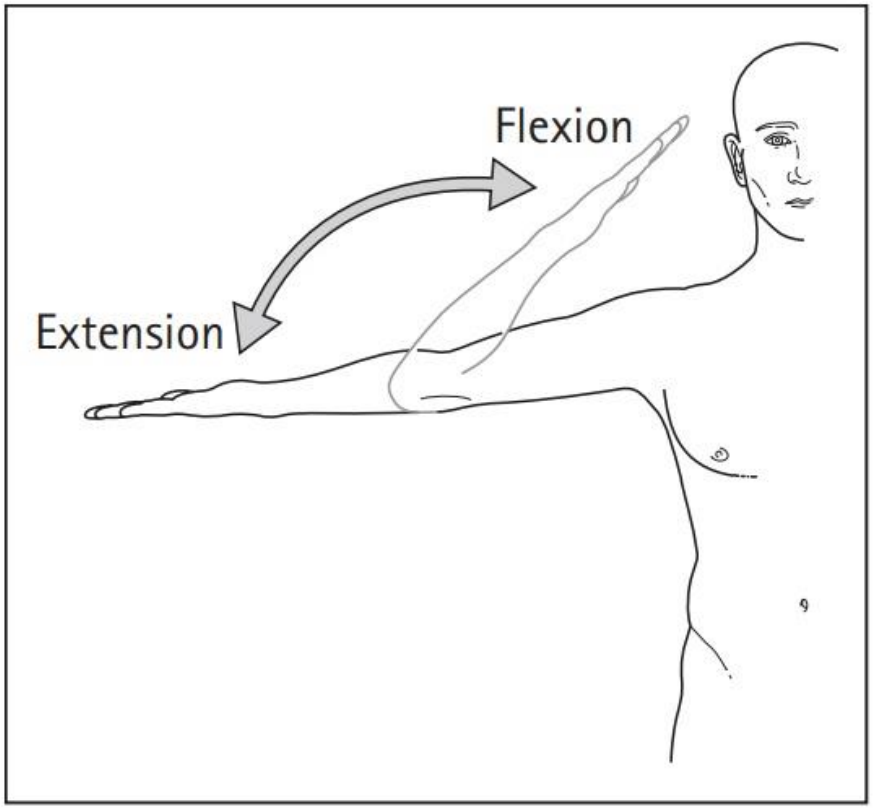

Flexion and extension of elbow

Positioning terminology

Types of joint movement at synovial joints-angular

Abduction-movement away from the midline
Adduction-movement toward the midline

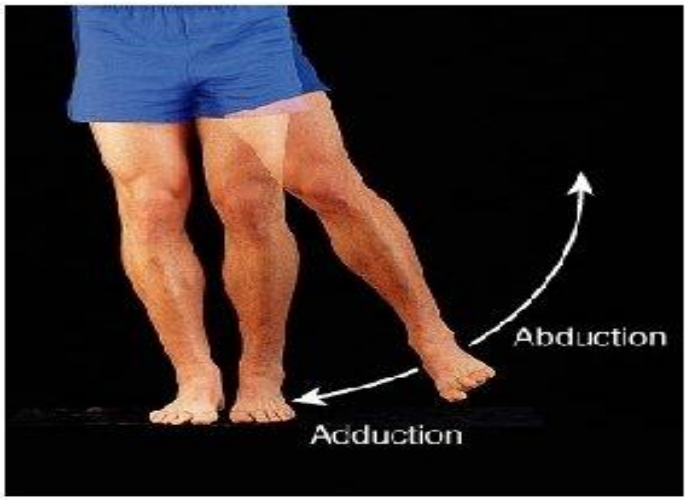

(c) Hip joint

John Wilson White

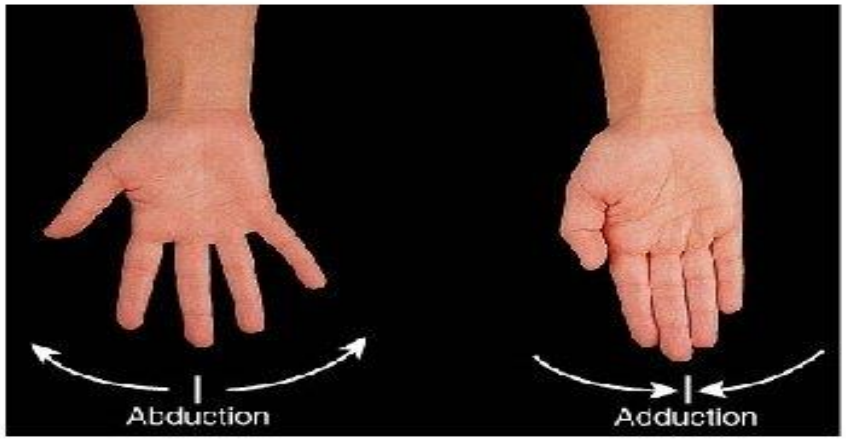

(d) Metacarpophalangeal joints of the fingers (not the thumb)

John Wilson White

Pronation and supination of hand/forearm

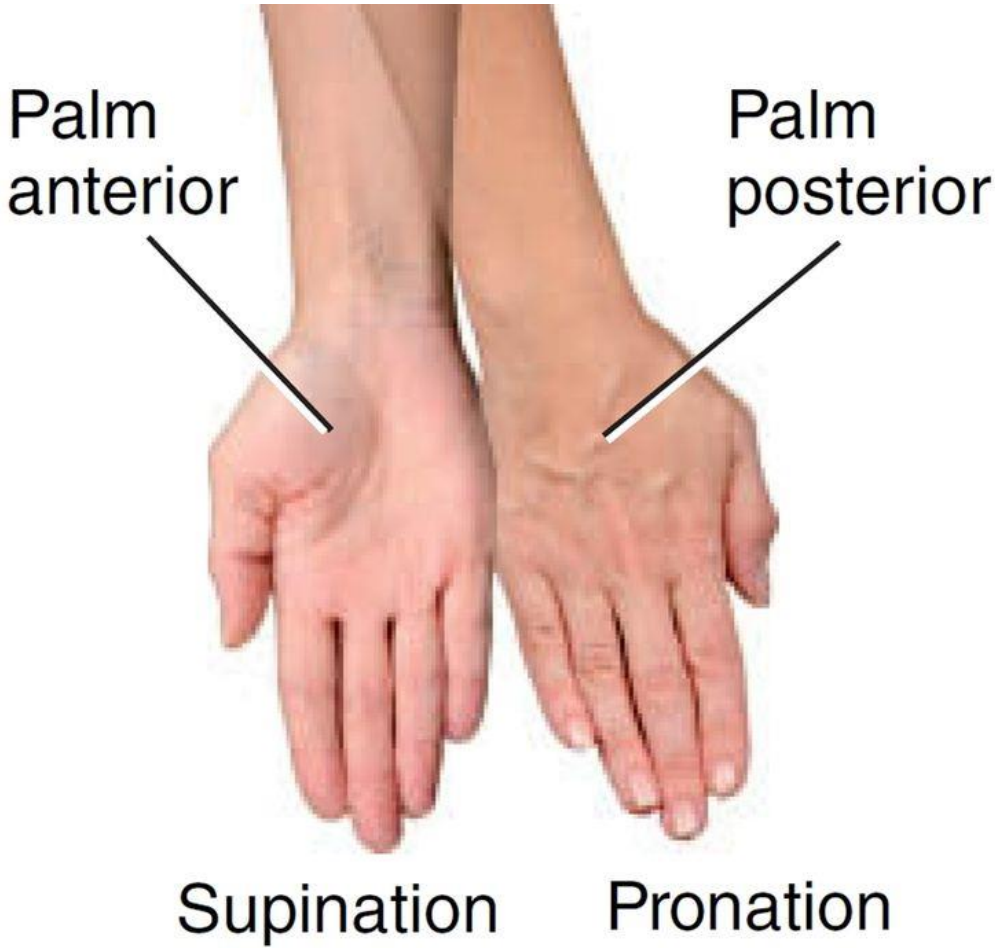

Projection terminology

projection is described by the direction of the central ray relative to aspects and planes of the body.

Antero-posterior

Postero-anterior

Lateral

oblique

Antero-posterior&Postero-anterior

Antero-posterior :The central ray is incident on the anterior aspect, passes along

or parallel to the median sagittal plane, and emerges from the

posterior aspect of the body.

Postero-anterior: The central ray is incident on the posterior aspect, passes along

or parallel to the median sagittal plane, and emerges from the

anterior aspect of the body.

AP

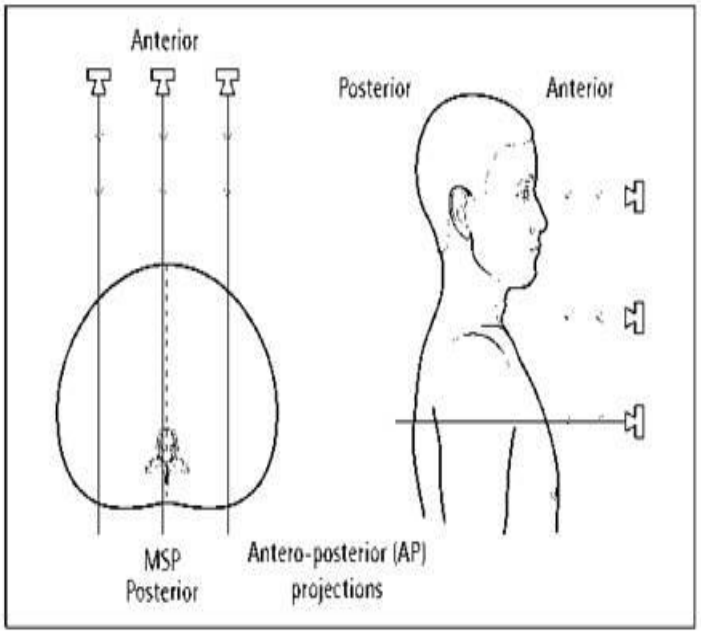

PA

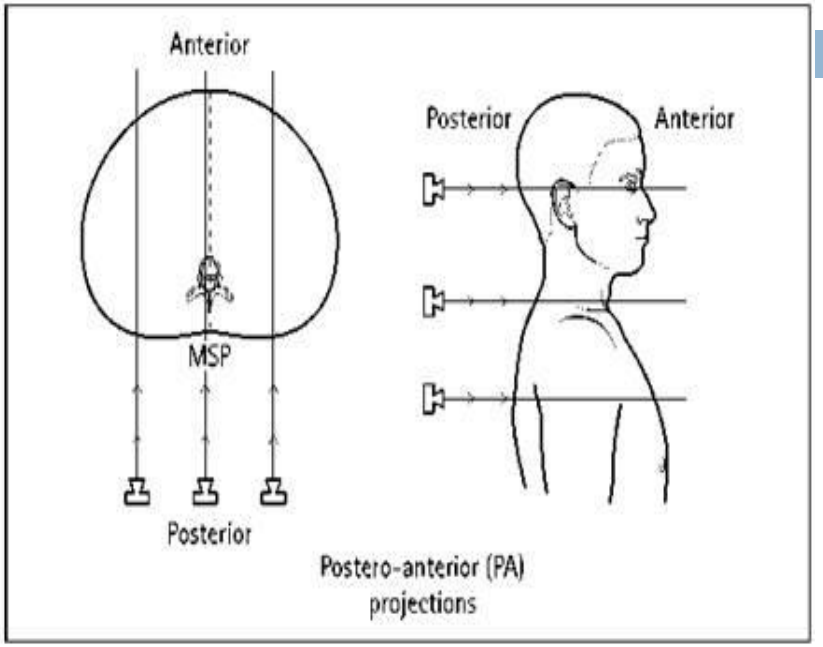

AP Projection



Mosby items and derived items © 2005, 2001, 1997, 1993, 1987, 1982 by Mosby, Inc.



Lateral

Lateral:

The central ray passes from one side of the body to the other along a coronal and transverse plane.

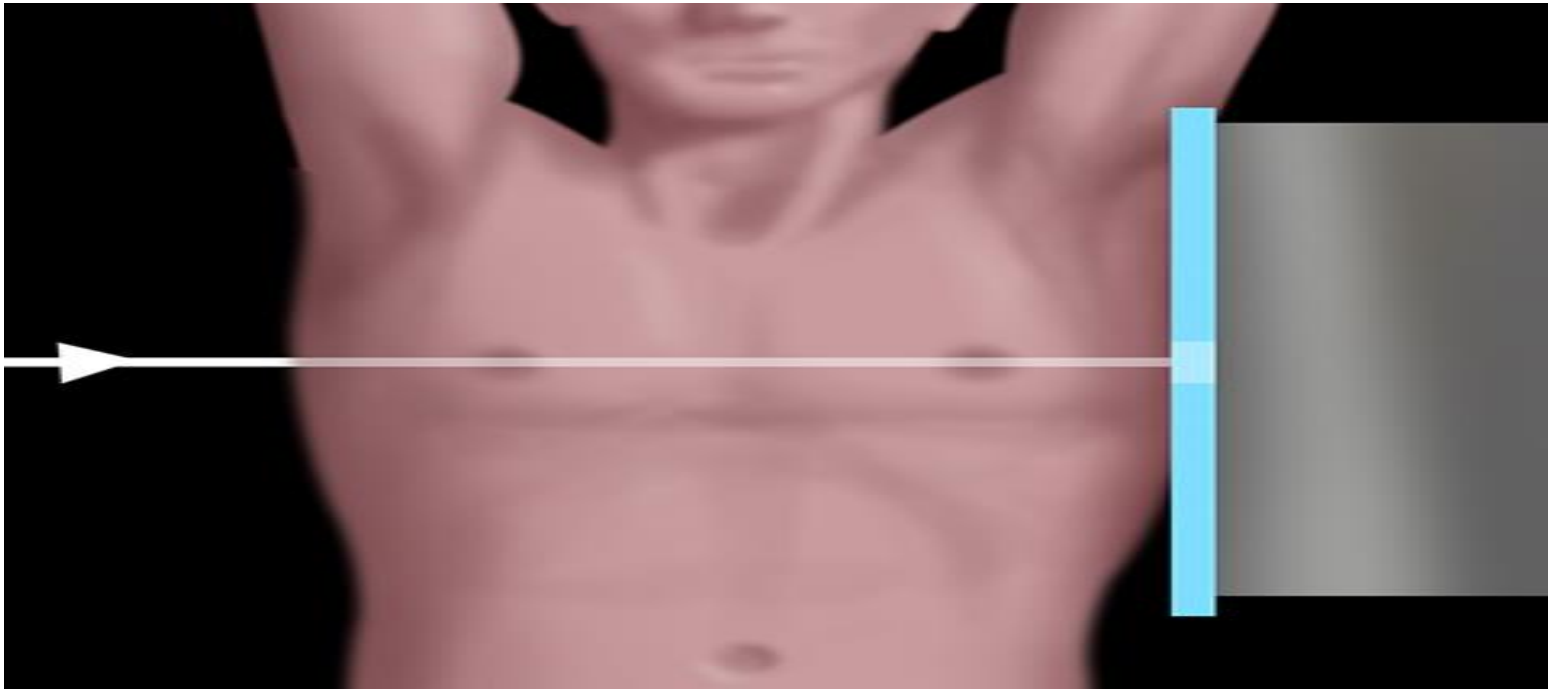

Posterior oblique

Posterior oblique

The central ray enters the anterior aspect, passes along a transverse

plane at some angle to the median sagittal plane, and

emerges from the posterior aspect. Again, the projection is

described by the side of the torso closest to the cassette. The

diagram below shows a left posterior oblique.

Oblique

The central ray passes through the body along a transverse plane at some angle between the median sagittal and coronal planes. For this projection, the patient is usually positioned with the median sagittal plane at some angle between zero and 90 degrees to the cassette, with the central ray at right-angles to the cassette. If the patient is positioned with the median sagittal plane at right-angles to or parallel to the cassette, then the projection is obtained b directing the central ray at some angle to the median sagittal plane

Oblique

Anterior oblique

The central ray enters the posterior aspect, passes along a transverse

plane at some angle to the median sagittal plane, and

emerges from the anterior aspect. The projection is also described

by the side of the torso closest to the cassette. In the diagram

below, the left side is closest to the cassette, and therefore the

projection is a described as a left anterior oblique

Anterior oblique

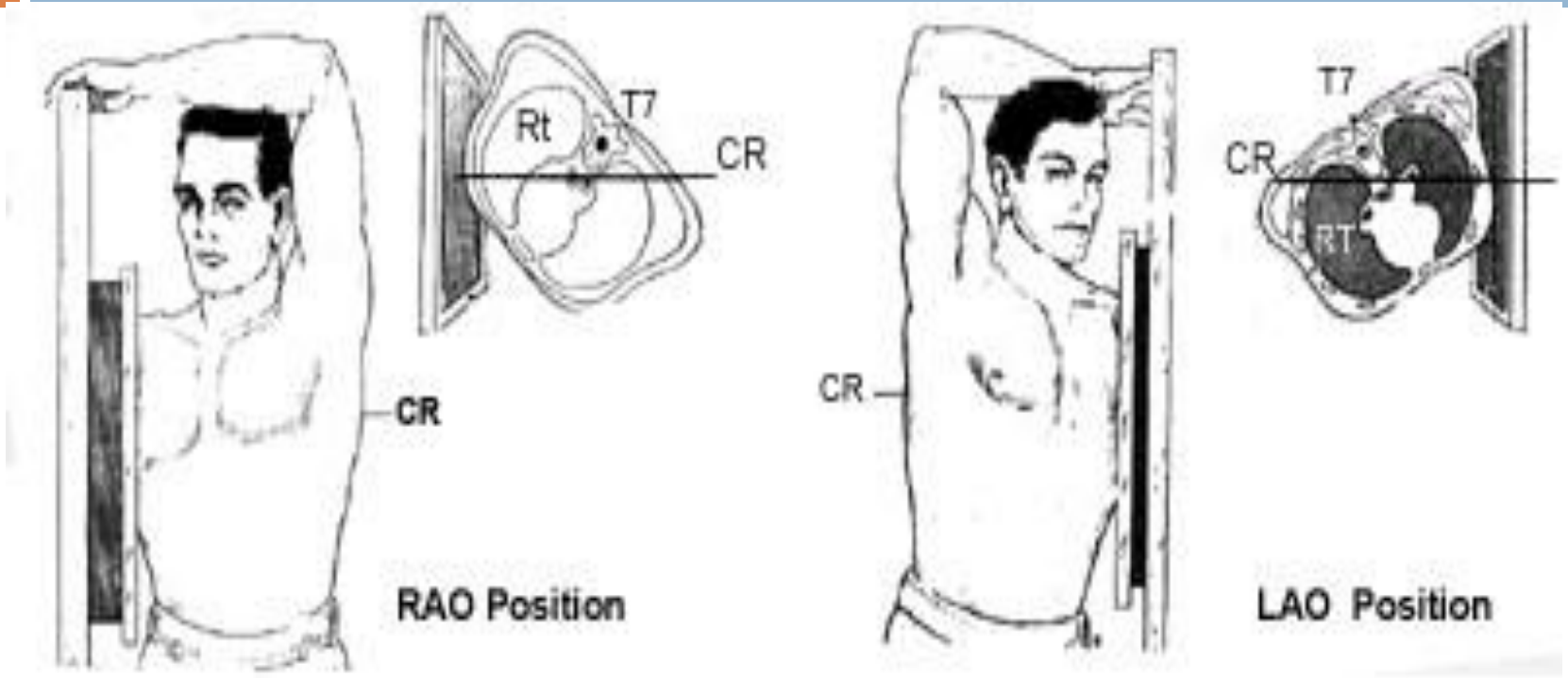

Anterior (PA) oblique projections -- the side of interest is the side furthest from the cassette. Image courtesy of Dr. Naveed Ahmad.

Posterior oblique

Posterior oblique:

The central ray enters the anterior aspect, passes along a transverse

plane at some angle to the median sagittal plane, and

emerges from the posterior aspect. Again, the projection is

described by the side of the torso closest to the cassette. The

diagram below shows a left posterior oblique.