By Layth Kareem

Ms.c in MRI applications

# radiographic techniques for upper limbs(lec8)

## wrist joint(carpal bones)

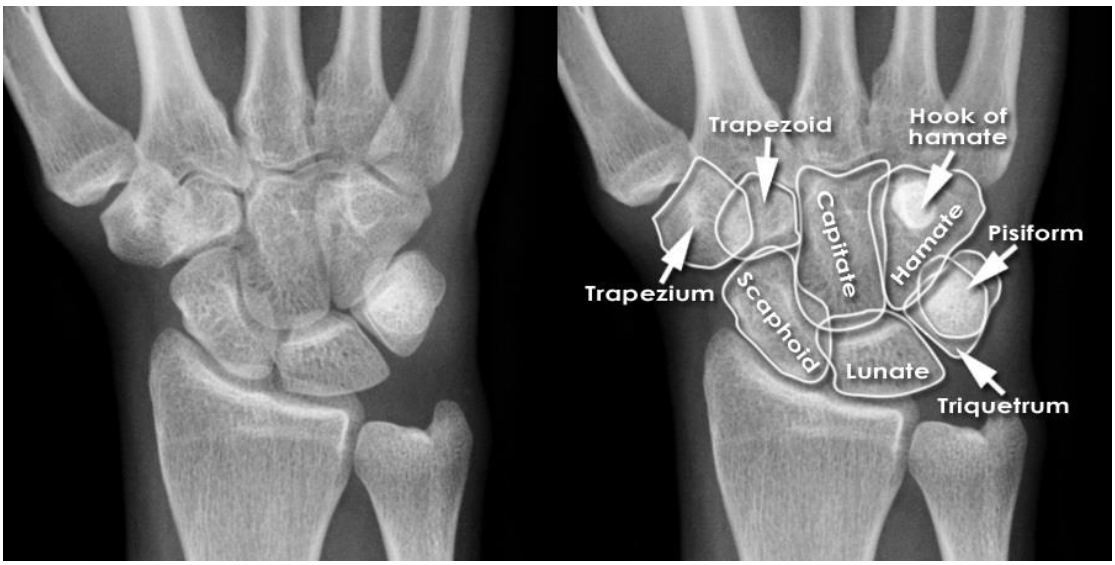


**scaphoid, lunate, triquetrum, and pisiform (proximal row)**

**trapezium, trapezoid, capitate, and hamate (distal row)**

carpal bones are bones of the wrist that connect the distal aspects of the radial and ulnar bones of the forearm to the bases of the five metacarpal bones of the hand. There are eight carpal bones, which divide into two rows: a proximal row and a distal row

## positioning of wrist joint

**1. wrist PA**

**2.wrist lat**

**3.wrist medial oblique**

**4.wrist lat oblique**

***PA and lateral are basic position of wrist x – ray**

PA position of wrist joint



## PA position

**1.** the patient is placed in sitting position

**2.** place the hand in pronation state on image receptor(IR)

**3.** Adhere the hand on the IR completely

**4.** place the wrist joint on the center of the IR

**5.** lower the shoulder to align wrist joint, elbow joint and shoulder joint

## Evaluation

**1.**All the bones related to the wrist joint need to be included

**2.** distal radioulnar joint must not overlap

## Region

-carpal bone**,**

**Pathology**

-fracture and osteoarthritis of ulna and radius ,ligament injury of wrist joint

**IR size**

(8*10 inch )

**SID** (100 cm)

**Central ray**

-project perpendicularly toward wrist joint

**Respiration**

-unrelated

**KVP (52)**

**MAs (2.5)**

# Anatomy of wrist joint



# Lateral position of wrist x ray



1. the patient is placed in sitting position
2. place the hand on image receptor(IR) in true lateral position.

3. place the fingers overlap with each other

## Anatomy of wrist joint PA position




## Anatomy of wrist joint  lateral position

## Special position

## -ulnar deviation position

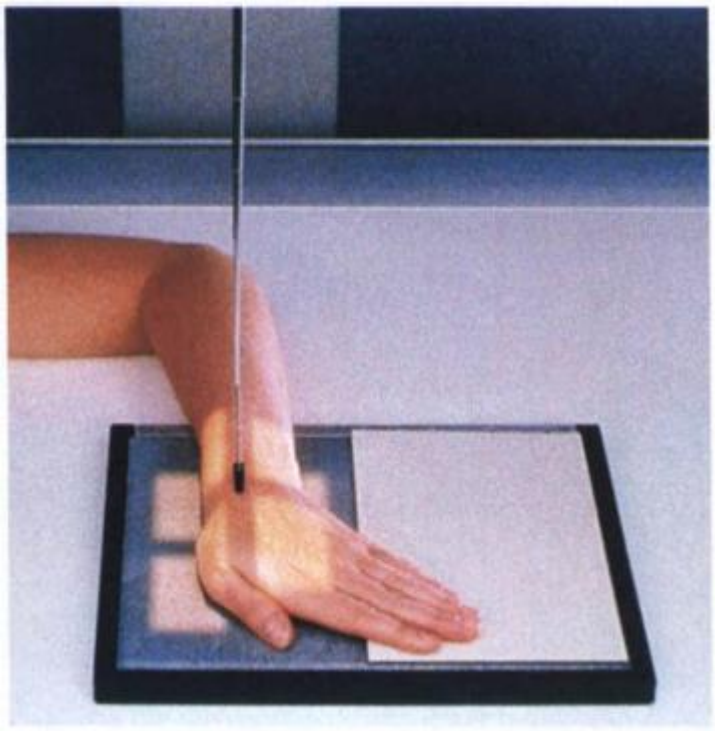



## Ulnar deviation position

**1.** the patient is placed in sitting position

**2.** place the hand in pronation state on image receptor(IR)

**3.** Adhere the hand on the IR completely and **flexion** the hand towards ulna

## Pathology

-Fracture of scaphoid