By Layth Kareem

Ms.c in MRI applications

radiographic techniques for upper limbs(lec5)

humerus

The **humerus** is a long bone of the upper limb, which extends from the shoulder to the elbow.

The proximal aspect of the humerus articulates with the glenoid fossa of the scapula, forming the glenohumeral joint. Distally, at the elbow joint, the humerus articulates with the **head of the radius** and trochlear notch of the ulna.

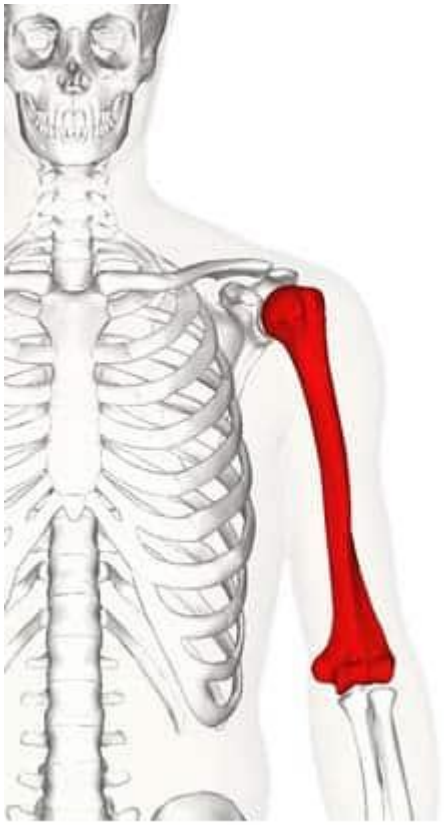

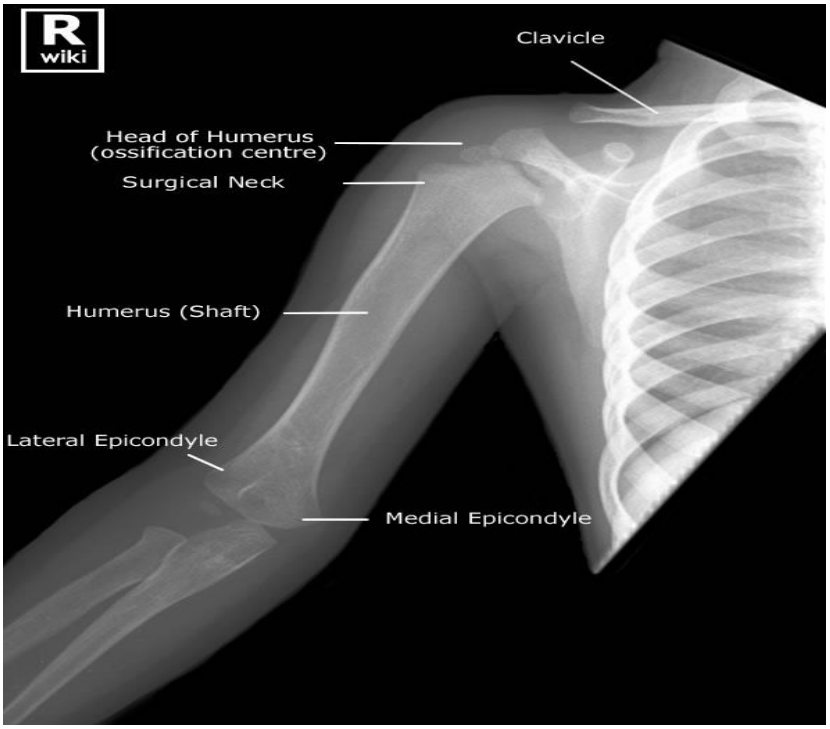

Humerus positions

1. AP

2.LAT (mediolateral)

3.LAT(transthoracic)

4.oblique(medial oblique)

AP position

1.the patient is placed either in supine position or in erect position.

2.place humerus on the middle of the image receptor(IR).

3.lean the body towards the table to adhere shoulder joint and proximal portion of the humerus to (IR)

4.abduct the arm to place lateral epicondyle of elbow joint and medial epicondyle in parallel with (IR)

Region

-humerus, elbow joint, shoulder joint

Pathology

-fracture and bony lesion of humerus

IR size

14*14

Central ray

-project perpendicularly toward the midline of humerus

Respiration

-suspended

Collimation

-include the whole humerus including form proximal portion of forearm to elbow joint

Evaluation

1.greater tubercle and lesser tubercle must overlap at the lateral portion

2.distal portion of humerus, latera; epicondyle and medial epicondyle should be shown overlapped.

SID

100cm

AP position



Lateral position

1.the patient is placed either in supine position or in erect position.

2.adhere humerus and shoulder joint to Image receptor(IR)

3.pose elbow joint of the filming arm in flexion of 90

Region

-humerus, elbow joint, shoulder joint

Pathology

-fracture and bony lesion of humerus

SID

-100 cm

Central ray

-project perpendicularly toward the midline of humerus

Respiration

-suspended

Collimation

-include the whole humerus including form proximal portion pf forearm to elbow joint.

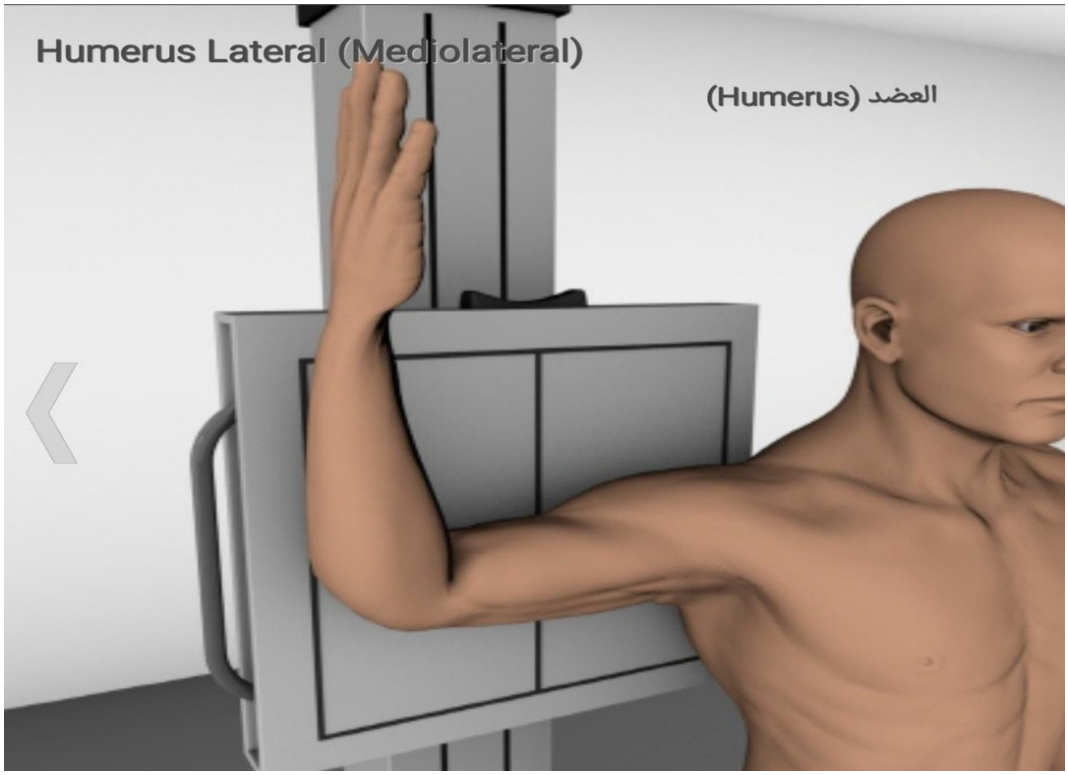

Thank you