By Layth Kareem

Ms.c in MRI applications

radiographic techniques for upper limbs(lec7)

forearm

Your arm is made up of three bones: the upper arm bone (humerus) and two forearm bones (the ulna and the radius)

Positioning of forearm

1.forearm AP (basic)

2. lateral(basic)

3.medial oblique

4.lateral oblique

AP position

1.the patient is placed in sitting position.

2.lower the shoulder to place shoulder joint and elbow joint on flat and stretch out and place the arm on image receptor**(IR)**

3.pose the hand in supination, and place the middle of forearm in center of **IR**. Adhere the forearm to IR completely.

4.in order to project whole forearm in true anterior-posterior. Tilt the shoulder to lateral direction.

Region

-ulna, radius, elbow joint

Pathology(indications)

-fracture and bony lesion of ulna and radius

IR size (10*12 inch)

SID (100cm)

Central ray

Project perpendicularly toward the midline of forearm

Respiration

-unrelated

Collimation

-include all structures from proximal portion of carpal bones to distal portion of elbow joint.

KVP (54)

MAs(3) **AP position of forearm**

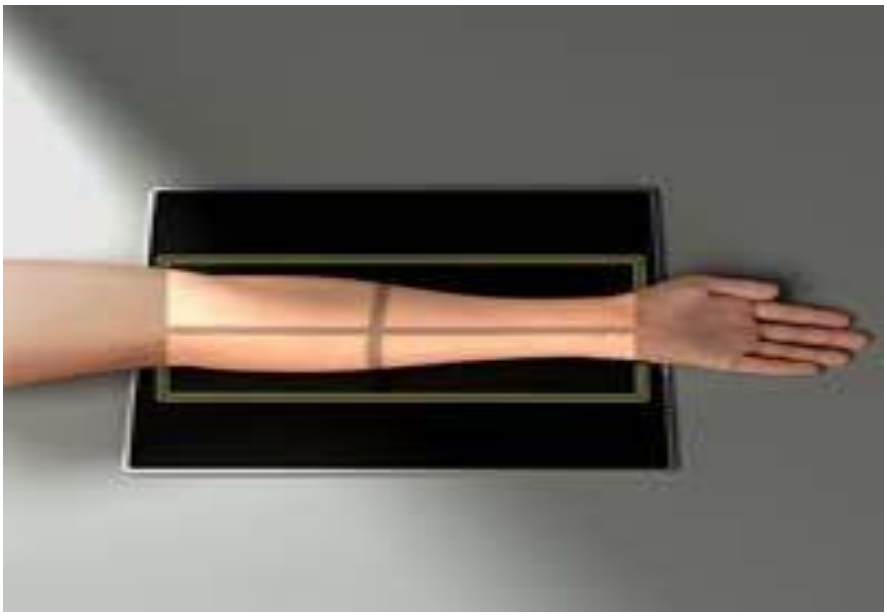

Anatomy of forearm

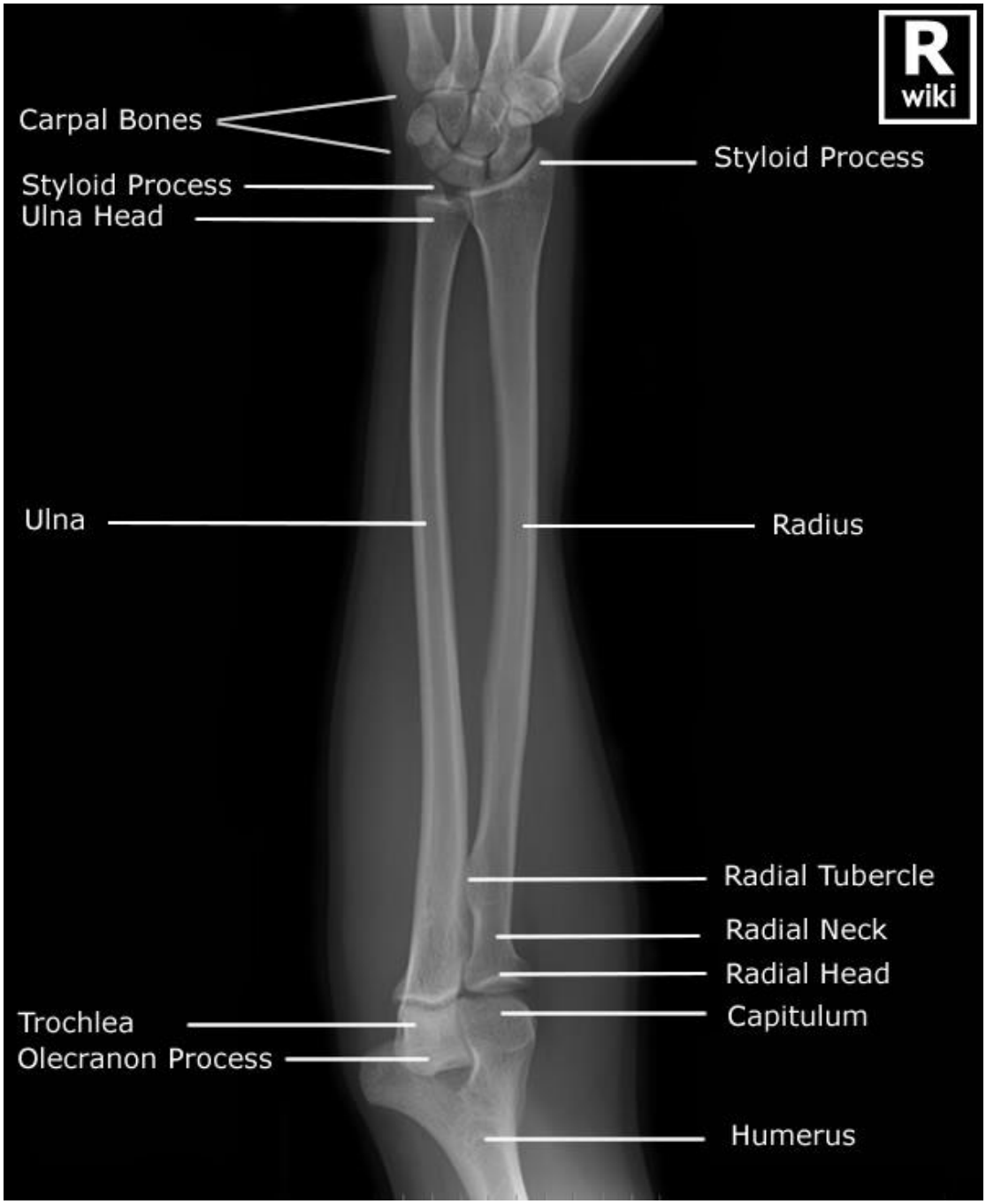

2. lateral position

1.the patient is placed in sitting position.

2. lower the shoulder to place shoulder joint and elbow joint on flat. Place elbow joint on IR in flexion of 90

3. and place the middle of forearm on the center of IR

4.lift thumb upward to be in ture lateral position and support the hand to avoid its movement.

Note (collimation and other thing like AP position)

lateral position of forearm



Anatomy of forearm

