By
Layth Kareem
Ms.c in MRI applications
radiographic techniques for upper limbs(lec4)

Clavicle

It Is a long bone approximately 15cm long that surves as a strut between the shoulder blade and the sternum ,

There are two clavicles one on the left and one on the right

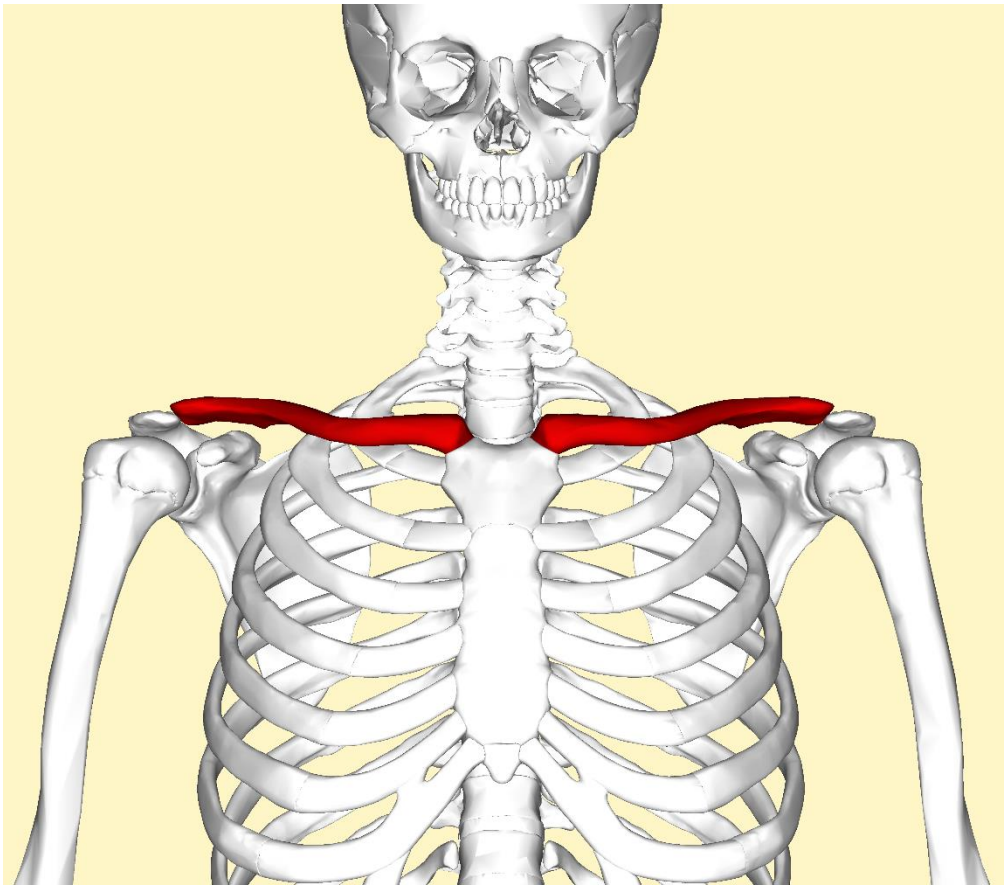

Clavicle position

1.Anterior posterior (AP)

2.clavicle AP axial (30 cephalad)

Region
Clavicle

Pathology
-fracture and dislocation of clavicle

IR size
10*12 inch

SID
-100 cm

Central ray
-project perpendicularly toward the center of clavicle with angle of 10 -20 cephalad

Respiration
-suspended with expiration

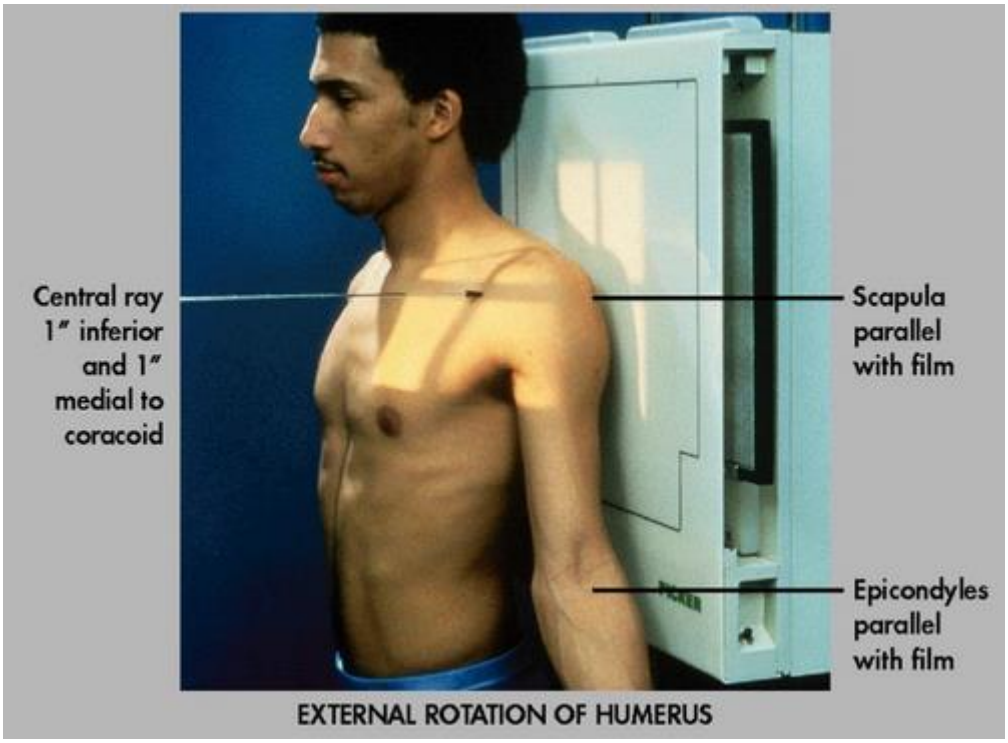

Position

1.the patient is placed either in supine position or in erect position

2. match the center of clavicle in middle of image receptor (IR) and adhere back of shoulder to IR

3.make the patient straight ahead by lifting the chine

Collimation

-include clavicle

Evaluation

1. Acromion of scapula to distal portion of clavicle must show
2. Acromio-clavicular joint and sterno-clavicular joint (S-C joint) must show

KVP

60

MAs

12

Normal clavicle bone

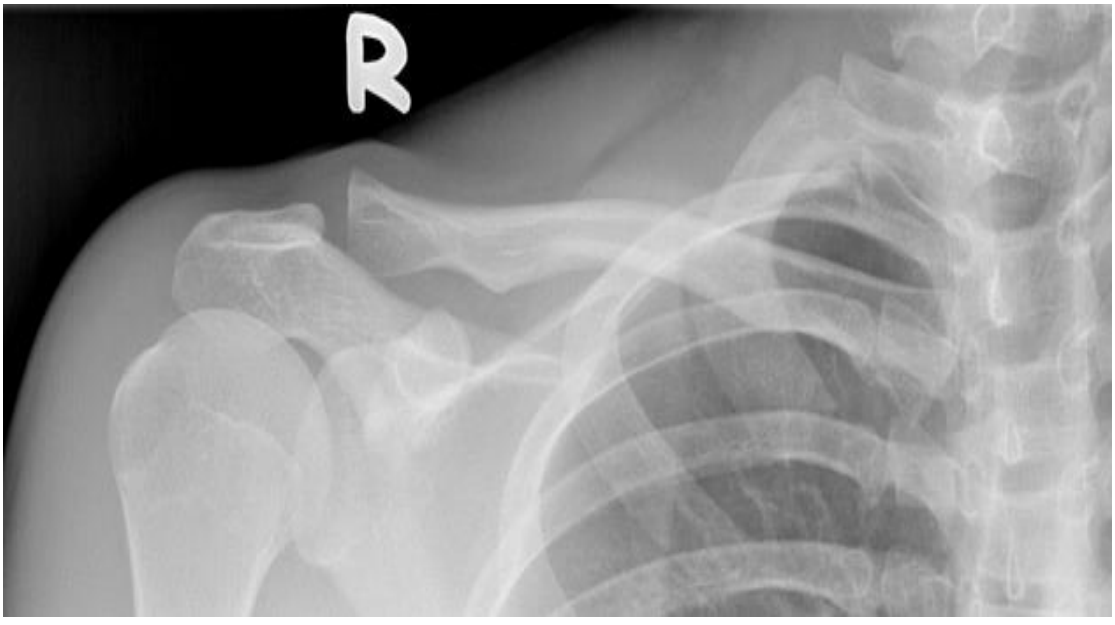

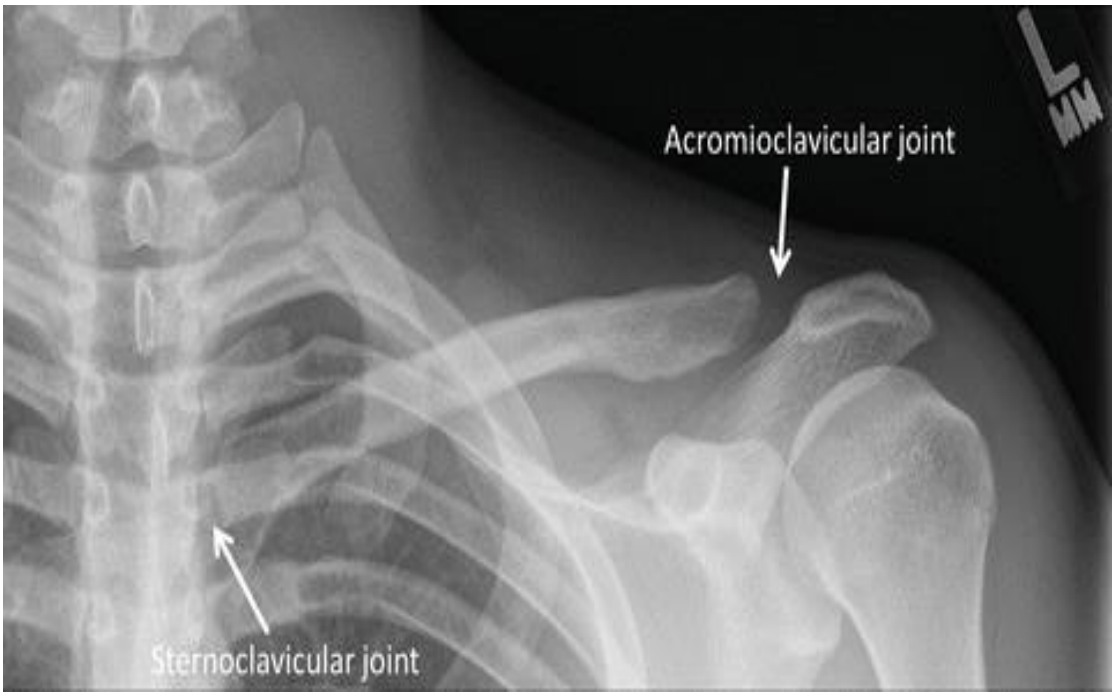

Clavicle fracture

