Blood Vessels Of Upper Limbs by muneer jawad MS.c RT

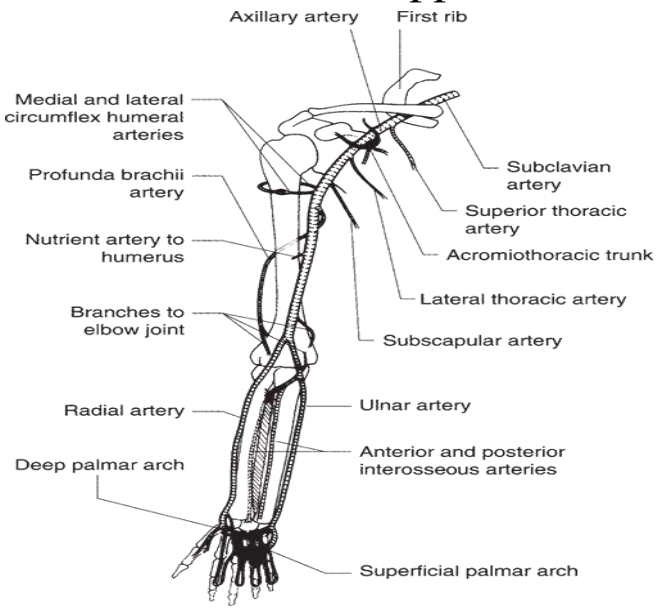

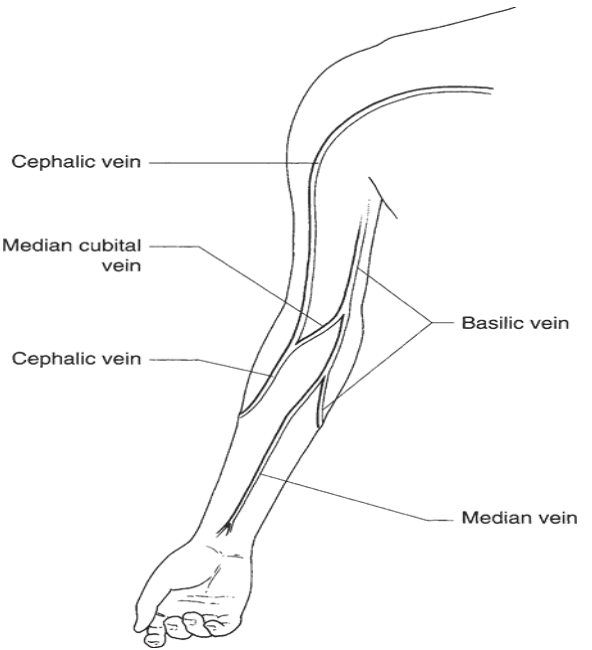

Arteries of Upper Limb

- The arterial supply to the upper limb is delivered via five main vessels (proximal to distal):

- **Subclavian artery**
- **Axillary artery**
- **Brachial artery**
- **Radial artery**
- **Ulnar artery**

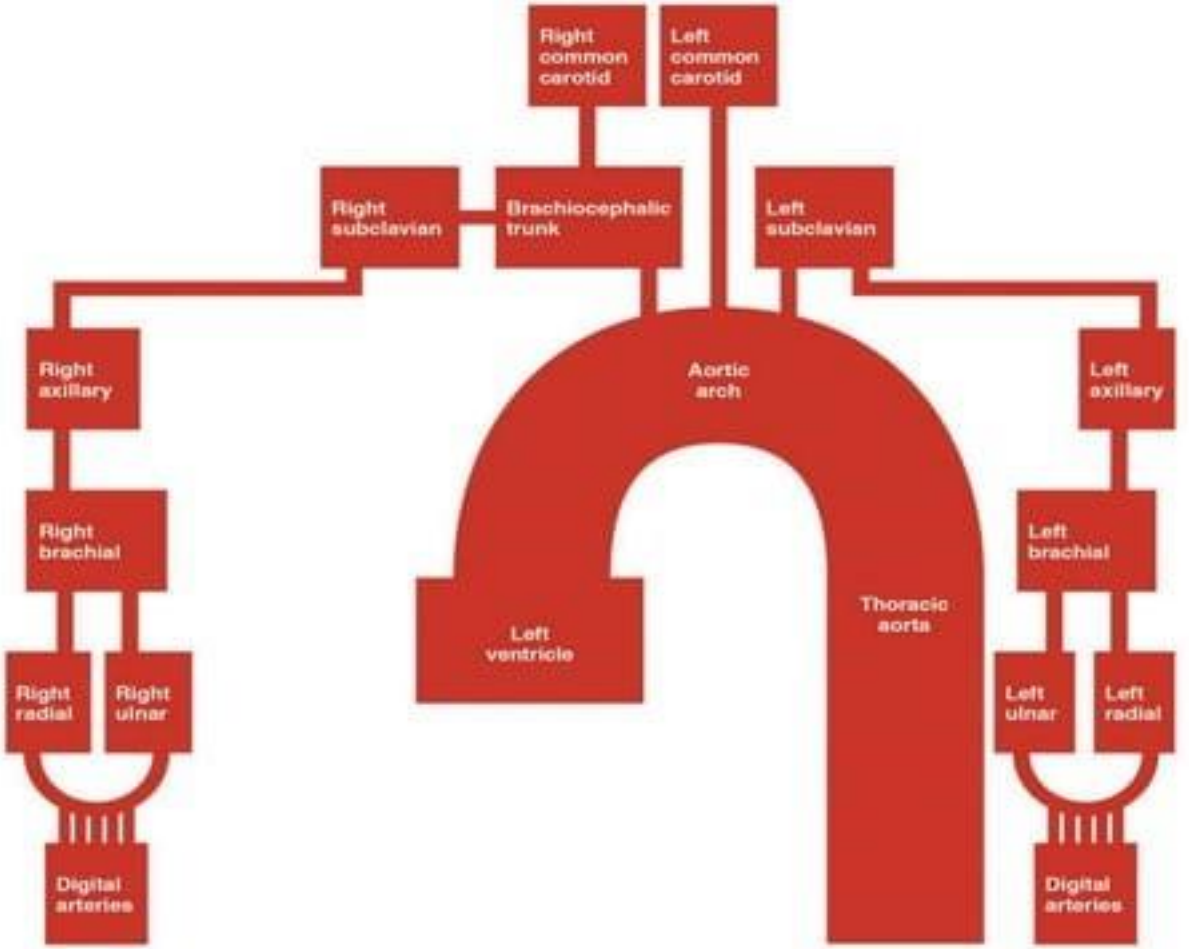
Right common carotid
Left common carotid
Right subclavian
Brachiocephalic trunk
Left subclavian
Right axillary
Aortic arch
Left axillary
Right brachial
Left brachial
Thoracic aorta
Left ventricle
Right radial
Right ulnar
Left ulnar
Left radial
Digital arteries
Digital arteries

Subclavian Artery

- On the right : the subclavian artery arises from the **brachiocephalic trunk**.
- On the left : directly from the **arch of aorta.**

- The subclavian artery travels laterally towards the axilla.
- It can be divided into three parts based on its position relative to the **anterior scalene muscle**:

- First part – origin of the subclavian artery to the medial border of the anterior scalene.
- Second part – posterior to the anterior scalene.
- Third part – lateral border of anterior scalene to the lateral border of the first rib.

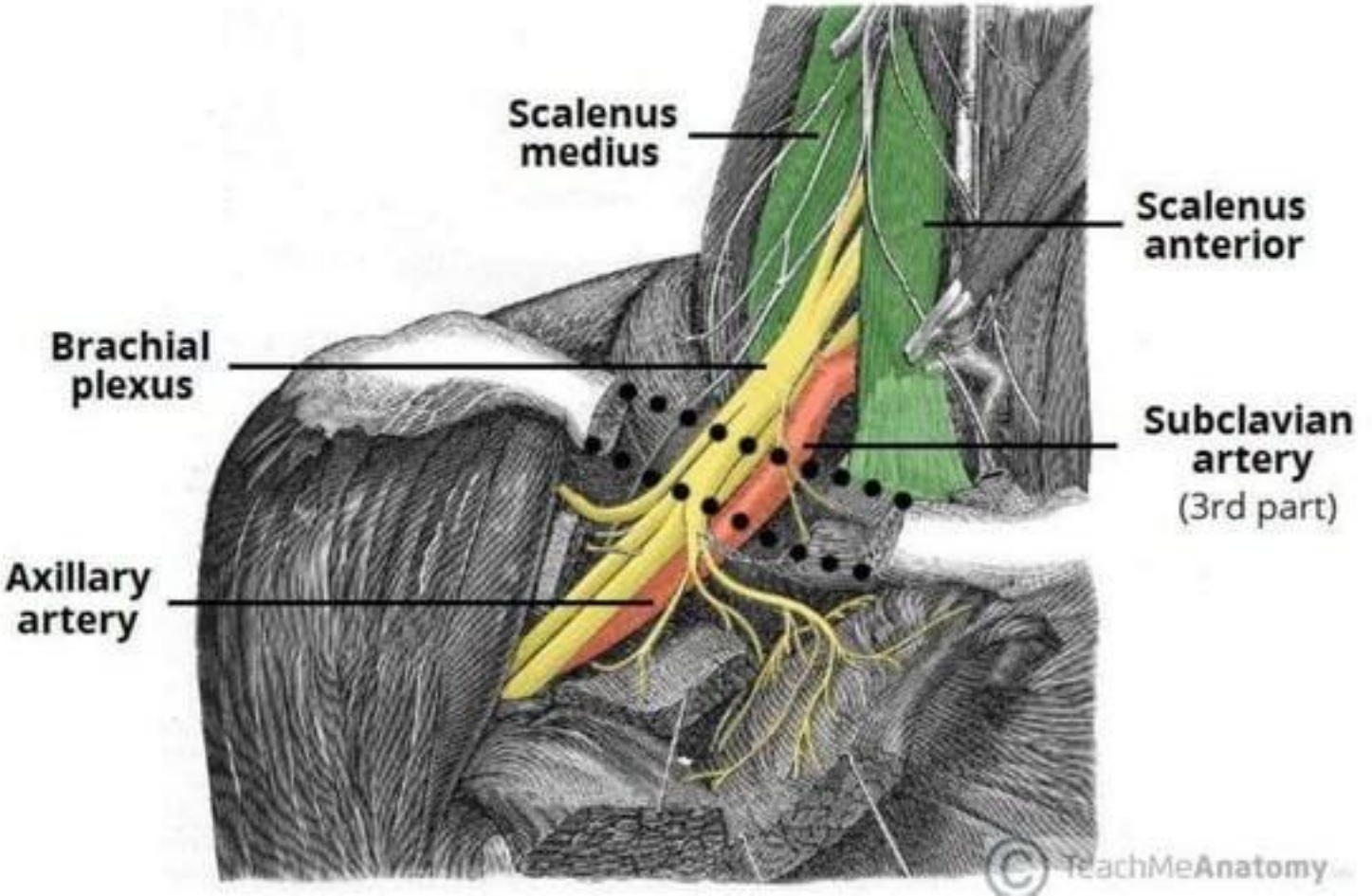
Scalenus medius
Scalenus anterior
Brachial plexus
Subclavian artery
(3rd part)
Axillary artery
© TeachMeAnatomy

Axillary Artery

- The axillary artery lies deep to the pectoralis minor and is enclosed in the axillary sheath (a fibrous layer that covers the artery and the three cords of the brachial plexus).

- The artery can be divided into three parts based on its position relative to the pectoralis minor muscle:

- First part – proximal to pectoralis minor
- Second part – posterior to pectoralis minor
- Third part – distal to pectoralis minor

Axillary Artery

First Part	Second Part	Third Part
Superior Thoracic Artery	Thoracoacromial artery Lateral thoracic artery	Subscapular artery Anterior Circumflex Humeral artery Posterior circumflex Humeral Artery

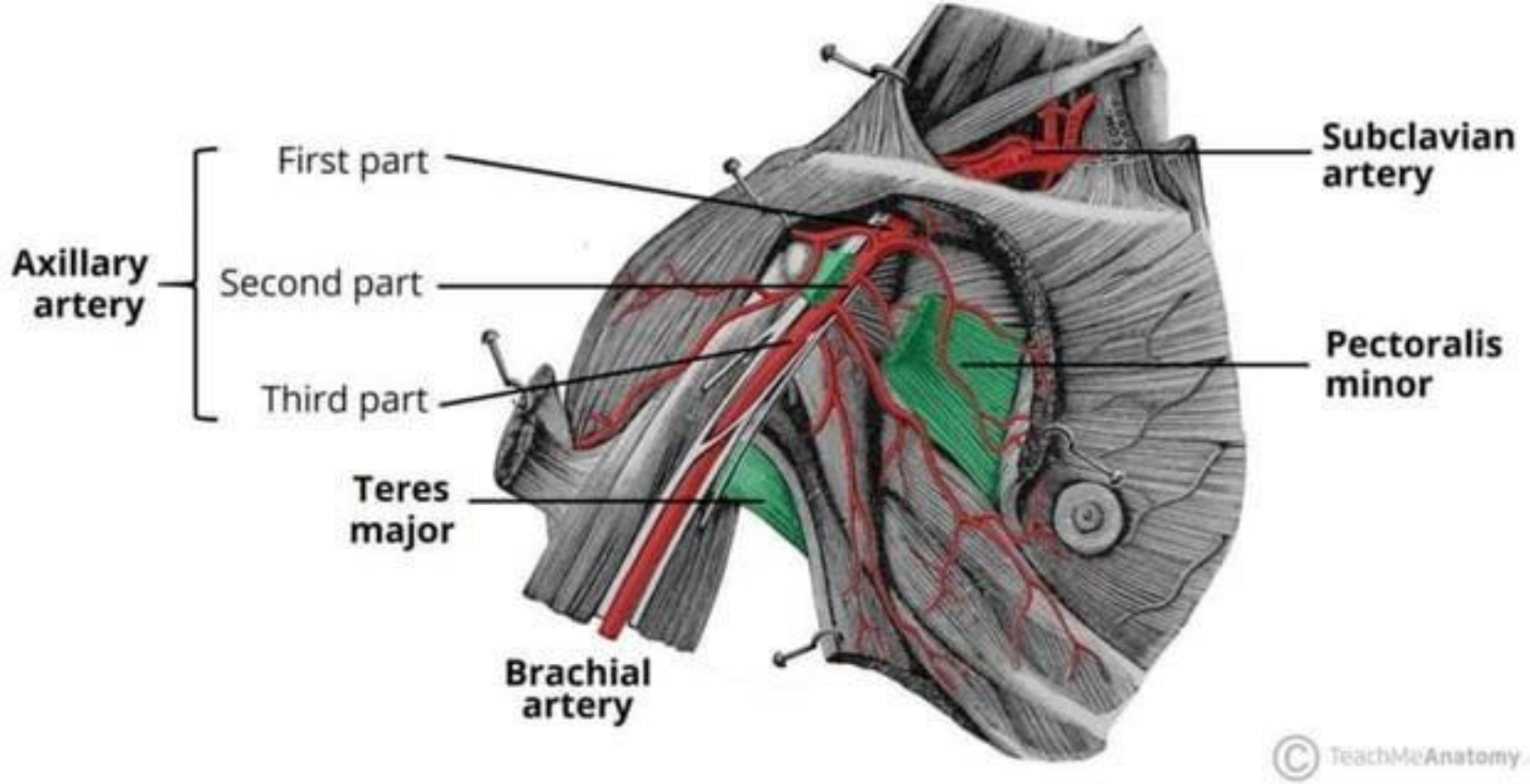
Axillary artery
First part
Second part
Third part
Subclavian artery
Pectoralis minor
Teres major
Brachial artery
© TeachMeAnatomy

Clinical Relevance: Axillary Artery Aneurysm

- An axillary artery aneurysm is a dilation of the vessel to more than twice its original size. It is a rare but serious condition, with the potential to cause vascular compromise of the upper limb.

- The dilated portion of the axillary artery can compress the brachial plexus, producing neurological symptoms such as paraesthesia and muscle weakness.

- The definitive treatment of an axillary artery aneurysm is surgical. It involves excising the aneurysm and reconstructing the vessel wall using a vascular graft.



Saccular Aneurysm



Fusiform Aneurysm



Ruptured Aneursym

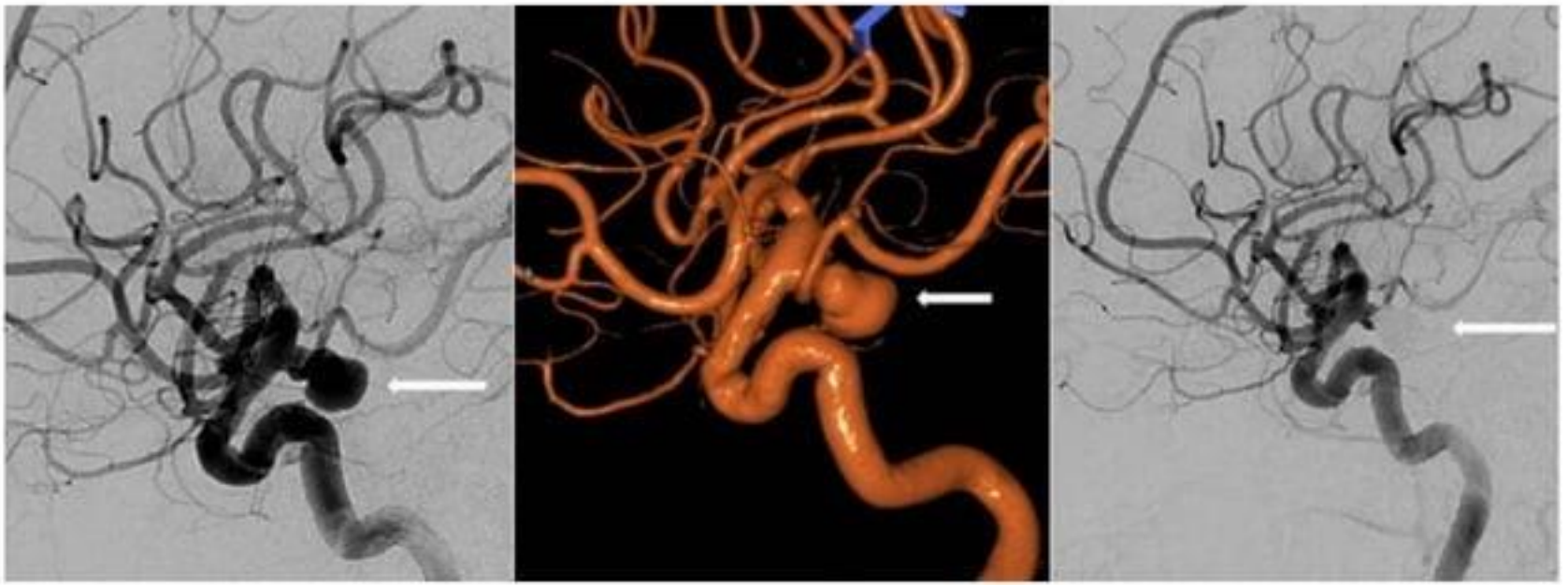

Brachial Artery

- The brachial artery is a continuation of the axillary artery past the lower border of the teres major.
- It is the main supply of blood for the arm.
- Immediately distal to the teres major, the brachial artery gives rise to the profunda brachii (deep artery), which travels with the radial nerve in the radial groove of the humerus and supplies structures in the posterior aspect of the upper arm (e.g. triceps brachii).
- The brachial artery proper descends down the arm.
- As it moves through the cubital fossa, underneath the bicipital aponeurosis, the brachial artery terminates by bifurcating into the radial and ulnar arteries

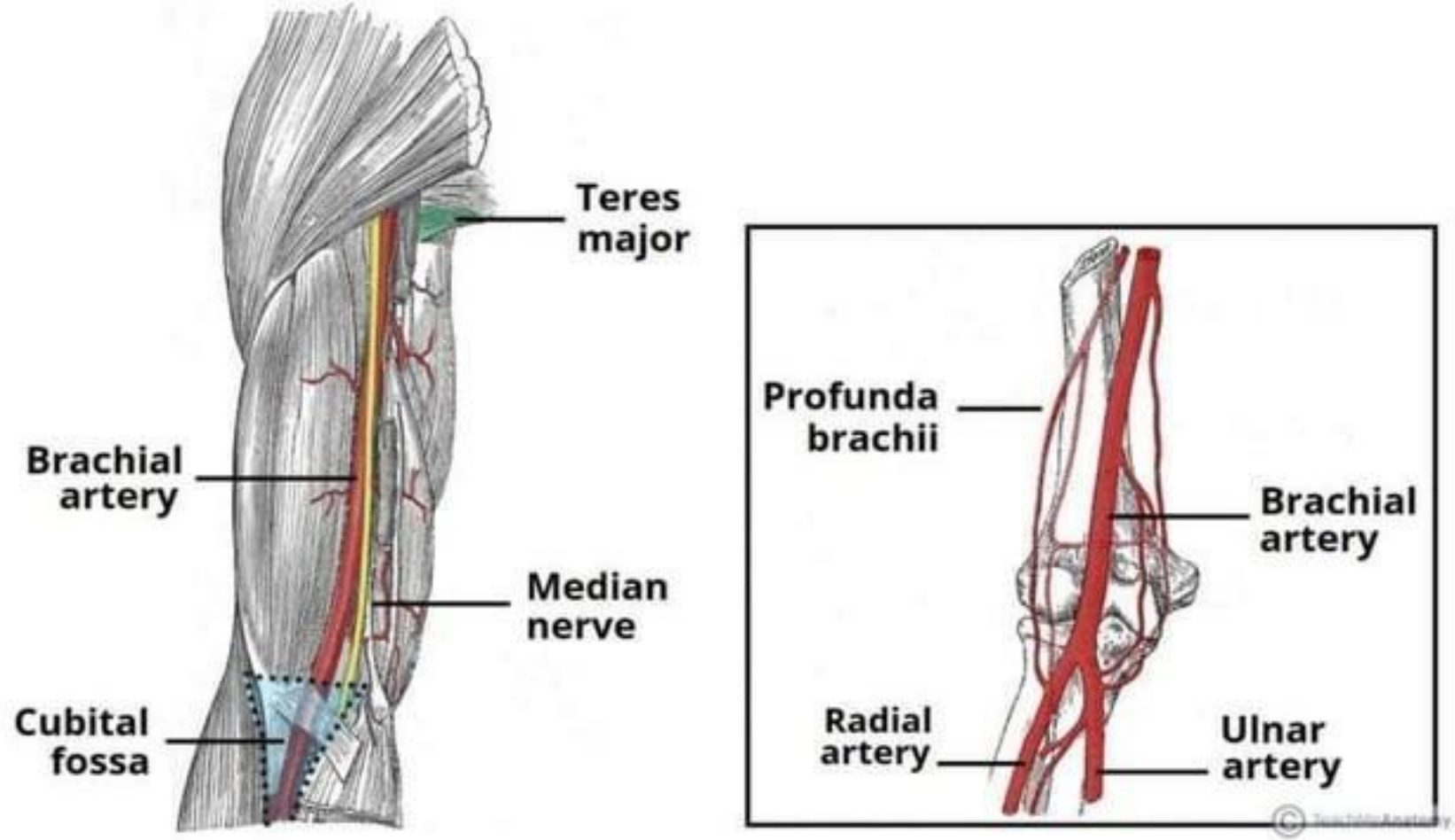
Teres major
Brachial artery
Median nerve
Cubital fossa
Profunda brachii
Brachial artery
Radial artery
Ulnar artery

Blood Pressure Measurement

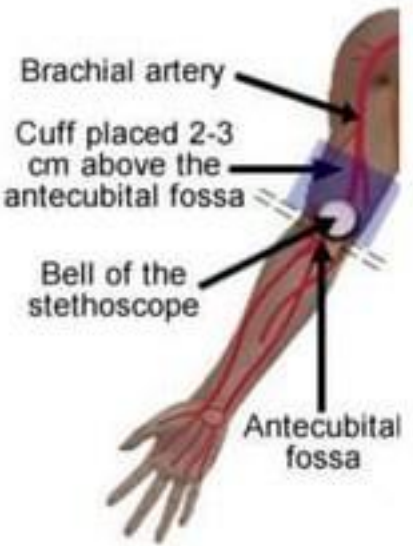

WSU Health Care Sciences


LEFT ARM
RIGHT ARM

Brachial Pulse



Clinical Relevance: Occlusion or Laceration of the Brachial Artery

- The arm has relatively good anastomotic supply. This means that it is well protected from ischaemia in cases of temporary or partial occlusion of the brachial artery.

- However, if the artery is completely occluded (or severed), the resulting ischaemia can cause necrosis of forearm muscles. Muscle fibres are replaced by scar tissue and shorten considerably – this can cause a characteristic flexion deformity, called Volkmann's ischaemic contracture.



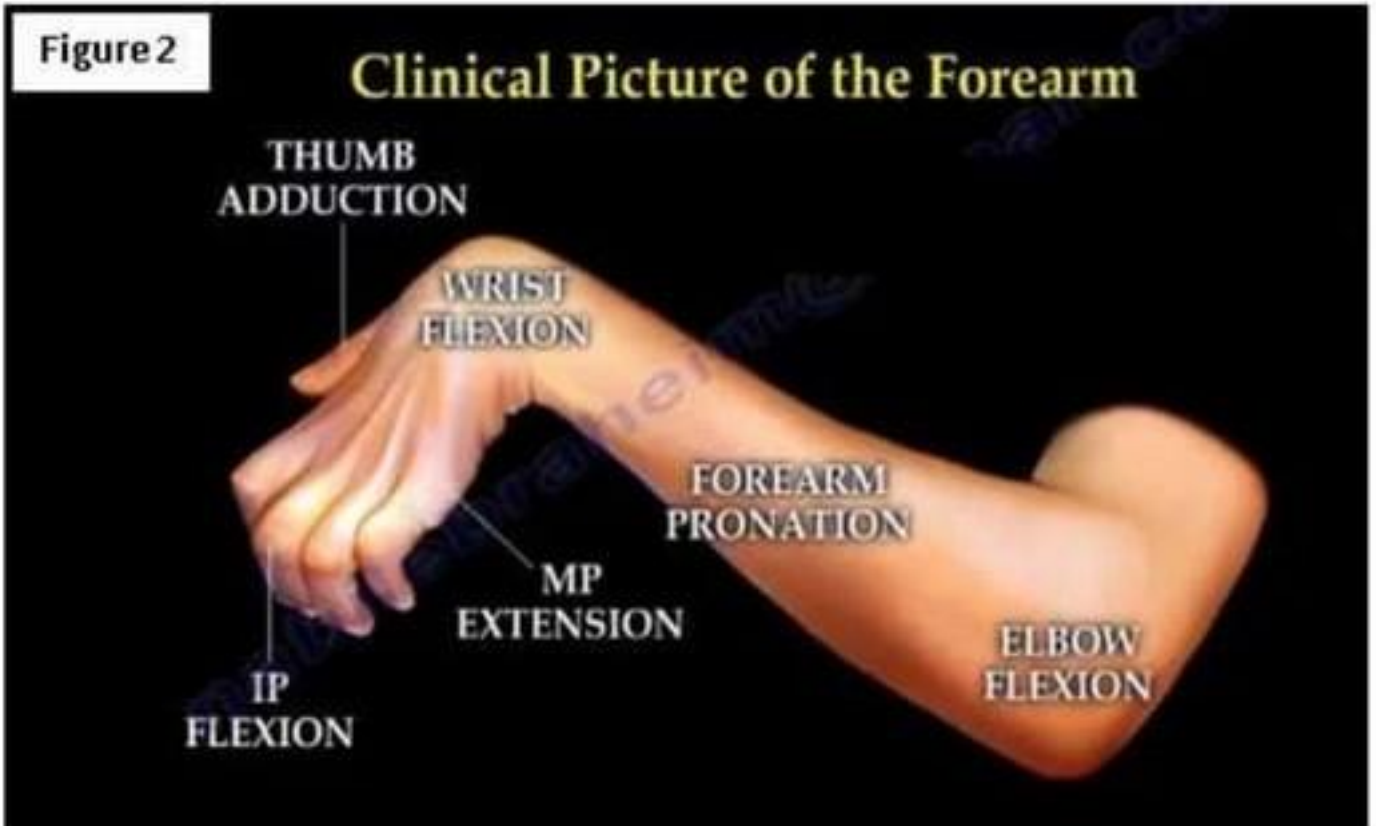
Figure 2
Clinical Picture of the Forearm
THUMB ADDUCTION
WRIST FLEXION
FOREARM PRONATION
MP EXTENSION
ELBOW FLEXION
IP FLEXION

Radial & Ulnar Arteries

- Formed by the bifurcation of the brachial artery within the cubital fossa:
- Radial artery – supplies the posterolateral aspect of the forearm. It contributes to anastomotic networks surrounding the elbow joint and carpal bones.
- The radial pulse can be palpated in the distal forearm, immediately lateral to the prominent tendon of the flexor carpi radialis muscle.
- Ulnar artery – supplies the anteromedial aspect of the forearm. It contributes to an anastomotic network surrounding the elbow joint.
- Also gives rise to the anterior and posterior interosseous arteries, which supply deeper structures in the forearm.
- These two arteries anastomose in the hand by forming two arches – the superficial palmar arch, and the deep palmar arch

Arterial Arches of Palm

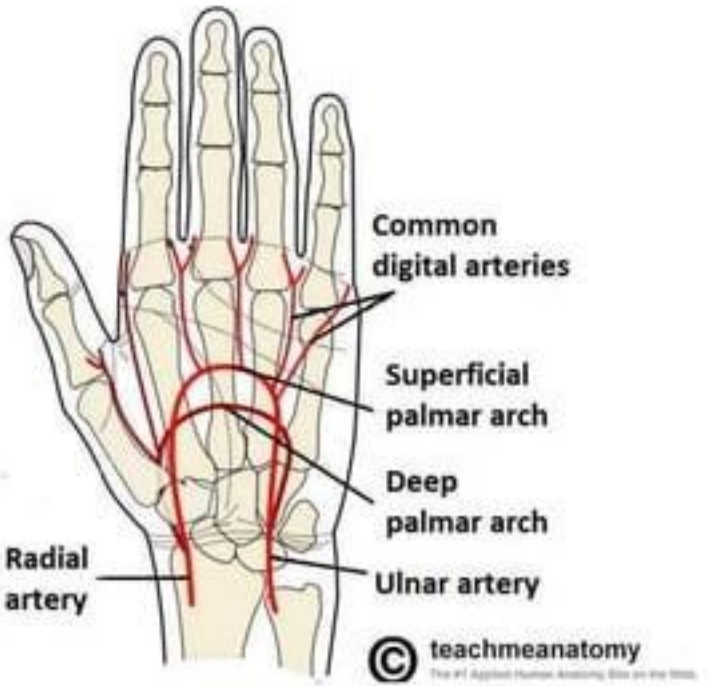

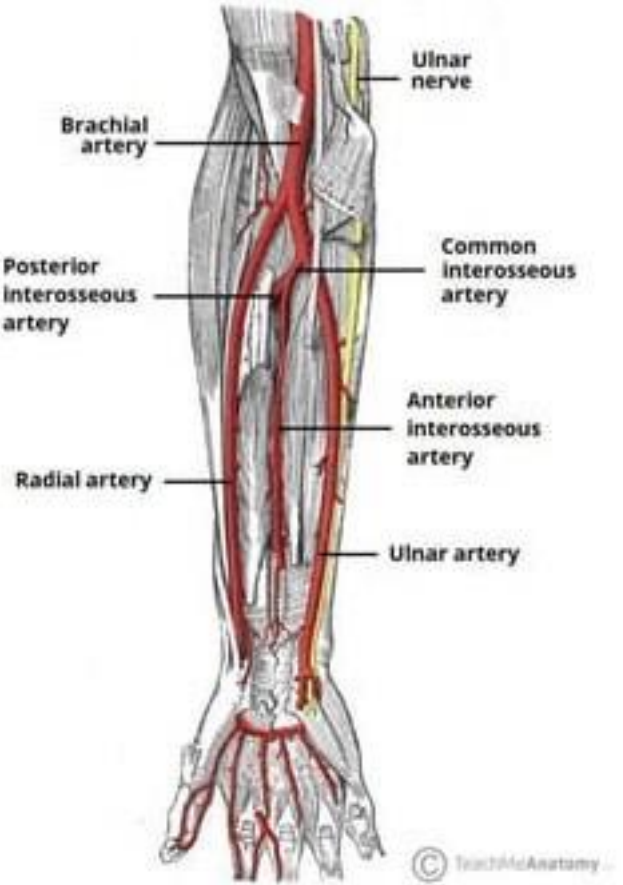
Ulnar nerve
Brachial artery
Posterior interosseous artery
Common interosseous artery
Anterior interosseous artery
Radial artery
Ulnar artery
© TeachMeAnatomy

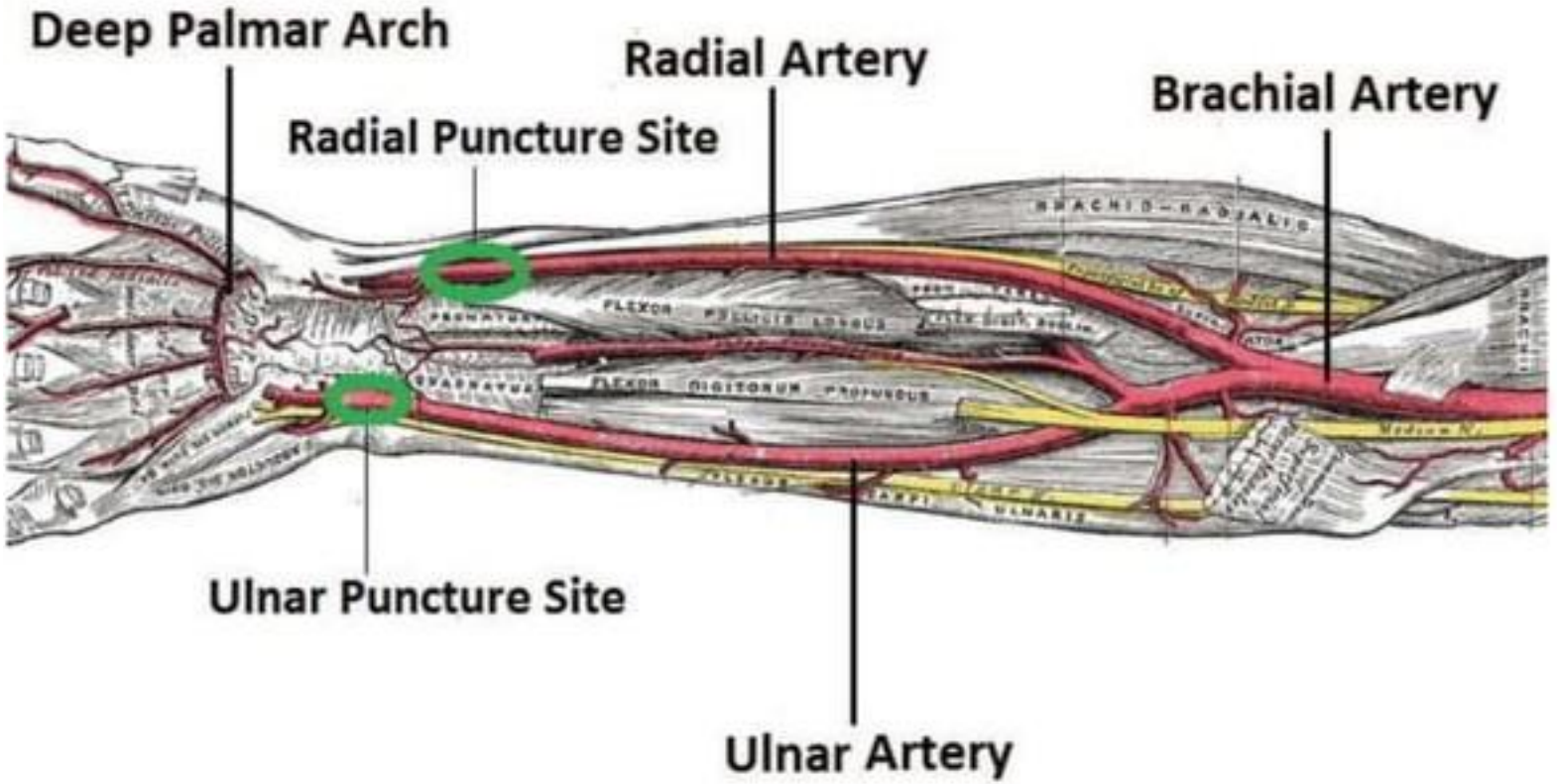
Deep Palmar Arch
Radial Artery
Brachial Artery
Radial Puncture Site
Ulnar Puncture Site
Ulnar Artery

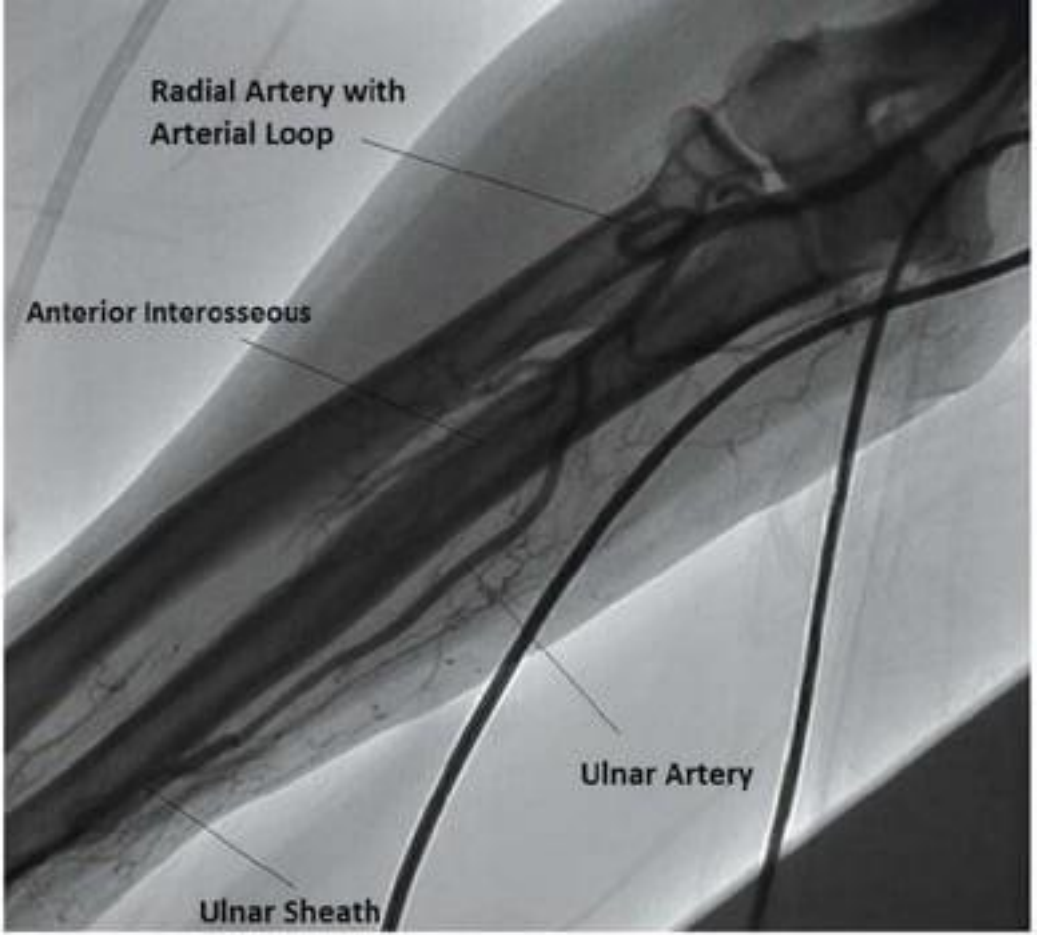
Radial Artery with
Arterial Loop
Anterior Interosseous
Ulnar Artery
Ulnar Sheath

Radial Pulse

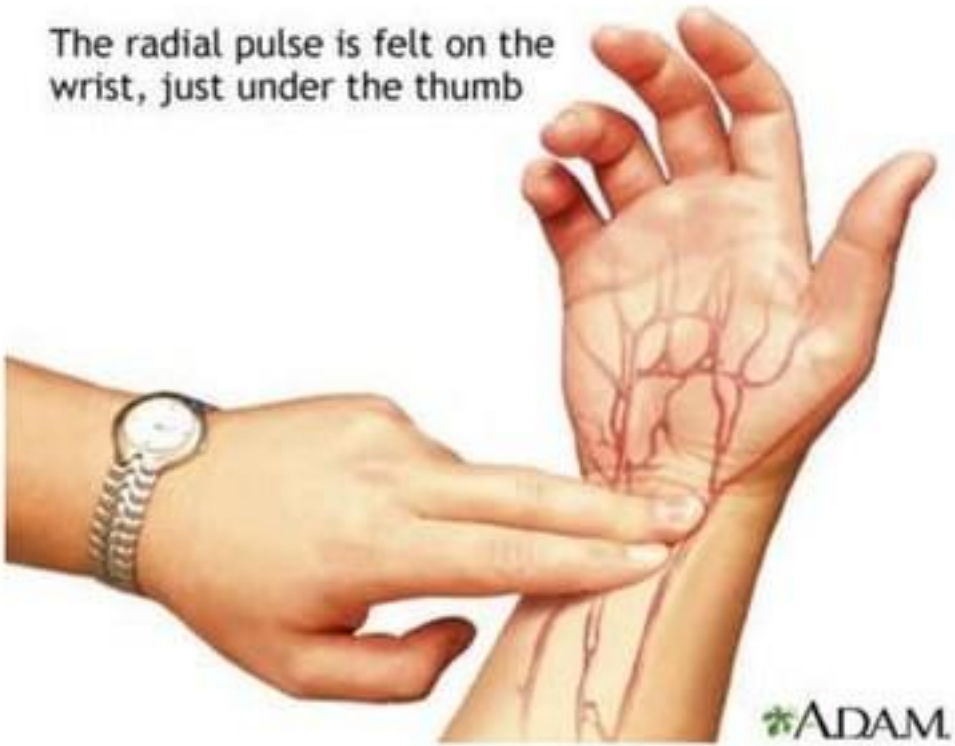

Veins of Upper Limb

- The venous system of the upper limb drains deoxygenated blood from the arm, forearm and hand.
- It can be subdivided into the superficial system and the deep system.

Superficial Veins

Basilic Vein:

- The basilic vein originates from the dorsal venous network of the hand and ascends the medial aspect of the upper limb.
- At the border of the teres major, the vein moves deep into the arm. Here, it combines with the brachial veins from the deep venous system to form the axillary vein.

Cephalic Vein:

- The cephalic vein also arises from the dorsal venous network of the hand. It ascends the antero-lateral aspect of the upper limb, passing anteriorly at the elbow.
- At the shoulder, the cephalic vein travels between the deltoid and pectoralis major muscles (known as the deltopectoral groove), and enters the axilla region via the clavipectoral triangle. Within the axilla, the cephalic vein empties into axillary vein.

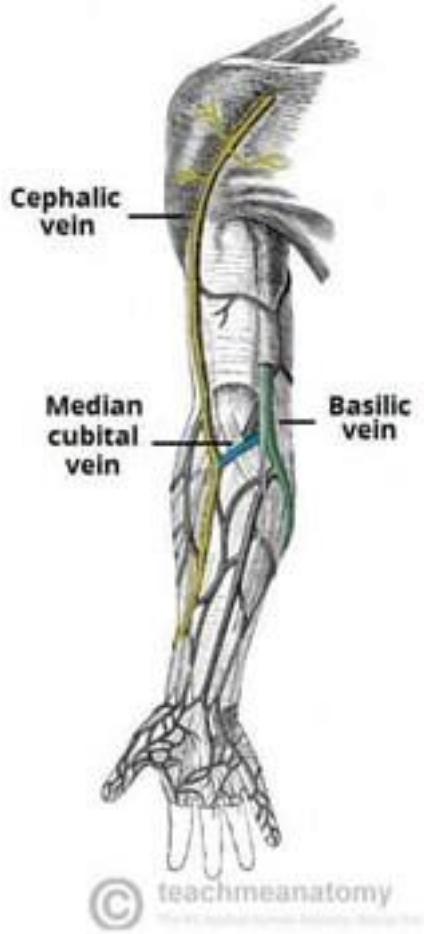
Cephalic vein
Median cubital vein
Basilic vein
© teachmeanatomy

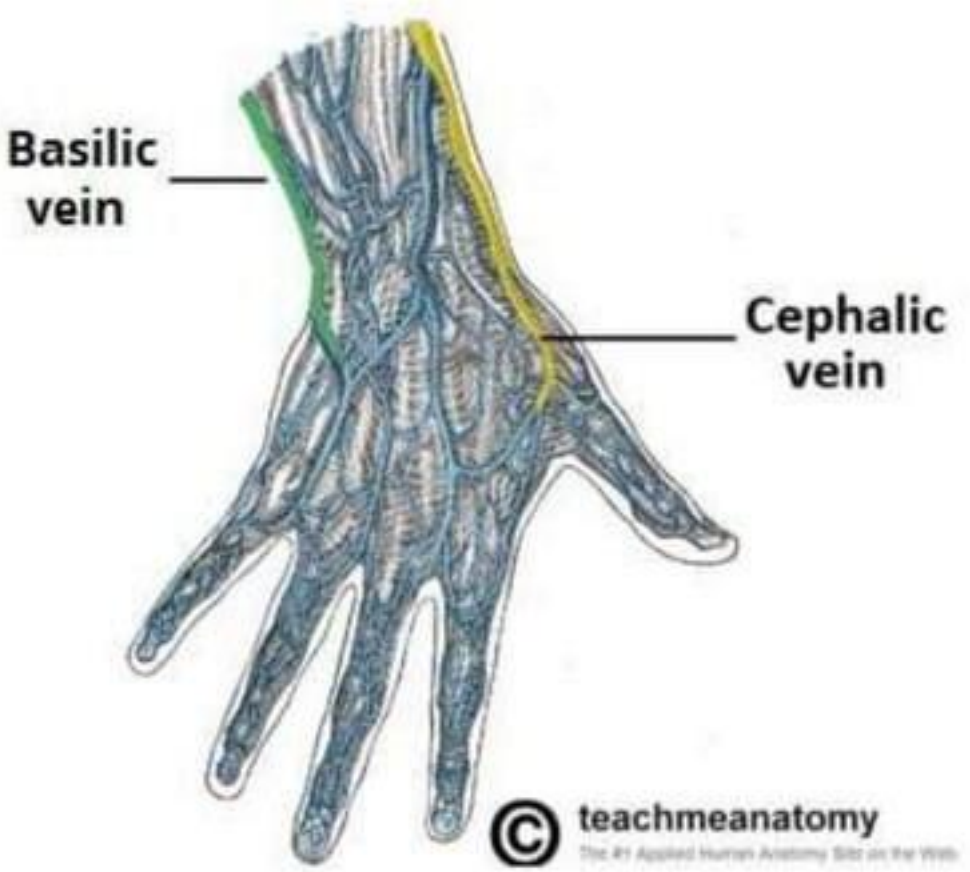
Basilic vein
Cephalic vein
© teachmeanatomy

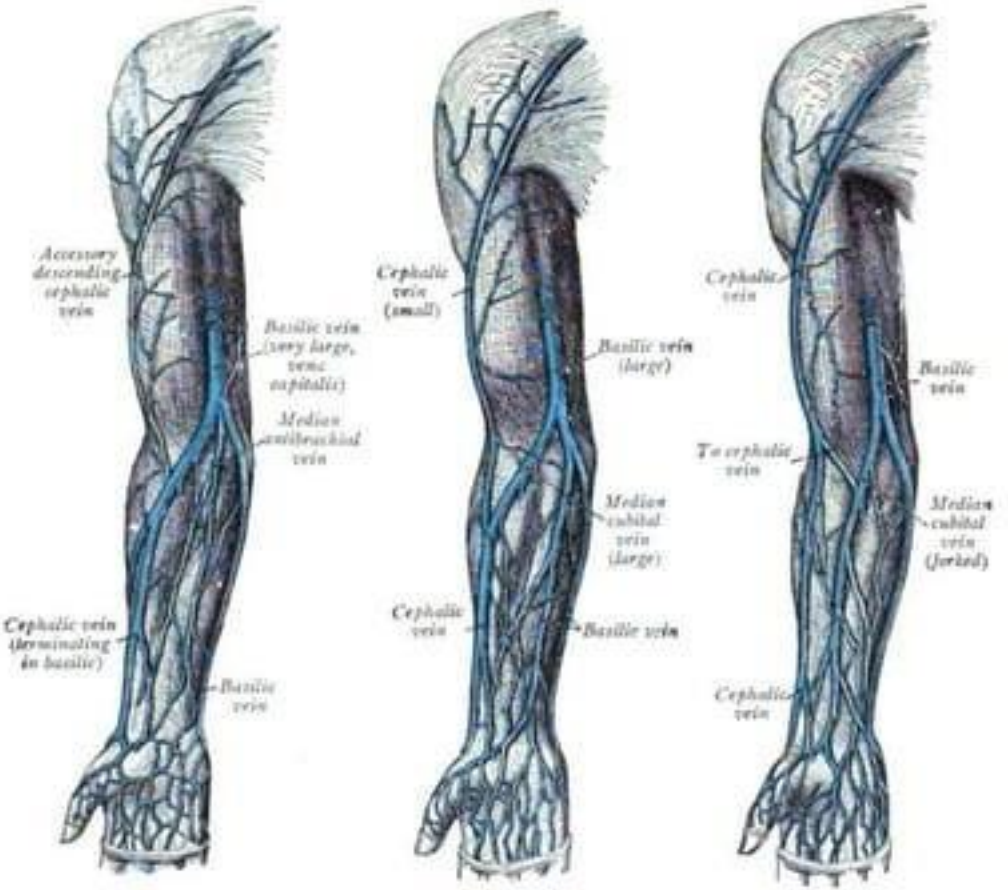

FIG. 507.—The most frequent variations in the veins of the forearm (schematic).

Median Cubital Vein

This provides an excellent site for Mary to draw blood, called venipuncture techniques. Venipuncture involves the collection of blood for purposes such as lab analysis, donation, or testing for drugs or alcohol.

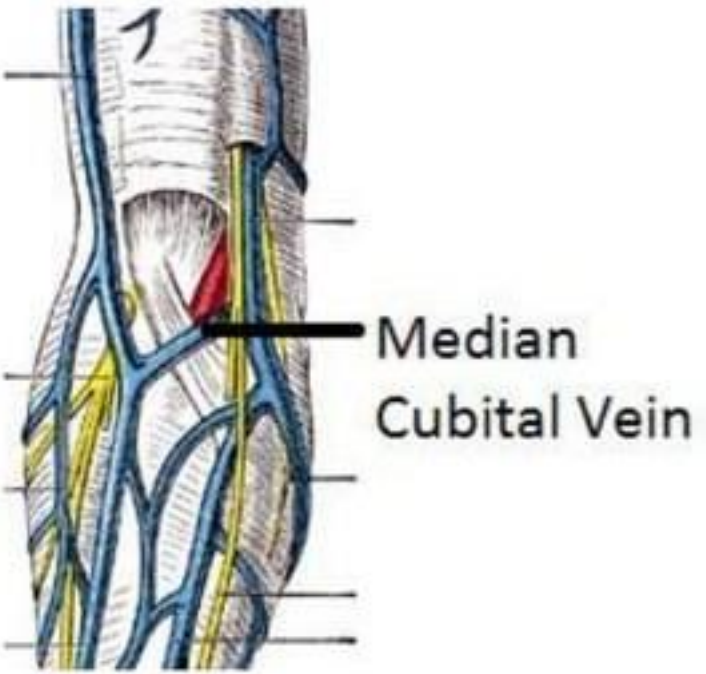

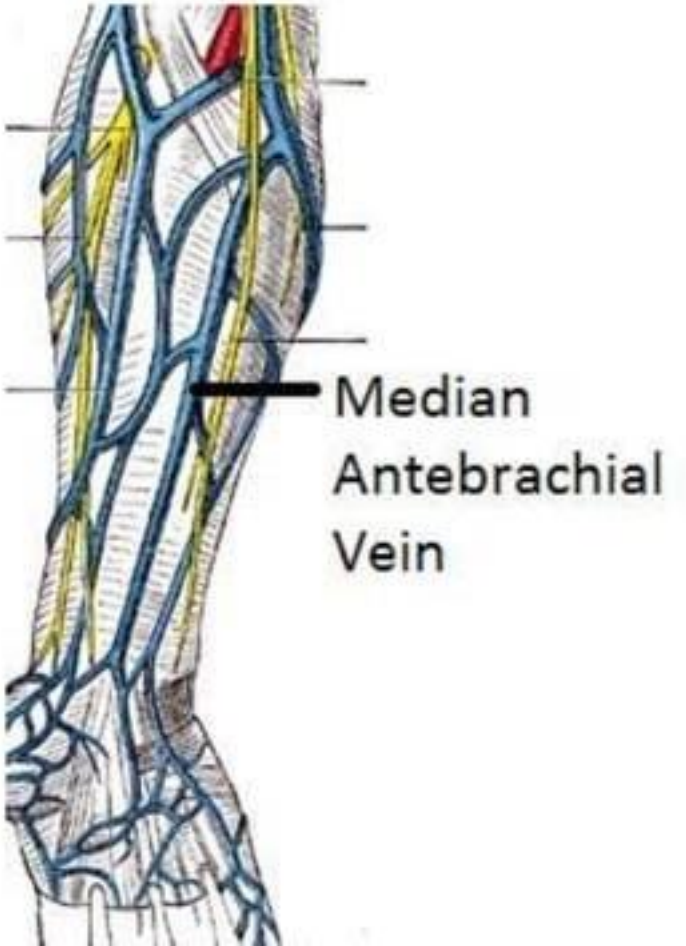
Median
Antebrachial
Vein

Deep Veins

- The deep venous system of the upper limb is situated underneath the deep fascia. It is formed by paired veins, which accompany and lie either side of an artery. In the upper extremity, the deep veins share the name of the artery they accompany.

- The brachial veins are the largest in size, and are situated either side of the brachial artery. The pulsations of the brachial artery assist the venous return. Veins that are structured in this way are known as vena comitantes.

- Perforating veins run between the deep and superficial veins of the upper limb, connecting the two systems

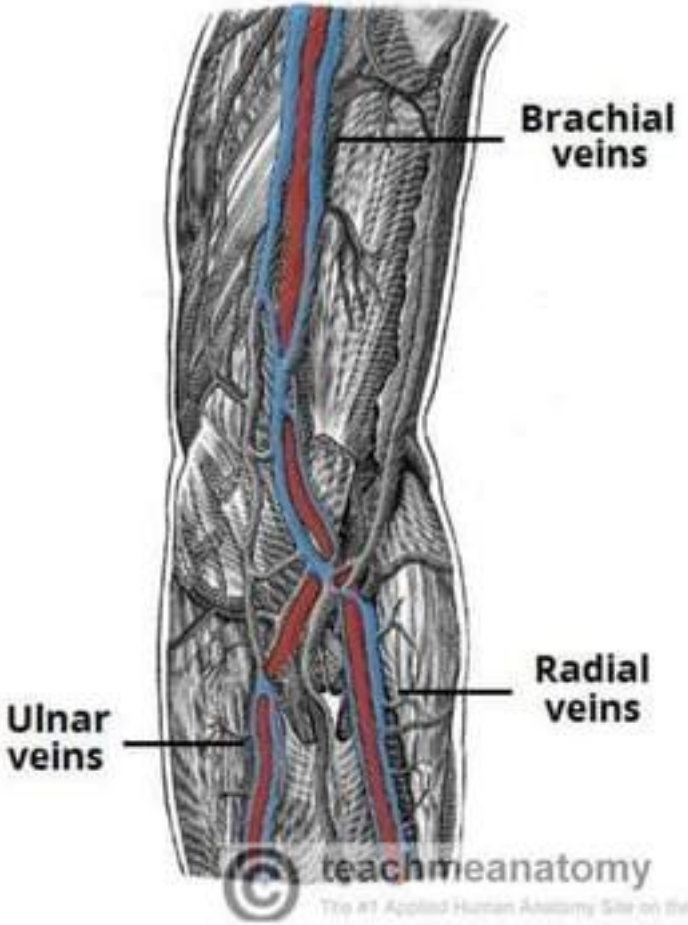
Brachial veins
Radial veins
Ulnar veins
teachmeanatomy

Clinical Relevance: Venepuncture

- Venepuncture is the practice of obtaining intravenous access. This is usually for the purpose of providing intravenous therapy (e.g. fluids, medications) or for obtaining a blood sample.

- The median cubital vein is a common site of venepuncture. It is a superficial vein that is located anteriorly to the cubital fossa region. It is thought to be fixed in place by perforating veins, which arise from the deep venous system and pierce the bicipital aponeurosis.

- Its ease of access, fixed position and superficial position make the median cubital vein a good site for venepuncture in many individuals.



Thank You