Computed Tomography

- Coronary CTA scanningPrepared By: BY AHMED JASEM ABASS
- MSC of Medical Imaging

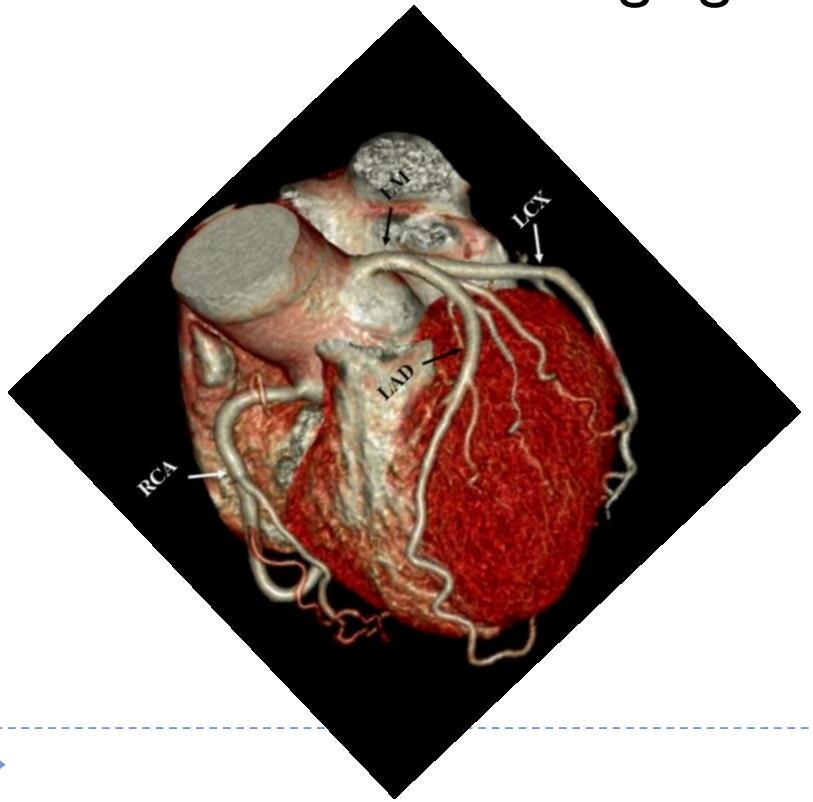





Coronary CTA scanning



- Coronary computed tomography angiography (also called coronary CT angiography or CCTA) uses an injection of iodine-containing contrast material and CT scanning to examine the arteries that supply blood to the heart and determine whether they have been narrowed. The images generated during a CT scan can be reformatted to create three-dimensional (3D) images that may be viewed on a monitor, printed on film or by a 3D printer, or transferred to electronic media.



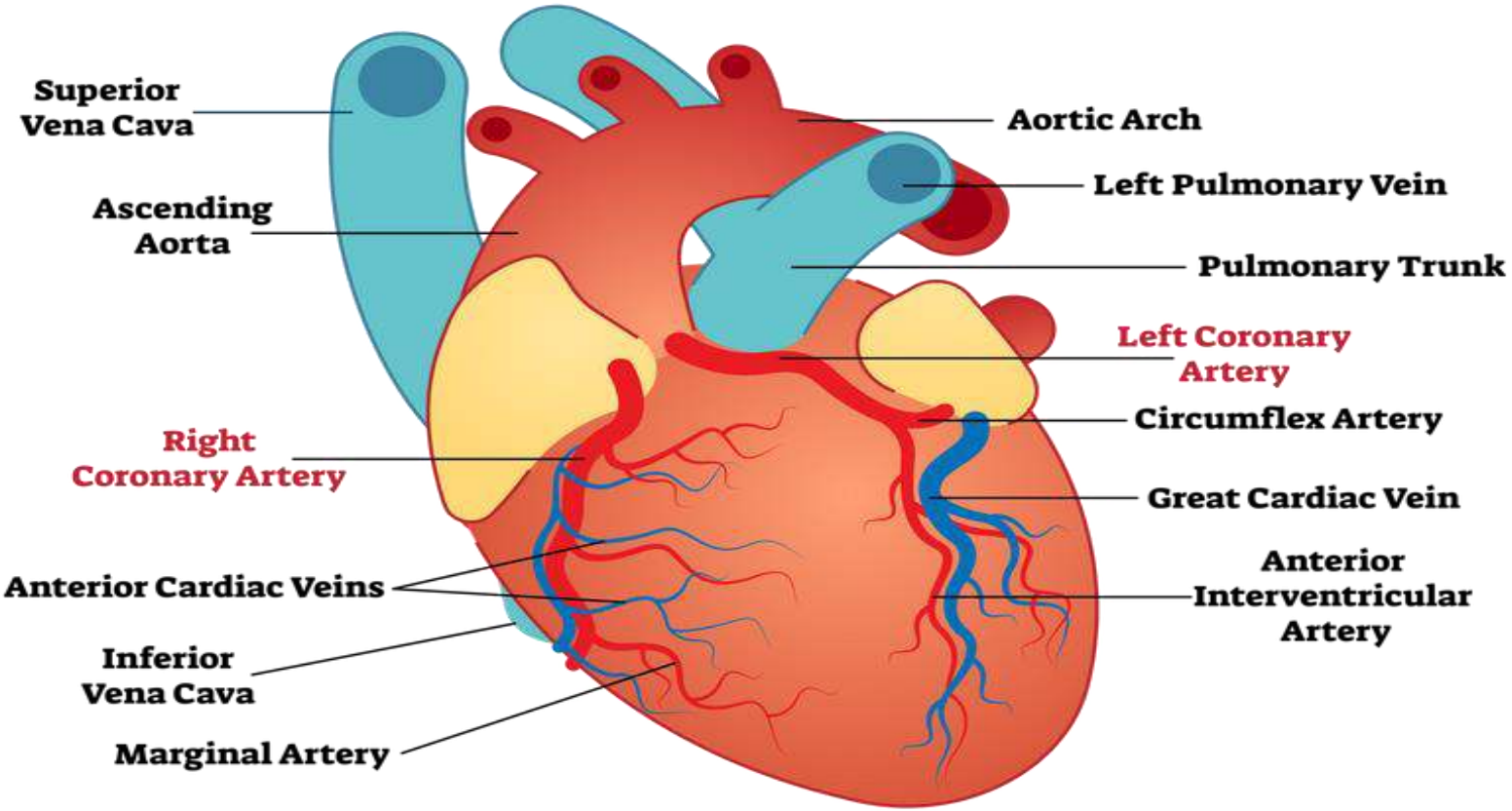
Superior Vena Cava
Aortic Arch
Left Pulmonary Vein
Ascending Aorta
Pulmonary Trunk
Left Coronary Artery
Circumflex Artery
Right Coronary Artery
Great Cardiac Vein
Anterior Cardiac Veins
Anterior Interventricular Artery
Inferior Vena Cava
Marginal Artery

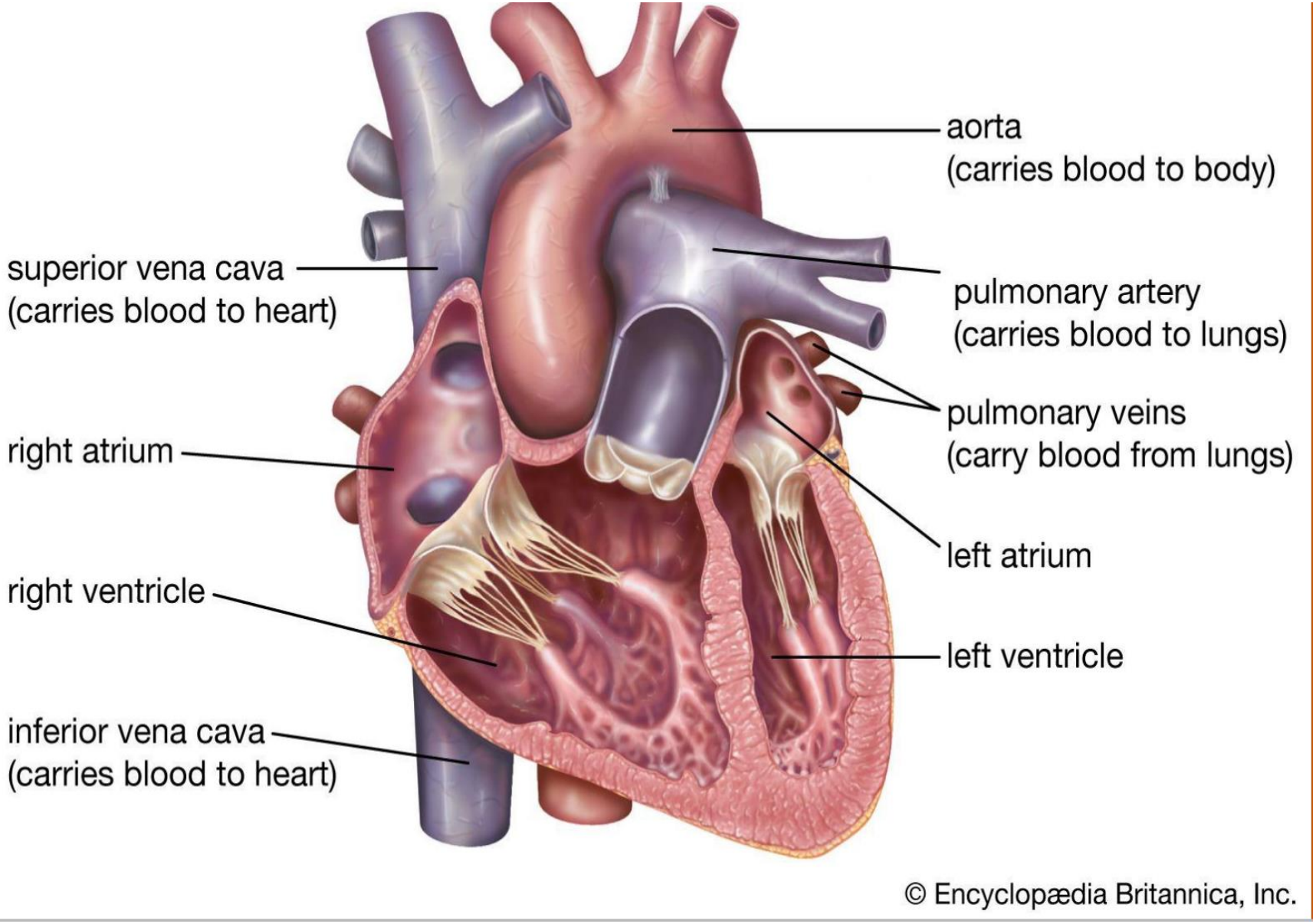
aorta
(carries blood to body)
superior vena cava
(carries blood to heart)
pulmonary artery
(carries blood to lungs)
pulmonary veins
(carry blood from lungs)
right atrium
left atrium
right ventricle
left ventricle
inferior vena cava
(carries blood to heart)
© Encyclopædia Britannica, Inc.

Patient Preparation Prior to CT

1) Wear comfortable, loose-fitting clothing to your exam. You may need to change into a gown for the procedure.
2) Metal objects, including jewelry, eyeglasses, dentures, and hairpins, may affect the CT images.
3) Checking contraindications for CTA.
4) No food 3-4 hours before the scan.
5) No caffein for 12 hours.
6) Instruction on how to breath.
7) An electrocardiogram signal needs to be acquired.
8) Heart rate control.
9) If the have breast feeding stopped until all contrast material has cleared from your body (about 24 hours after the test)
10) If the pt have metformin medication stopped before and after procedure 48 h.



Patient Preparation - Heart Rate

- IV Beta Blockade (preferred)
  - 2.5 – 30 mg Metoprolol
    - Titrate to heart rate of 55-60
    - Monitor BP while giving metoprolol
  - If asthmatic, consult physician
    - No more than 10mg metoprolol
    - Consider calcium channel blockers
      - Diltiazem (bolus 0.25mg/kg)
- Oral Beta Blocker
  - 50 – 100 mg Metoprolol 1 hour prior to examination



Cardiac Indications

1) Emergency evaluation of acute chest pain.
2) Cardiac evaluation of a patient with chest pain syndrome (e.g. anginal equivalent, angina), who is not a candidate for cardiac catheterization
3) Management of a symptomatic patient with known coronary artery disease (e.g., post-stent) when the results of the MDCT may guide the decision for repeat invasive intervention
4) Assessment of suspected congenital anomalies of coronary circulation 1- Congenital coronary artery anomalies.2- Coronary artery disease. (Coronary atherosclerosis plaque evaluation). 3- Visualization of cardiac veins.
5) Unclear findings after invasive coronary angiography (ICA).



Contraindications:

- 1- Factors leading to potentially non-diagnostic scans (Inability to
- cooperate) (e.g. breath-hold instructions and arm elevation).
- 2- Contraindications against iodinated contrast media, nitrates, and β-blocker.
- 3- Pregnancy or uncertain pregnancy status in premenopausal women.



Limitations of Coronary CTA

- The technologist may ask you to hold your breath during the scanning. Any motion, including breathing and body movements, can lead to artifacts on the images.
- Coronary Motion
- Slab artifacts
  - Ventricular Ectopy
  - Ventilatory Motion
- Calcium
- Stents



Limitations of Coronary CTA

Slab Artifact

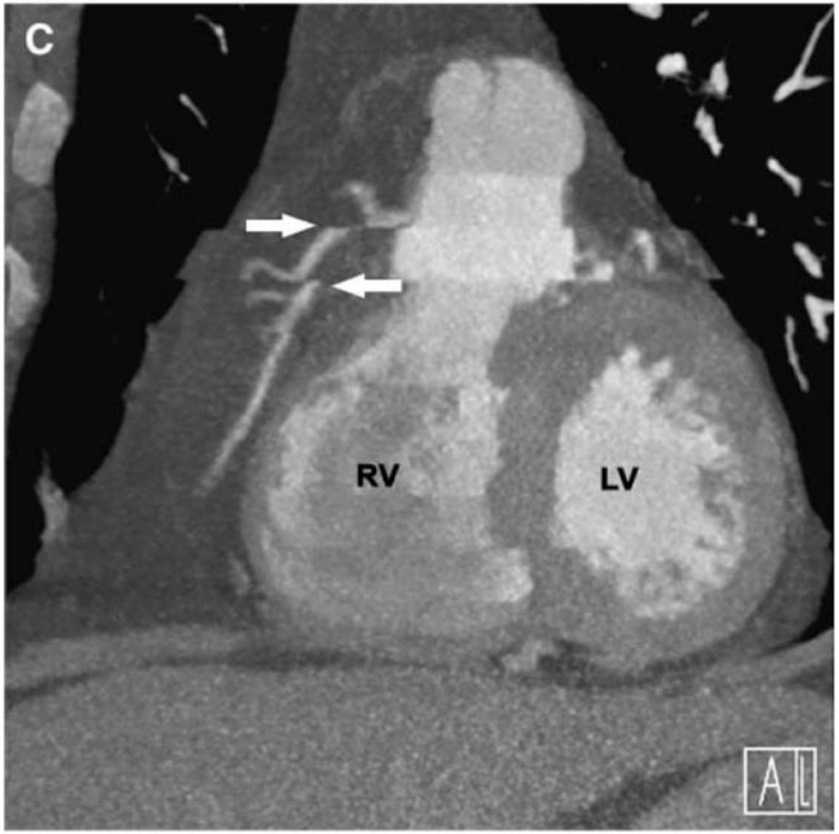

Coronary Motion

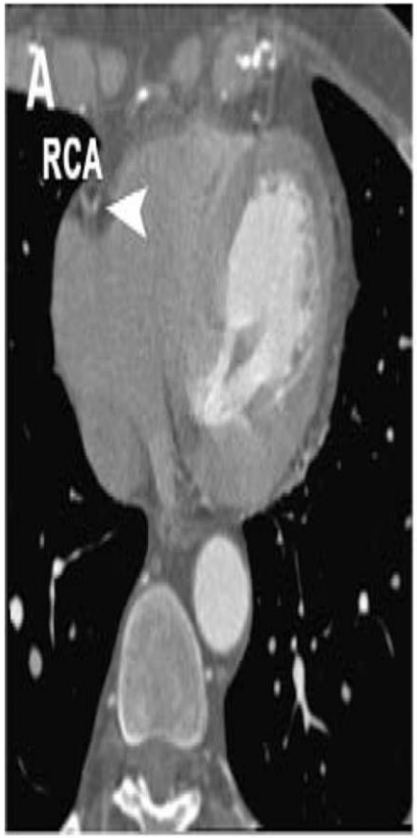



Limitations of Coronary CTA

Stents

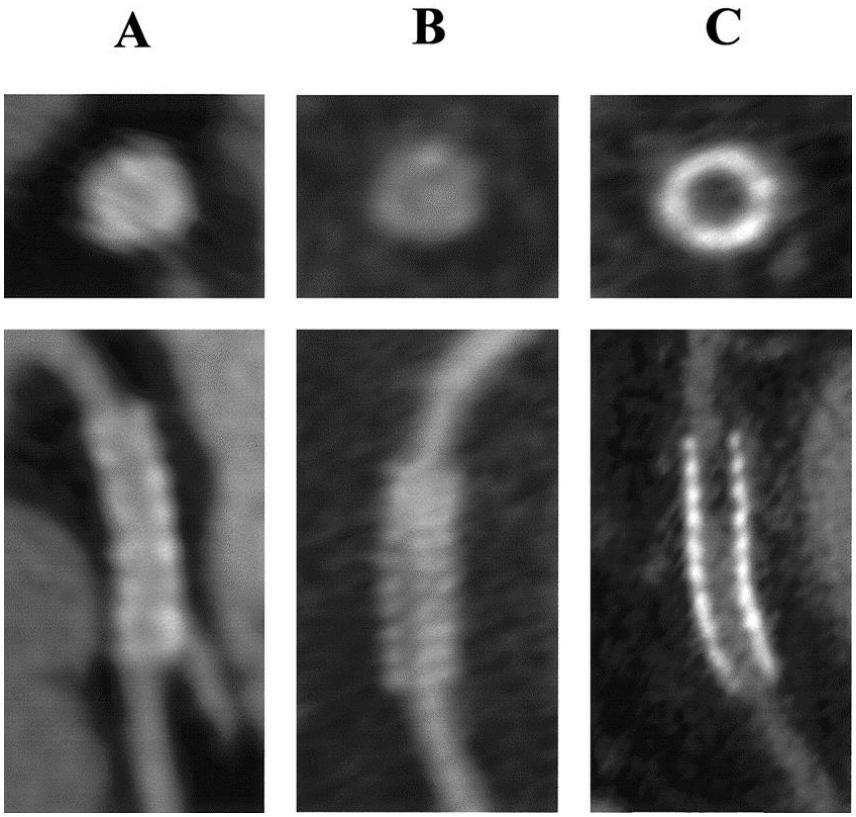

Stents

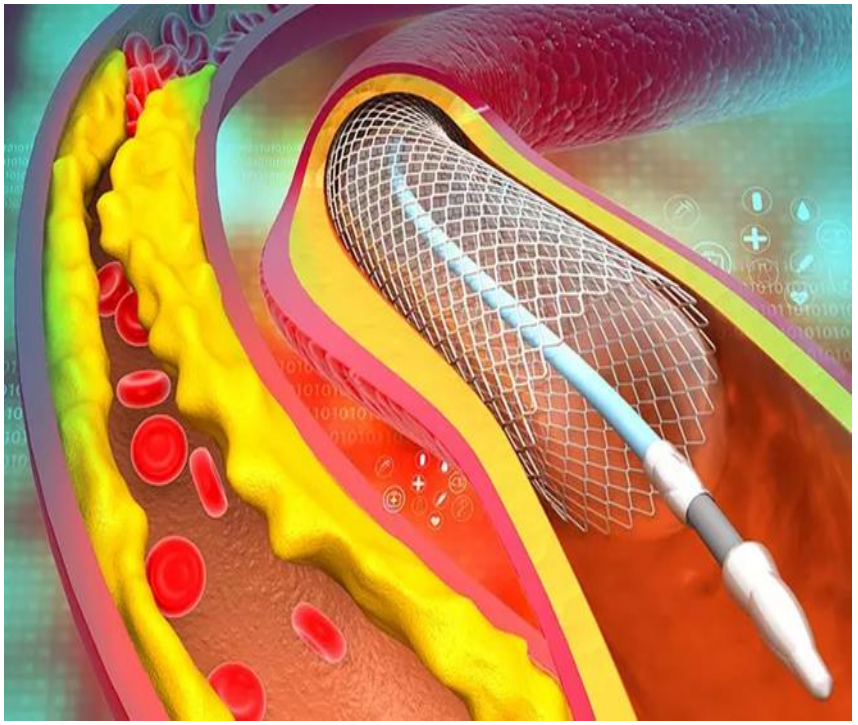

Limitations of Coronary CTA

Calcium

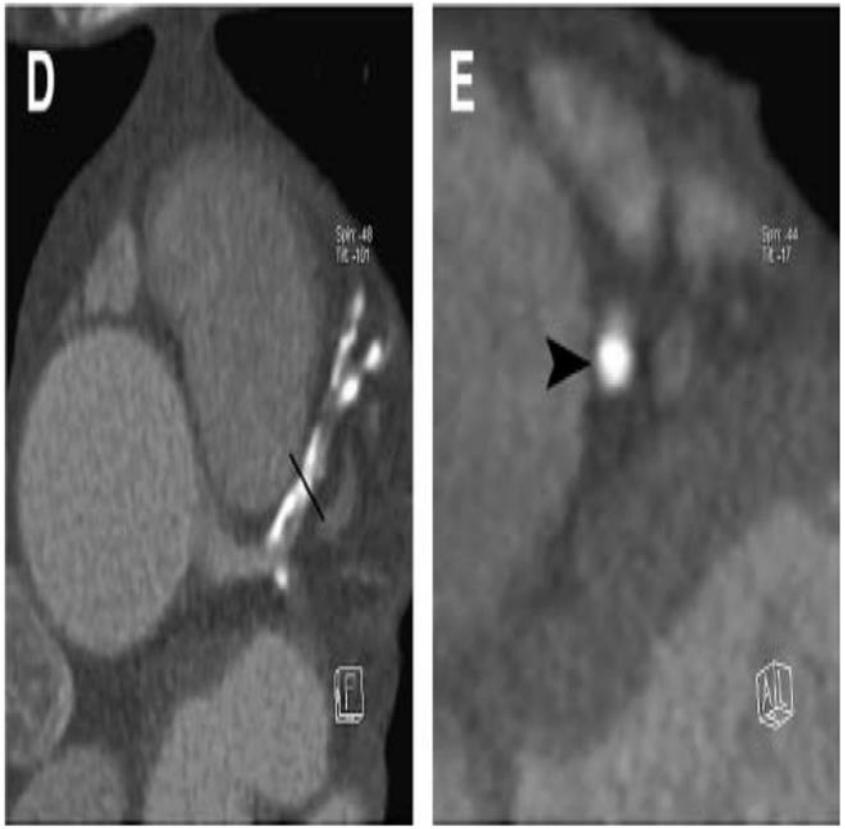

Technique: -

- 1- Patient position: - Supine with both arms above their heads.
- 2- ECG placement.
- 3- Acquisition: -
- A-Prospective ECG-gated acquisition.
- B- Retrospective ECG-gated acquisition.
- 4- Tube potential: - 120kVp.
- 5- Tube current: - Use automated current adjustment mode.
- 6-Scout: - Pulmonary apices to below the heart.
- 7- Scan direction: - Craniocaudal.
- 8- Contrast injection consideration: -
- - Contrast agent with high iodine concentration (350mg iodine/mL).
- - Contrast timing: - test bolus.
- - Flow rate 5-6ml /s



Scan Start Position

- Scan extent: - From the carina to below the heart.



Scan Ending Position

- Note overlap of heart & diaphragm
- Observe contour of heart
- Extend scan ~2cm below the caudal extent of the heart
- Position of heart will change with inspiratory effort



Center the Scan on the Heart

- Maximize spatial resolution for coronaries
  - CT resolution is greatest in the center of scan field
  - Set left-right position on AP scout view
  - Move table up-down to center on aortic root and Left ventricle

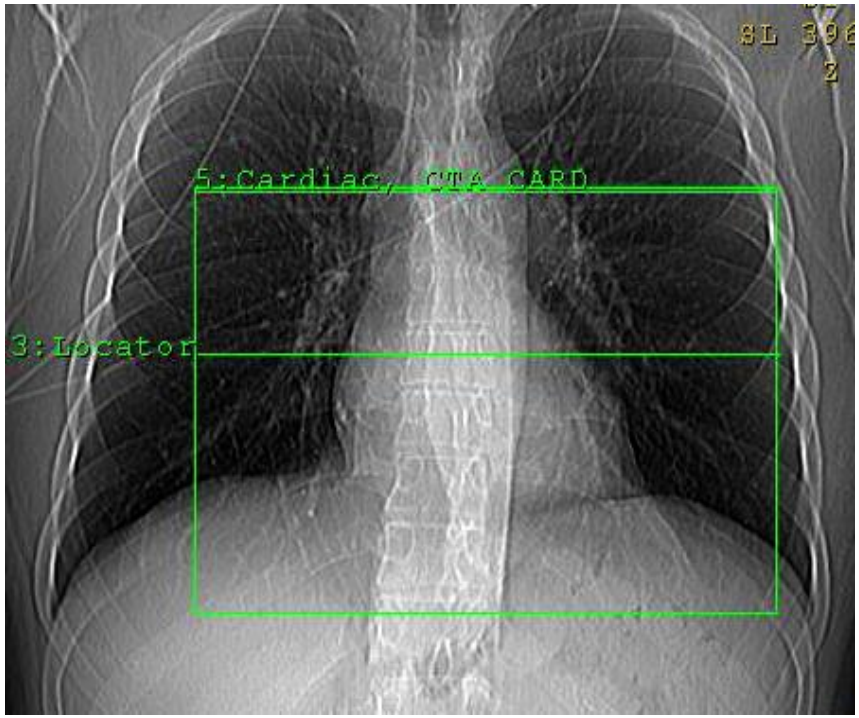

Image Reconstruction

- Reconstruction slice thickness
  - 3mm for function
  - 0.5-0.8mm for coronary arteries
- Reconstruction kernel
  - Sharper kernel: noisier image, but may be required to visualize coronary lumen with stents and calcified vessels



Benefits

- CT examinations are fast and simple.
- CCTA is not invasive. An alternative test, cardiac catheterization with a coronary angiogram.
- A major advantage of CT is that it is able to view bone, soft tissue and blood vessels all at the same time.



Risks

1. If contrast material leaks out from the vessel being injected and spreads under the skin where the IV is placed, skin damage or damage to blood vessels and nerves, though unlikely, can result. If you feel any pain in your arm at the location of the IV during contrast material injection, you should immediately inform the technologist.
2. Renal failure.
3. The radiation dose for this procedure varies.




Thank You!
shawnliv.com