Computed Tomography

- CT pulmonary angiogram:
  BY AHMED JASEM ABASS
- MSC of Medical Imaging



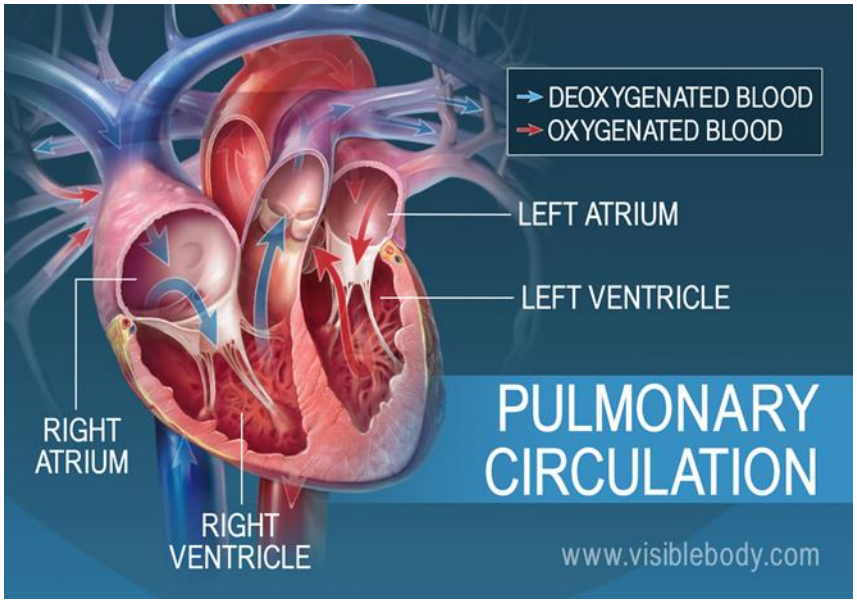



ANATOMY

- The pulmonary arteries carry blood from the heart to the lungs. They are the only arteries that carry deoxygenated blood.

- Pulmonary artery begins at the base of the right ventricle.
- It is short and wide approximately 5 cm (2 inches) in length and 3 cm (1.2 inches) in diameter.
- It then branches into two pulmonary arteries (left and right), which deliver de-oxygenated blood to the corresponding lung.



ANATOMY

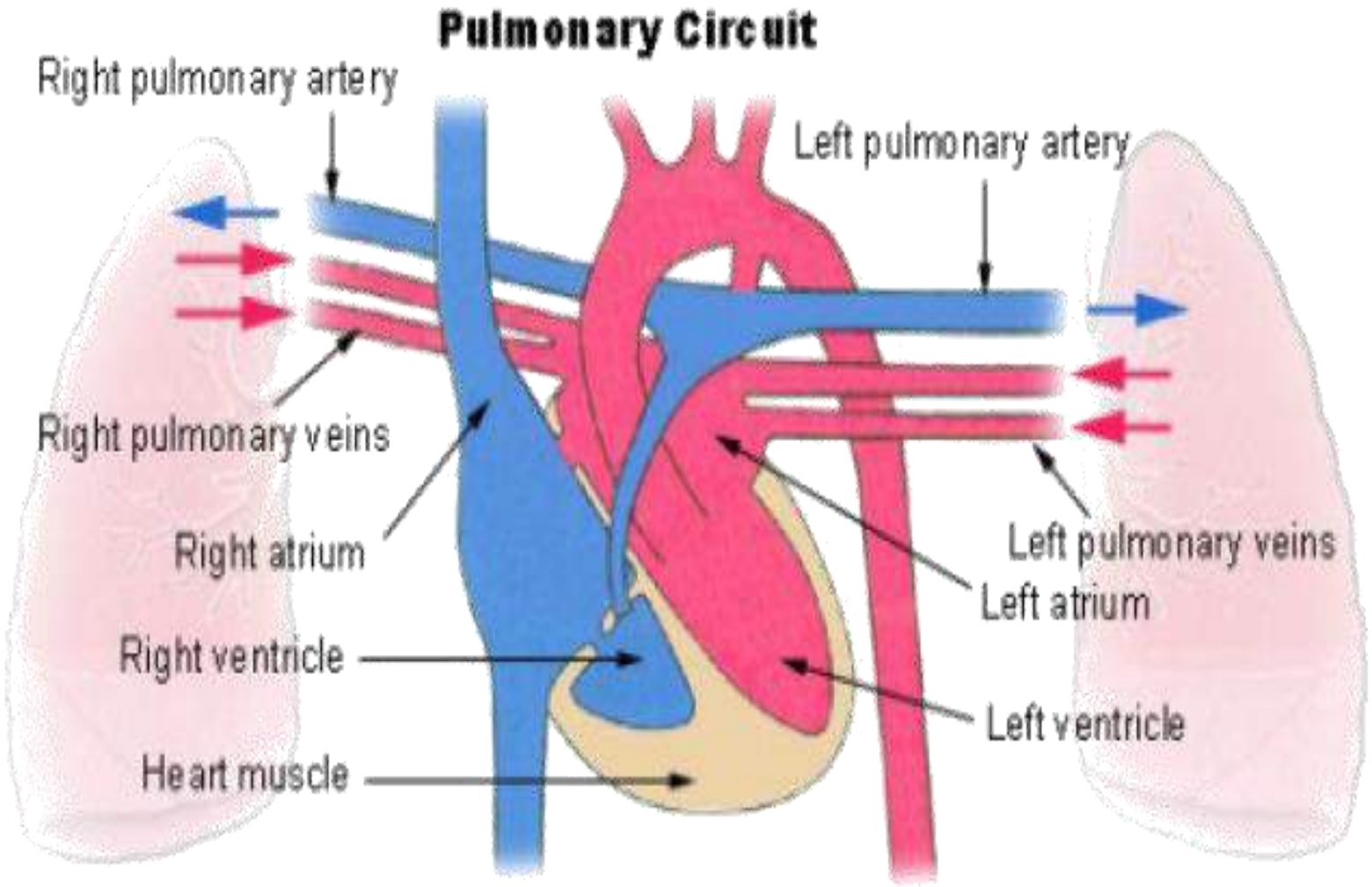
Pulmonary Circuit
Right pulmonary artery
Left pulmonary artery
Right pulmonary veins
Right atrium
Left pulmonary veins
Left atrium
Right ventricle
Left ventricle
Heart muscle

showing pulmonary artery (PA) bifurcation

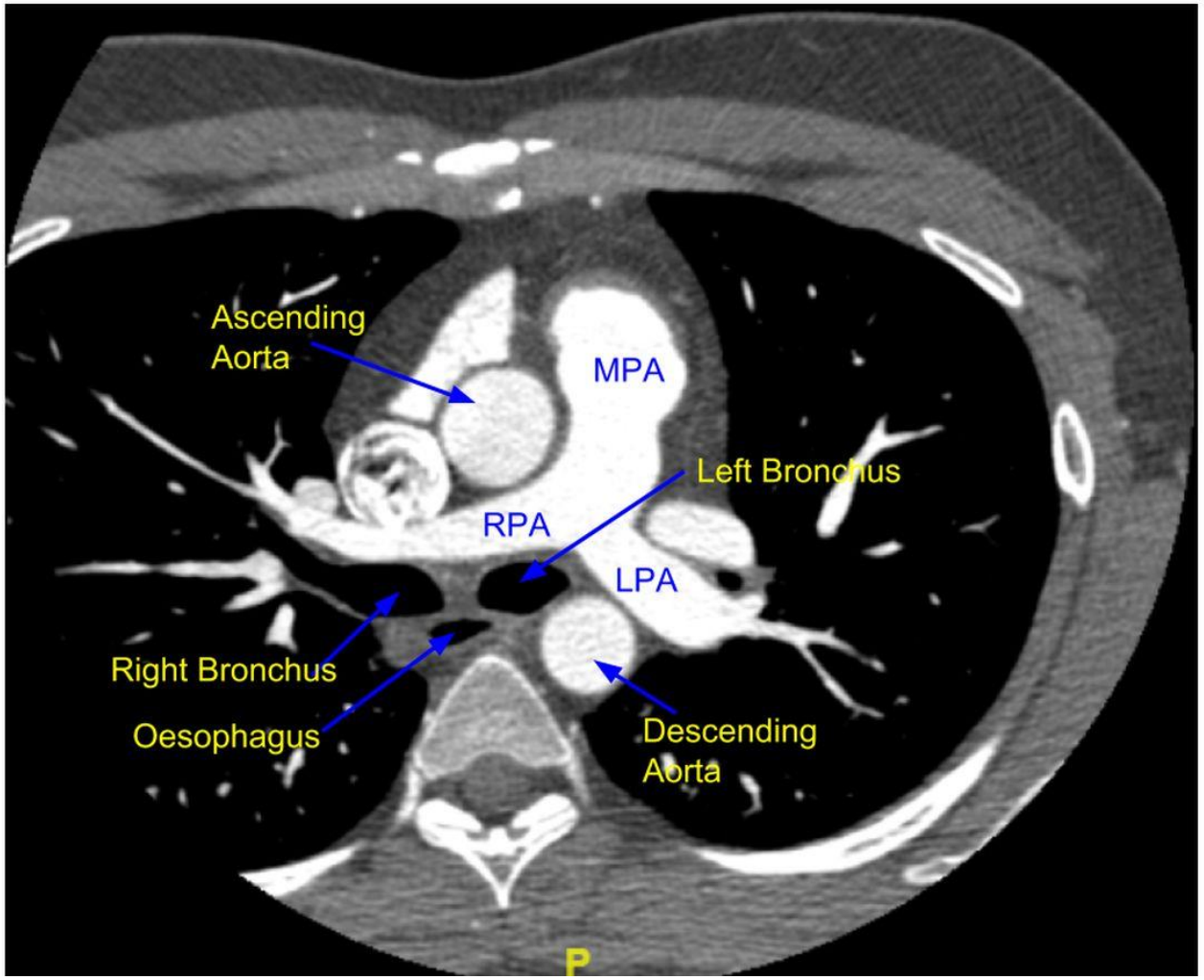

CT pulmonary angiogram



- The computed tomography pulmonary angiogram (CTPA/CTPE) is a commonly performed diagnostic examination to exclude pulmonary emboli (PE). Each radiology department will have a slightly different method for achieving the same outcome, i.e. diagnostic density of the main pulmonary artery and its branches.

- There is one principal approaches for performing a CTPA of high diagnostic quality:

- bolus tracking: sequential axial slices at a set region of interest are conducted during the contrast injection until a threshold enhancement is met, triggering a diagnostic scan.

CT pulmonary angiogram

- Because of its minimally invasive nature and high sensitivity and specificity, CTPA has evolved into the first line imaging study for the evaluation of suspected pulmonary embolism.
- Images are acquired using a breath hold technique during the pulmonary arterial enhancement phase following intravenous contrast material injection, with pulmonary embolism appearing as a filling defect in the otherwise densely opacified pulmonary artery.



CT pulmonary angiogram

- INDICATION
- • Suspected pulmonary embolism: acute or chronic.
- • Aortic dissection
- • Aortic overloading
- • Left ventricular stress

- CONTRAINDICATION
- • Renal failure
- • Allergic to contrast reactions
- • Pregnant patients



PREPERATION

- • Enquire about pregnancy from females.
- • Renal parameters are to be checked.
- • Nil oral preparation for 4-6 hours
- • All metal objects are to be removed from the region of interest
- • Enquire about allergic history



Technique

- Bolus tracking
- patient position :supine with their arms above their head
- scout :apices to diaphragm
- scan extent :apices to diaphragm
- scan direction :caudocranial
- contrast injection considerations
- monitoring slice (region of interest)
- below the carina at the level of the pulmonary trunk with an ROI on the pulmonary artery
- Threshold :150 HU
- Volume : 60 mL of non-ionic contrast with a 40mL saline chaser at 4.5/5 mL/s
- respiration phase :inspiration



Technique

- CT Technique Patient is positioned feet first with the help of laser localizers at the level of sternal notch with coronal beam at mid-axillary line.
- Proper immobilization should be done.
- Proper breath hold instructions should be given.
- Ensure the patient connected IV lines, are long enough to allow full travel of the couch without being pulled or entangled while undergoing a CT.



Technique

- Images of the thorax in a caudal–cranial direction. The caudal– cranial direction is used because most emboli are located in the lower lobes and, if the patient breathes during image acquisition, there is more excursion of the lower lobes compared with the upper lobes.



Technique

- Test dose of about 2 – 5 ml of contrast is injected and patient is observed for any reaction associated.
- 1.2ml /kg (body weight) of non-ionic iodinated contrast medium is injected intravenously into the patient using a pressure injector at a Rate of injection being 4-5 ml /sec, and scan is performed with no delay.
- For good timing bolus tracking is needed.
- A ROI is placed in the pulmonary trunk. When the treshhold of 150 HU is reached, the patient is asked to breath in and scanning is started immediately.



Purpose

- This technique is based on the detection of filling defects in the pulmonary arterial vasculature , so acquisition at the right time is of vital importance. The study is optimal when the pulmonary arteries are opacified, and the aorta is not.
- Late acquisition will make it difficult to differentiate between pulmonary arterial and pulmonary venous branches.



Axial image of CT pulmonary angiogram showing thrombi as filling defects in right main pulmonary artery (right arrow) extending into its branch and in distal left pulmonary artery (left arrow) with extension into its superior branch.

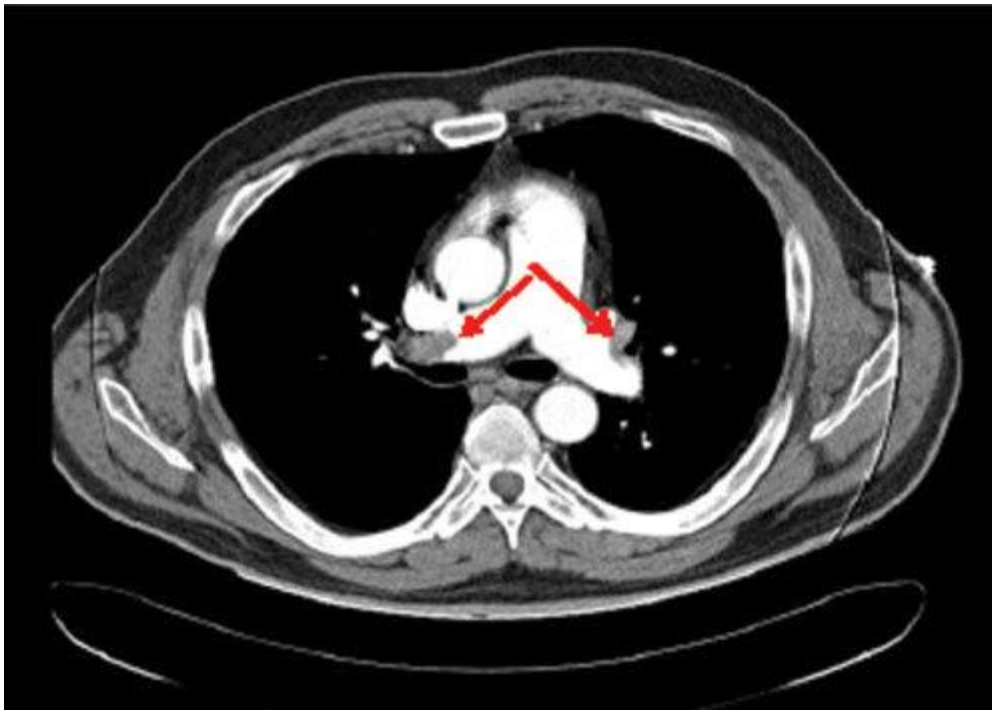

Figure 1: CT angiogram of the chest showing thrombus in the right pulmonary artery (yellow arrow)

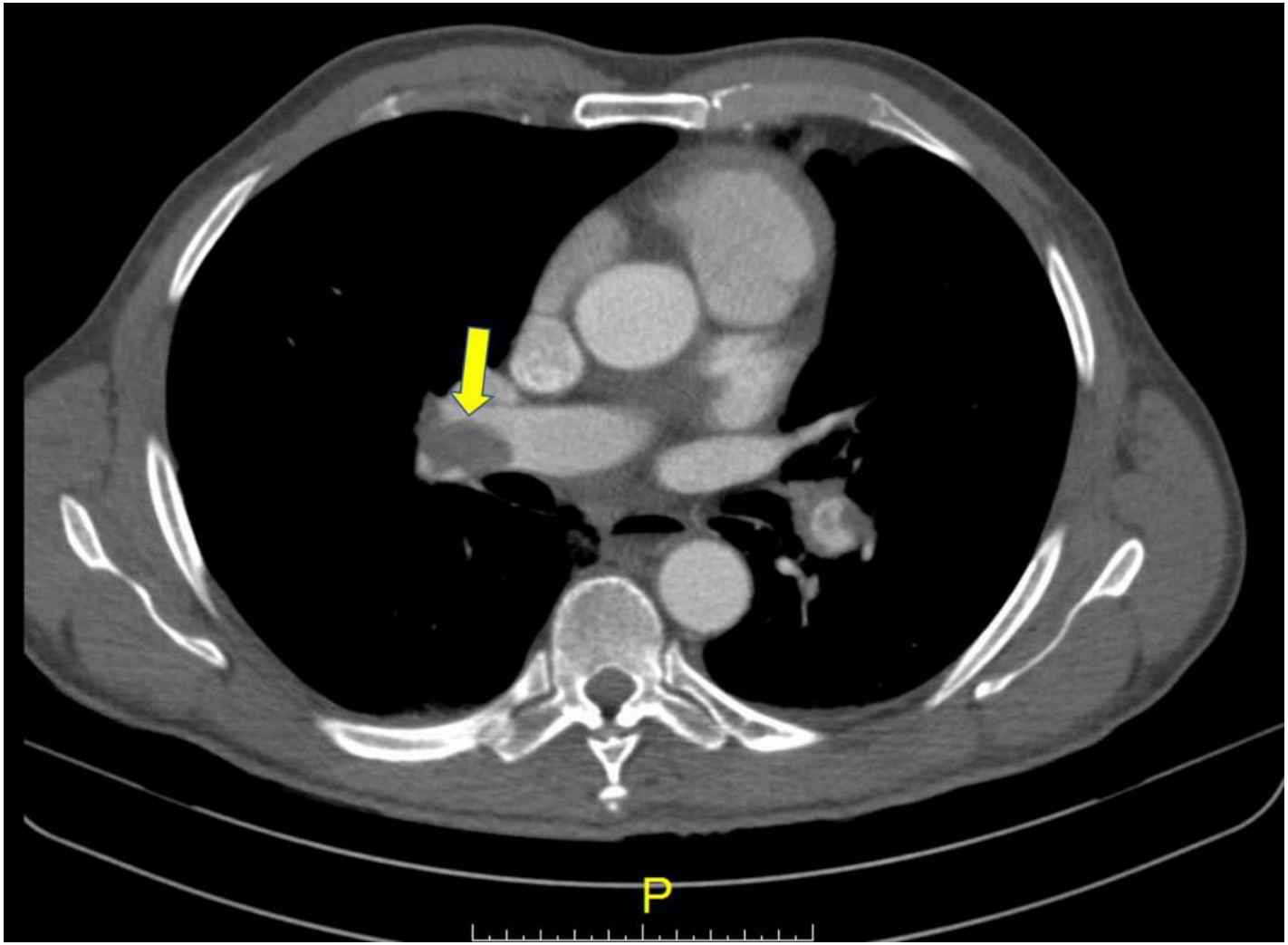

Normal pulmonary arteries shown on the CT angiogram.



Artefacts

- Transient interruption of contrast TIC is a flow artefact, that consists of relatively poor contrast enhancement in the pulmonary arteries, while there is good enhancement in the SVC and also in the aorta.
- This vascular phenomenon occurs when the patient performs a deep inspiration just before the scan starts, resulting in increased venous return of unopacified blood from the inferior vena cava (IVC).
- More unopacified blood from the IVC than opacified blood from the SVC enters the right atrium resulting in poor enhancement of the pulmonary arteries



Transient Interruption of Contrast:

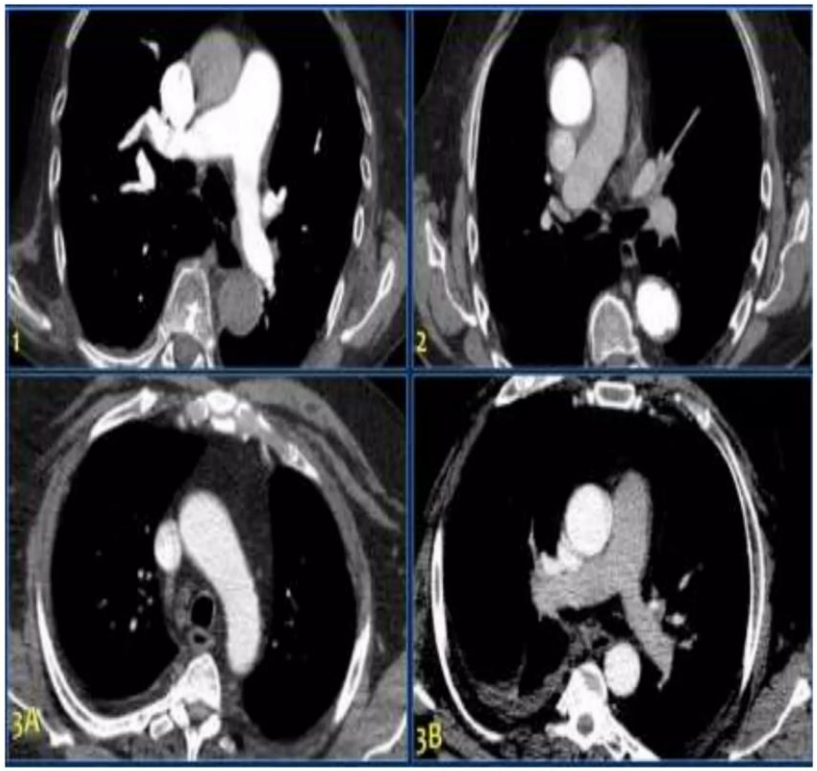

1. Optimal
2. Too late.
3. Transient interruption of contrast

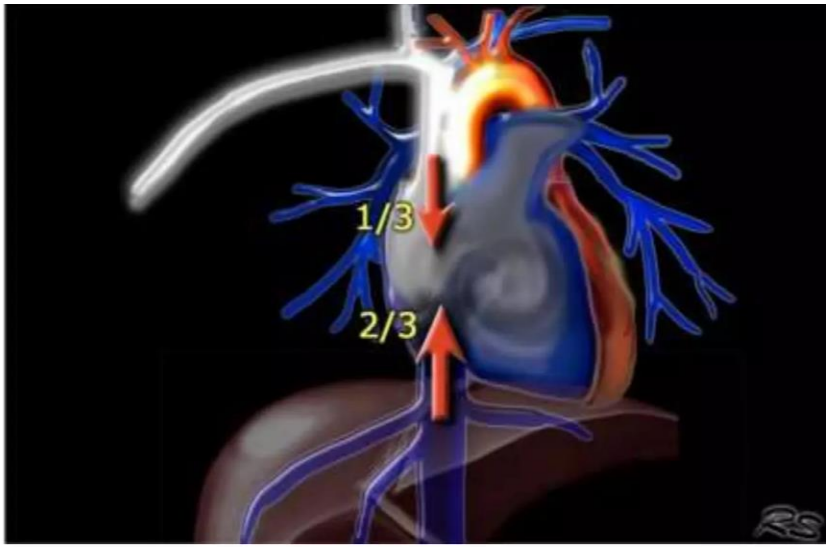

Transient Interruption of Contrast: Deep inspiration results in dilution of contrast in the right atrium by unopacified blood from the inferior vena cava

Motion Artifacts

- Respiratory motion artifacts are the most common cause of an indeterminate CTPA and can be a cause of misdiagnosis of pulmonary embolism.
- They are best seen on lung window settings that show composite images of vessels.
- A rapid change in position of vessels on contiguous images also confirms motion artifact.
- At the moment, the breath-hold required for 16-MDCT is approximately 10 seconds.



Streak Artifacts

- Streak artifact that obscures pulmonary vessels because of metallic implants can make a study indeterminate.
- . Streak artifact from high-density contrast material in the superior venacava can obscure adjacent pulmonary arteries.
- The frequency of this artifact can be reduced by using a saline bolus immediately after the contrast material injection.



Streak Artifacts



Figure 2. Axial image of thorax CT with contrast agent, which shows a streak artifact caused by the wall calcifications of the ascending thoracic aorta.

ADVANTAGES

- Less time consuming.
- Non-invasive nature.
- Almost all radiology departments have CT scan.
- Less complication than conventional (elevated pulmonary artery pressures).
- Lesser volume of contrast needed.
- Simple post procedure care.



Examination

- Which of the following investigations is most appropriate for a clinically unstable patient with suspected acute pulmonary embolism?

- catheter angiogram
- CTPA (CT pulmonary angiogram)
- echocardiogram
- ventilation perfusion scan (VQ scan)




Thank You!
shawnliv.com