Computed Tomography

- CT of the Liver: BY AHMED JASEM ABASS
- MSC of Medical Imaging



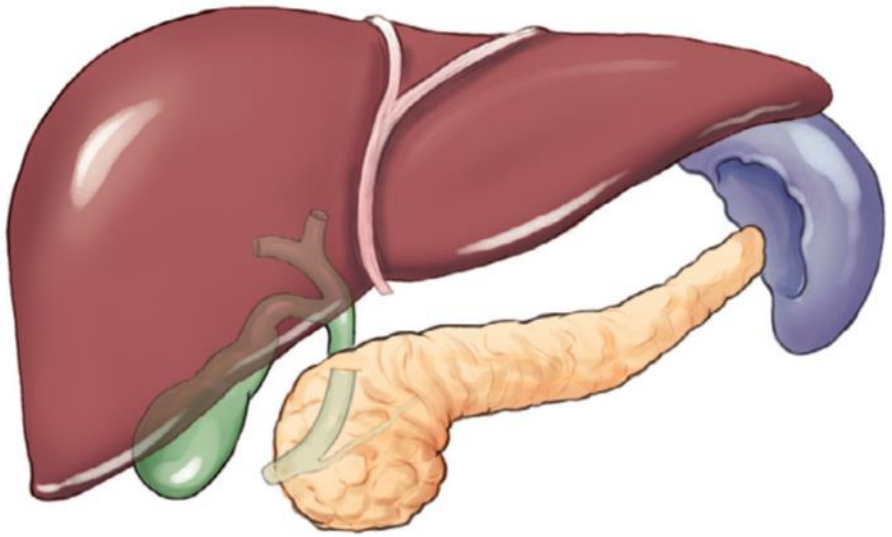



Liver Anatomy

- The liver is the largest solid organ in the body, occupying most of the right upper quadrant. The liver has numerous functions, one of which is the production of bile that assists in the digestion of fats. If bile is not needed for digestion, it is stored and concentrated for future use in the gallbladder.

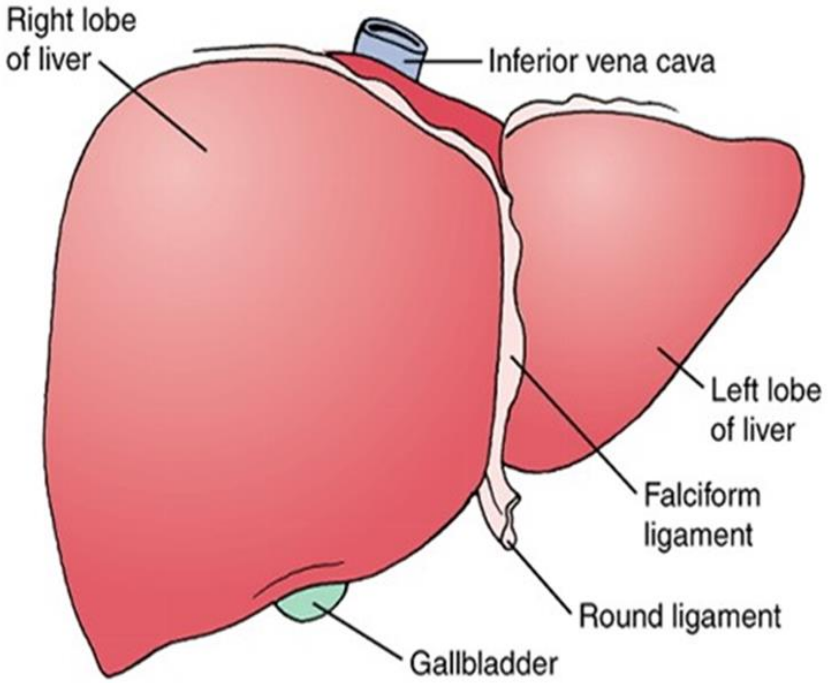

Figure 39-1 The liver and biliary system.

Copyright © 2004 Lippincott Williams & Wilkins.

Liver Normal Appearance

- The normal liver measures 7: craniocaudal length: 10-12.5 cm
- transverse diameter: 20-23 cm.

- The liver parenchyma is homogeneous with attenuation values of 54–60 HU, usually 8–10 HU greater than the spleen. The vascular structures can be identified by their location on the unenhanced images and confirmed by enhancement with IV contrast medium. The peripheral intrahepatic biliary tree is not normally visualized, although the main right and left hepatic ducts and the common hepatic and bile ducts are normally seen



Triphasic liver CT scan

- is a useful examination in the assessment of focal liver lesions, hypervascular liver metastases and endocrine tumors.
- Indications
- Suspected liver lesions such as hepatocellular carcinoma, focal nodular hyperplasia, adenoma, and hemangioma.
- Principles Of Hepatic Contrast Enhancement • When contrast agent is administered intravenously, it is rapidly redistributed from the vascular to the interstitial space while being continuously excreted by the kidneys. • In the liver, with its unique dual blood supply this process occurs quite rapidly



Triphasic liver CT scan

- Purpose
- Differentiating liver lesions on non-contrast studies is difficult due to the homogeneity of the liver tissue on CT however this exam helps solve that problem. The portal vein accounts for~75% of the liver's blood supply with the remainder from the hepatic artery, so a later arterial phase is required for the best enhancement of the parenchyma.

- To help characterize the vascularity of hypervascular liver lesions. This examination is most typically utilized to differential a hepatocellular carcinoma from other lesions.

- A hepatocellular carcinoma, a highly vascular primary lesion, will demonstrate hyperenhancement in the arterial phase and venous or delayed phase washout whilst a hemangioma should match the blood pool in each phase (same as the aorta in arterial etc).



Triphasic liver CT scan

- Minority of tumors contain calcifications , cystic components, fat or hemorrhage and will be detected on NECT.
- When we give IV contrast, it is important to understand that there is a dual blood supply to the liver.
- Normal parenchyma is supplied for 80% by PV & only for 20% by hepatic artery, so it will enhance in the portal venous phase.
- All liver tumors however get 100% of their blood supply from hepatic artery , so when they enhance it will be in arterial phase



Triphasic liver CT scan

Lesion Characterization

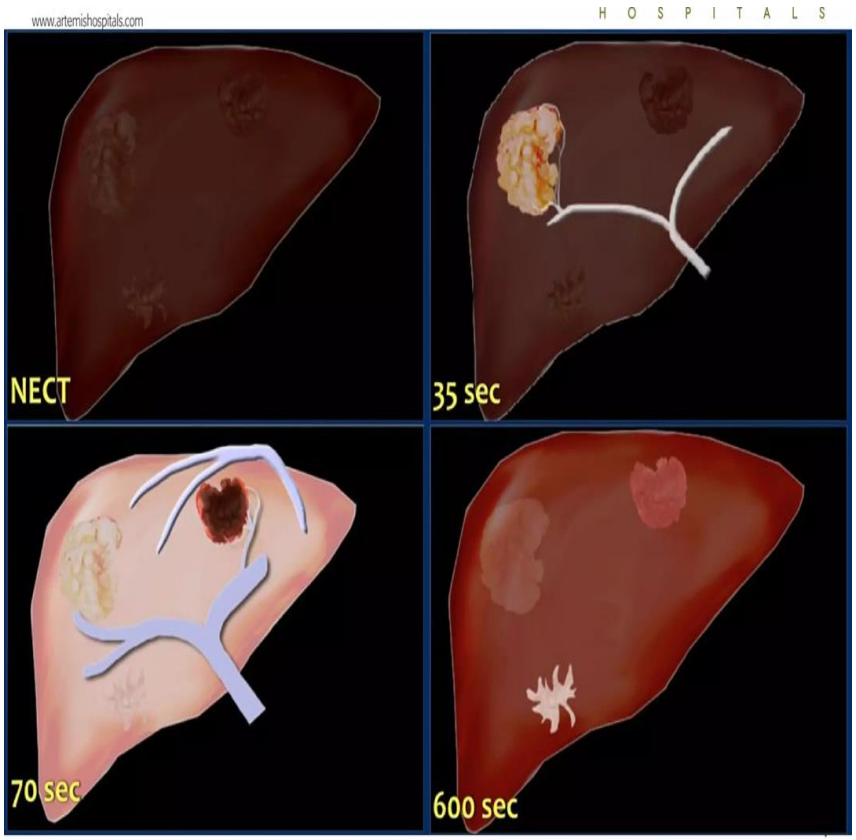

Dual Blood Supply

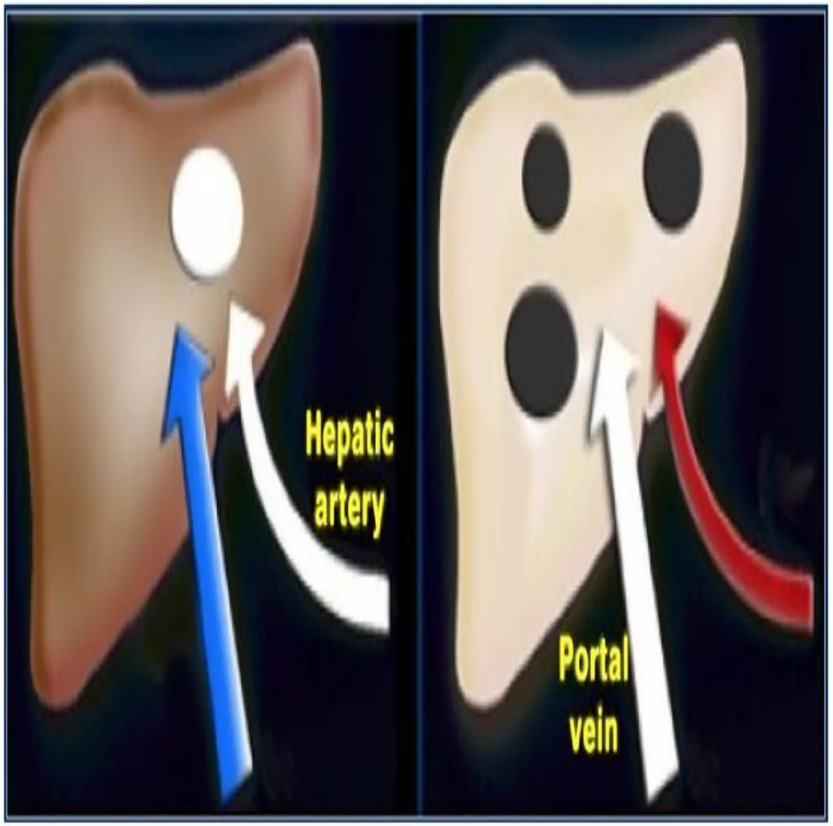

Triphasic liver CT scan

- Scanning liver with intravenous (IV) contrast in three different phases:
- Phase 1 (arterial): when IV contrast in arteries/ 30 to 40 seconds after IV contrast injection.
- Phase 2 (portal-venous): when IV contrast in veins/ 60 to 70 seconds after IV contrast injection.
- Phase 3 (delayed or equilibrium): after 3 to 5 minuets after IV contrast injection.
- Triphasic scan helps in differentiating benign from malignant masses:
- Benign = Black in phase 1 / White in phase 3 (e.g. hemangioma)
- Malignant = White in phase 1 / Black in phase 3 (e.g. HCC)



Technique

- patient position
- supine with their arms above their head
- scan extent
- diaphragm to iliac crests
- some departments will perform a full abdomen and pelvis in the portal venous phase
- contrast injection considerations (timing)
- volume
- 100-120 mL of non-ionic contrast at 3 to 5 mL/s (a higher flow rate will equal great enhancement)
- scan direction
- craniocaudal



Technique

- scan delay 1
- late arterial phase
- 15-30 seconds post bolus trigger (35-45 s after injection)
- portal venous phase
- 60-75 seconds post-injection (independent of arterial timing)
- delayed phase
- 2-5 minutes
- respiration phase
- inspiration, breath-hold



Arterial phase imaging

- Optimal timing and speed of contrast injection are very important for good arterial phase imaging.
- Hypervascular tumors will enhance optimally at 35 sec after contrast injection (late arterial phase).
- This time is needed for the contrast to get from the peripheral vein to the hepatic artery and to diffuse into the liver tumor.

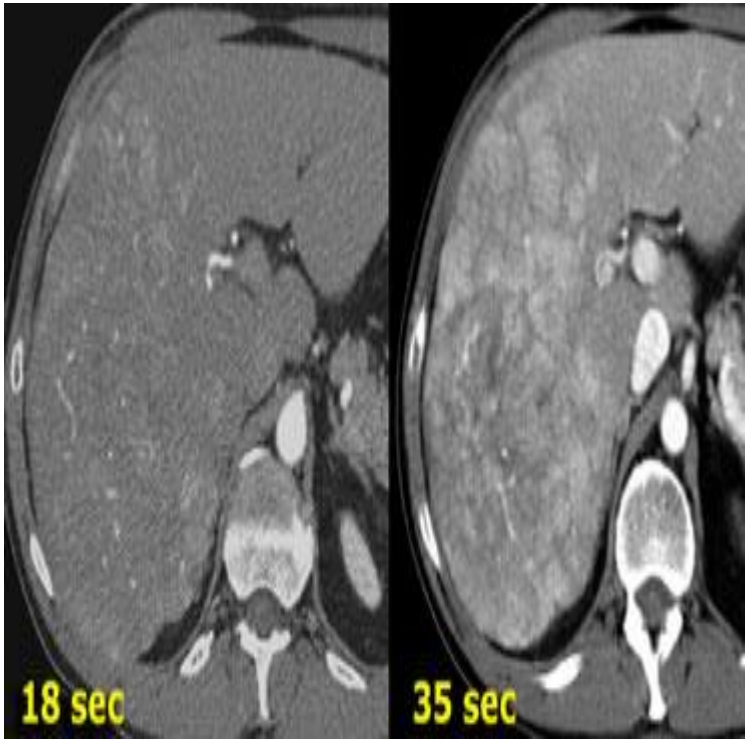

- On the left a patient who underwent two phases of arterial imaging at 18 and 35 seconds. In the early arterial phase we nicely see the arteries, but we only see some irregular enhancement within the liver.
- In the late arterial phase we can clearly identify multiple tumor masses.
- Notice that in the late arterial phase there has to be some enhancement of the portal vein.
- The only time that an early arterial phase is needed is when you need an arteriogram, for instance as a roadmap for chemoembolization of a liver tumor.



Timing of scanning

- Timing of scanning is important, but almost as important is speed of contrast injection.
- For arterial phase imaging the best results are with an injection rate of 5ml/sec.
- There are two reasons for this better enhancement: at 5ml/sec there will be more contrast delivered to the liver when you start scanning and this contrast arrives in a higher concentration.
- On the left a patient with cirrhosis examined after contrast injection at 2.5ml/sec and at 5ml/sec.
- At 5ml/sec there is far better contrast enhancement and better tumor detection.

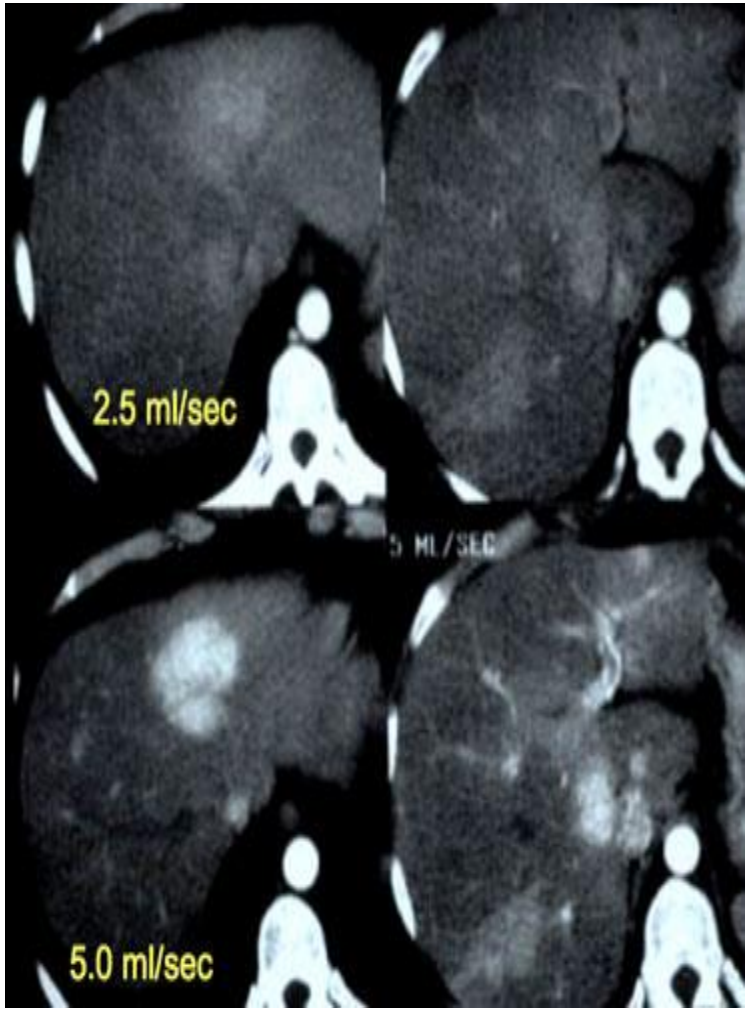

Portal Venous phase

- Portal venous phase imaging works on the opposite idea.
- We image the liver when it is loaded with contrast through the portal vein to detect hypovascular tumors (figure).
- The best moment to start scanning is at about 75 seconds, so this is a late portal venous phase, because enhancement of the portal vein already starts at 35 sec in the late arterial phase.
- This late portal venous phase is also called the hepatic phase because there already must be enhancement of the hepatic veins. If you do not seen enhancement of the hepatic veins, you are too early.
- If you only do portal venous imaging, for instance if you are only looking for hypovascular metastases in colorectal cancer, fast contrast injection is not needed, because in this phase the total amount of contrast is more important and 3ml/sec will be sufficient

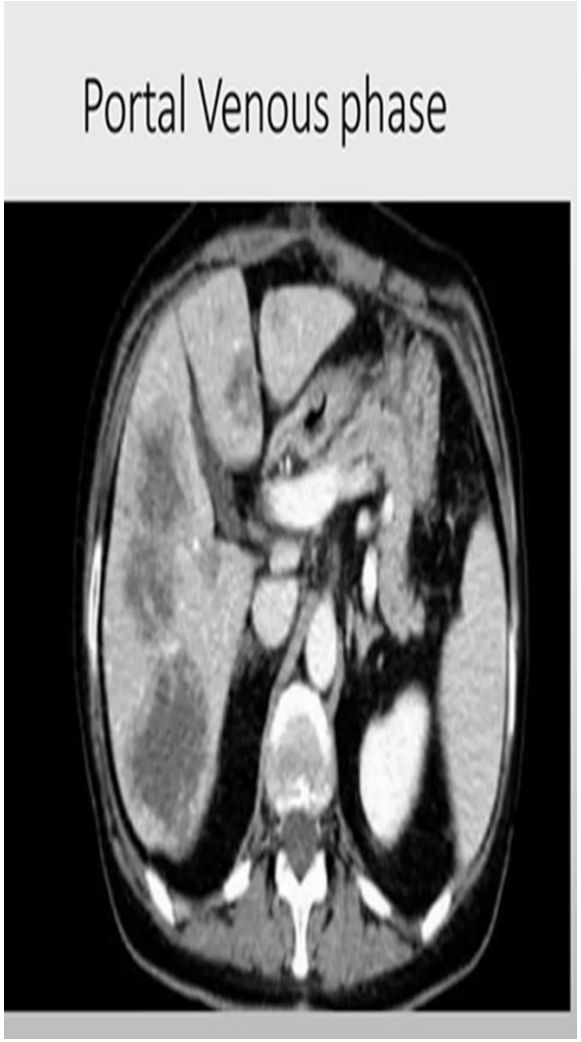

Equilibrium Phase

- The equilibrium phase is when contrast is moving away from the liver and the liver starts to decrease in density.
- This phase begins at about 3-4 minutes after contrast injection and imaging is best done at 10 minutes after contrast injection.
- This phase can be valuable if you're looking for: fast tumor washout in hypervascular tumors like HCC or retention of contrast in the blood pool as in hemangiomas or the retention of contrast in fibrous tissue in capsules (HCC) or scar tissue (FNH, Cholangioca).

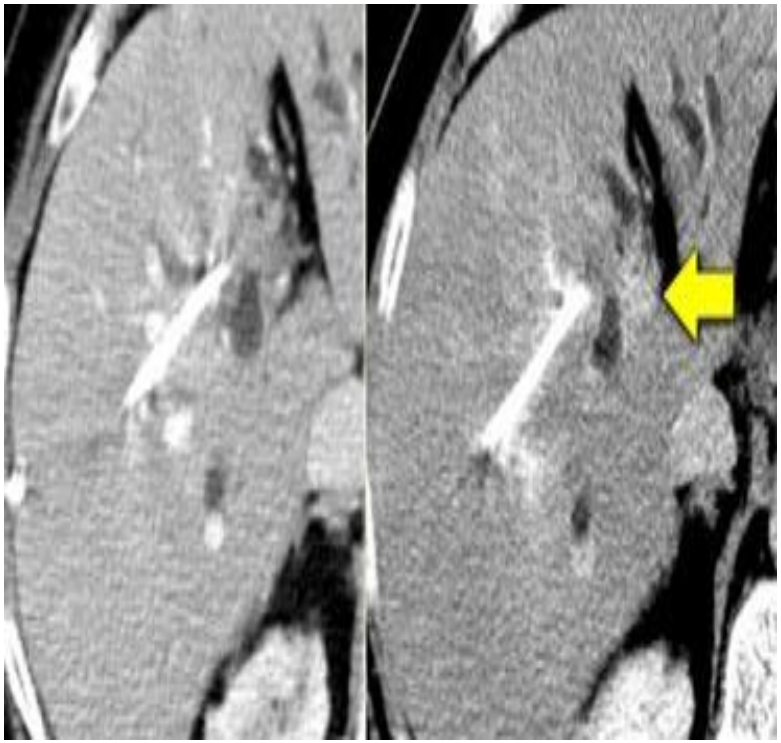

Small cholangiocarcinoma not visible in portal venous phase (left), but seen as relative hyperdense lesion in the delayed phase (right).



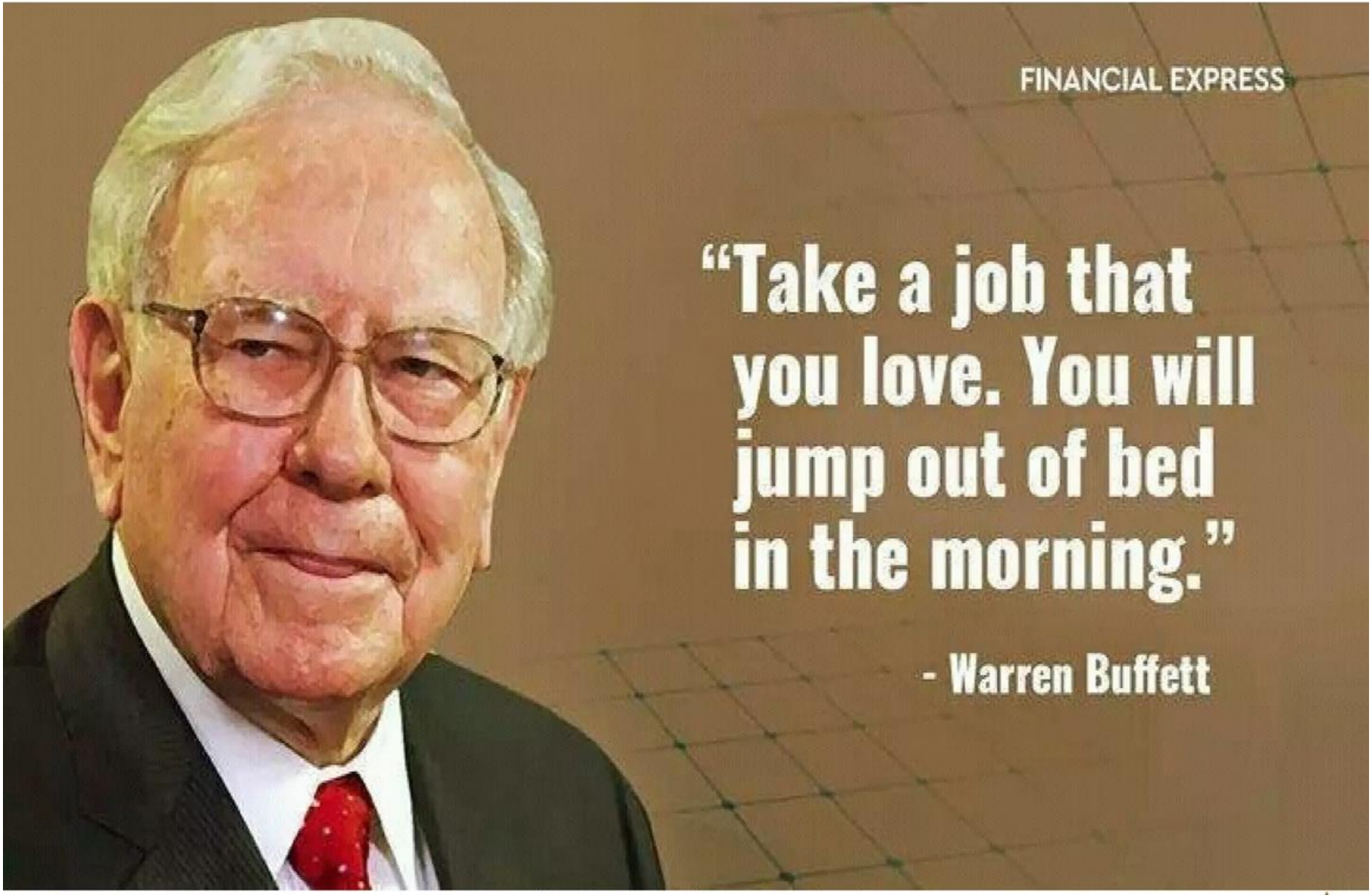

First hospital in Gurgaon to be JCI and NABH accredited.

Thank You !!!