Computed Tomography

- Multi Detector CT of the Pancreas: BY AHMED JASEM ABASS
- MSC of Medical Imaging



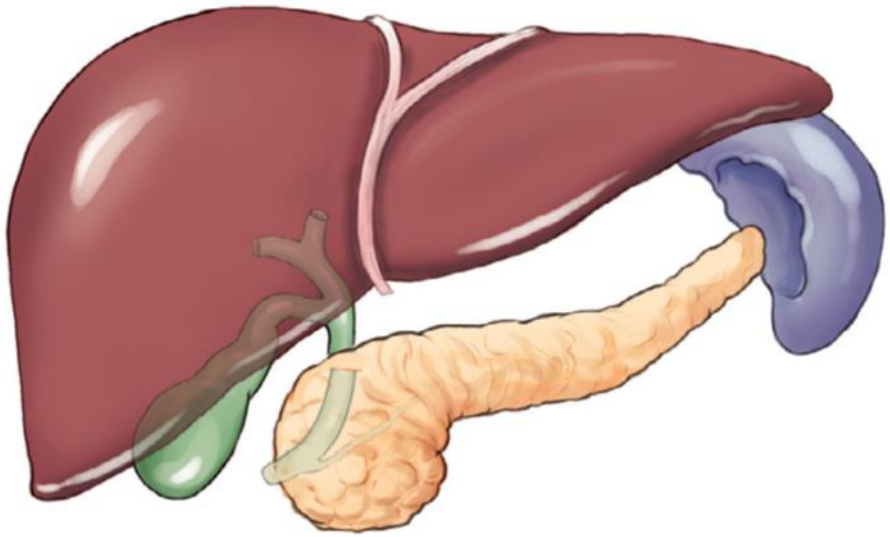



Anatomy of the Pancreas

- The pancreas is an elongated, tapered organ, about 6 inches long, located across the back of the abdomen, and behind the stomach. The right side of the organ (called the head) is the widest part of the organ and lies in the curve of the duodenum (the first section of the small intestine). The tapered left side extends slightly upward (called the body of the pancreas) and ends near the spleen (called the tail) in the upper left part of the abdomen.

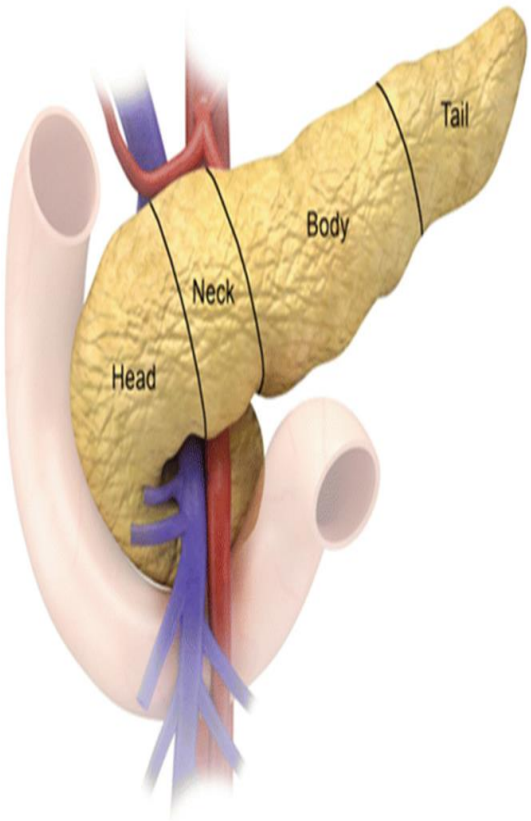

Anatomy of the Pancreas

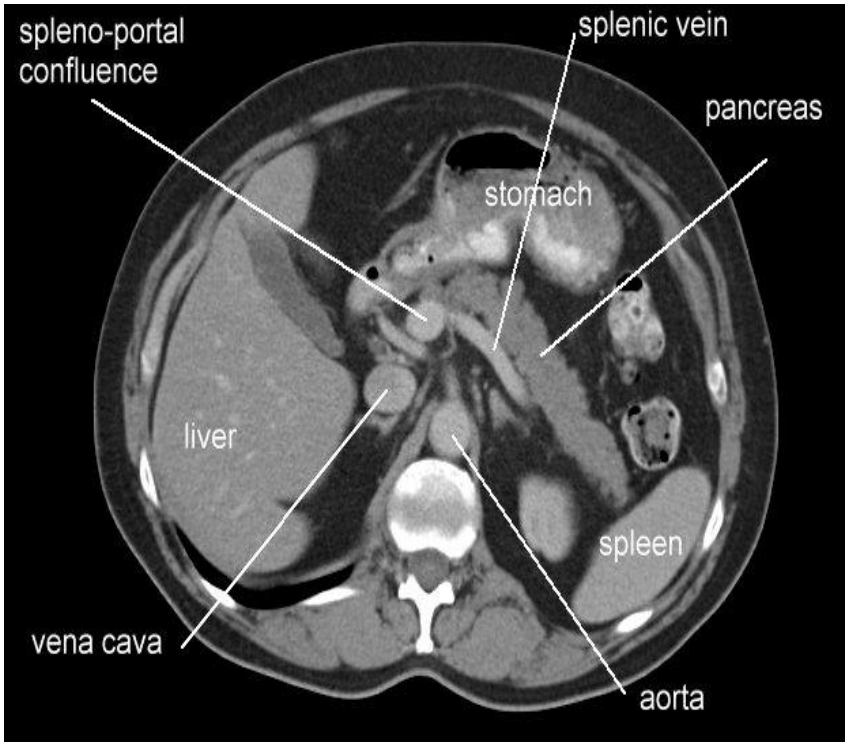

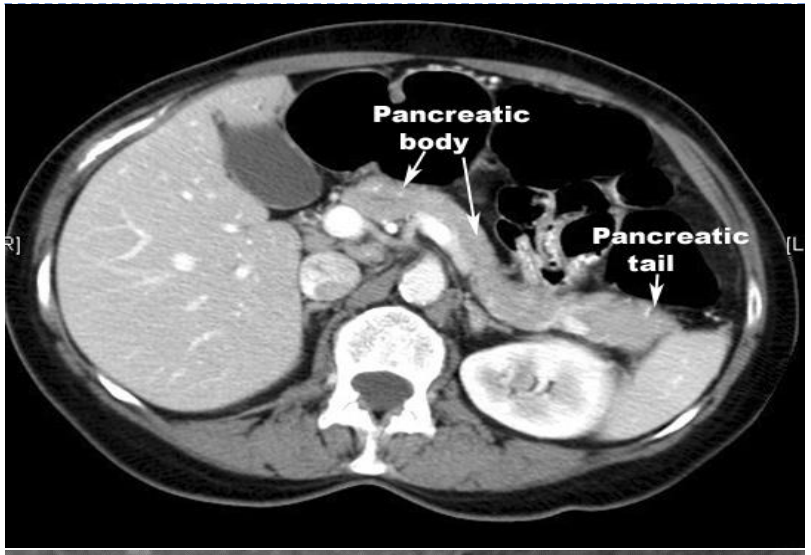



Imaging Modality of Pancreas

- Previously the pancreas was a difficult organ to eval-uate, clinically or with routine radiologic studies. Cross-sectional imaging methods such as ultraso-nography, CT, and MRI now permit direct dem-onstration of the pancreas. The role of MRI in the diagnosis of pancreatic disorders is still question- able, and the technique probably offers no signifi-cant advantages over CT. When the pancreas is well visualized on a sonogram, the accuracy is compa- rable to that of CT. In general, the success rate for delineating the entire pancreas is much higher with CT than with ultrasonogra.



Multi Detector CT of the Pancreas

- A CT scan of the pancreas may be performed to assess the pancreas for tumors and other lesions, injuries, bleeding, infections, abscesses, unexplained abdominal pain, obstructions, or other conditions, particularly when another type of examination, such as X-rays or physical examination, is not conclusive.
- CT scans of the pancreas may be used to distinguish between disorders of the pancreas and disorders of the retroperitoneum (the back portion of the abdomen behind the peritoneal membrane).
- There may be other reasons for your doctor to recommend a CT scan of the pancreas.



Indications for CT scan of the pancreas:

- The main indications for CT of the pancreas are:
- 1. Staging of acute pancreatitis.
- 2. Evaluating complications of acute and chronic pancreatitis.
- 3. The detection and staging of suspected pancreatic carcinoma.



Technique

- Use water for bowel prep
- Scan native before IV CM for calcifications
- 1 cc/ kg
- Rate 3-5 ml/s.
- Thickness 2-3 mm
- Early arterial 20 sec for vascular assessment pre-op
- Early portal phase 40-50 sec the most important phase for the best opacification of the pancreas parenchyma
- Late portal or hepatic phase for liver etc



Technique

- Before the initiation of contrast enhanced MDCT, the patients drink approximately one liter of water to distend the stomach, duodenum, and jejunum so that to facilitate detection of abnormalities in the pancreas.The scanned area extends from the diaphragm to below the transverse duodenum in a single breath hold.
- Water (a negative contrast medium) is preferred rather than iodine or barium-based contrast (positive contrast materials) for the following reasons:
- 1. To avoid interference with volume-rendered reconstructions of the peri-pancreatic vessels.
- 2. Water does not mask radio-opaque stones in the common bile ducts.
- 3. Water may aid in the evaluation of gastric and duodenal wall lesions.



Technique

- Contrast-enhanced imaging of the pancreas can be performed in three distinct phases
- 1. The early arterial phase, which is seen at approximately20 s after the start of contrast administration, demonstrates contrast uptake within the Arterial tree with almost no enhancement of the pancreatic parenchyma.
- This phase is performed if CT angiography is desired. This phase is also useful in demonstrating pancreatic hormone producing tumors which are typically hypervascular. The presence of hypervascular metastatic deposits to the pancreas can be detected in the arterial phase.



Technique

- 2. The next phase is the delayed arterial phase (pancreatic parenchymal phase), which is acquiredat about 35–40 s following after the start of contrast administration. This phase is performed using 1-2 mm slice collimation. The scanned area extends from the diaphragm to below the transverse duodenum in a single breath hold . In this phase, there is optimal enhancement of the pancreatic parenchyma thus, most pancreatic adenocarcinomas appear as low-density lesions compared with the normal enhancing pancreatic parenchyma, making tumor conspicuity maximal during this phase. The pancreatic phase also facilitates visualization of major arterial structures and permits staging the tumor and determining resectability based on vascular involvement and excellent delineation of the arterial vascular system.



Technique



Fig. 4: A) Pancreatic arterial phase CT demonstrating a hypervascular tumor (white arrow) in the head of the pancreas. B) In the portal phase the tumor is not clear & there is hypodensity in the region of the tumor. It is important to perform an arterial phase CT in a patient with suspected endocrine tumor to allow adequate characterization of the mass.

Technique

- 3. The third phase is the portal venous phase (hepatic parenchymal phase), which is usually acquired at 65–70 s after the start of contrast administration. This phase covers the entire upper abdomen using 2.5- 5 mm slice collimation, depending on the patient's body habitus .This phase offers good enhancement of the liver parenchyma. This phase is critical for the detection of small hypodense liver metastases and in the diagnosis of venous encasement by a tumor.



Contrast-enhanced CT of the pancreas is diagnostic and can show:

- Enlargement of pancreas due to edema
- Peripancreatic inflammation: linear strands in the peripacreatic fat.
- Hemorrhagic: Enlarged pancreas with increased density due to hemorrhage.
- Necrosis: On contrast enhanced phases the necrotic pancreatic parenchyma will show decreased or no enhancement when compared with normally enhancing viable tissue.
- Fluid collections: A simple peripancreatic fluid collection will not have a well-defined capsule.
- Pseudocysts: As liquefaction of necrotic pancreatic tissue progresses it will gradually take on the appearance of localized fluid collection...pseudocyst.
- Abscesses: Diffusely enlarged pancreas with air pockets.



Pancreatic Cancer

- Approximately 75% of all pancreatic carcinomas occur within the head or neck of the pancreas, 15-20% occur in the body of the pancreas, and 5-10% occur in the tail.
- Typically, pancreatic cancer first metastasizes to regional lymph nodes, then to the liver, and less commonly, to the lungs.

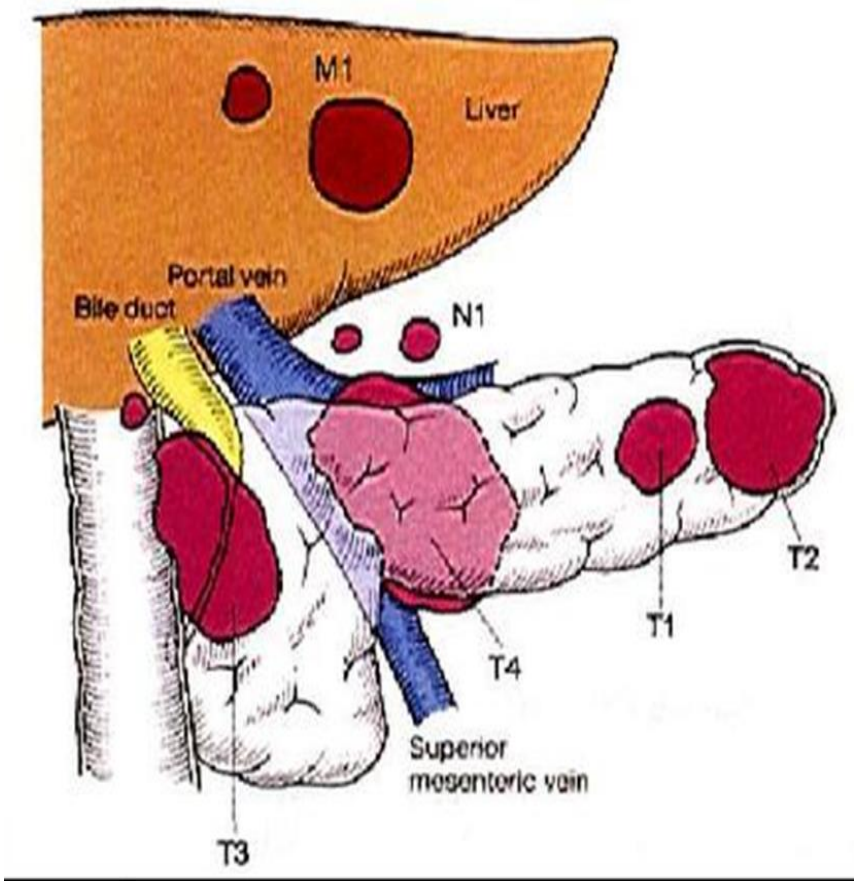

TNM staging of pancreatic carcinoma. T1-T4=local tumor extension; N=lymph node; M=metastasis.

Pancreatic Cancer

- Worldwide, pancreatic cancer is the eighth most common cause of death from cancer in both sexes combined, a relative position higher than for incidence (thirteenth) because of the very poor prognosis.
- Fewer than 5% of all patients are still alive 5 years after initial diagnosis. The collective median survival time of all patients is 4-6 months.
- Despite the poor prognosis of patients with pancreatic cancer, surgical resection is still the only potentially curative treatment for the disease.



Pancreatic Cancer

- CT is generally accepted to be the first line of investigation in a patient with suspected pancreatic cancer.
- At present, CT is the most widely used and most sensitive test for an evaluation of the pancreas for pancreatic carcinoma.
- Dynamic CT has a detection rate of approximately 99%.



Pancreatic Cancer

- Features suggestive of underlying pancreatic cancer include the following:

1. alterations in morphology of the gland with abnormalities of CT attenuation values.
2. obliteration of peripancreatic fat.
3. loss of sharp margins with surrounding structures.
4. involvement of adjacent vessels and regional lymph nodes.
5. pancreatic ductal dilatation.
6. pancreatic atrophy.
7. obstruction of the common bile duct (CBD).



CT scan in Adenocarcinoma of the Pancreas

- The role of CT in pancreatic adenocarcinoma is the detection and staging of suspected pancreatic carcinoma (it is established as the primary initial imaging method for this). CT is also highly reliable for demonstration of features indicating that a tumor is unresectable.
- Imaging features that generally indicate unresectability include:
- 1. Extra - pancreaticinvasion of major vessels (defined astumor-to-vessel contiguity >50%) such as celiacartery, hepatic artery, portal vein, superior mesentericartery or superior mesenteric vein, or massivevenous invasion with thrombosis
- 2. lymph node metastases beyond those in the immediatevicinity of the pancreas
- 3. distant metastases, which most commonly involve the liver or peritoneum.



CT scan in Adenocarcinoma of the Pancreas

- For the detection or staging of pancreatic adenocarcinoma dual phase images are acquired in two phases: a pancreatic parenchymalphase to detect the tumor itself within the pancreas;and a venous or hepaticparenchymal phase for the detection of small hypodense livermetastases and in thediagnosis of venous encasement by a tumor.

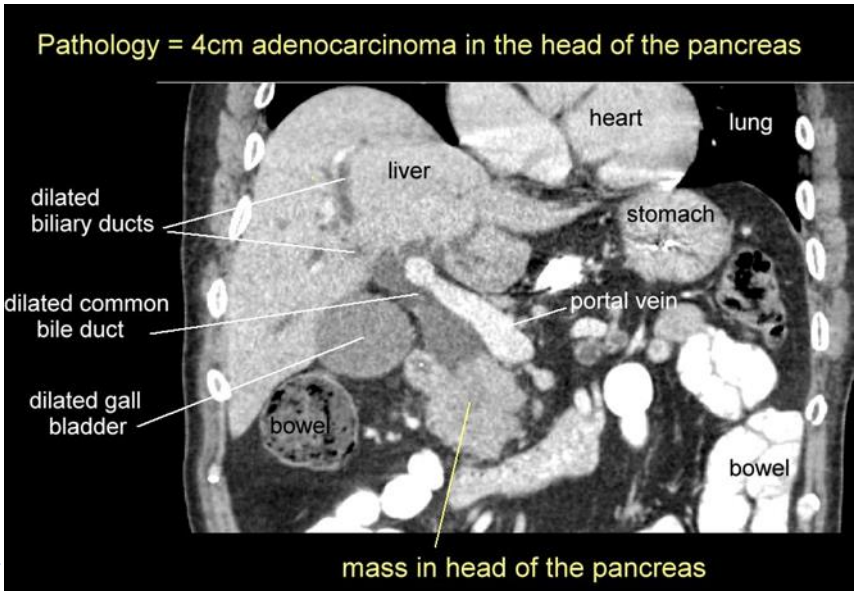

CT scan in Pancreatitis

- Contrast-enhanced CT is the most reliable imaging modality for the staging of acute pancreatitis but requires meticulous technique. Thin sections should be obtained during maximum pancreatic enhancement. Oral water is given (to opacify the stomach,duodenum, jejunum) with an IV iodinated contrast agent (a volume of 100–150 ml injected at a rate of 3 ml s-1)with data acquisition delayed for 30 and 70s to visualize the pancreas in both the arterial and portal venous phases of enhancement.



CT scan in Pancreatitis

- Inspite of the high reliability of Contrast-enhanced CT for the staging of acute pancreatitis, the indications for CT in suspected or confirmed acute pancreatitis are not universally agreed. This is because of the following facts:
- 1. There is concern that iodinated contrast agents may exacerbate pancreatic necrosis and renal impairment.
- 2. If CT is carried out very early, it may underestimate the degree of necrosis and in most patients it will not influence management in the first few days.
- 3. Never the less, patients with persisting or new organ failure and those with continuing pain or signs of sepsis will require a contrast-enhanced study because the presence of necrosis as detected on CT has a high correlation with the risk of local and systemic complications.



CT scan in Pancreatitis

- CT is the imaging method of choice for evaluating complications of acute and chronic pancreatitis.
- Three-dimensional reconstructions,Multiplanar reconstructions, and curved planar reconstructions of the data are useful for demonstrating the followings:
- 1. extent of pancreatic necrosis (Fig. 1)
- 2. the presence &amount of peri-pancreatic fluid collections
- 3. demonstrating intra-ductal pancreatic calculi.
- 4. CT angiography is an excellent technique for delineating pseudo-aneurysms of the peri-pancreatic vessels.



Enlargement of pancreas due to edema

- Acute edematous pancreatitis. A,B: Contrast-enhanced axial CT images, venous phase, demonstrating diffuse pancreatic enlargement, densification of the peripancreatic fat planes (long arrows) and acute fluid collections in the left anterior pararenal space and in the left paracolic gutter (short arrows), without areas of parenchymal necrosis. A B

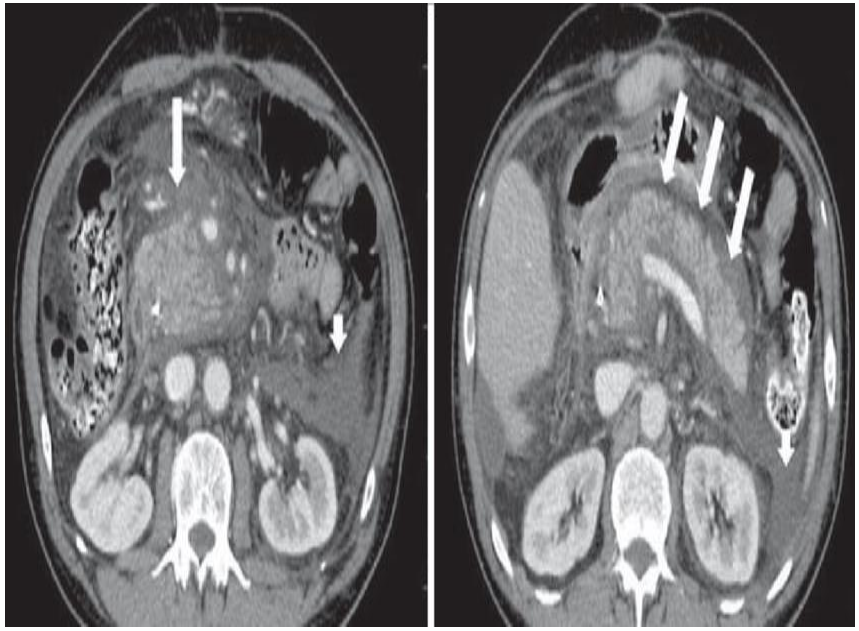

CT scan in Acute Pancreatitis

- Post Contrast CT findings reveal diffusely enlarged pancreas with low density from edema.

- C: Colon
- St: Stomach
- P: Pancreas

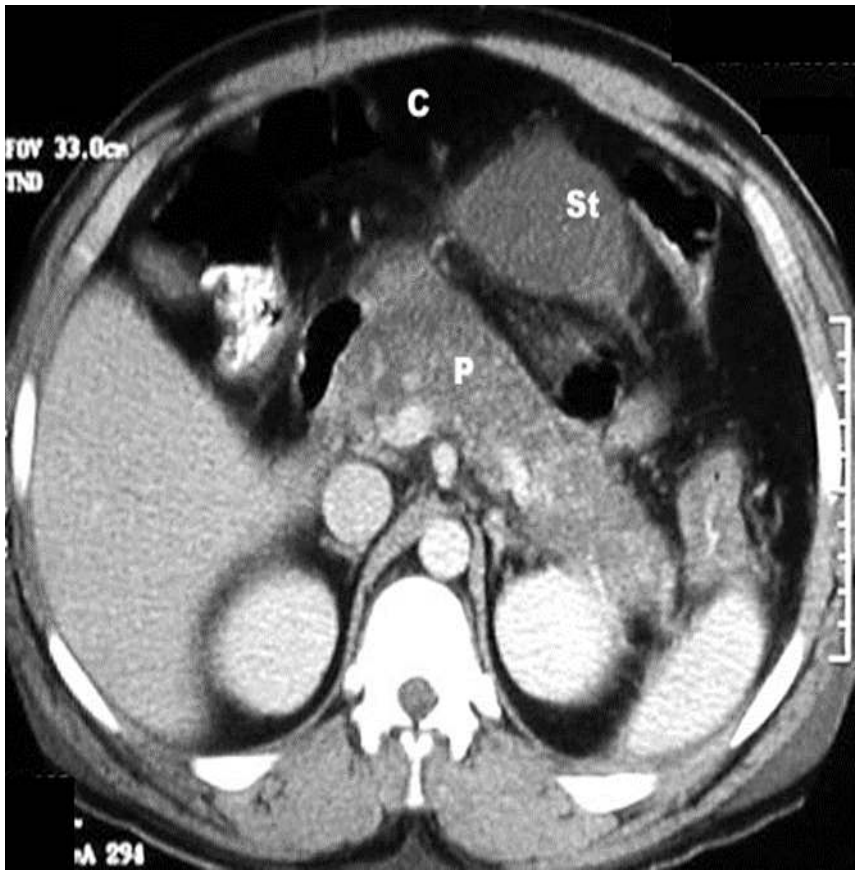

CT scan in Pancreatitis

- Fig. 1: Pancreatic necrosis in a patient with severe acute pancreatitis.Curved planar reformatted image through the pancreas shows necrosis of the pancreatic head and neck (arrow; D duodenum,P
- intact pancreatic parenchyma)

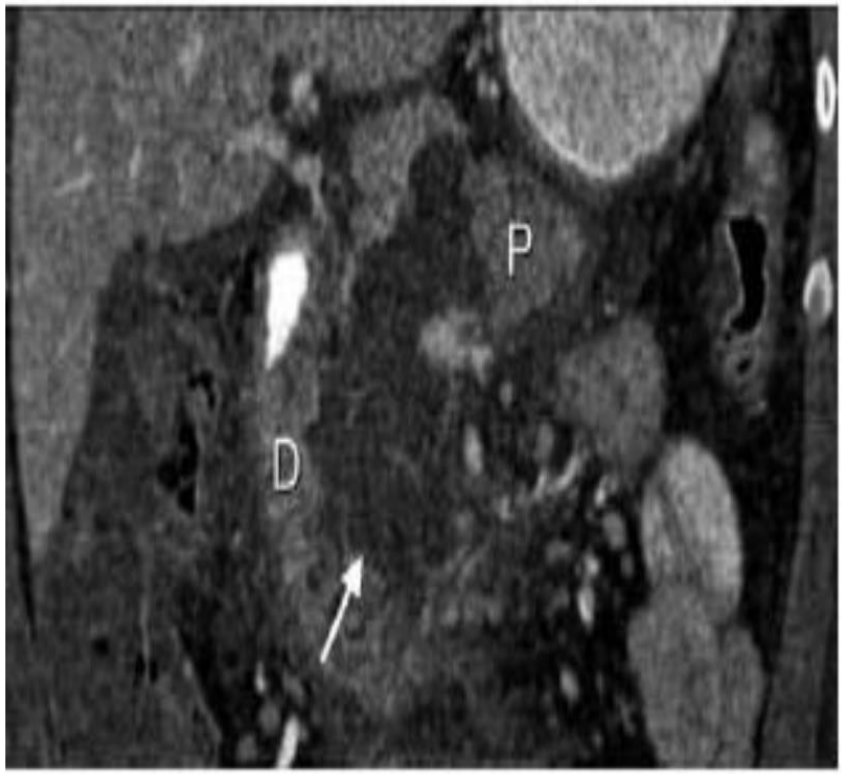

CT scan in Pancreatitis

- CT scan in a patient with chronic pancreatitis and pseudocyst

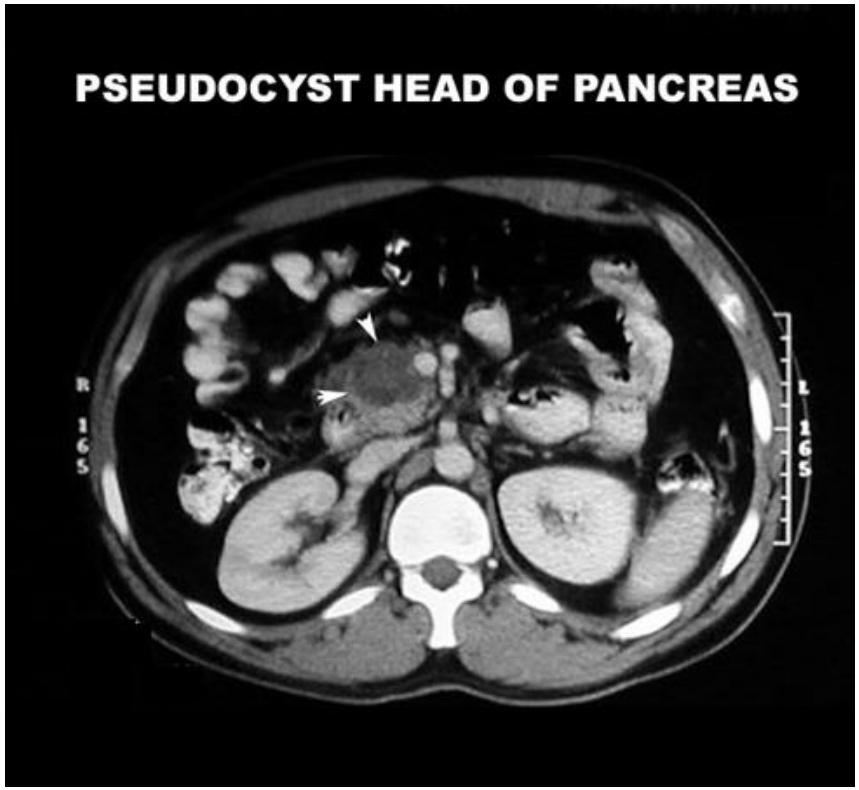

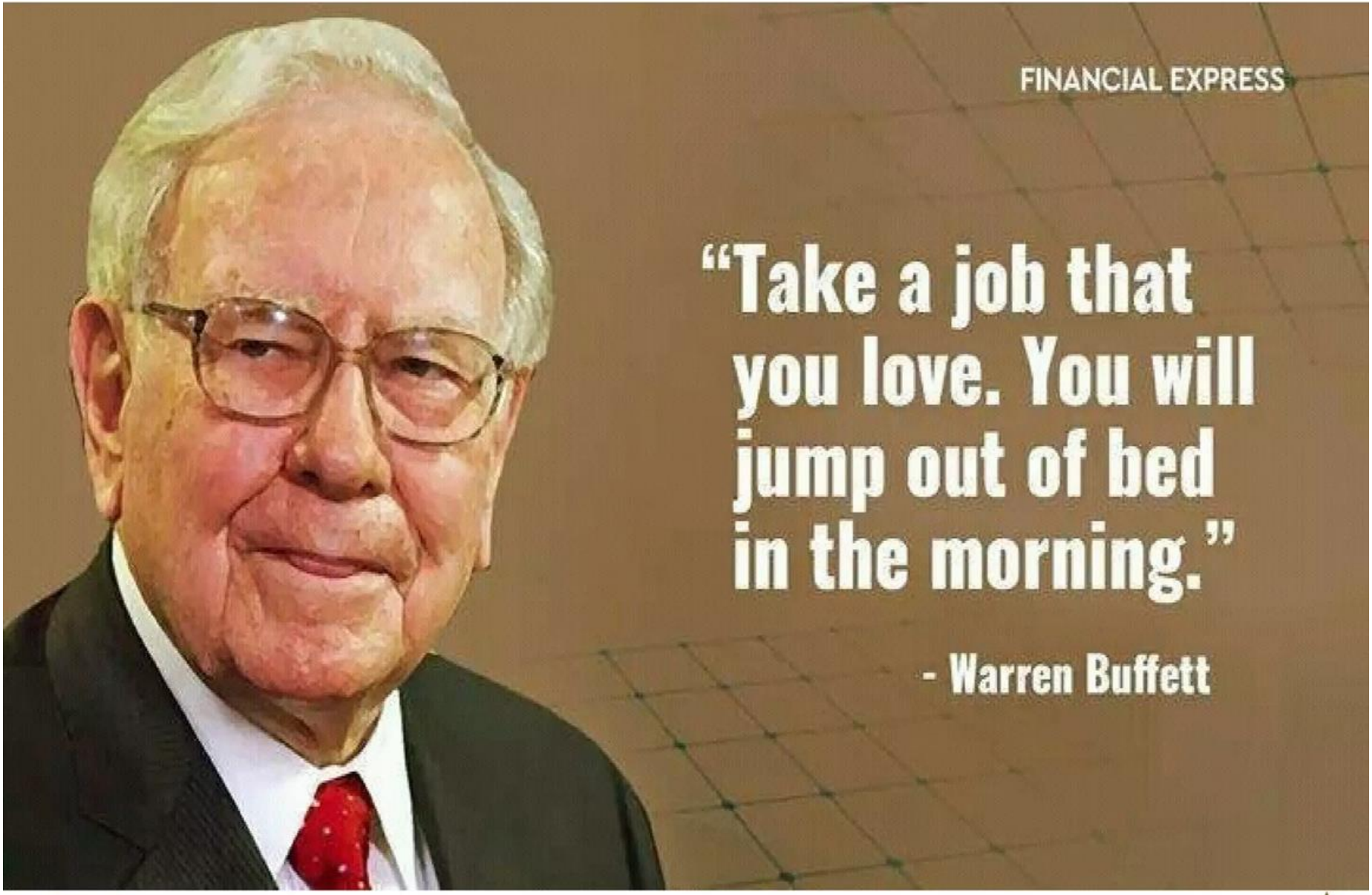

First hospital in Gurgaon to be JCI and NABH accredited.

Thank You !!!