Computed Tomography

- Multi Detector CT of the Kidney: BY AHMED JASEM ABASS
- MSC of Medical Imaging



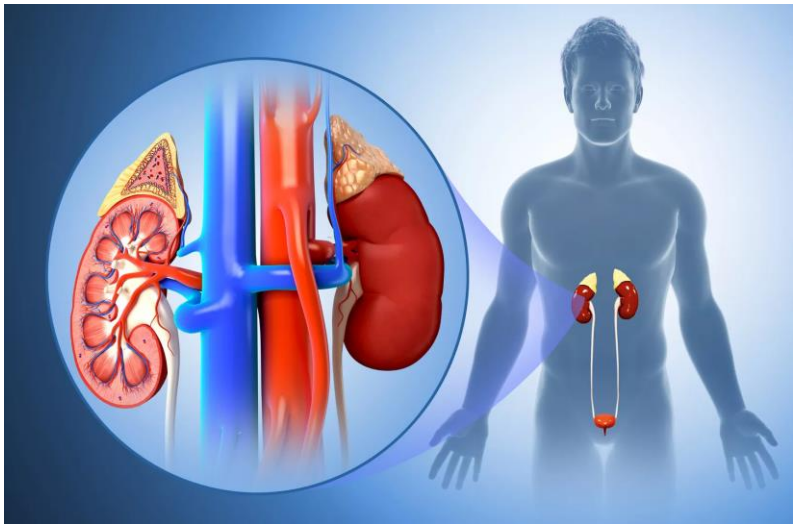



Anatomical Position

- The kidneys lie retroperitoneally (behind the peritoneum) in the abdomen, either side of the vertebral column.

- They typically extend from T12 to L3, although the right kidney is often situated slightly lower due to the presence of the liver. Each kidney is approximately three vertebrae in length.

- The adrenal glands sit immediately superior to the kidneys within a separate envelope of the renal fascia.

Anatomy of the Kidney

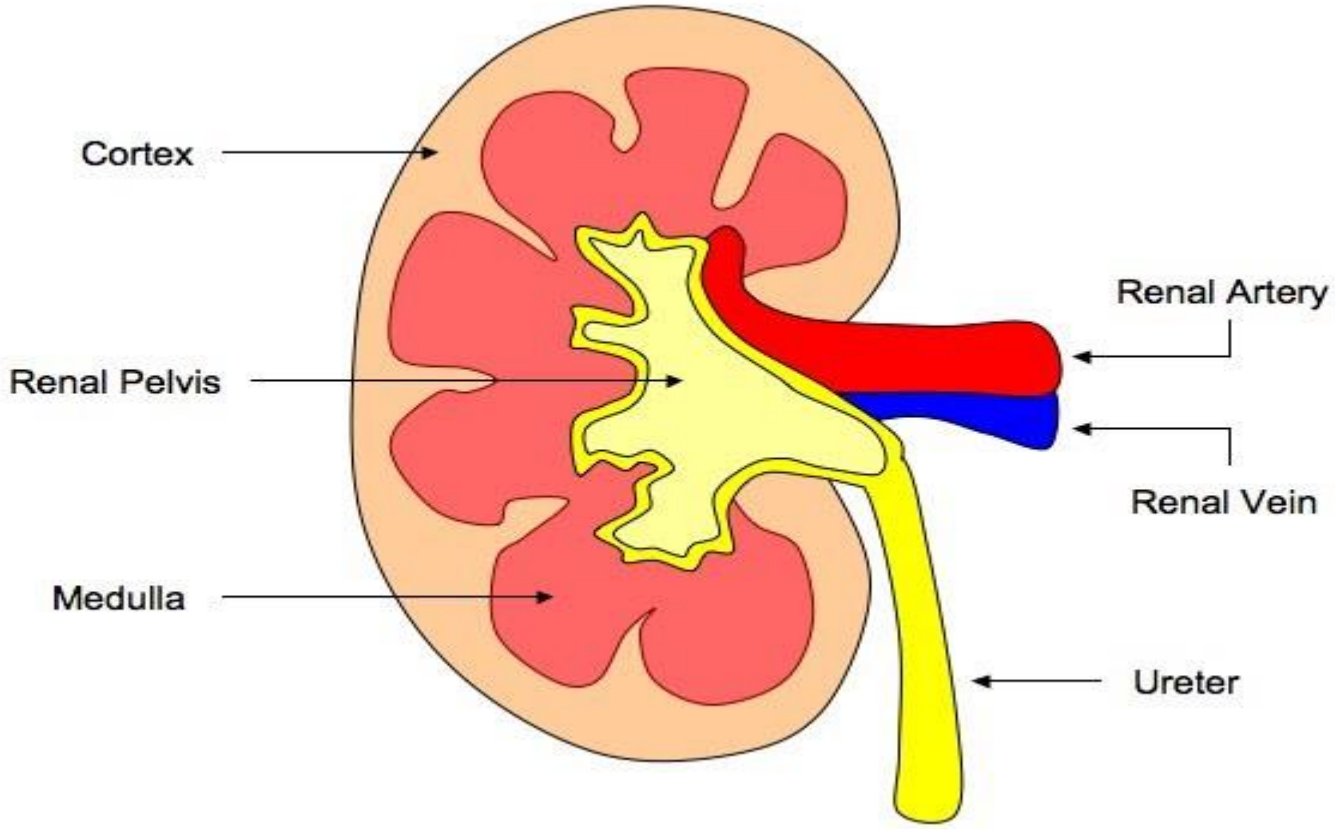

Patient positioning

Supine, head first with the arms above the head.

Topogram, scan range

Kidneys and adrenals only: diaphragm to iliac crest the pelvic kidney should be included in the image;

entire upper urinary tract: diaphragm to pubic symphysis.

Multiphase MSCT of the Kidney:

1) The initial non-enhanced (native scan) is indicated for:

a) Diagnosis of nephrolithiasis

b) Diagnosis of haemorrhage

c) Diagnosis of angiomyolipomas

d) As baseline for confirmation of subsequent enhancement

2) Early arterial (arteriographic phase): typically acquired after a scan delay of 20 seconds.

3) Late arterial (cortico-medullary) phase: typically acquired after a scan delay of 45 seconds. In this phase, the renal cortex is well enhanced, while the medulla is poorly enhanced. :

4) Nephrographic phase: typically acquired after a scan delay of 90-200 seconds. The renal cortex & medulla exhibit a similar degree of contrast enhancement.

5) Excretory phase: The scan delay for optimal opacification of the collecting system is variable & may range from 3-15 minutes (more than 200 seconds). This phase is useful for evaluation of the collecting system.

Native CT

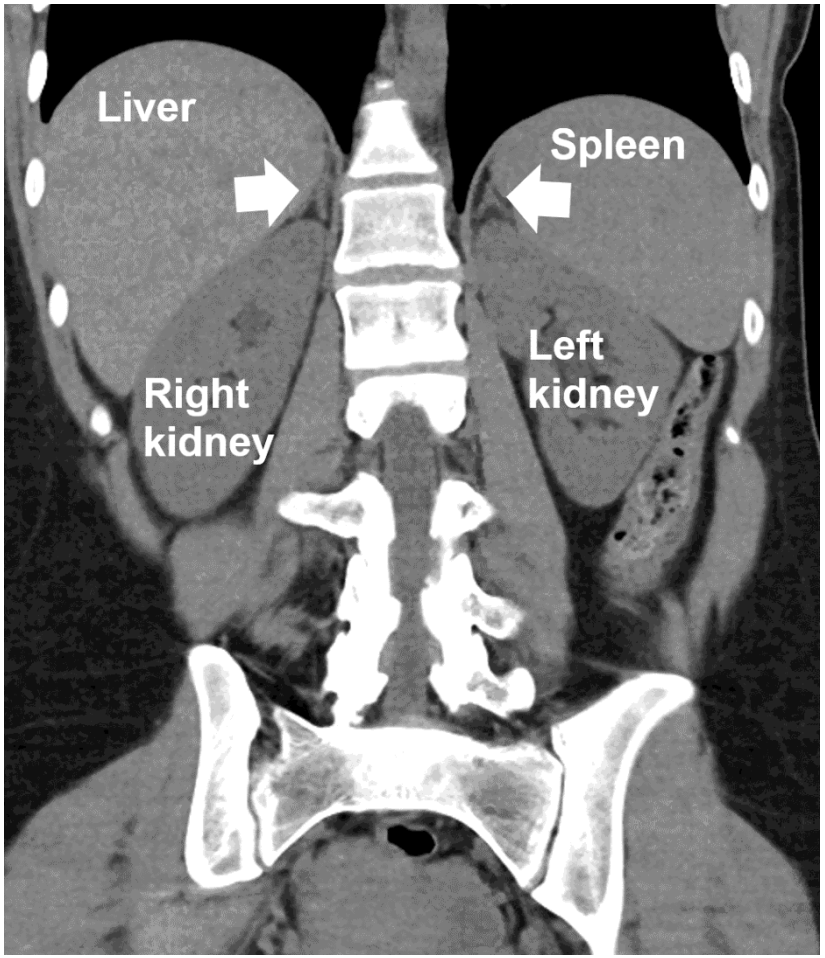

cortico-medullary) phase



Nephrographic phase

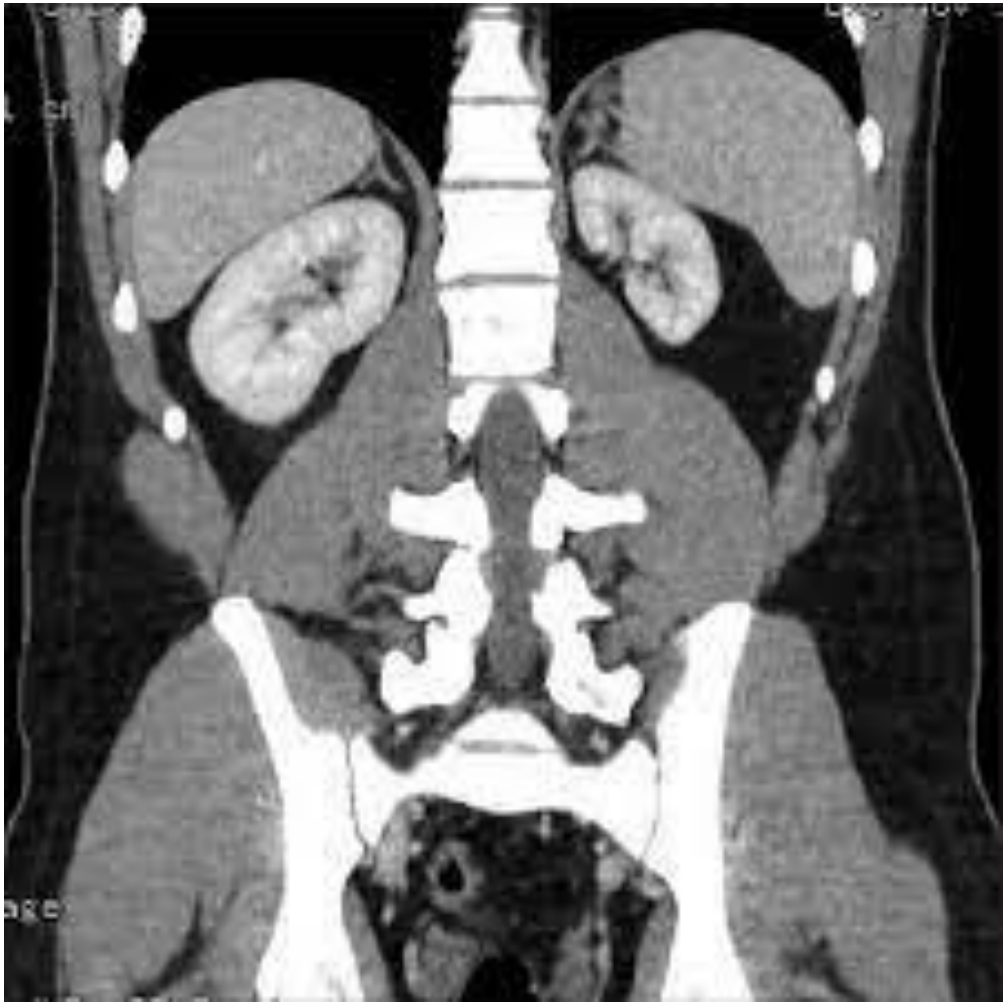

Nephrographic phase



Excretory phase



LT renal stone



RT renal stone



RT &LT renal stone



RT renal stone

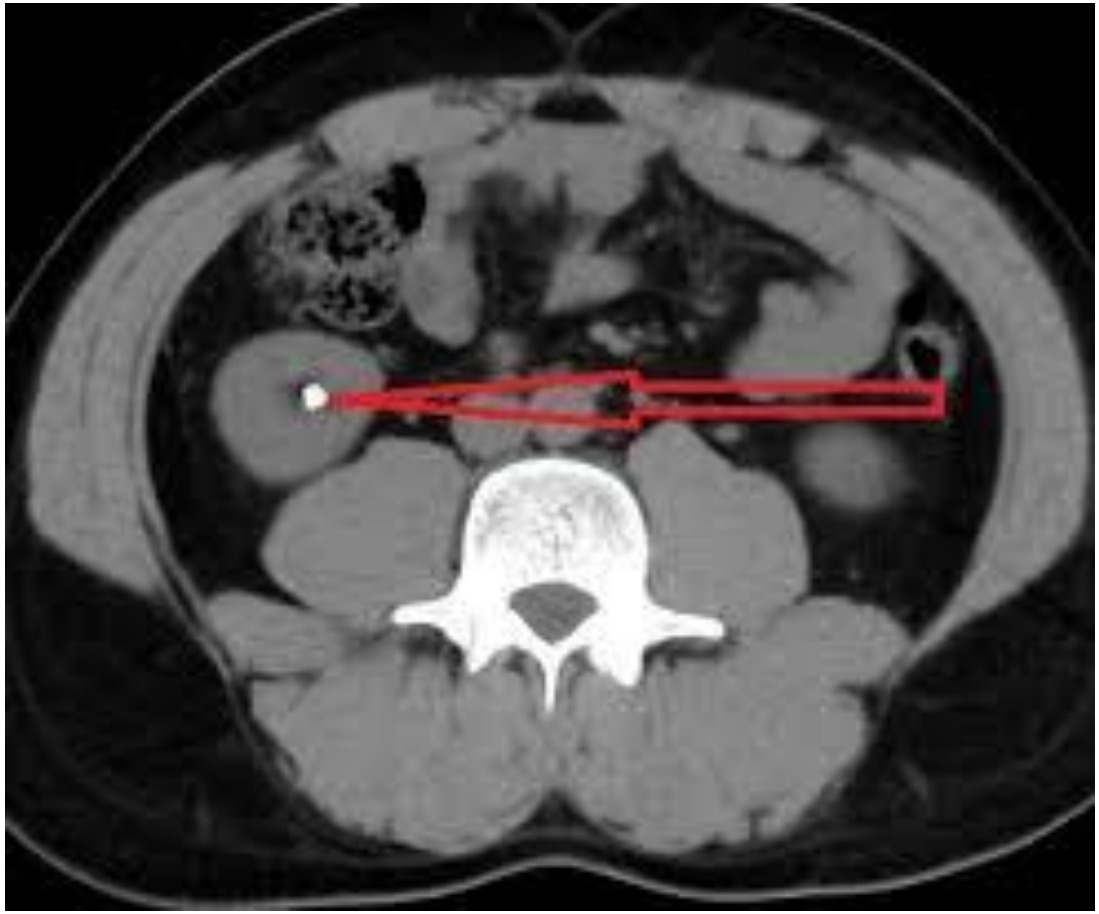

RT renal stone



RT renal MASS

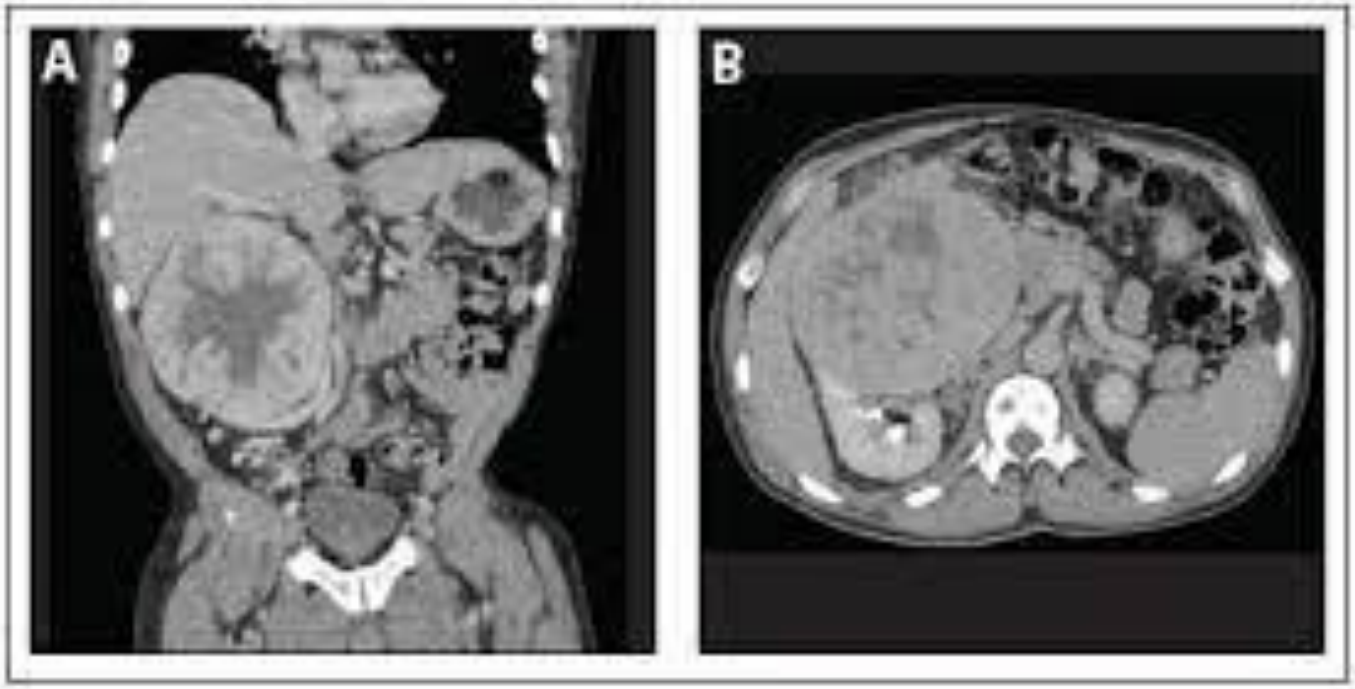

Figure: Abdominal CT Scan With Oral and Venous Contrast—(A) Sagittal image of right renal mass with central necrosis and multiple vascular collaterals; (B) Axial image of tumor enhanced by contrast, with no extension to renal vein seen.

RT renal MASS

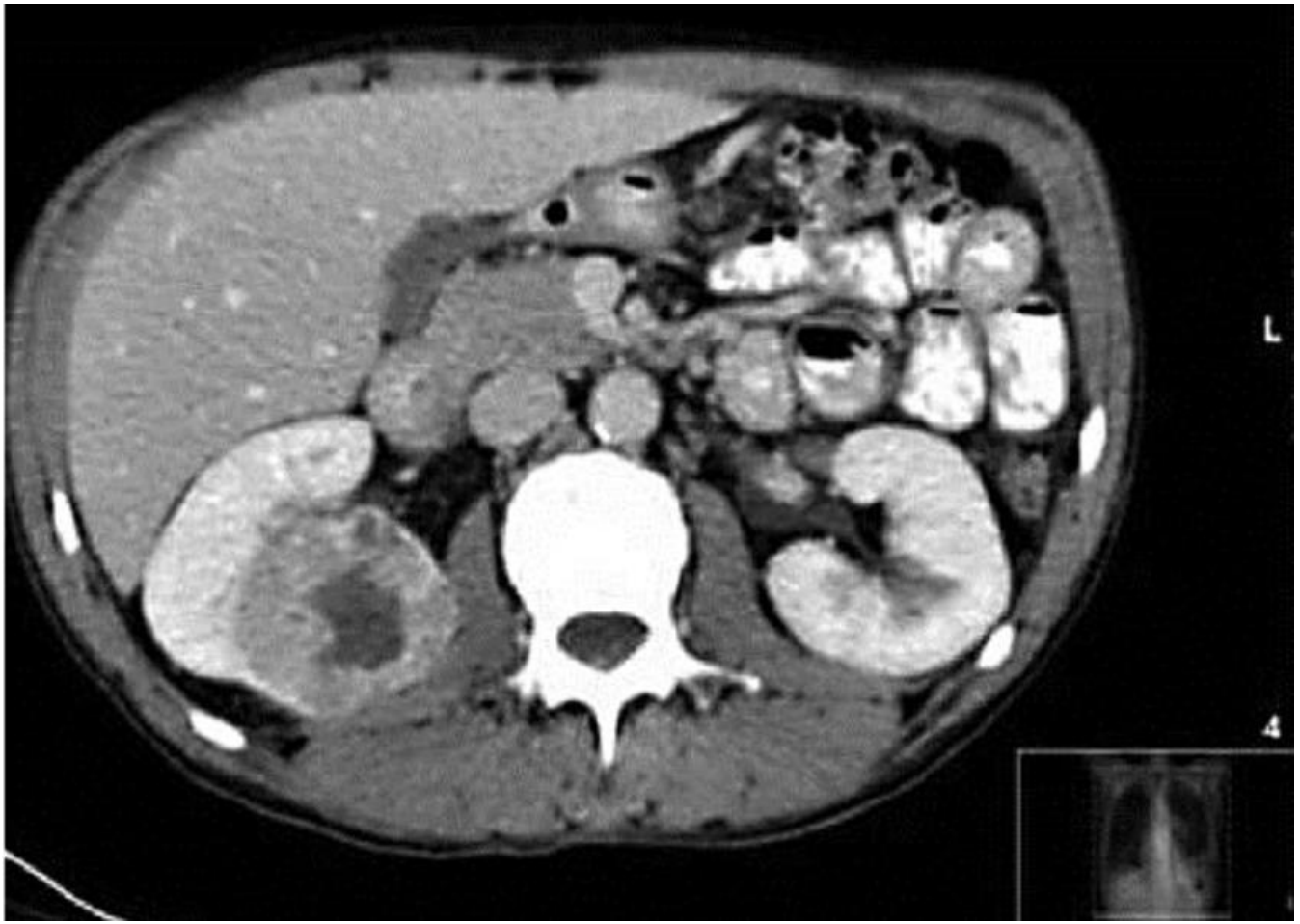

RT renal MASS

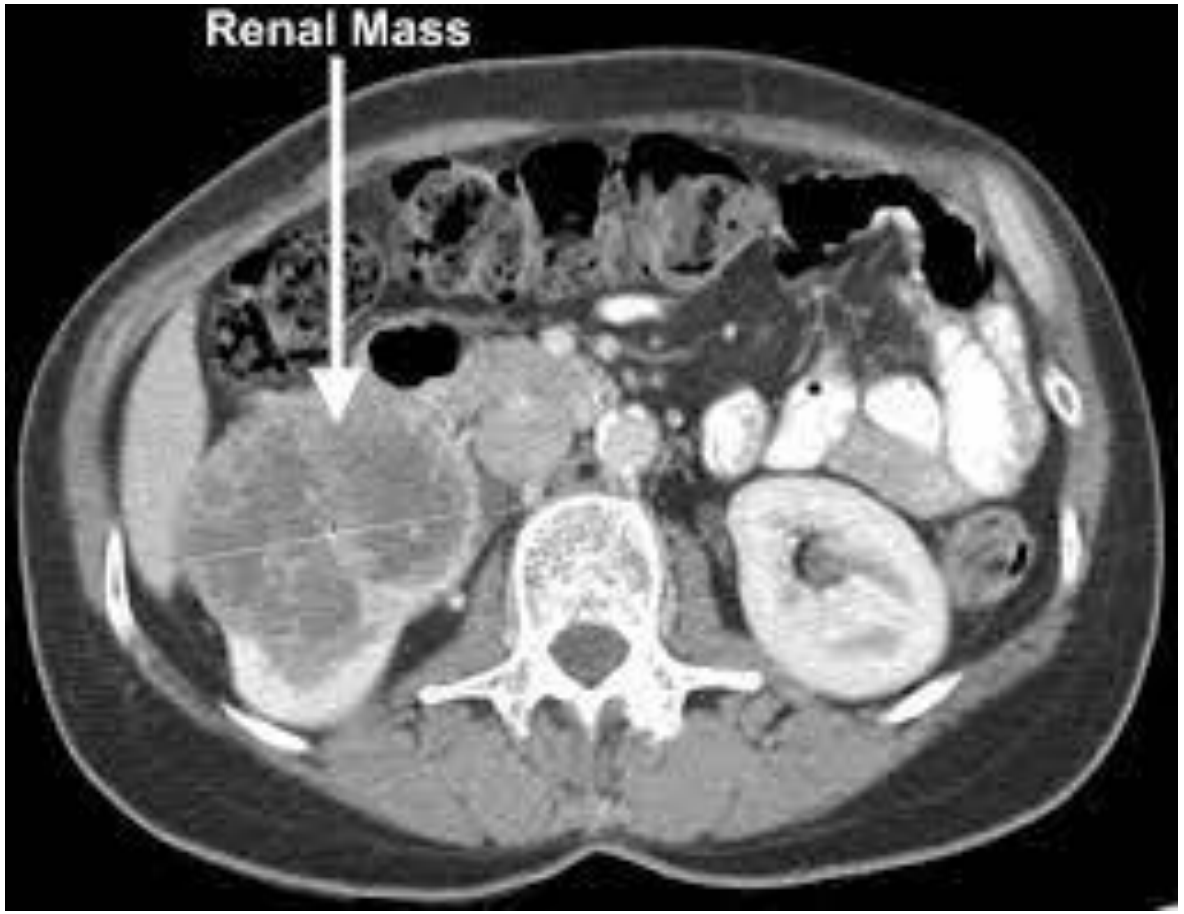

RT renal MASS



UB mass



Urinary bladder mass



Urinary bladder mass



Urinary bladder mass



Urinary bladder mass



Urinary bladder mass



UB stone



UB stone



UB stone



UB stone

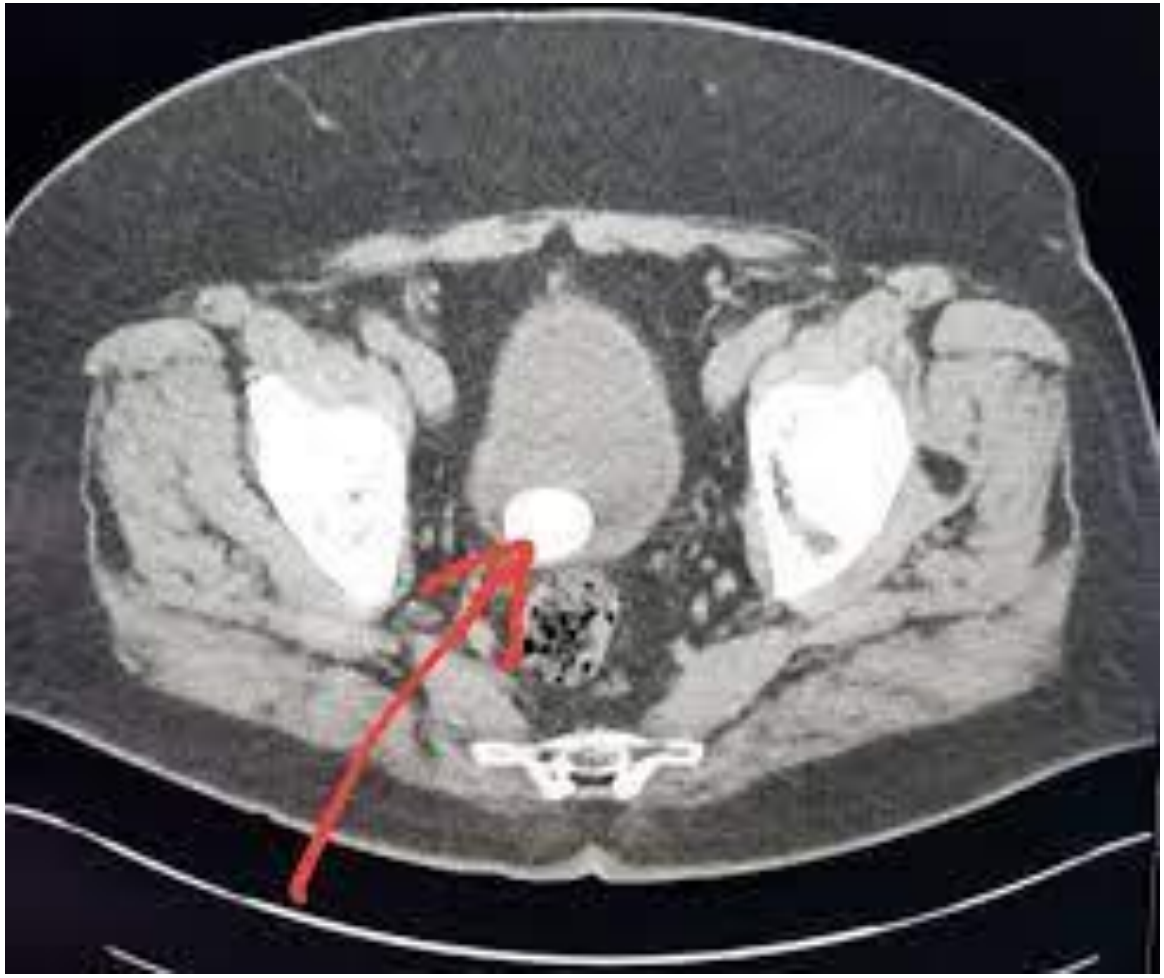

CT cystography

In patients with pelvic injury (suspected UB injury)

CT cystography is done. Contrast material (up to 400 ml) is infused into the U.B through a catheter. Then the pelvis is examined with a full bladder and after voiding.

UB perforation



UB perforation

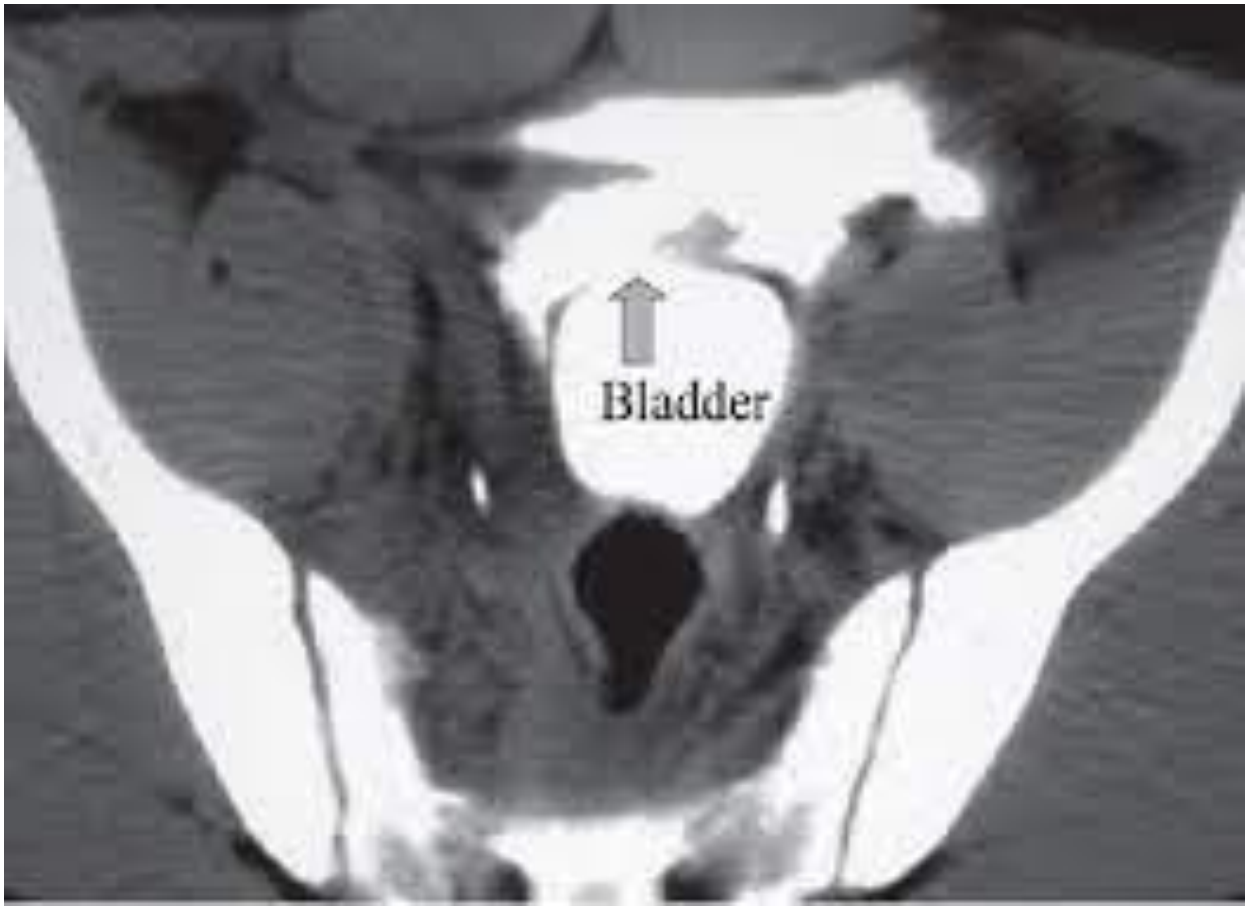

UB perforation



UB perforation

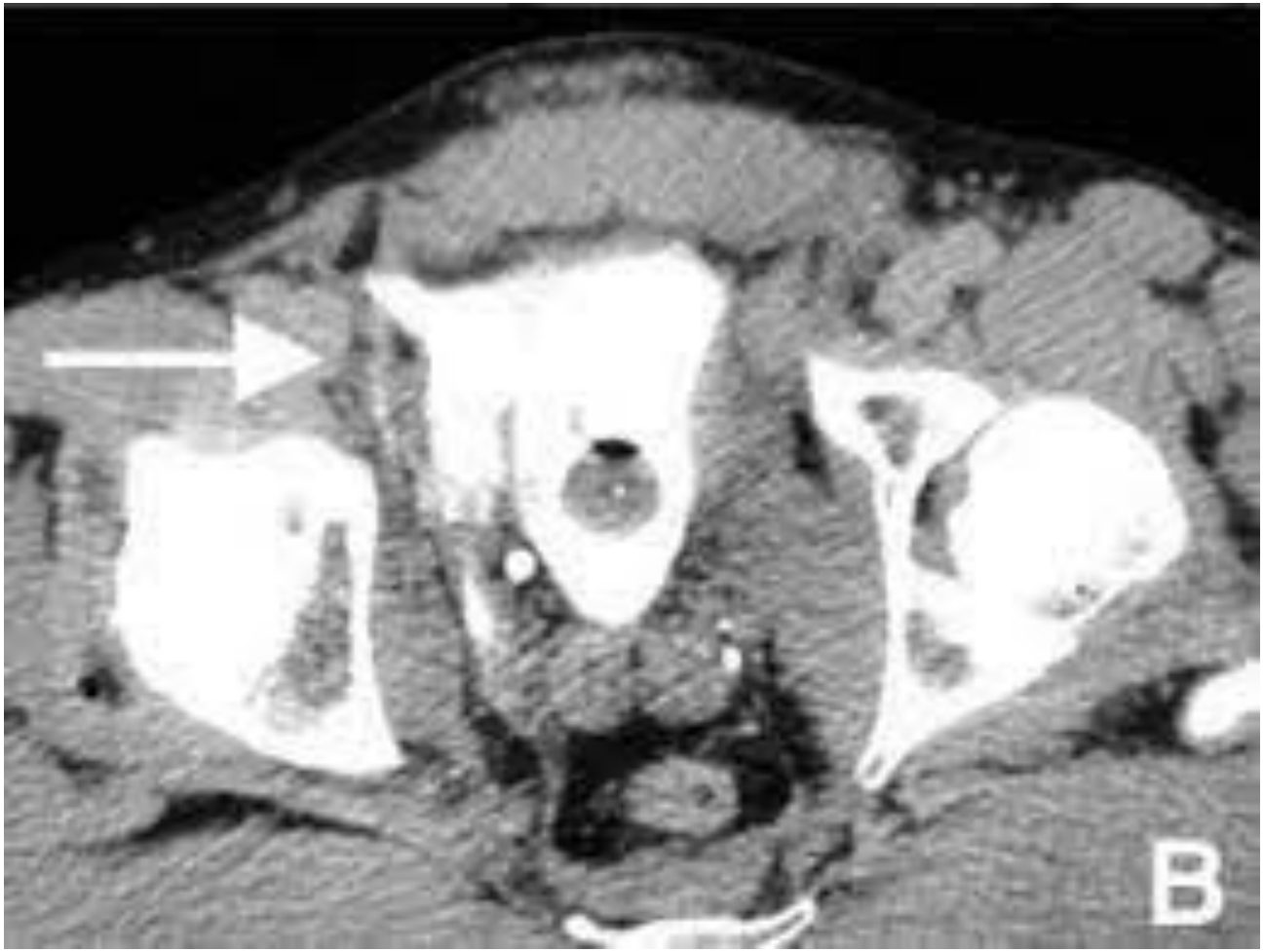

Renal cyst

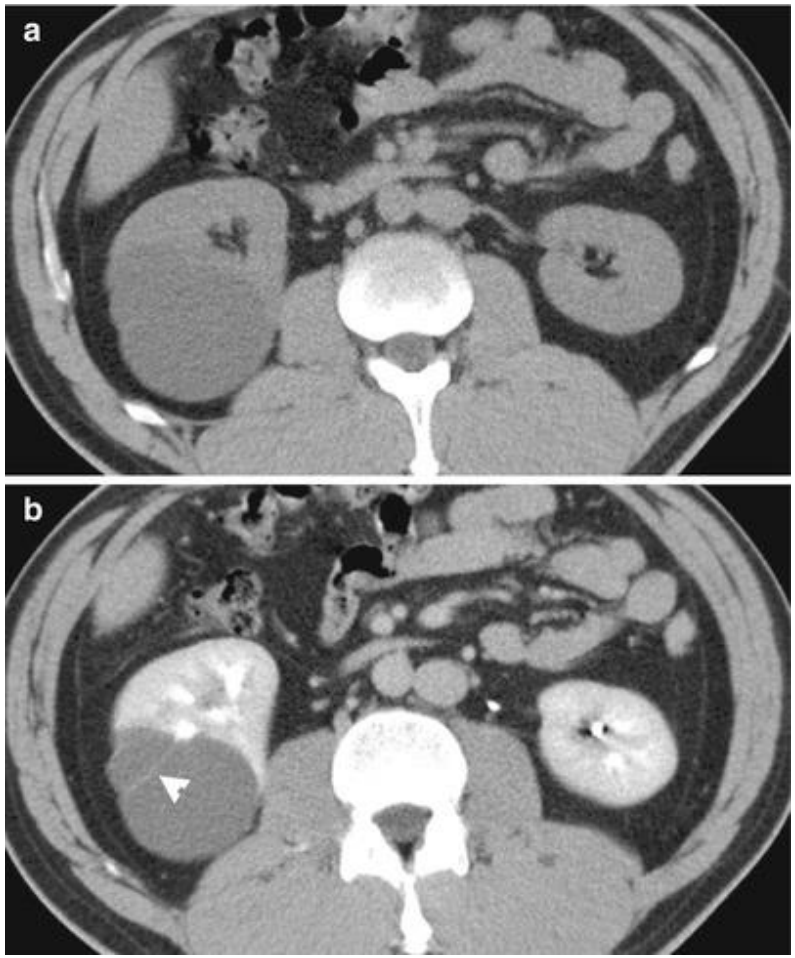

LT ureteric stone



LT ureteric stone



RT ureteric stone



English100

I never dreamed of success. I worked for it

لم أحلم يوماً بالنجاح ، بل عملت لتحقيقه

- Estee Lauder -

