Computed Tomography

- Multi Detector CT of the CT stomach &SM : BY AHMED JASEM ABASS
- MSC of Medical Imaging







The stomach

- The stomach is a dilated part of the alimentary canal between the esophagus and the small intestine.
- It is a muscular sac.
- It is a J-shaped.

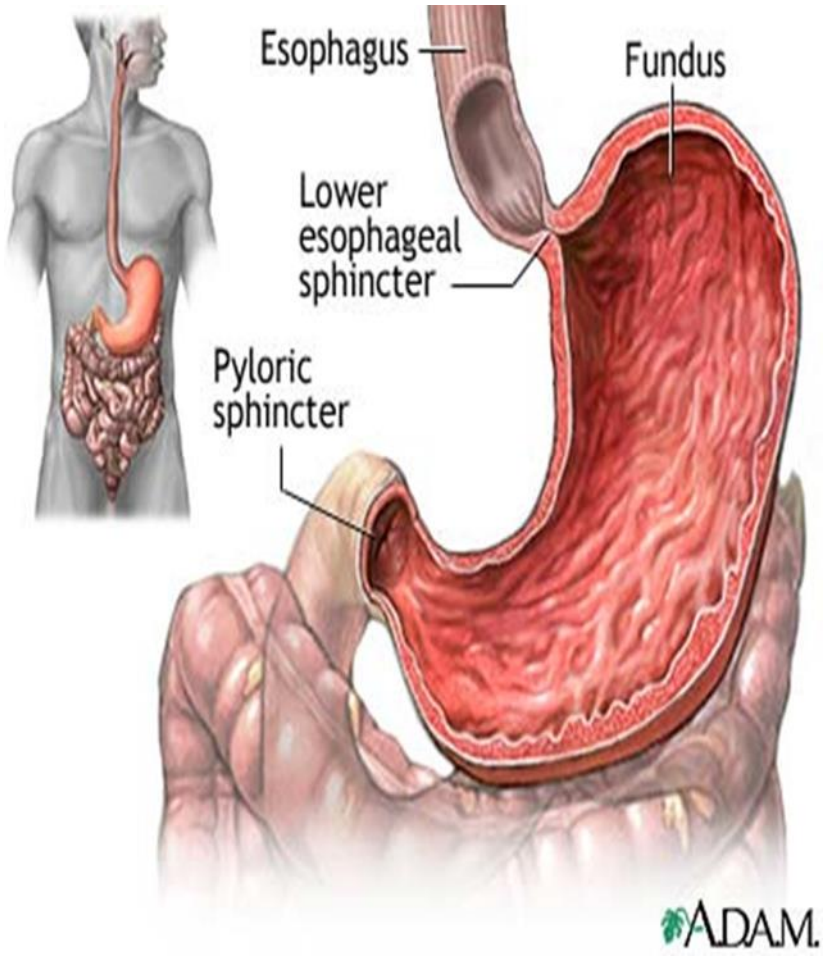

The stomach

- The stomach is divided into four regions:
- The cardia, which surrounds the opening of the esophagus into the stomach.
- The fundus of stomach, which is the area above the level of the cardial orifice.
- The body of stomach, which is the largest region of the stomach.
- The pyloric part, which is divided into the pyloric antrum and pyloric canal and is the distal end of the stomach.

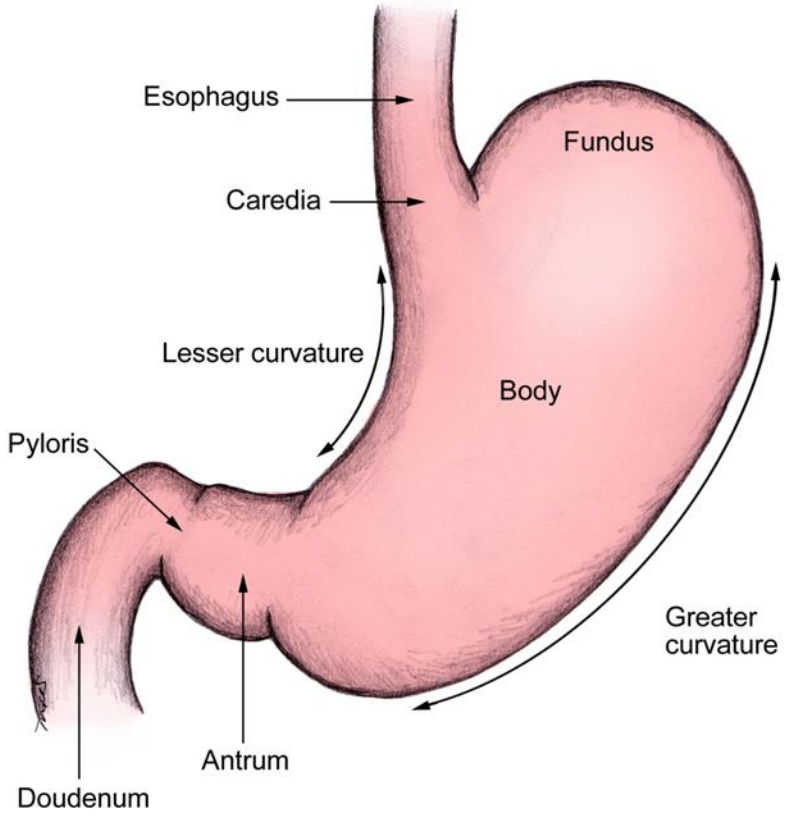

The stomach

- Computed tomographic (CT) gastrography, also called virtual gastroscopy (VG), is a noninvasive procedure for the detection of gastric abnormalities.
- Advantages
- rapid and noninvasive exam.
- offers information about local tumor invasion, lymph node and distant metastasis in cases of gastric cancer.



The stomach

- The relationship of the stomach to the structures of the stomach bed, such as the pancreas, the aorta, the spleen and the left kidney and adrenal, can be seen
- The thickness of the stomach wall varies considerably depending on the degree of distension and can appear thickened in the fasting state. Food in the stomach can appear as a pseudomass, and is seen especially in the dependent portion.
- The mucosa of the stomach enhances with intravenous contrast and the stomach layers are best appreciated in the arterial phase of contrast enhancement, when there is no positive contrast in the stomach



Indications

1. early detection of gastric carcinoma.
2. to examine gastric abnormalities, e.g. hiatus hernia, polyps and ulcers.
3. post-surgical assessment of the stomach.
4. CT gastrography and volumetry are used to assess the volume of the gastric pouch after bariatric surgery .



Technique

- patient preparation, fasting at least 8 hours before the exam bowel distension, optimal gastric distention is a fundamental prerequisite for CT gastrography data evaluation; collapsed gastric wall may mimic disease or obscure underlying pathology.
- negative oral contrast medium with effervescent granules is effective for optimal gastric distension.



Gastrography

- Data acquisition and analysis
- CT scanning is ideally performed on a multi-detector computed tomography (MDCT) with a thin collimation.
- data interpretation with the use of two-dimensional (2D) and three-dimensional (3D) displays for proper evaluation.



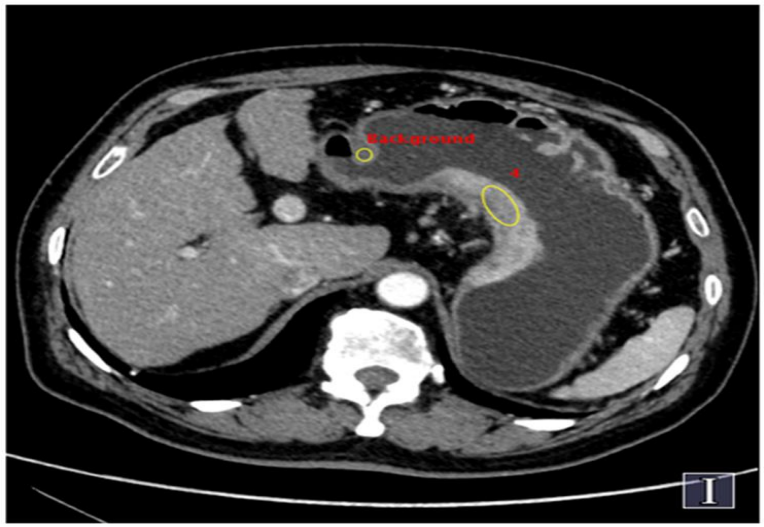

What is a virtual gastroscopy?

- Virtual endoscopy is a new-generation technique which combines the features of endoscopic viewing and cross-sectional volumetric imaging. In the evaluation of gastrointestinal cancers, virtual endoscopy has been most commonly used in colorectal carcinomas and to a much lesser extent in gastric carcinomas.
- Multidetector computed tomography with a stomach protocol, used in conjunction with virtual gastroscopy, shows good accuracy in the tumor and lymph node staging of gastric adenocarcinoma.



Virtual gastroscopy

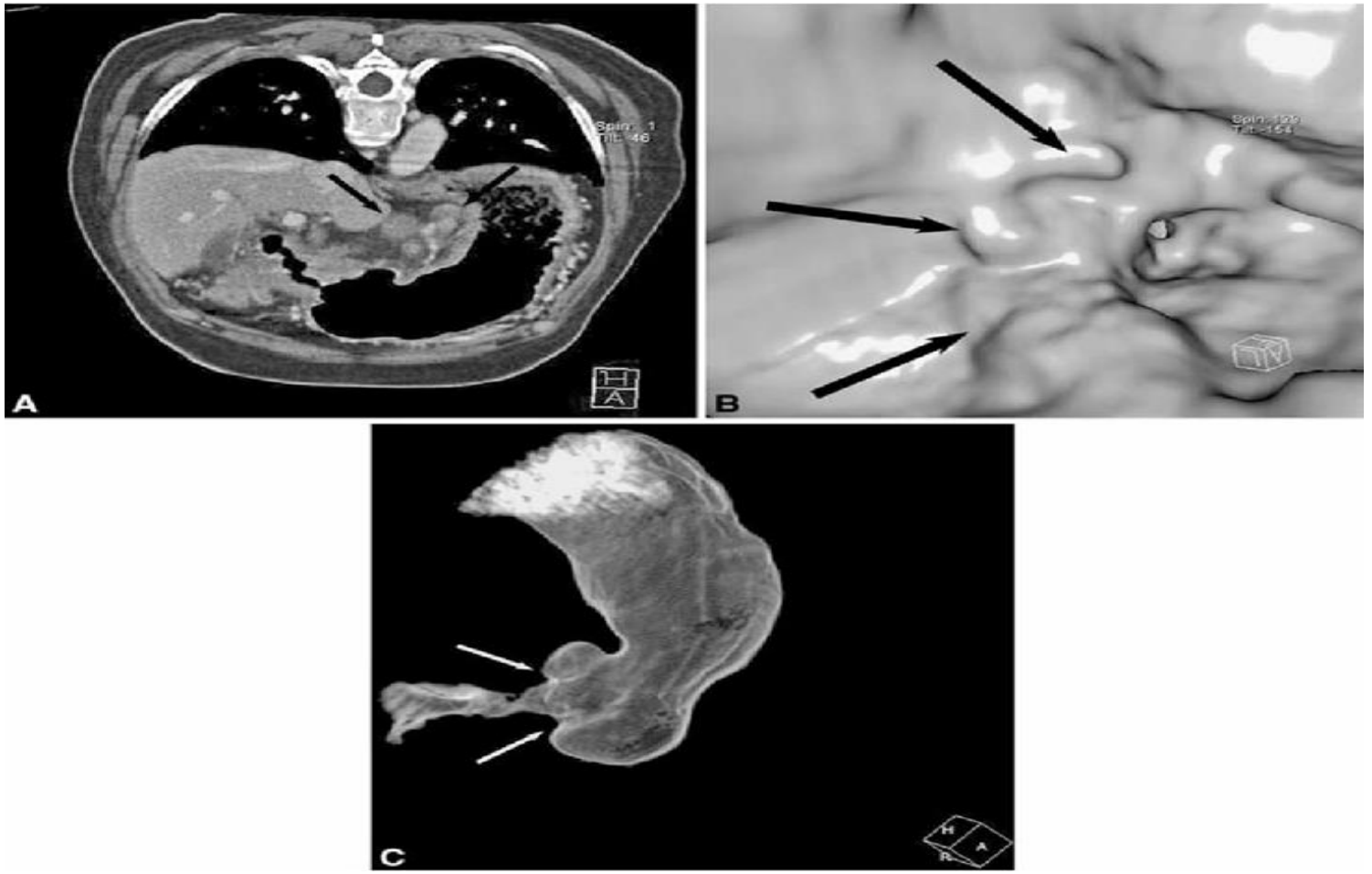

CT enterography OR CT enteroclysis

- CT enterography is a new non-invasive imaging technique that offers superior small bowel visualisation compared with standard abdomino-pelvic CT, and provides complementary diagnostic information to capsule endoscopy and MRI enterography. CT enterography is well tolerated by patients and enables accurate, efficient assessment of pathology arising from the small bowel wall or surrounding organs.



CT enterography

- Until recently, diagnosis of small bowel pathology had relied primarily on radiological techniques, in part due to the relative inaccessibility of the small bowel to conventional endoscopy. However, new endoscopic developments—notably the recent introduction of capsule endoscopy and double balloon enteroscopy—are challenging this position. Capsule endoscopy, for example, is now generally accepted as first-line investigation for occult gastrointestinal haemorrhage, and increasingly advocated for diagnosis of early Crohn's disease.



CT enterography

- However, the radiological community has not stood still. In parallel with the development of new endoscopic techniques, rapid progress has been made in cross-sectional imaging technologies, harnessing the power of multidetector row CT (MDCT), MRI and ultrasound, facilitating rapid, accurate and minimally invasive investigation of the small bowel and adjacent tissues.



Indications

- Indications for CT enterography include
- Crohn disease diagnosis and complications (primarily) most common indication
- suspected small bowel bleeding, usually performed after negative endoscopy suspected small bowel tumor, e.g. carcinoid, polyposis syndromes.
- celiac disease: assess for complications such as lymphomapartial small bowel obstructions, e.g. postoperative adhesions, radiation enteritis, scleroderma.
- chronic diarrhea and/or abdominal pain suspected chronic mesenteric ischemia.



CT enterography

- Advantages
- useful in the assessment of the solid organs and provides a global overview of the abdomen.

- Disadvantages
- exposure to ionizing radiation.



Technique

- Bowel preparation
- 1-abstain from all food and drink 4-6 hours before the exam.
- 2-patients drink about 1.5 L of oral contrast over 30-60 minute. adequate luminal distension is necessary as collapsed bowel loops may mimic pathology.
- 3-CT enterography utilizes negative or neutral oral contrast attenuation similar to that of water - e.g. water, PEG, mannitol, methylcellulose, locust bean gum, and low-density barium sulphate preparations (Volumen, 0.1% W/V) .
- Fluid distension of the small bowel allows better assessment of mucosal enhancement, mural thickness as well as mesenteric vasculature, this is important especially in the evaluation of Crohn disease.



CT enterography

- Procedure
- CT scanning is ideally performed on a multi-detector computed tomography (MDCT) scanner intravenous contrast.
- Crohn disease, celiac disease, postoperative adhesions, radiation enteritis, and scleroderma: a single enteric phase where peak mucosal enhancement is achieved is sufficient - either enteric phase (45-50s) or portal venous phase (60-70s).
- small bowel tumors: an additional arterial phase can be performed, in particular for the assessment of hypervascular lesions (e.g. neuroendocrine tumors)
- in cases of suspected GI bleeding, pre-contrast, arterial, portal venous, and delayed phases should be considered.



CT enterography

- Findings
- inflammatory bowel disease and its complications e.g. Crohn disease small bowel tumors, including benign tumors (e.g. hamartomatous or hyperplastic polyps) or malignant tumors (e.g. adenocarcinoma, carcinoid, lymphoma and gastrointestinal stromal tumors)
- mesenteric ischemia and gastrointestinal tract bleeding
- Celiac disease .



Crohn disease

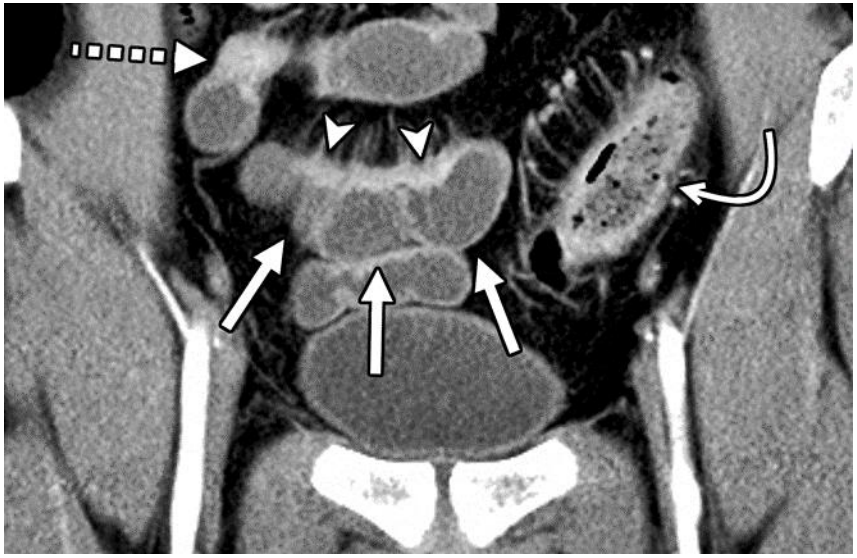

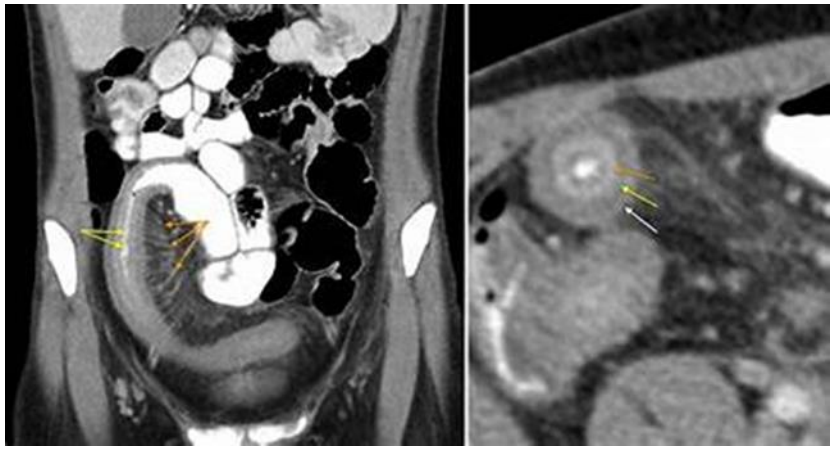

Figure 1b. Asymmetric mural hyperenhancement in two patients with Crohn disease.. The CT image (b) also shows active inflammation with luminal narrowing in a different small bowel loop (dashed arrow in b) and inflammation of the distal colon (curved arrow in b).

The coronal image on the left shows a long segment of very abnormal distal ileum. The bowel wall is thickened and oedematous (see below).



hyperplastic polyps

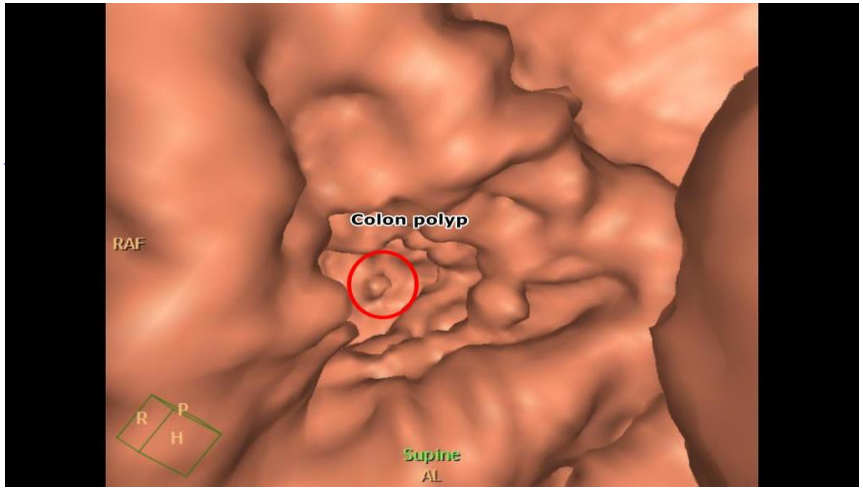

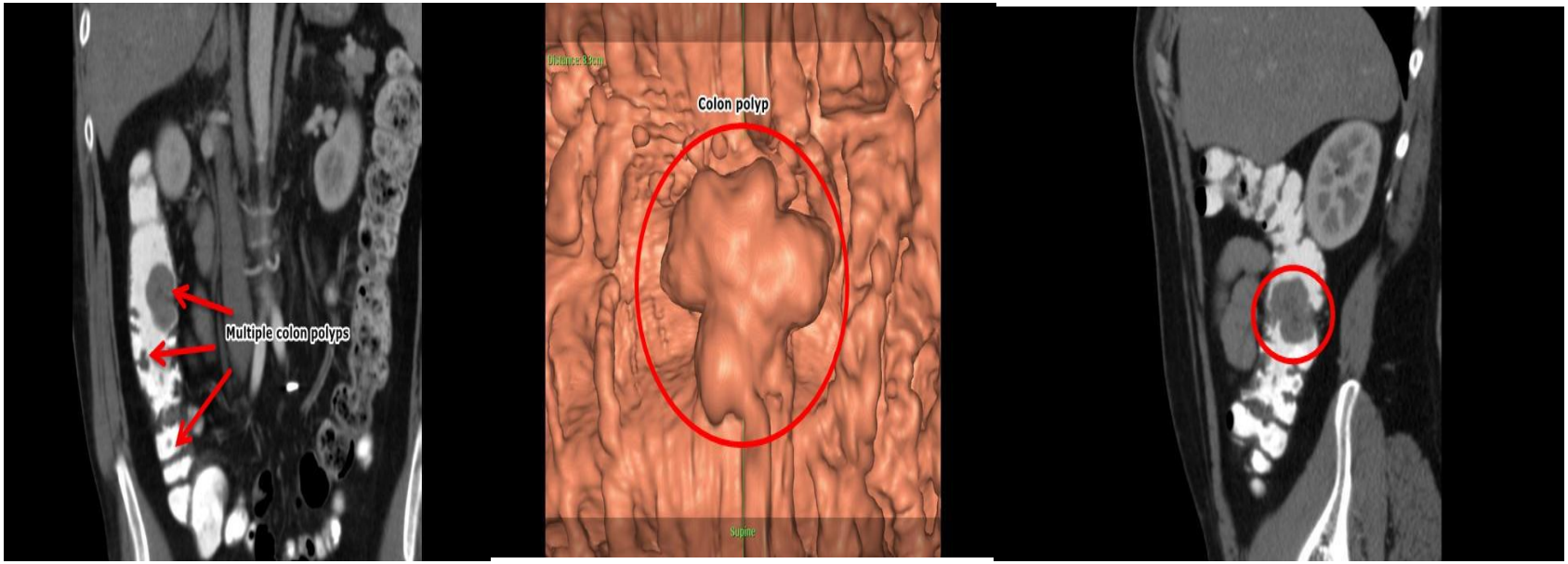

Coronal CT scan shows multiple pedunculated colon polyps-

Sagittal CT scan shows colon polyp-Case

Celiac disease

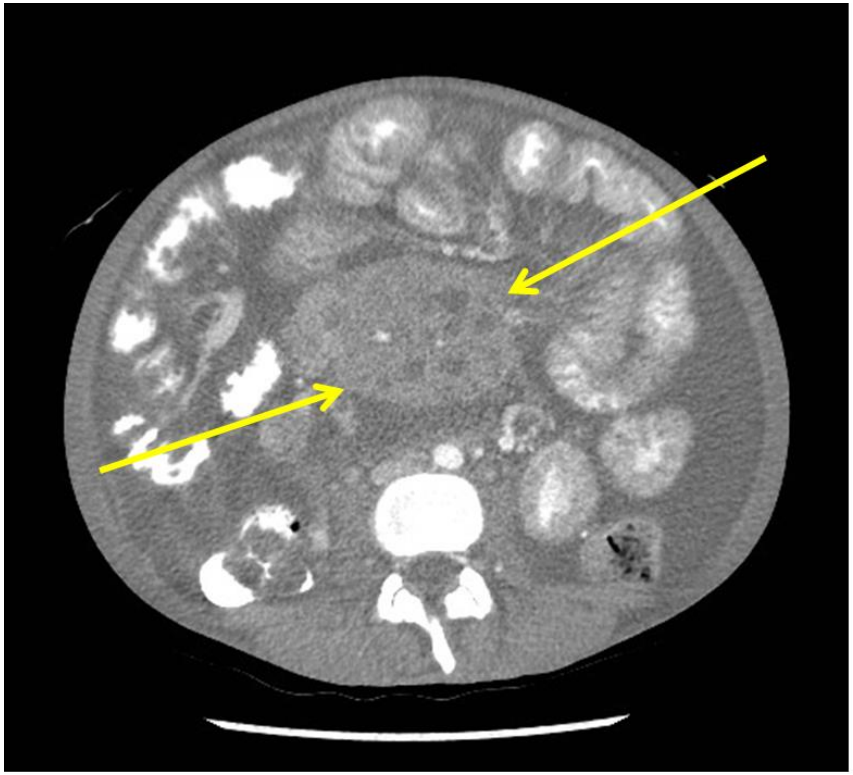



Mesenteric lymphadenopathy associated with celiac diesease

Mesenteric ischemia

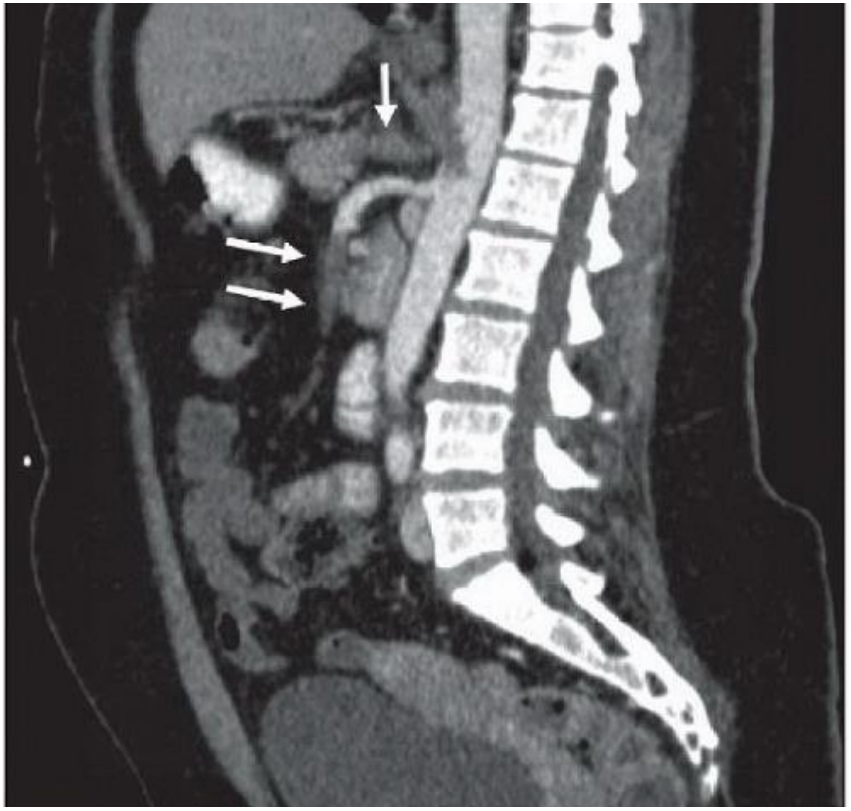

Sagittal contrast-enhanced CT image of the abdominal aorta demonstrates filling defects in the enlarged proximal celiac artery and mid and distal superior mesenteric artery, consistent with acute thromboemboli

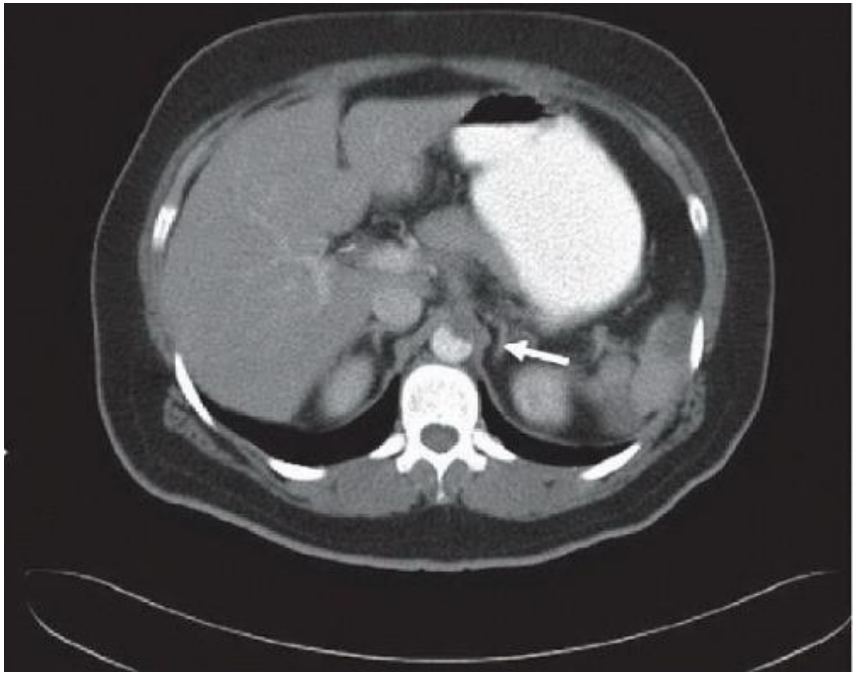

Axial contrast-enhanced CT image of the upper abdomen demonstrates thrombus within the anterior abdominal aorta (arrow).

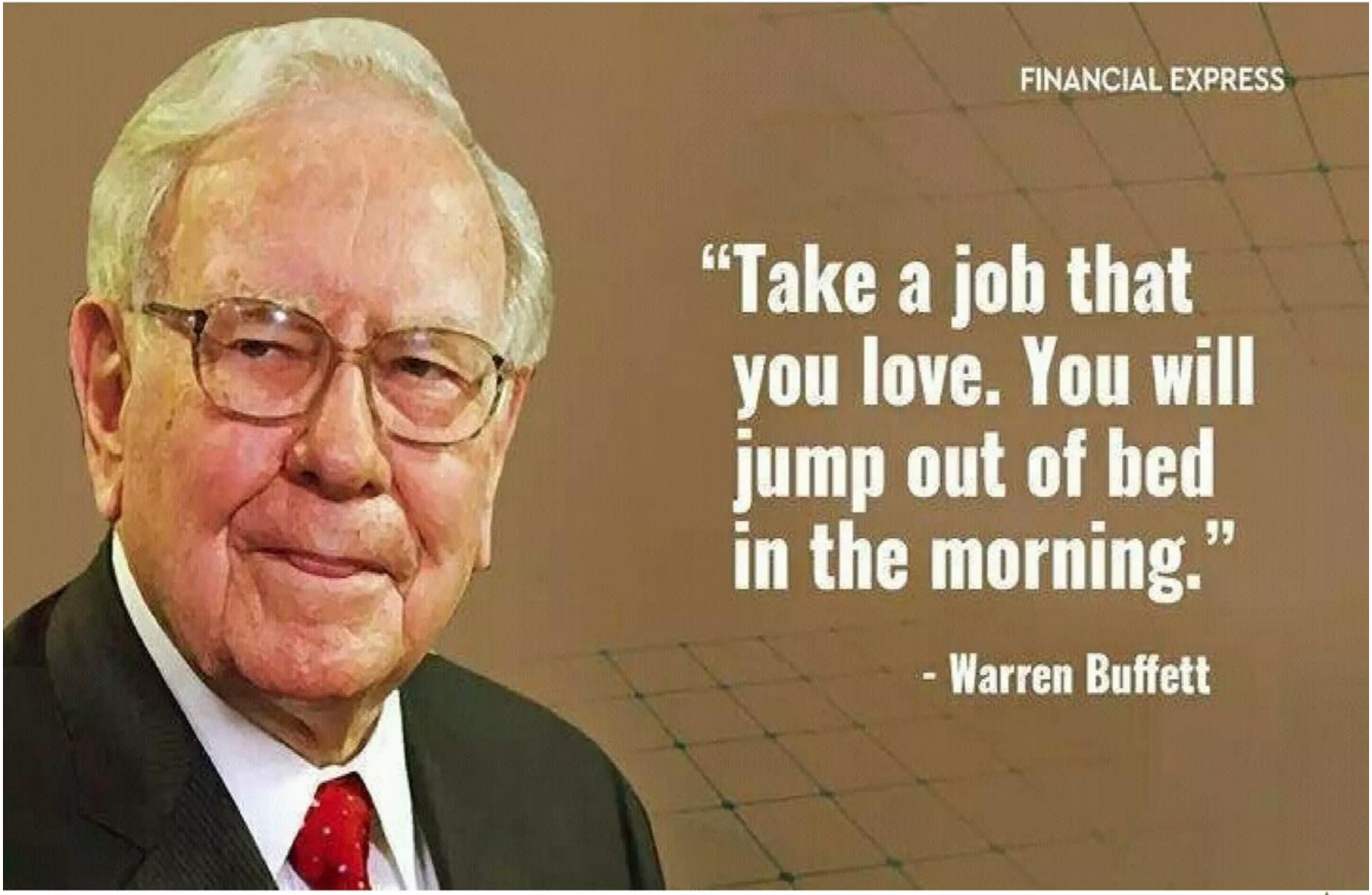

First hospital in Gurgaon to be JCI and NABH accredited.

Thank You !!!